

Case Report
Medical Imaging



Radiography and ct features of atherosclerosis in two miniature schnauzer dogs

Eunji Lee ^{1,†}, Hyun Woo Kim ^{1,†}, Hyeona Bae ², DoHyeon Yu ^{2,*}, Jihye Choi ^{1,*}

¹College of Veterinary Medicine, Chonnam National University, Gwangju 61186, Korea

²College of Veterinary Medicine, Gyeongsang National University, Jinju 52828, Korea

 OPEN ACCESS

Received: Aug 20, 2020

Accepted: Sep 28, 2020

*Corresponding authors:

DoHyeon Yu

College of Veterinary Medicine, Gyeongsang National University, Jinju 52828, Korea.

E-mail: yudh@gnu.ac.kr

Jihye Choi

College of Veterinary Medicine, Chonnam National University, Gwangju 61186, Korea.

E-mail: imsono@jnu.ac.kr

[†]Eunji Lee and Hyunwoo Kim equally contributed to this work.


© 2020 The Korean Society of Veterinary Science

This is an Open Access article distributed under the terms of the Creative Commons Attribution Non-Commercial License (<https://creativecommons.org/licenses/by-nc/4.0>) which permits unrestricted non-commercial use, distribution, and reproduction in any medium, provided the original work is properly cited.


ORCID iDs

Eunji Lee 


<https://orcid.org/0000-0003-2324-0755>

Hyun Woo Kim 


<https://orcid.org/0000-0002-4692-3017>

Hyeona Bae 

<https://orcid.org/0000-0002-2888-5782>

DoHyeon Yu 

<https://orcid.org/0000-0001-7645-6926>

Jihye Choi 

<https://orcid.org/0000-0002-1258-7158>

ABSTRACT

Two miniature Schnauzer dogs with chronic pancreatitis were investigated. Both dogs showed systemic hypertension and increased concentrations of triglycerides and C-reactive protein. Abdominal radiography revealed cylindrical calcification in the retroperitoneum, and computed tomography (CT) showed extensive calcification of the abdominal and peripheral arteries in both dogs. Metastases and other dystrophic conditions that can cause arterial calcification were excluded based on the laboratory tests, and the dogs were diagnosed with atherosclerosis ante mortem. Atherosclerosis should be considered when extensive arterial calcification is observed on abdominal radiography or CT in miniature Schnauzers.

Keywords: Arterial calcification; computed tomography C-reactive protein; hypertension; case report

INTRODUCTION

Atherosclerosis is defined as focal thickening of the arterial walls associated with lipid deposition [1]. Plaque develops in the arterial walls, and inflammation promotes plaque progression with micro- and macrocalcification. Atherosclerosis can be confirmed through a histopathology examination. On the other hand, because of the invasiveness of sampling, diagnostic imaging is used alternatively to assess the presence and degree of atherosclerosis in practice [2]. Only a few reports have described the ante mortem imaging features of atherosclerosis in dogs [3]. Moreover, to the best of the authors' knowledge, there are no reports on the computed tomography (CT) features of atherosclerosis in dogs. The present report describes the diagnostic approach of atherosclerosis ante-mortem in 2 miniature Schnauzer dogs and suggests the possible risk factors of atherosclerosis in these dogs.

CASE PRESENTATION

A 10-year-old, neutered male (dog 1) and a 15-year-old, spayed female (dog 2), miniature Schnauzer dogs presented with vomiting, depression, and decreased appetite for 1–2 weeks. Both dogs had a history of chronic pancreatitis, systemic hypertension (150–160 mmHg),

Funding

This research was supported by the Animal Medical Institute of Chonnam National University and Basic Science Research Program through the National Research Foundation of Korea (NRF), funded by the Ministry of Science, ICT, and Future Planning (NRF-2018R1A2B6006775 and NRF-2020R1C1C1008675).

Conflicts of Interest

The authors declare no conflicts of interest.

Author contribution

Conceptualization: Choi J, Yu DH; Data curation: Kim H; Formal analysis: Kim H; Funding acquisition: Yu DH, Choi J; Investigation: Lee E, Kim H, Yu DH, Choi J; Methodology: Kim H, Yu DH, Choi J; Project administration: Yu DH, Choi J; Software: Lee E, Choi J; Supervision: Yu DH, Choi J; Validation: Lee E, Kim H, Bae H, Yu DH, Choi J; Visualization: Yu DH, Choi J; Writing - original draft: Lee E, Kim H; Writing - review & editing: Bae H, Yu DH, Choi J.

normocytic normochromic non-regenerative anemia, and increased triglycerides, alkaline phosphatase, specific canine pancreatic lipase, and C-reactive protein (CRP) (**Table 1**).

In dog 1, hepatomegaly and a pair of cylindrical calcifications were observed in the retroperitoneum on radiography (**Fig. 1A**). CT was performed using a 16-channel multi-detector row CT scanner (Somatom EMOTION, Siemens, Germany) with the following settings: 120 kVp, 130 mA; slice thickness, 1 mm; and pitch, 1. Marked and extensive calcification of the vascular walls was observed in the carotid, lingual, and maxillary arteries in the cervix, the coronary and pulmonary arteries in the thorax and aorta, and the celiac, cranial mesenteric, renal, iliac, lumbar, and caudal gluteal arteries in the abdomen (**Fig. 2A and B**). The primary causes of the arterial calcification, such as calcium metastasis, hyperadrenocorticism, chronic kidney diseases, were excluded based on the laboratory tests. Finally, the arterial calcification was diagnosed as atherosclerosis. Further examinations related to hypothyroidism and dyslipoproteinemia were performed to identify the risk factors of atherosclerosis. Hypothyroidism was excluded based on a thyroid panel. No evidence of dyslipoproteinemia characterized by a high LDL and low HDL was detected by serum lipid-profile analysis (IDEXX Laboratories Inc., USA). The dog was started on a low-fat diet to manage the hypertriglyceridemia, and did not show any clinical signs during 2 months of follow-up and was lost to further monitoring.

In dog 2, a mild decrease in the serosal detail in the cranial abdomen was detected on radiography (**Fig. 1B**). Extrahepatic bile duct obstruction due to severe pancreatitis was diagnosed by ultrasonography, and conservative treatment for pancreatitis was performed.

Table 1. Hematologic and biochemical findings of the 2 dogs

| Variables | Dog 1 | Dog 2 | Reference range |
|----------------------------------------|-------|-------|-----------------|
| Hematocrit (%) | 32.4 | 33 | 37.3–61.7 |
| Reticulocyte count ($\times 10^9/L$) | 38.6 | 7.2 | 10–110 |
| Alanine transaminase (U/L) | 50 | 2,471 | 110–320 |
| Alkaline phosphatase (U/L) | 536 | 9,500 | 23–212 |
| γ -glutamyl transferase (U/L) | 0 | 57 | < 11 |
| Bilirubin (mg/dL) | 0.2 | 10 | < 0.9 |
| Cholesterol (mg/dL) | 118 | 499 | 110–320 |
| Triglyceride (mg/dL) | 290 | 280 | 10–110 |
| Glucose (mg/dL) | 110 | 86 | 70–143 |
| Spec cPL ($\mu g/dL$) | 447 | 1,504 | < 200 |
| CRP (mg/L) | 148 | 27.6 | < 20 |
| Serum total calcium (mg/dL) | 9.5 | 11.2 | 7.9–12 |
| Ionized calcium (mmol/L) | 1.36 | 1.41 | 1.12–1.42 |
| Phosphate (mg/dL) | 4.7 | 4.9 | 2.5–6.8 |
| LDDST | | | |
| Resting cortisol ($\mu g/dL$) | 1.2 | 2.1 | 2–6 |
| Cortisol at 4 hr ($\mu g/dL$) | < 0.5 | 1.5 | 0–1.4 |
| Cortisol at 8 hr ($\mu g/dL$) | < 0.5 | 0.9 | 0–1.4 |
| Serum thyroid panel* | | | |
| Serum T ₄ ($\mu g/dL$) | 1.5 | n/a | 1.0–4.0 |
| Free T ₄ ($\mu g/dL$) | 2.2 | n/a | 0.7–3.7 |
| Endogenous TSH (ng/mL) | 0.12 | n/a | 0.03–0.4 |
| Serum lipid profile analysis† | | | |
| HDL (mg/dL) | 83 | n/a | 97–173 |
| LDL (mg/dL) | 12.5 | n/a | < 75 |
| LDL:HDL ratio | 0.15 | n/a | |

Spec cPL, specific canine pancreatic lipase (IDEXX Laboratories Inc., USA); CRP, C-reactive protein (LifeAssays AB, Sweden); LDDST, low-dose dexamethasone suppression test; T₄, thyroxine; n/a, not available; TSH, thyroid-stimulating hormone; HDL, high-density lipoprotein; LDL, low-density lipoprotein.

*Serum thyroid panel, IDEXX Laboratories Inc.; †Serum lipid profile analysis, IDEXX Laboratories Inc.

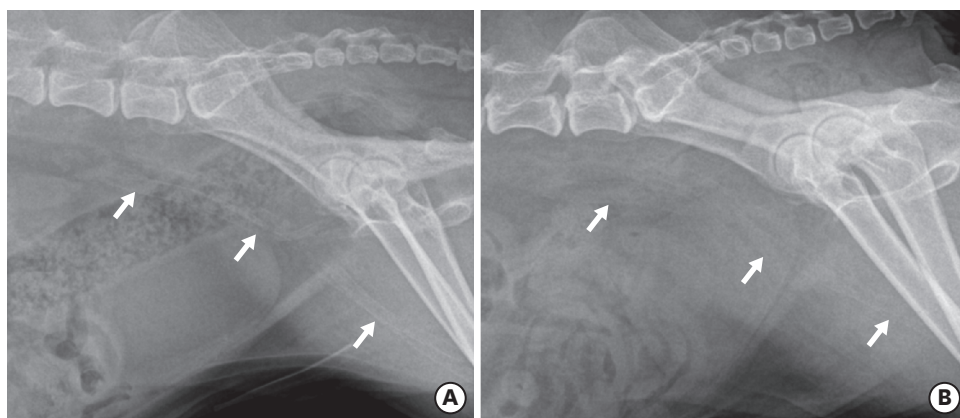


Fig. 1. Abdominal radiography of dog 1 (A) and dog 2 (B); right lateral views. A pair of cylindrical calcifications in the level of retroperitoneum, extending from the 7th lumbar vertebra to the hindlimbs are noted (arrows).

At the 21-day follow-up, calcification of the retroperitoneal vessel was newly identified by radiography. The CT images revealed marked calcification of the caudal abdominal aorta and bilateral external iliac arteries to the peripheral branches (**Fig. 2C**). Metastatic calcification

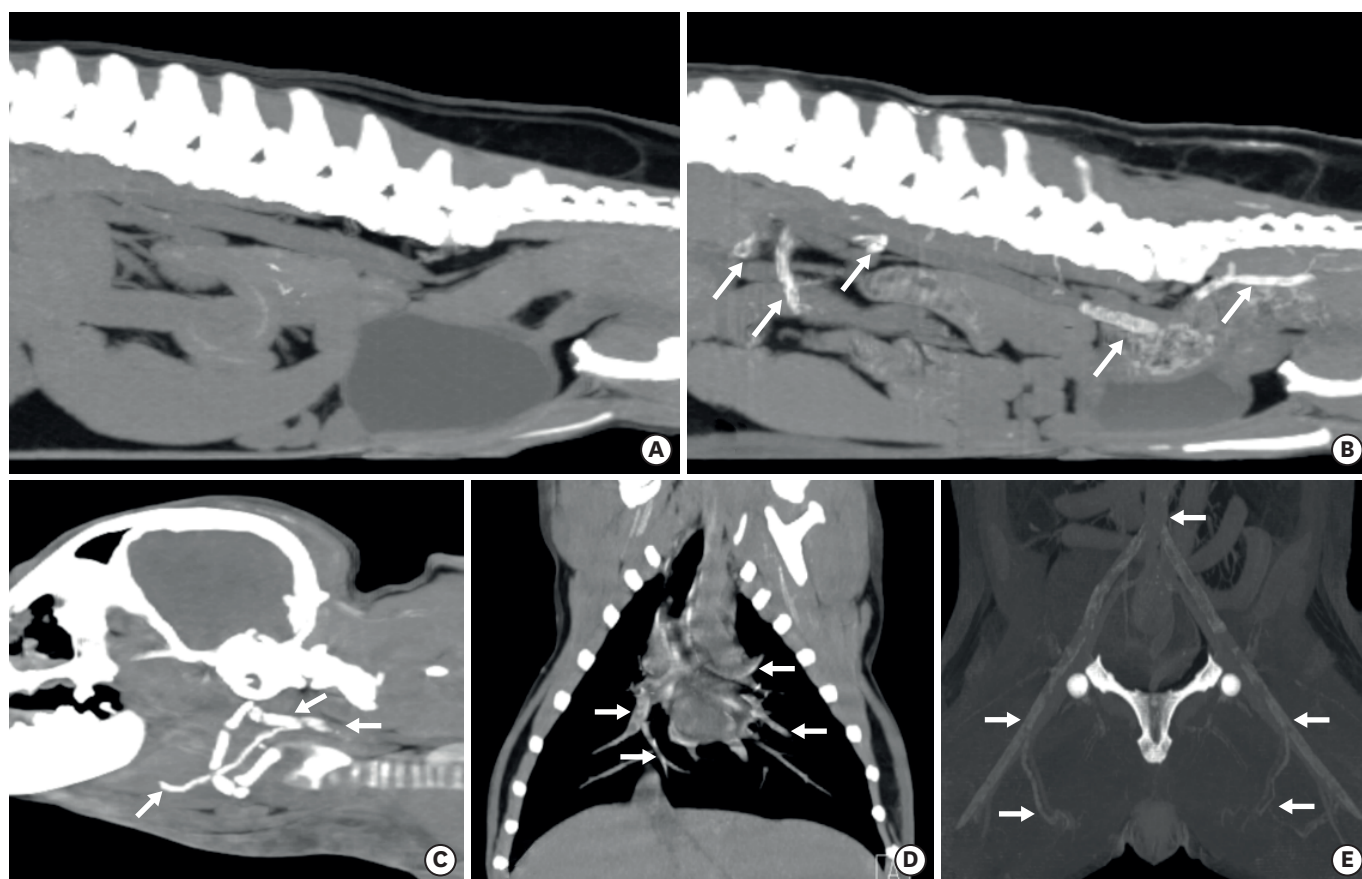


Fig. 2. Maximal intensity projection CT reconstruction of Dog 1 (A-D) and Dog 2 (E). On sagittal plane CT images taken at 21 days follow-up (B) of Dog 1, extensive calcification of the celiac, cranial mesenteric, renal, iliac, caudal abdominal aorta and caudal gluteal artery is observed (arrows), which is not found 6 months prior (A). The calcification of the external, common carotid and lingual artery (arrows) is also found on sagittal plane CT image (C) and the calcification of pulmonary arteries is detected on dorsal plane CT image (D) taken at 21 days follow-up. Window level=40, window width=400. Dorsal plane CT image (E) of Dog 2. marked calcification of the abdominal arteries, from the caudal abdominal aorta and bilateral iliac arteries to the peripheral branches, is observed (arrows). Window level = 450, window width = 1500.

and hyperadrenocorticism, chronic renal failure, and diabetes mellitus were excluded (**Table 1**), and the arterial calcification was diagnosed as atherosclerosis. The blood pressure was decreased to 140 mmHg following the use of 0.125 mg/kg Ramipril (Vasotop, MSD Animal Health, UK) for 8 months. The recurrence of pancreatitis and systemic hypertension were repeated for longer than one year until the present.

DISCUSSION

This report describes 2 Schnauzers that had extensive arterial calcification. The possibility of atherosclerosis was presented by excluding other underlying causes that can induce calcification of the vascular wall. Soft tissue calcification is classified into metastatic and dystrophic types. Metastatic calcification involves the deposition of calcium salts secondary to an abnormal metabolism of calcium and phosphorus with serum elevations of one or both electrolytes by paraneoplastic hypercalcemia, hyperparathyroidism, and vitamin D intoxication [4]. In the present cases, metastatic calcification was readily excluded based on the normal serum calcium and phosphorus concentrations. Dystrophic calcification is the deposition of calcium salts in injured, degenerating, or dead tissue by inflammatory or infectious diseases. Hyperadrenocorticism and atherosclerosis cause dystrophic calcification of the arteries in dogs. In the 2 dogs, dystrophic vascular calcification associated with hyperadrenocorticism was excluded based on low-dose dexamethasone suppression tests and the normal appearance of adrenal glands on ultrasonography. Therefore, the extensive arterial calcification was diagnosed as atherosclerosis.

Calcified atheromatous plaque can be detected easily on radiography and coronary calcification is specific to atherosclerosis [5]. Recently, a significant relationship between abdominal aortic calcification on the lumbar radiographs and carotid artery plaques was revealed in humans [6]. Similarly, each dog and cat with atherosclerosis showed extensive calcification of the abdominal arteries with calcification of the lung parenchyma, pulmonary vessels, and aorta on radiography [3,4].

CT allows excellent visualization of vascular calcification and characterization of atherosclerotic plaque; calcified plaque shows high-attenuation, whereas lipid-rich or fibrous plaque appears hypoattenuated within the vessel wall [7]. The total plaque area measured by CT correlates well with the histology [8]. Circumferential and successive calcification of the abdominal aorta and external iliac arteries in these 2 dogs was similar to previous reports, where the caudal aorta, aortic bifurcation, and external iliac arteries were affected [3]. Calcified atherosclerotic plaque can present in various forms and sizes from small, focal areas of irregular opacities to tram-track parallel calcifications with vertical-linear radiolucent areas, depending on the site of the affected arteries and extent of calcification [5]. Aortic bifurcation is a common location for atherosclerosis in humans, and it is related to endothelial injury and inflammation due to changes in wall shear stress in this region [9].

CT angiography allows the identification of vascular stenosis associated with plaque [2]. In particular, 'spotty' calcification within the plaque (calcified plaque < 3 mm) is considered a sign of plaque instability, which is more likely to rupture and cause acute clinical signs [9]. In these 2 cases, cylindrical and successive calcification of the retroperitoneal arteries was found on radiography, and CT confirmed a far broader extent, visualizing the minor calcifications.

On the other hand, there was no evidence of stenosis or spotty calcification within the plaque on CT angiography, which may explain why there were no clinical signs of atherosclerosis.

A few risk factors for atherosclerosis, such as hypercholesterolemia and hypothyroidism, are known in dogs [10,11]. Of these, dyslipoproteinemia, hypothyroidism, and diabetes mellitus were excluded in dog 1. These cases had several things in common. Both were miniature Schnauzers that had high concentrations of triglycerides and CRP. The relationship between triglycerides and atherosclerosis was not fully elucidated, but a previous study reported hypertriglyceridemia in 5 dogs that were confirmed histopathologically to have atherosclerosis [1]. The consistent increase in CRP in these 2 cases was thought to result from pancreatitis. Alternatively, it could be related to a breed effect; miniature Schnauzer dogs have significantly higher CRP than non-miniature Schnauzer dogs [12]. In humans, CRP was reported to be both a marker and a mediator of atherosclerosis in the endothelium of atherosclerotic vessels [13]. Moreover, CRP independently stimulates endothelial dysfunction characterized by the excretion of various cytokines and the proliferation of smooth muscle cells [14]. Similarly, in the present 2 cases, high concentrations of CRP may have promoted a risk of spontaneous atherosclerosis. Hypertension is a major risk factor for the development of atherosclerosis in humans [15]. These cases had hypertension that was refractory to antihypertensive medication. Although there is no detailed study on whether atherosclerosis can cause hypertension in dogs, there is the possibility of hypertension caused by endothelial dysfunction during atherogenesis in these cases.

The 2 dogs were diagnosed with atherosclerosis through diagnostic imaging without histopathologic confirmation because invasive procedures, such as arterial biopsy or necropsy, were not justifiable in living patients. On the other hand, the extensive vascular calcification in miniature Schnauzer dogs, without any other causes of metastatic calcification or endocrinopathy, could assist in the ante mortem diagnosis of atherosclerosis. Therefore, extensive vascular calcification on radiography and CT can indicate atheromatous plaque and provide further information on the predisposing factors, dyslipidemia, and endocrine diseases, particularly in miniature Schnauzer dogs.

REFERENCES

1. Kagawa Y, Hirayama K, Uchida E, Izumisawa Y, Yamaguchi M, Kotani T, et al. Systemic atherosclerosis in dogs: histopathological and immunohistochemical studies of atherosclerotic lesions. *J Comp Pathol.* 1998;118(3):195-206.
[PUBMED](#) | [CROSSREF](#)
2. Wang Y, Osborne MT, Tung B, Li M, Li Y. Imaging cardiovascular calcification. *J Am Heart Assoc.* 2018;7(13):115.
[PUBMED](#) | [CROSSREF](#)
3. Drost WT, Bahr RJ, Henry GA, Campbell GA. Aortoiliac thrombus secondary to a mineralized arteriosclerotic lesion. *Vet Radiol Ultrasound.* 1999;40(3):262-266.
[PUBMED](#) | [CROSSREF](#)
4. Lefbom BK, Adams WH, Weddle DL. Mineralized arteriosclerosis in a cat. *Vet Radiol Ultrasound.* 1996;37(6):420-423.
[CROSSREF](#)
5. Guimarães Henriques JC, Kreich EM, Helena Baldani M, Luciano M, Cezar de Melo Castilho J, Cesar de Moraes L. Panoramic radiography in the diagnosis of carotid artery atheromas and the associated risk factors. *Open Dent J.* 2011;5(1):79-83.
[PUBMED](#) | [CROSSREF](#)

6. Kobayashi K, Ando K, Seki T, Hamada T, Suzuki K, Ishiguro N, et al. Carotid artery plaque screening using abdominal aortic calcification on lumbar radiographs. *PLoS One*. 2019;14(1):e0209175.
[PUBMED](#) | [CROSSREF](#)
7. Ibañez B, Badimon JJ, Garcia MJ. Diagnosis of atherosclerosis by imaging. *Am J Med*. 2009;122(1 Suppl):S15-S25.
[PUBMED](#) | [CROSSREF](#)
8. Joshi FR, Lindsay AC, Obaid DR, Falk E, Rudd JH. Non-invasive imaging of atherosclerosis. *Eur Heart J Cardiovasc Imaging*. 2012;13(3):205-218.
[PUBMED](#) | [CROSSREF](#)
9. Tarkin JM, Dweck MR, Evans NR, Takx RA, Brown AJ, Tawakol A, et al. Imagingtherosclerosis. *Circ Res*. 2016;118(4):750-769.
[PUBMED](#) | [CROSSREF](#)
10. Liu SK, Tilley LP, Tappe JP, Fox PR. Clinical and pathologic findings in dogs with atherosclerosis: 21 cases (1970–1983). *J Am Vet Med Assoc* 1986;189(2):227-232.
[PUBMED](#)
11. Hess RS, Kass PH, Van Winkle TJ. Association between diabetes mellitus, hypothyroidism or hyperadrenocorticism, and atherosclerosis in dogs. *J Vet Intern Med*. 2003;17(4):489-494.
[PUBMED](#) | [CROSSREF](#)
12. Wong VM, Kidney BA, Snead EC, Myers SL, Jackson ML. Serum C-reactive protein concentrations in healthy miniature Schnauzer dogs. *Vet Clin Pathol*. 2011;40(3):380-383.
[PUBMED](#) | [CROSSREF](#)
13. Yasojima K, Schwab C, McGeer EG, McGeer PL. Generation of C-reactive protein and complement components in atherosclerotic plaques. *Am J Pathol*. 2001;158(3):1039-1051.
[PUBMED](#) | [CROSSREF](#)
14. Benzaquen LR, Yu H, Rifai N. High sensitivity C-reactive protein: an emerging role in cardiovascular risk assessment. *Crit Rev Clin Lab Sci*. 2002;39(4-5):459-497.
[PUBMED](#) | [CROSSREF](#)
15. Teramoto T, Sasaki J, Ishibashi S, Birou S, Daida H, Dohi S, et al. Executive summary of the Japan Atherosclerosis Society (JAS) guidelines for the diagnosis and prevention of atherosclerotic cardiovascular diseases in Japan-2012 version. *J Atheroscler Thromb*. 2013;20(6):517-523.
[PUBMED](#) | [CROSSREF](#)