



# Evaluation of the Clinical Outcomes of the Arthroscopic Treatment of Rotator Cuff Tears Using the Modified Suture Bridge Technique\*

## *Avaliação dos resultados clínicos do tratamento artroscópico de lesões do manguito rotador pela técnica de suture bridge modificada*

João Manoel Fonseca Filho<sup>1</sup> Guilherme do Val Sella<sup>2</sup> Luis Henrique Lima de Souza<sup>2</sup>  
Renato Miyadahira<sup>2</sup> João Roberto Polydoro Rosa<sup>3</sup> Alberto Naoki Miyazaki<sup>1,2</sup>

<sup>1</sup> Shoulder and Elbow Surgery Group, Hospital Alemão Oswaldo Cruz, São Paulo, SP, Brazil

<sup>2</sup> Shoulder Surgery Group, Department of Orthopedics and Traumatology, Faculdade de Ciências Médicas, Santa Casa de São Paulo (FCMSCSP), São Paulo, SP, Brazil

<sup>3</sup> Sports Trauma Surgery Group, Department of Orthopedics and Traumatology, Faculdade de Ciências Médicas da Santa Casa de São Paulo (FCMSCSP), São Paulo, SP, Brazil

Address for correspondence João Manoel Fonseca Filho, MD, Rua Frei Caneca, 640, apto. 264, Torre Natura, São Paulo, SP, 01307-000, Brazil (e-mail: drjoaoortopedia@me.com).

Rev Bras Ortop 2022;57(6):984–991.

### Abstract

**Objective** To evaluate the postoperative clinical outcomes of the arthroscopic repair of rotator cuff injuries using a suture configuration we have developed based on a modification of the Suture Bridge (Arthrex, Naples, FL, United States).

**Methods** A retrospective study with 28 male (41.2%) and 40 female (58.8%) subjects with a mean age of 60 years. All patients underwent rotator cuff repair with the modified Suture Bridge technique and follow-up for a minimum period of 18 months. The clinical assessment was performed using the University of California, Los Angeles (UCLA) Shoulder Score.

**Results** The mean postoperative range of motion was of 134° (range: 110° to 140°) for elevation, 58° (range: 40° to 70°) for lateral rotation, and T10 (range: L4 to T7) for medial rotation. The mean increase was of 15° for elevation, 14° for lateral rotation, and 2 vertebral levels for medial rotation. The outcomes were excellent in 61 (83.6%) cases, good in 8 (10.9%), and regular in 4 cases (5.5%).

### Keywords

- ▶ wound healing
- ▶ ischemia
- ▶ rotator cuff injuries
- ▶ recurrence
- ▶ suture techniques

\* Study developed at the Department of Orthopedics and Traumatology, Hospital Alemão Oswaldo Cruz, São Paulo, SP, Brazil.

received  
April 24, 2021  
accepted after revision  
February 18, 2022  
published online  
August 2, 2022

DOI <https://doi.org/10.1055/s-0042-1746179>.  
ISSN 0102-3616.

© 2022. Sociedade Brasileira de Ortopedia e Traumatologia. All rights reserved.

This is an open access article published by Thieme under the terms of the Creative Commons Attribution-NonDerivative-NonCommercial-License, permitting copying and reproduction so long as the original work is given appropriate credit. Contents may not be used for commercial purposes, or adapted, remixed, transformed or built upon. (<https://creativecommons.org/licenses/by-nc-nd/4.0/>)

Thieme Revinter Publicações Ltda., Rua do Matoso 170, Rio de Janeiro, RJ, CEP 20270-135, Brazil

**Conclusion** The modified Suture Bridge technique for the arthroscopic repair of rotator cuff injuries led to excellent or good postoperative clinical outcomes in most cases (69; 94.5%).

## Resumo

**Objetivo** Avaliar os resultados clínicos pós-operatórios do reparo artroscópico de lesões do manguito rotador com uma configuração de sutura desenvolvida por nós a partir de modificação do Suture Bridge (Arthrex, Naples, FL, Estados Unidos).

**Métodos** Estudo retrospectivo de 28 pacientes do gênero masculino (41,2%) e 40 do gênero feminino (58,8%), com média de idade de 60 anos. Todos foram submetidos a reparo do manguito rotador com a técnica *Suture Bridge* modificada e acompanhados por um período mínimo de 18 meses. Os pacientes foram avaliados clinicamente através da Escala de Ombro da University of California, Los Angeles (UCLA).

**Resultados** A amplitude de movimento média no pós-operatório foi elevação de 134° (variação: 110° a 140°), rotação lateral de 58° (variação: 40° a 70°), e rotação medial de T10 (variação: L4 a T7). O aumento médio de elevação foi de 15°, o de rotação lateral, de 14°, e o de rotação medial, de 2 níveis vertebrais. Os resultados foram considerados excelentes em 61 casos (83,6%) e bons, em 8 (10,9%). Em 4 casos (5,5%), o resultado foi regular.

**Conclusão** Os resultados clínicos pós-operatórios do reparo artroscópico de lesões do manguito rotador, pela técnica *Suture Bridge* modificada, foram excelentes e bons na maioria dos casos (69; 94,5%).

## Palavras-chave

- ▶ cicatrização
- ▶ isquemia
- ▶ lesões do manguito rotador
- ▶ recidiva
- ▶ técnicas de sutura

## Introduction

Knowledge of the anatomy of the rotator cuff led to an evolution in repair techniques for injuries to it.<sup>1-3</sup> These methods aim to promote better biomechanical stability of the repair, maximize the contact between the tendon and the bone bed, and enable a uniform distribution of tension, providing a favorable environment for healing.<sup>4,5</sup>

The double-row suture is an established configuration for rotator cuff injuries (RCIs). It consists of placing one or more anchors adjacent to the articular cartilage and other anchors laterally. This configuration, introduced by Lo and Burkhart,<sup>6</sup> does not interconnect the medial and lateral rows; consequently, there is no compression of the tendon against the bone bed,<sup>7,8</sup> potentially compromising healing.<sup>2,3,8,9</sup>

This technique underwent several modifications to press the entire mobilized area of the tendon to its footprint.<sup>1,2,5</sup> These alterations were called the “transosseous equivalent” suture: suture threads of the medial row anchors are placed over the bursal surface, tensioned to bring them closer to the bone, and then connected to the lateral row anchors.

Concurrent with this evolution, hypotheses have been raised on the importance of blood supply to the rotator cuff after the repair.<sup>10</sup> Angiograms and Doppler-laser flowmetry led to a better understanding of the vascularization and blood flow of the rotator cuff. The muscular region has a rich network of arterial anastomosis. In contrast, the tendinous area is more delicate and predisposed to injury and hypoflow, presenting avascular corridors.<sup>10,11</sup> From these observations, we can infer that a suture such as the Suture Bridge (SB; Arthrex, Naples, FL, United States),<sup>12</sup> in which the

threads that interconnect the rows cross each other, can compromise the tendon vascularization and its healing.

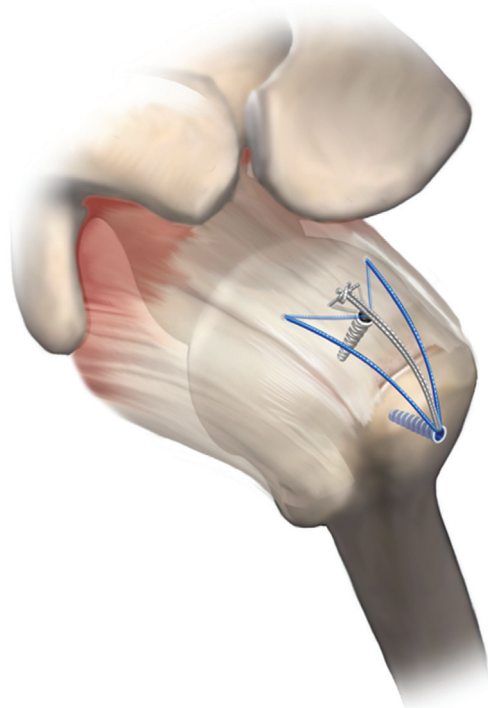
To improve the therapeutic arsenal, the present study assesses the postoperative clinical outcomes of the arthroscopic repair of RCIs using an SB-based suture configuration developed and modified by us. We herein detail the so-called Modified Suture Bridge (MSB).

## Casuistry and Methods

We performed the surgery in the “beach chair” position under general anesthesia and interscalene anesthetic block. The first step of the procedure is an arthroscopic inspection of the joint, followed by an approach to the subacromial space. After exploration of the lesion, we mobilize the tendons, open the bone bed in the greater tubercle, and then repair the injury.

The technique consists of at least one medial fixation point with an anchor loaded with two suture threads at the joint margin, followed by lateral fixation with a single interference anchor.

The repair of small lesions and some medium lesions involving only the supraspinatus tendon use only a conventional medial anchor loaded with two suture threads, totaling four ends. All ends transfix the tendon from the articular to the bursal aspects; next, they are arranged parallel to the tendon fibers and to each other. The central ends form a mattress-like suture, approximating the articular surface of the tendon to the underlying bone; the peripheral ends are left free. Then, the four ends are pulled and fixed on the



**Fig. 1** Modified Suture Bridge (MSB) with one medial anchor. Illustration of the configuration of the MSB technique for small and medium-sized lesions.

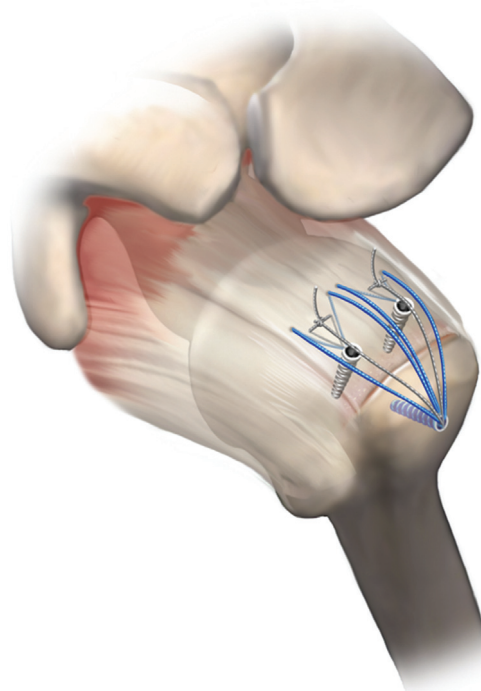
lateral face of the greater tuberosity using a wireless (interference) anchor, generating a lateral fixation point (►**Figure 1**).

The technique is similar for medium and large lesions involving more than one tendon; however, we perform this configuration twice, using two conventional medial anchors loaded with two sutures each, totaling two groups with four ends. The procedure requires a single modification: after preparing the central mattresses, we discard one of the ends and pull the six remaining ends (three from each group) to the lateral fixation point. Next, we section the discarded ends because the lateral interference anchor only has room for six of them (►**Figure 2**).

All patients followed similar rehabilitation regimens. A functional sling immobilized the shoulders for four to six weeks; next, the patients remained on physical therapy until six months of rehabilitation.

From January 2016 to February 2019, 71 patients underwent surgery; 5 procedures were bilateral, totaling 76 shoulders submitted to the arthroscopic treatment using the MSB technique performed by us.

The present study included patients with complete small, medium, or large RCIs (according to the DeOrio and Cofield<sup>13</sup> classification) involving the supraspinatus or infraspinatus tendon or both, and with or without an associated injury to the long bicipital head, who exclusively underwent primary surgery using the MSB technique and had a minimum follow-up of 1.5 years. The exclusion criteria were involvement of other rotator cuff tendons and previous surgery on the evaluated shoulder. Since the presence of injury to the subscapularis tendon led to the exclusion of 3 patients, the



**Fig. 2** Modified Suture Bridge (MSB) with two medial anchors. Illustration of the configuration of the MSB technique for large lesions.

final sample was composed of a total of 68 patients (73 shoulders).

From this total, 28 subjects were male (41.2%), and 40 were female (58.8%). Their mean age was 60 years, ranging from 44 to 81 years. Before surgery, the patients had 119° (range: 30° to 140°) of mean elevation, 44° (range: 10° to 60°) of lateral rotation, and T12 (range: trochanter to T7) of medial rotation (►**Table 1**).

Preoperatively, 13 shoulders (17.8%) had rotator cuff pseudoparesis,<sup>14</sup> with an average of 72° (range: 30° to 80°) of elevation, 43° (range: 10° to 60°) of lateral rotation, and L5 (range: T10 to trochanter) of medial rotation (►**Table 2**).

As shown in ►**Figure 1**, we used 2 anchors (1 medial, 1 lateral) in 48 cases (65.8%); 25 patients (34.2%) required 3 anchors (2 medial, 1 lateral) (►**Figure 2**).

We divided the patients into two groups according to the etiology of the RCI; group I was composed of patients with traumatic etiology, and group II, of patients with degenerative etiology; next, we reassessed them using the modified University of California, Los Angeles (UCLA) Shoulder Score<sup>15</sup> (►**Figure 3**). We compared the pre- and postoperative active ranges of motion (ROMs) according to the parameters of the American Academy of Orthopaedic Surgeons (AAOS). Group I comprised 4 small, 10 medium, and 6 large lesions, whereas group II presented 6 small, 30 medium, and 17 large lesions.

For the statistical analysis, we evaluated all data using the Minitab (Minitab, LLC, State College, PA, United States), software, version 19. For the comparison of the data, we used the Fisher exact test and the chi-squared test ( $p < 0.05$ ).

The Teaching and Research Committee of Hospital Alemão Oswaldo Cruz approved the present scientific research (under CAEE: 26308719.0.0000.0070).

**Table 1** Comparison of the pre- and postoperative functions stratified by shoulder, movement type, number of involved tendons, number of anchors, and UCLA Shoulder Score

Cases	Gender	Trauma	Preop and postop E	Preop and postop LR	Preop and postop MR	Number of affected tendons	Number of anchors (medial/lateral)	Postop UCLA score
1	F		140/140	60/90	T12/T7	1	1/1	35
2	M		140/140	60/60	T12/L3	1	1/1	35
3	F		140 /140	60/70	T7/T7	1	1/1	35
4	M		80/120	60/60	GL/T10	1	1/1	35
5	F		80 /120	60/60	GL/L4	1	1/1	35
6	F	+	80/130	40/60	GL/T7	1	1/1	35
7	F	+	130 /130	60/60	T10/T7	1	1/1	35
8	M		130 /130	60/60	T12/T7	1	1/1	35
9	M	+	140 /140	60/60	T7/T7	1	1/1	35
10	M	+	140/140	60/65	T7/T7	1	1/1	35
11	M	+	140/140	60/70	T12/T8	1	1/1	35
12	F		80/120	10/60	GL/L3	1	1/1	32
13	F	+	80/130	60/65	TR/T7	1	1/2	35
14	M		80/130	60/70	TR/T8	1	1/1	35
15	F		130/130	60/65	T12/T7	1	1/1	35
16	M		130/140	60/45	T12/T8	1	1/1	35
17	M		130/130	50/60	T10/T9	1	1/1	35
18	F		130/135	60/60	T10/T9	1	1/1	35
19	F		80/120	50/50	TR/L4	1	1/1	27
20	M		80/110	50/50	TR/L3	1	1/1	27
21	F		130/130	60/60	T9/T7	1	1/1	34
22	M		110/140	60/60	T9/T9	1	1/1	35
23	M	+	120/140	60/60	T10/T7	1	1/1	35
24	M	+	80/110	40/60	GL/T12	2	1/2	32
25	F		30/140	40/60	T12/T12	1	1/1	35
26	F	+	130/140	40/70	T12/L2	1	1/1	35
27	F	+	60/130	50/60	T10/L1	1	1/1	35
28	F		140/140	60/60	T7/T9	1	1/1	35
29	F		130/140	30/60	T12/T7	2	1/2	35
30	M		120/140	40/60	T12/T10	2	1/2	35
31	M	+	120/140	30/60	T12/T10	2	1/2	35
32	M		130/140	40/60	T12/T7	1	1/1	35
33	M		120/140	30/60	T12/T7	1	1/1	34
34	M	+	130/140	60/60	T12/T7	2	1/2	34
35	F		130/140	60/60	T12/T10	2	1/1	35
36	M		130/140	30/60	T12/T10	1	1/1	34
37	M		120/140	30/60	T12/T10	2	1/2	34
38	F		110/130	30/50	T10/T10	2	1/2	35
39	M	+	110/140	20/60	L1/L1	2	1/1	35
40	M	+	60/130	20/60	T12/T10	1	1/1	34

(Continued)

**Table 1** (Continued)

Cases	Gender	Trauma	Preop and postop E	Preop and postop LR	Preop and postop MR	Number of affected tendons	Number of anchors (medial/lateral)	Postop UCLA score
41	F	+	120/120	30/40	T12/T12	2	1/1	30
42	F		130/140	20/70	L1/L1	2	1/1	34
43	F		130/130	40/50	T12/T12	2	1/2	34
44	F		100/140	30/60	T12/T8	1	1/1	35
45	F		130/130	40/50	T12/T9	1	1/1	35
46	F		120/140	40/60	T12/T12	2	1/2	35
47	F	+	130/140	40/60	T12/T12	2	1/2	35
48	F		130/130	50/60	T12/T7	2	1/2	33
49	F		70/110	20/50	T12/L1	2	1/2	30
50	M		120/140	60/60	T9/T7	2	1/2	35
51	M		130/130	40/40	T12/T10	2	1/2	35
52	M		120/140	40/60	T12/T12	2	1/1	35
53	F		120/140	30/60	T12/T12	1	1/1	35
54	F		120/130	30/50	T12/T12	1	1/2	35
55	F		120/130	40/60	T12/T12	1	1/1	34
56	F		130/140	30/60	T12/T9	2	1/2	35
57	F		130/140	40/60	T10/T9	1	1/1	35
58	F		130/140	40/60	T12/T7	2	1/1	35
59	F		130/130	40/60	T12/T9	1	1/1	35
60	F		120/140	30/70	T12/T7	2	1/2	35
61	F	+	120/120	30/50	T12/L3	1	1/1	27
62	M		130/130	40/45	T12/L4	1	1/1	27
63	F		140/140	60/70	T12/T9	1	1/1	35
64	F		140/140	60/60	T9/T9	1	1/1	35
65	F		140/140	60/60	T7/T7	1	1/1	35
66	F	+	120/140	40/60	T12/T10	1	1/1	35
67	F		130/130	60/50	T9/T10	2	1/1	35
68	F		130/130	60/40	T9/L2	2	1/2	32
69	F		130/140	30/60	T12/L2	1	1/1	32
70	F		120/130	30/60	T12/L2	2	1/2	35
71	M	+	120/140	30/60	T12/T9	2	1/2	35
72	M	+	120/130	30/40	T7/T7	2	1/2	35
73	M		120/130	30/40	T12/T10	2	1/2	32

Abbreviations: E, elevation (in degrees); F, female; GL, gluteus; M, male; Postop, postoperative; Preop, preoperative; LR, lateral rotation (in degrees); MR, medial rotation per vertebral level; TR, trochanter; UCLA, University of California, Los Angeles.

Note: Number of affected tendons: 1 = supraspinal, 2 = supraspinal + infraspinal.

## Results

The postoperative average ROM was of 134° (range: 110° to 140°) of elevation, 58° (range: 40° to 70°) of lateral rotation, and T10 (range: L4 to T7) of medial rotation. Most operated shoulders gained movement in all directions (– **Table 1**). The

mean increase was of 15° of elevation, 14° of lateral rotation, and 2 vertebral levels of medial rotation.

Regarding etiology, 1 patient from the traumatic group (group I) underwent surgery due to adhesive capsulitis. In the final evaluation, the patients in this group presented a mean increase in active elevation of 21°, a mean gain in

**Table 2** Active range of motion in patients with pseudoparesis

Preoperatively			Postoperatively			
	E	LR	MR	E	LR	MR
Cases						
4	80	60	GL	120	60	T10
5	80	60	GL	120	60	L4
6	80	40	GL	130	60	T7
12	80	10	GL	120	60	L3
13	80	60	TR	130	65	T7
14	80	60	TR	130	70	T8
19	80	50	TR	120	50	L4
20	80	50	TR	110	50	L3
24	80	40	GL	110	60	T12
25	30	40	T12	140	60	T12
27	60	50	T10	130	60	L1
40	60	20	T12	130	60	T10
49	70	20	T12	110	50	L1

Abbreviations: E, elevation (in degrees); GL, gluteus; LR, lateral rotation (in degrees); MR, medial rotation per vertebral level; TR, trochanter.

lateral rotation of 10.5°, and a mean gain in medial rotation of 2 vertebral levels. Their mean UCLA Shoulder Score was of 32.4 points (range: 27 to 35 points). Group II (degenerative etiology) included one patient who underwent surgery due to adhesive capsulitis and two who developed it afterwards. This group had a mean increase in active elevation of 13.4°, a mean gain in lateral rotation of 13.1°, and a mean gain in medial rotation of 2 vertebral levels. Their mean UCLA Shoulder Score was of 34.7 points (range: 27 to 35 points). The group comparison revealed no statistical differences regarding gender ( $p = 0.101$ ), age ( $p = 0.450$ ), or lesion size ( $p = 0.300$ ). In addition, there was no correlation between

**Table 3** Gain in range of motion and UCLA Shoulder Score per etiology

	Group I – traumatic etiology	Group II – degenerative etiology	<i>p</i>
E	21	13.4	0.363
LR	10.5	13.1	0.324
MR	2	2	0.134
UCLA	32.4	34.7	0.839

Abbreviations: E, elevation (in degrees); LR, lateral rotation (in degrees); MR, medial rotation per vertebral level; UCLA, University of California, Los Angeles.

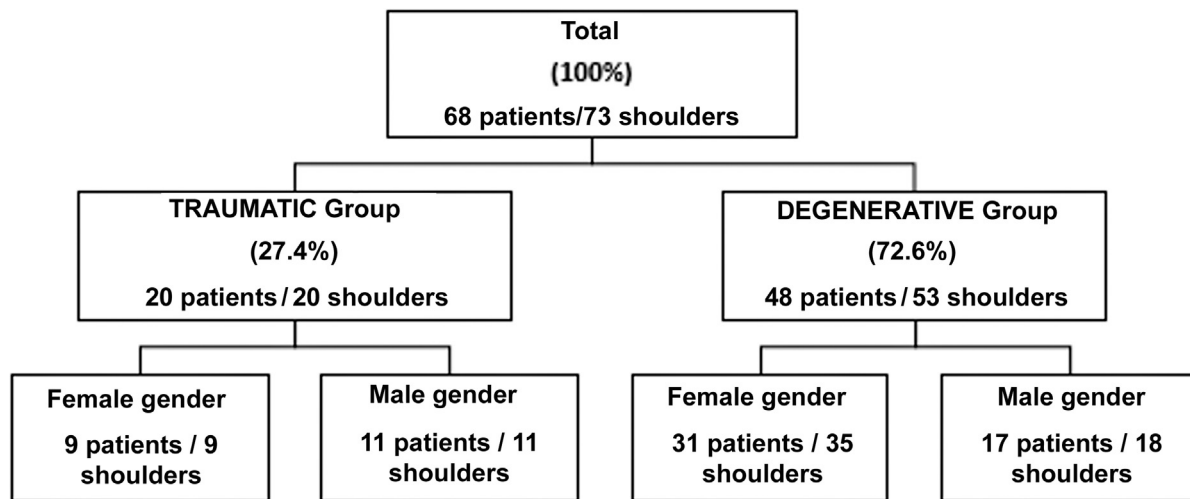
etiology and movement gains for elevation ( $p = 0.363$ ), lateral rotation ( $p = 0.324$ ), and medial rotation ( $p = 0.134$ ) (► **Table 3**).

There was no statistically significant correlation between the final UCLA Shoulder Score and the following variables: lesion size ( $p = 0.452$ ), gender ( $p = 0.256$ ), number of anchors used ( $p = 0.163$ ), etiology ( $p = 0.839$ ), and age range at the time of surgery ( $p = 1$ ). Neither was there statistical correlation between age group and lesion size ( $p = 0.941$ ).

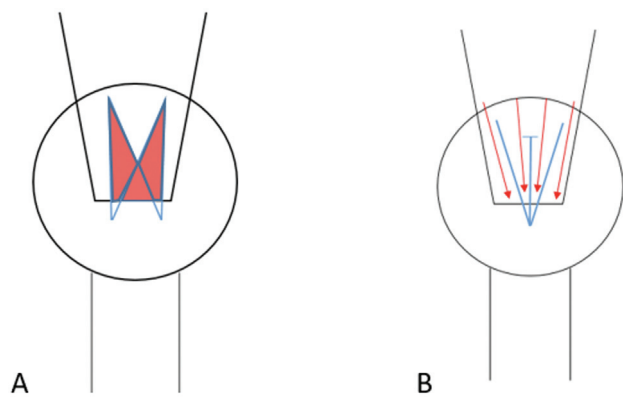
There was a statistically significant correlation between the variables “lesion size” and “number of anchors used” ( $p < 0.005$ ). The 23 large lesions required 3 anchors; the 10 small lesions used 2 anchors. Regarding the 40 medium-sized lesions, 2 received 3 anchors (2.7%), and the others required 2 anchors (52.1%).

**Discussion**

The SB repair technique provides sufficient resistance for suture maintenance and tendon healing.<sup>1,3,5,8,9</sup> However, it may reduce the blood flow to the tendon because the suture threads are not parallel to the fibers, disregarding



**Fig. 3** Stratification of patients and cases per etiology and gender.



**Fig. 4** Blood flow after tendon repair. (A) Rotator cuff repaired with the Suture Bridge technique (blue lines) and ischemia regions limited by red areas; (B) rotator cuff repaired with the MSB technique (blue lines) with preserved vascular corridors and blood flow (red arrows).

microvascularization.<sup>2,3,10,11</sup> Aiming to preserve the biology of the tendon and believing that healing relates directly to rotator cuff vascularization, we modified this technique to get the resistance associated with this repair with no ischemic areas in less perfused regions. Thus, our suture aims to maintain vascular corridors and preserve the blood flow, which progresses from medial to lateral<sup>16</sup> (►Figure 4).

A systematic review by Hein et al.<sup>8</sup> evaluated the de novo rupture rates using three techniques, and they observed a total of 26% of failure for single-row sutures, 21% for double-row sutures, and 21% for SB. This study<sup>8</sup> included 2,048 shoulders, and it shows that, in absolute numbers, double-row sutures resulted in fewer cases of complication than SB in small, medium, and large injuries. However, the de novo rupture rates were lower in extensive lesions treated with SB. Bedeir et al.<sup>17</sup> said that the lack of adequate tendon mobility in extensive lesions precludes the anatomical reduction of the lesion to its footprint even when the tendon stump undergoes exaggerated traction. On the other hand, in minor injuries, the repair is possible even with an inadequate release, keeping the tissue tensioned at suprphysiological loads and reinserting it into the bone; however, this can predispose to a poorly biological construction and result in greater ischemia.<sup>2,17</sup> From a clinical point of view, a meta-analysis by Ren et al.<sup>18</sup> demonstrated a superior UCLA Shoulder Score in patients undergoing repair with SB compared with repair using double-row sutures.

As well as the outstanding functional outcomes described in the literature for SB,<sup>18-21</sup> our patients showed an excellent clinical evolution (UCLA Shoulder Score = 34 points), with a ROM gain comparable to that of the preoperative period, both in traumatic and degenerative injuries. The literature also describes similar outcomes of other repair types. Abechain et al.<sup>22</sup> compared the clinical outcomes after the arthroscopic repair in two groups, namely with “traumatic” or “non-traumatic” injuries, with ages similar to those of our subjects (“traumatic” group: mean age of 59 years; “non-traumatic” group: mean age of 59.5 years). These authors<sup>22</sup> observed similar outcomes in both

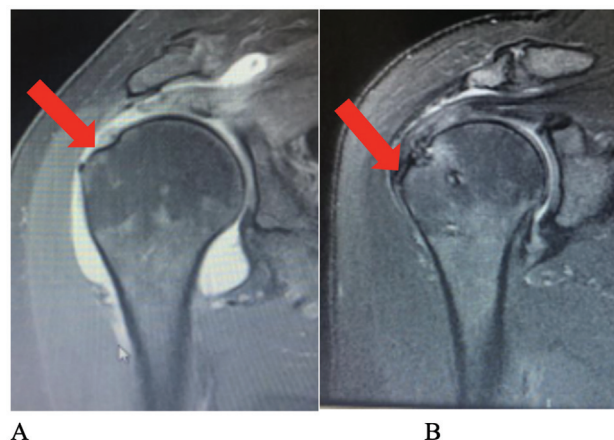
groups, regardless of lesion etiology, which is consistent with the present study.

We also found satisfactory outcomes in patients with pseudoparesis before the surgical approach, with reversal in all cases. With similar outcomes, a previous study by Miyazaki et al.<sup>19</sup> assessed patients with large and extensive RCIs associated with pseudoparesis who underwent arthroscopic repair of the rotator cuff. Almost all operated subjects (37 out of 38) presented functional improvement. Thus, we can infer that the MSB is a stable, resistant suture with outcomes similar to those of other repairs already described.<sup>19</sup>

As an unfavorable evolution, 4 of our patients presented regular functional outcomes (UCLA Shoulder Score = 27 points). Two of them underwent surgery due to adhesive capsulitis, and the other two developed it after the procedure. All had medium lesions and received two anchors (►Figure 1). The patients operated on due to adhesive capsulitis underwent anterior and inferior capsulotomies. Moreover, like those developing the disease after surgery, they received an anesthetic block of the suprascapular nerve every 14 days for 5 months to 1 year (average time: 7.75 months). Despite the UCLA Shoulder Score of 27, at the end of the anesthetic block series, all presented had a score of 35. Adhesive capsulitis was an intercurrent of the treatment; fortunately, however, it did not negatively influence the final function of the patients or the suture itself.

We do not routinely request postoperative imaging tests, such as magnetic resonance imaging (MRI), for outpatient follow-up. However, to find out whether the tendon adhered to its footprint, we randomly requested MRIs in six cases, and observed healing and tendon integration to the bone, as well as MSB maintenance, in all of them (►Figure 5).

Despite the promising results with a low number of complications, absence of de novo ruptures, and functional improvement in almost all patients, we believe that the small series, short follow-up, and lack of a control group are flaws of the present study.



**Fig. 5** Tendon healing in the bone. Magnetic resonance imaging of the shoulder from patient 51: (A) preoperative coronal, T2-weighted image showing a tendon lesion (red arrow); (B) a coronal, T2-weighted image obtained 18 months after surgery showing lesion healing (red arrow).

## Conclusion

The postoperative clinical outcomes of the arthroscopic repair of RCIs using the MSB technique were excellent and good in most cases (94.5%) according to the UCLA Shoulder Score after 1.5 years of follow-up.

### Financial Support

This study was financed in part by the Coordenação de Aperfeiçoamento de Pessoal de Nível Superior – Brasil (CAPES) – Finance Code 001.

### Conflict of Interests

The authors have no conflict of interests to declare.

## References

- Park MC, Cadet ER, Levine WN, Bigliani LU, Ahmad CS. Tendon-to-bone pressure distributions at a repaired rotator cuff footprint using transosseous suture and suture anchor fixation techniques. *Am J Sports Med* 2005;33(08):1154–1159
- Quigley RJ, Gupta A, Oh JH, et al. Biomechanical Comparison of Single-Row, Double-Row, and Transosseous-Equivalent Repair Techniques after Healing in an Animal Rotator Cuff Tear Model. *J Orthop Res* 2013;31(08):1254–1260
- Park MC, Peterson A, Patton J, McGarry MH, Park CJ, Lee TQ. Biomechanical effects of a 2 suture-pass medial inter-implant mattress on transosseous-equivalent rotator cuff repair and considerations for a “technical efficiency ratio”. *J Shoulder Elbow Surg* 2014;23(03):361–368
- Park MC, Tibone JE, ElAttrache NS, et al. Part II: Biomechanical assessment for a footprint-restoring transosseous-equivalent rotator cuff repair technique compared with a double-row repair technique. *J Shoulder Elbow Surg* 2007;16(04):469–476
- Busfield BT, Glousman RE, McGarry MH, Tibone JE, Lee TQ. A Biomechanical Comparison of 2 Technical Variations of Double-Row Rotator Cuff Fixation: The Importance of Medial Row Knots. *Am J Sports Med* 2008;36(05):901–906
- Lo IK, Burkhart SS. Double-row arthroscopic rotator cuff repair: Re-establishing the footprint of the rotator cuff. *Arthroscopy* 2003;19(09):1035–1042
- Mazzocca AD, Millett PJ, Guanche CA, Santangelo SA, Arciero RA. Arthroscopic single-row versus double-row suture anchor rotator cuff repair. *Am J Sports Med* 2005;33(12):1861–1868
- Hein J, Reilly JM, Chae J, Maerz T, Anderson K. Retear rates after arthroscopic single-row, double-row, and Suture Bridge rotator cuff repair at minimum of one year of imaging follow-up: a systematic review. *Arthroscopy* 2015;31(11):2274–2281
- Park MC, ElAttrache NS, Tibone JE, et al. Part I: Footprint contact characteristics for a transosseous-equivalent rotator cuff repair technique compared with a double-row repair technique. *J Shoulder Elbow Surg* 2007;16(04):461–468
- Christoforetti JJ, Krupp RJ, Singleton SB, Kissenberth MJ, Cook C, Hawkins RJ. Arthroscopic suture bridge transosseous equivalent fixation of rotator cuff tendon preserves intratendinous blood flow at the time of initial fixation. *J Shoulder Elbow Surg* 2012;21(04):523–530
- Ikemoto RY, Murachovsky J, Nascimento LGP, Bueno RS, Ueno FH, Akita J Junior. Microvascular evaluation of the supraspinatus tendon borders in rotator cuff lesions. *Rev Bras Ortop* 2007;42(11/12):382–386
- Park MC, ElAttrache NS, Ahmad CS, Tibone JE. “Transosseous-equivalent” rotator cuff repair technique. *Arthroscopy* 2006;22(12):1360.e1-5
- DeOrto JK, Cofield RH. Results of a second attempt at surgical repair of a failed initial rotator-cuff repair. *J Bone Joint Surg Am* 1984;66(04):563–567
- Tokish JM, Alexander TC, Kissenberth MJ, Hawkins RJ. Pseudoparalysis: a systematic review of term definition, treatment approaches, and outcomes of management techniques. *J Shoulder Elbow Surg* 2017;26(06):e177–e187
- Ellman H, Hunker G, Bayer M. Repair of rotator cuff. Factors influencing reconstruction. *J Bone Joint Surg Am* 1986;68(08):1136–1144
- Dukan R, Ledinet P, Donadio J, Boyer P. Arthroscopic Rotator Cuff Repair With a Knotless Suture Bridge Technique: Functional and Radiological Outcomes After a Minimum Follow-Up of 5 Years. *Arthroscopy* 2019;35(07):2003–2011
- Bedeir YH, Jimenez AE, Grawe B. Recurrent tears of the rotator cuff: Effect of repair technique and management options. *Orthop Rev (Pavia)* 2018;10(02):7593
- Ren YM, Zhang HB, Duan YH, Sun YB, Yang T, Tian MQ. Comparison of arthroscopic suture-bridge technique and double-row technique for treating rotator cuff tears: A PRISMA meta-analysis. *Medicine (Baltimore)* 2019;98(20):e15640
- Miyazaki AN, Santos PD, Sella GD, Checchia CS, Salata TR, Checchia SL. Evaluation of the functional results after rotator cuff arthroscopic repair with the suture bridge technique. *Rev Bras Ortop* 2017;52(02):164–168
- Kim KC, Shin HD, Lee WY, Han SC. Repair integrity and functional outcome after arthroscopic rotator cuff repair: double-row versus suture-bridge technique. *Am J Sports Med* 2012;40(02):294–299
- Kim KC, Shin HD, Lee WY, Yeon KW, Han SC. Clinical outcomes and repair integrity of arthroscopic rotator cuff repair using suture-bridge technique with or without medial tying: prospective comparative study. *J Orthop Surg Res* 2018;13(01):212
- Abechain JJK, Godinho GG, Matsunaga FT, Netto NA, Daou JP, Tamaoki MJS. Functional outcomes of traumatic and non-traumatic rotator cuff tears after arthroscopic repair. *World J Orthop* 2017;8(08):631–637