

Good recovery of subarachnoid hemorrhage concomitant with ischemia due to anterior cerebral artery dissection by conservative treatment: A case report

YIQI WANG, YU GENG, ZONGJIE SHI, TIANMING SHI and JINHUA ZHANG

Department of Neurology, Zhejiang Provincial People's Hospital, People's Hospital of Hangzhou Medical College, Hangzhou, Zhejiang 310014, P.R. China

Received November 1, 2015; Accepted March 6, 2017

DOI: 10.3892/etm.2017.4462

Abstract. The present report describes the case of a 57-year-old woman presenting with subarachnoid hemorrhage (SAH) and acute ischemic stroke (AIS) due to anterior cerebral artery (ACA) dissection, which exhibited severe stenosis at the origin with distal dilatation of the A2 segment and occlusion of the A3 segment. In this case, computed tomography (CT) revealed SAH in right superior frontal sulcus and the interhemispheric fissure. Magnetic resonance imaging demonstrated acute infarct in the territory of the right ACA. Brain digital subtraction angiography showed severe stenosis at the origin of the A2 segment with distal dilatation and occlusion at the origin of the A3 segment of the right ACA, suggesting a diagnosis of dissection. Only treatment with atorvastatin, her clinical condition subsequently improved. The stenosis and dilatation of A2 segment were ameliorated as demonstrated by a follow-up CT angiography 5 months after onset. SAH concomitant with ischemia caused by ACA dissection is rare. Conservative treatment may be a safe and effective choice for patients with SAH concomitant with AIS due to ACA dissection.

Introduction

Spontaneous intracranial artery dissection is an uncommon cause of stroke; however, it is a notable cause of stroke in young

and middle-aged adults. The proportion of intracranial artery dissection in cervicocephalic dissection varies between ethnic origin (1). For example, it was reported that only 11% of cervicocephalic artery dissection occurs in the intracranial arteries of Europeans, compared with 67-78% in East Asians (2,3). The majority of cases of intracranial artery dissection affect the vertebrobasilar system (3-5). This condition occurs relatively rarely in the anterior circulation, particularly in the anterior cerebral artery (ACA) (5-7). Previous studies have suggested that only 5.8-7.7% of cases of intracranial artery dissection occur in the ACA (4,5), and ACA dissection commonly affects middle-aged patients (7). Although intracranial artery dissection usually presents with subarachnoid hemorrhage (SAH) or cerebral infarction (7,8). The concurrent presence of SAH and cerebral infarction in patients with intracranial artery dissection is rare (8,9). In the present study, a rare case of SAH concomitant with acute ischemic stroke (AIS) in the territory of the ACA due to ACA dissection is described. The symptoms and angiography of the patient got improved with only conservative treatment.

Case report

The patient, a 57-year-old woman with a 10-year history of hypertension, was transferred to the Emergency Department of Zhejiang Provincial People's Hospital (People's Hospital of Hangzhou Medical College, Hangzhou, China) in May 2014. She presented with sudden-onset left hemiparesis with urinary incontinence, and a prodromal right temporal headache. Her blood pressure was 199/115 mmHg on admission. Neurological examination revealed left facial palsy, with muscle power rated as 4 on a scale from 0 to 5 in the left upper extremity and 0 in the left lower extremity, as follows: 0, no contraction; 1, flicker or trace of contraction; 2, active movement with gravity eliminated; 3, active movement against gravity; 4, active movement against gravity and resistance; and 5, normal power. The National Institutes of Health Stroke Scale (NIHSS) score was 7, and the modified Rankin Scale (mRS) score was 5.

A computed tomography (CT) scan of the brain revealed a high-density lesion within the right superior frontal sulcus and right interhemispheric fissure (Fig. 1A). Brain magnetic resonance imaging (MRI) conducted 2 days later demonstrated an

Correspondence to: Dr Jinhua Zhang, Department of Neurology, Zhejiang Provincial People's Hospital, People's Hospital of Hangzhou Medical College 158 Shangtang Road, Hangzhou, Zhejiang 310014, P.R. China
E-mail: jinhuaazh@163.com

Abbreviations: SAH, subarachnoid hemorrhage; AIS, acute ischemic stroke; ACA, anterior cerebral artery; NIHSS, National Institutes of Health Stroke Scale; mRS, modified Rankin Scale; CT, computed tomography; MRI, magnetic resonance imaging; RCVS, reversible cerebral vasoconstriction syndrome; CAA, cerebral amyloid angiopathy

Key words: anterior cerebral artery, dissection, subarachnoid hemorrhage, acute ischemic stroke, conservative treatment

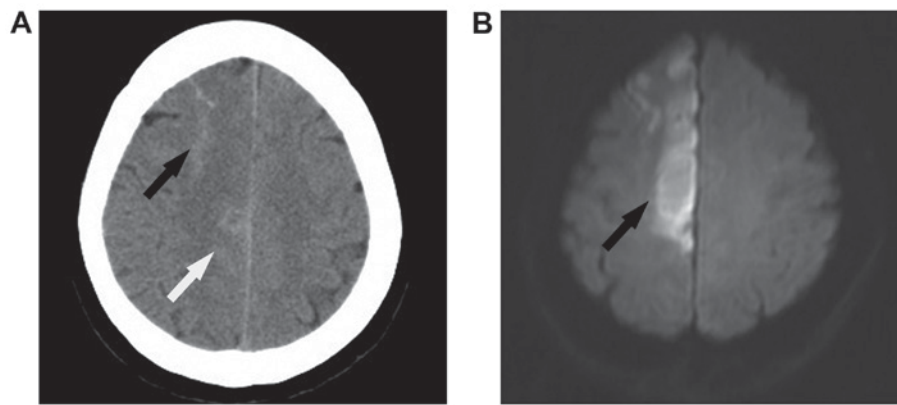


Figure 1. (A) On day 1 after onset, computed tomography demonstrated subarachnoid hemorrhage in the right superior frontal sulcus (black arrow) and right interhemispheric fissure (white arrow). (B) On day 2 after onset, diffusion weighted imaging sequences of magnetic resonance imaging showed hyperintense lesions in the territory of the right anterior cerebral artery (black arrow).

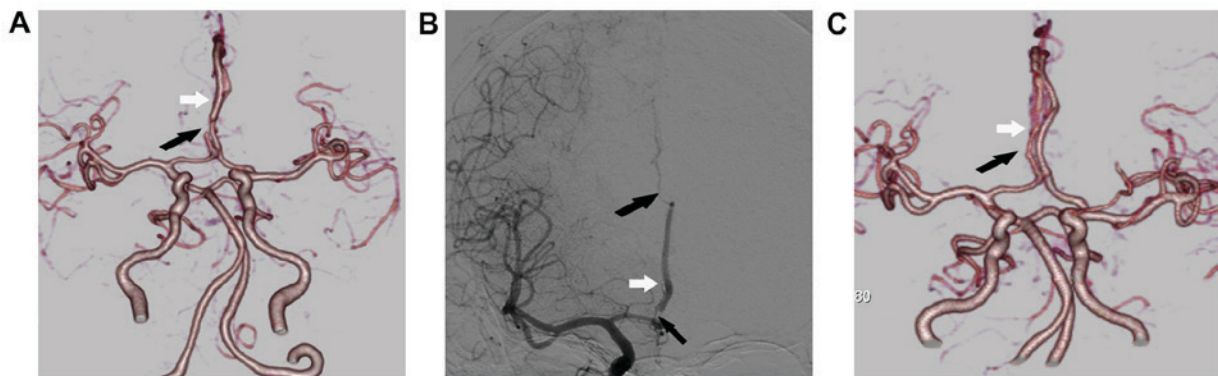


Figure 2. (A) CT angiography on day 5 after onset showed severe stenosis at the origin of the A2 segment (black arrow) with distal dilatation (white arrow) and occlusion at the origin of A3 segment of the right ACA. (B) Digital subtraction angiography on day 6 also showed severe stenosis at the origin of the A2 segment (black arrow) with distal dilatation (white arrow) and occlusion at the origin of the A3 segment of the right ACA (black arrow). (C) CT angiography after 5 months showed that the stenosis of A2 segment was considerably improved (black arrow) and the dilatation of A2 segment had almost disappeared (white arrow). CT, computed tomography; ACA, anterior cerebral artery.

acute infarct in the territory of the right ACA (Fig. 1B). CT angiography on day 5 and brain digital subtraction angiography on day 6 showed severe stenosis at the origin of the A2 segment with distal dilatation and occlusion at the origin of the A3 segment of the right ACA (Fig. 2A and B, respectively), suggesting a diagnosis of ACA dissection.

Treatment with atorvastatin (Pfizer, Inc., New York, NY, USA) at a dose of 20 mg/day was prescribed to the patient. Following stabilization of her condition, the patient was returned to her local hospital and rehabilitation, which included muscle strength enhancement training and motion range training, was initiated. A follow-up CT angiography performed 5 months after onset demonstrated that the stenosis and dilatation of the A2 segment was much ameliorated (Fig. 2C). The previous diagnosis of ACA dissection was confirmed by the rapid change observed in the repeat angiography. The NIHSS score of the patient was improved to 3 and the mRS score was improved to 3 at the 5-month follow-up.

Discussion

Simultaneous hemorrhage and ischemia due to ACA dissection appears to be very rare. To the best of our knowledge, only

14 cases of simultaneous hemorrhage and ischemia caused by ACA dissection have been reported so far (7,9,10-17). The age range of the individuals affected is from 35 to 64 years. All of these cases presented with lower-extremity dominant hemiparesis and some of them also complained of sudden onset headache. The SAH was located in the interhemispheric fissure or frontal surface in all cases (12-16). The patient in the present case was a middle-aged woman with a 10-year history of hypertension. As two typical clinical features observed in previous cases, sudden onset headache and lower-extremity dominant hemiparesis were present on admission in the present case. A CT scan of the current case revealed SAH within the right superior frontal sulcus and right interhemispheric fissure where SAH was often located in similar patients from previous reports. Notably, all previous reports describe patients from Japan and Korea and none of the patients affected are from western countries. A case involving simultaneous hemorrhage and ischemia due to ACA dissection has never been reported in China before and the present case is the first such report.

Diagnosis of ACA dissection can be challenging. The pathognomonic radiological findings of artery dissection are double lumen, mural hematoma and intimal flap (18). However, in view of the small size of the ACA, it is not possible to

observe these typical radiological findings in all patients with ACA dissection. It has been reported that intracranial artery dissection can present with aneurysmal dilatation, segmental stenosis or occlusion (19). It is worthy of note that fusiform or irregular aneurysmal dilatation at a non-branching site is very suggestive of intracranial artery dissection if it is associated with a segmental stenosis. If those radiological findings rapidly change on repeated imaging, for example, by an increase or reduction in artery size, or the appearance of aneurysmal dilatation, the diagnosis of intracranial artery dissection can be confirmed (1). Such serial changes on follow-up angiograms were considered to be the most characteristic angiographic findings in a patient with ACA dissection in a previous report (7). In the present case, segmental stenosis and fusiform aneurysmal dilatation in the A2 segment and occlusion in the A3 segment of right ACA were identified. A follow-up CT angiography conducted 5 months after onset demonstrated that the stenosis in the A2 segment resolved and dilatation in the A2 segment disappeared. The patient was confirmed as a case of ACA dissection using those characteristic radiological features. Therefore, in cases in which a diagnosis cannot be confirmed in the acute stage, a follow-up angiogram is very important as it may help with making the diagnosis.

Although artery dissection is an important cause of SAH concomitant with AIS, previous reports indicate these concurrent conditions may also occur in association with reversible cerebral vasoconstriction syndrome (RCVS), cerebral amyloid angiopathy (CAA) and cerebral artery atherosclerotic stenosis (20-22). SAH usually affects the convexities of the brain and is distant from the location of narrowing arteries in the RCVS. Watershed infarcts rather than territorial infarcts often coexist with SAH in RCVS (21). In the present case, SAH was not only located in the convexities of the brain but also in the right interhemispheric fissure. Brain MRI demonstrated an acute infarct in the territory of the right ACA near to the segment of the narrowing artery rather than in the watershed area. Thus, the diagnosis of RCVS was excluded by those imaging features. In 2014, Nakajima *et al* (19) suggested a diagnosis of CAA in two patients presenting with SAH accompanied with AIS concomitantly. However, none of the patients with CAA showed stenosis and dilatation of the cerebral artery. Thus, the diagnosis of CAA was not considered in the present case. Cerebral artery atherosclerotic stenosis has been reported as another cause of SAH concomitant with AIS (22,23). The exact mechanism by which cerebral artery atherosclerotic stenosis causes SAH is unknown. Rupture of the leptomeningeal collaterals could be the possible mechanism for SAH exclusively localized in the convexities of the brain in all the patients with cerebral artery atherosclerotic stenosis. However, in the present case, SAH was located in the convexities of the brain and also in the right interhemispheric fissure. The possible mechanism of SAH in this case maybe the direct rupture of the artery dissection. Furthermore, the rapid change of segment stenosis and dilation on repeated imaging that was observed in the present case would not occur in a patient with cerebral artery atherosclerotic stenosis. Therefore, the diagnosis of cerebral artery atherosclerotic stenosis was also excluded in this case.

The appropriate treatment of simultaneous hemorrhage and AIS due to ACA dissection remains controversial. It has

been suggested that patients with intracranial artery dissection and SAH should be treated with surgical or endovascular procedures because of the high incidence of rebleeding (20). Medical treatment, such as with anticoagulant or antiplatelet agents, has been suggested for patients with intracranial artery dissection without SAH (20). However, in the 15 cases of ACA dissection with SAH and ischemia (which includes the present case), only 6 cases underwent surgical or endovascular procedures and all of them showed evident dissection aneurysm (7-9,12,16,17). In addition, 6 cases, including the present case, received only conservative treatment without antithrombotic therapy (1,13-16). All of them experienced a good recovery and none of them suffered from rebleeding or further ischemia. In the present case, the patient's NIHSS score was improved to 3 and mRS score was improved from 5 to 3 at 5 months after onset following conservative treatment. The follow-up CT angiography showed clear improvements in the stenosis and dilatation in the A2 segment, which provides angiographic confirmation of the effectiveness of conservative treatment for the first time. Therefore, SAH concomitant with AIS due to ACA dissection maybe a somewhat benign type of SAH. Conservative treatment without antithrombotic therapy maybe a safe and effective choice in patients with SAH concomitant with AIS due to ACA dissection.

In conclusion, simultaneous hemorrhage and ischemia due to ACA dissection is very rare and, to the best of our knowledge, the present case is the first to be reported in China. Conservative treatment without antithrombotic therapy maybe a safe and effective choice in patients with SAH concomitant with ischemia due to ACA dissection.

References

1. Kwak JH, Choi JW, Park HJ, Chae EY, Park ES, Lee DH and Suh DC: Cerebral artery dissection: Spectrum of clinical presentations related to angiographic findings. *Neurointervention* 6: 78-83, 2011.
2. Huang YC, Chen YF, Wang YH, Tu YK, Jeng JS and Liu HM: Cervicocranial arterial dissection: Experience of 73 patients in a single center. *Surg Neurol* 72 (Suppl 2): S20-S27, 2009.
3. Mizutani T: Natural course of intracranial arterial dissections. *J Neurosurg* 114: 1037-1044, 2011.
4. Ono H, Nakatomi H, Tsutsumi K, Inoue T, Teraoka A, Yoshimoto Y, Ide T, Kitanaka C, Ueki K, Imai H and Saito N: Symptomatic recurrence of intracranial arterial dissections: Follow-up study of 143 consecutive cases and pathological investigation. *Stroke* 44: 126-131, 2013.
5. Guridi J, Gállego J, Monzón F and Aguilera F: Intracerebral hemorrhage caused by transmural dissection of the anterior cerebral artery. *Stroke* 24: 1400-1402, 1993.
6. Ohkuma H, Suzuki S, Kikkawa T and Shimamura N: Neuroradiologic and clinical features of arterial dissection of the anterior cerebral artery. *AJNR Am J Neuroradiol* 24: 691-699, 2003.
7. Suzuki I, Nishino A, Nishimura S, Numagami Y, Suzuki H, Utsunomiya A, Suzuki S, Uenohara H and Sakurai Y: Nontraumatic arterial dissection of the anterior cerebral artery: six cases report. *No To Shinkei* 57: 509-515, 2005 (In Japanese).
8. Inoue T, Fujimura M, Mastsumoto Y, Kondo R, Inoue T, Shimizu H and Tominaga T: Simultaneous occurrence of subarachnoid hemorrhage and cerebral infarction caused by anterior cerebral artery dissection treated by endovascular trapping. *Neurol Med Chir (Tokyo)* 50: 574-577, 2010.
9. Yasukama K, Kamijo Y, Momose G, Kobayashi S and Ikeda A: A case of anterior cerebral artery dissecting aneurysm presenting subarachnoid hemorrhage and cerebral infarction at the same time. *Surg Cerebral Stroke* 21: 461-466, 1993.

10. Kato N, Yamada Y, Hyodo A and Nose T: A case of anterior cerebral artery dissection presenting subarachnoid hemorrhage and cerebral infarction. *No Shinkei Geka J* 9: 157-161, 2000 (In Japanese).
11. Miyahara K, Sakata K, Gondo G, Kanno H and Yamamoto I: Spontaneous dissection of the anterior cerebral artery presenting subarachnoid hemorrhage and cerebral infarction: A case report. *No Shinkei Geka* 29: 335-339, 2001 (In Japanese).
12. Kimura S, Igarashi T, Kotani A and Katayama Y: Nontraumatic arterial dissection of the anterior cerebral artery with simultaneous cerebral infarction and subarachnoid hemorrhage: A case report. *No Shinkei Geka* 38: 273-278, 2010 (In Japanese).
13. Suzuki K, Mishina M, Okubo S, Abe A, Suda S, Ueda M and Katayama Y: Anterior cerebral artery dissection presenting subarachnoid hemorrhage and cerebral infarction. *J Nippon Med Sch* 79: 153-158, 2012.
14. Nanbara, S Tsutsumi K, Takahata H, Fujimoto T, Kawahara I, Ono T, Toda K, Baba H and Yonekura M: Spontaneous dissection of the anterior cerebral artery that simultaneously presented with cerebral infarction and subarachnoid hemorrhage, successfully treated with conservative management: A case report. *No Shinkei Geka* 40: 635-642, 2012 (In Japanese).
15. Im TS, Lee YS, Suh SJ, Lee JH, Ryu KY and Kang DG: Two cases of subarachnoid hemorrhage from spontaneous anterior cerebral artery dissection: A case of simultaneous hemorrhage and ischemia without aneurysmal formation and another case of hemorrhage with aneurysmal formation. *J Cerebrovasc Endovasc Neurosurg* 16: 119-124, 2014.
16. Kato Y, Hayashi T, Uchino A, Kakehi Y, Yamane F, Ishihara S and Tanahashi N: Fusiform dilatation of the outer contour of a dissected anterior cerebral artery revealed by magnetic resonance cisternography in a patient with simultaneous cerebral infarction and subarachnoid hemorrhage. *J Stroke Cerebrovasc Dis* 23: 1717-1720, 2014.
17. Han M, Rim NJ, Lee JS, Kim SY and Choi JW: Feasibility of high-resolution MR imaging for the diagnosis of intracranial vertebrobasilar artery dissection. *Eur Radiol* 24: 3017-3024, 2014.
18. Ahn SS, Kim BM, Suh SH, Kim DJ, Kim DI, Shin YS, Ha SY and Kwon YS: Spontaneous symptomatic intracranial vertebrobasilar dissection: Initial and follow-up imaging findings. *Radiology* 264: 196-202, 2012.
19. Nakajima M, Inatomi Y, Yonehara T, Hirano T and Ando Y: Nontraumatic convexal subarachnoid hemorrhage concomitant with acute ischemic stroke. *J Stroke Cerebrovasc Dis* 23: 1564-1570, 2014.
20. Singhal AB, Hajj-Ali RA, Topcuoglu MA, Fok J, Bena J, Yang D and Calabrese LH: Reversible cerebral vasoconstriction syndromes: Analysis of 139 cases. *Arch Neurol* 68: 1005-1012, 2011.
21. Kleinig TJ, Kimber TE and Thompson PD: Convexity subarachnoid haemorrhage associated with bilateral internal carotid artery stenosis. *J Neurol* 256: 669-671, 2009.
22. Debette S, Compter A, Labeyrie MA, Uyttenboogaart M, Metso TM, Majersik JJ, Goeggel-Simonetti B, Engelter ST, Pezzini A, Bijlenga P, *et al*: Epidemiology, pathophysiology, diagnosis, and management of intracranial artery dissection. *Lancet Neurol* 14: 640-654, 2015.
23. Geraldes R, Sousa PR, Fonseca AC, Falcão F, Canhão P and Pinho e Melo T: Nontraumatic convexity subarachnoid hemorrhage: Different etiologies and outcomes. *J Stroke Cerebrovasc Dis* 13: e23-e30, 2014.