

# Long-term outcome of non-stented tubularized incised plate urethroplasty for distal hypospadias repair: a complication analysis

Mamdouh Abdel-Hamid El-Hawy, Mostafa Magdi Ali, Amr M. Abdelhamid, Ahmed M. Fawzy, Alayman Hussein, Mostafa Sh. Mohamed Elsharkawy

*Urology and Nephrology Hospital, School of Medicine, Minia University, Minia, Egypt*

**Citation:** Abdel-Hamid Mohamid El-Hawy M, Ali MM, Abdelhamid AM, Fawzy AM, Hussein A, Elsharkawy MSM. Long-term outcome of non-stented tubularized incised plate urethroplasty for distal hypospadias repair: a complication analysis. Cent European J Urol. 2021; 74: 595-600.

## Article history

Submitted: March 6, 2021

Accepted: Aug. 7, 2021

Published online: Sept. 6, 2021

**Introduction** Although it is apparently simpler to perform unstented tubularized incised plate (TIP) repair for distal hypospadias repair, consensus on feasibility of the use of unstented repair is still a matter of debate. Evidence reporting that unstented repair outcome is comparable to stented repair, especially in the long-term, is still weak due to reporting outcome inconsistencies, different study designs, inclusion of more than one technique, and inherent variability in meatal locations. Thus, we need a continuous and evolving assessment of the outcome of unstented repair to compile adequate evidence on the advantage of unstented TIP repair in distal hypospadias entity. The aim of this article was to review our long-term results with tubularized incised plate urethroplasty for distal hypospadias repair without a postoperative stent to determine its outcome which might justify its use.

**Material and methods** After a review of 154 patients with distal penile hypospadias, who underwent repair in Minia Urology & Nephrology University Hospital in the period between June 2015 and February 2018, we excluded cases who underwent MAGPI repair, redo cases and patients who failed to complete follow-up. We chose 72 patients who had only 1<sup>st</sup> time TIP repair and whom we could contact. A total of 44 out of 72 cases with stented repair were assigned to Group A, while 28 cases with unstented repair were assigned to Group B. Success was assessed based on Hypospadias Objective Penile Evaluation (HOPE) score by three separate senior pediatric urology consultants, independent of the surgeon and in the absence of high post-void residual urine (PVR). Average rate was calculated to be compared between both study groups.

**Results** There was no statistically significant difference regarding preoperative meatal location and age at repair and short-term complications. In the long-term; there was no statistically significant difference between the occurrence of urethrocutaneous fistula (UCF, 4 vs 2 cases in Group A & B, respectively) and complete disruption (2 cases in each group) with need for redo repair. Results of total mean of HOPE score calculated showed no statistically significant differences between study groups and also failed to show statistical significance on individual domains of HOPE score.

**Conclusions** Unstented TIP repair showed a similar outcome to stented TIP repair of distal hypospadias especially in the long-term despite a more troublesome early postoperative period.

## Corresponding author

Mostafa Magdi Ali

Minia University

Urology and Nephrology Hospital

Department of Urology

61111 Minia, Egypt

phone: +20 100 285 2689

m.magdi80@yahoo.com

**Key Words:** non-stented ↔ distal hypospadias ↔ complications

## INTRODUCTION

Tubularized incised plate urethroplasty (TIPU), that was first described by Snodgrass for correction of distal hypospadias, is currently the most frequently performed technique for single-stage primary hypospadias repair [1].

Snodgrass, in his early experience, used stented repair for a period of ten days as a urinary diversion. However, significant stent related complications were reported which included unresolved wound infection, bladder spasm and stent migration or obstruction, in addition, stenting required special care to prevent ventral bowing pressure on the neourethra with subsequent wound rupture [2].

In most of the reported series, stented repair for a few days may be useful to prevent neourethral stricture, urethrocutaneous fistula (UCF) and postoperative urinary retention. However, Hafez et al. recently showed that stenting repair was unnecessary to enhance normal urethral healing in an animal trial on TIP repair of distal hypospadias [3].

The role of indwelling urethral stent as a method of urinary drainage after hypospadias repair and the period needed for stenting are highly debated with no clear guidelines. Also, recent modifications discussing hypospadias repair move towards more simplicity and post-operative course which has been an evolving concern [4]. However, the main disadvantages of a stent-free repair are that it may compromise the patients' comfort and increase the risk of postoperative urinary retention.

Despite that, good outcome results in children with stent-free repair of distal penile hypospadias without prolonged discomfort in the short-term has been reported, long-term outcome is still not clear [5]. Recent evidence on stent-free TIP repair is still weak, so we are in need for more studies addressing the outcome of stent-free repair especially in the long term [6]. We reported our results comparing the outcome of stented and stent-free TIP repair of distal penile hypospadias.

## MATERIAL AND METHODS

We reviewed 154 children who had TIP repair of distal penile hypospadias in the period from June 2015 to February 2018 at Urology Department, Minia Nephrology & Urology University Hospital; we excluded cases who underwent meatal advancement and glanuloplasty incorporated (MAGPI) repair, redo cases and patients who failed to complete follow-up, only 72 patients with first time TIP repair of distal hypospadias were enrolled in the study after establishing contact with the patients and retrieval of pre-, intra-

and early postoperative data (Figure 1). All patients underwent primary distal hypospadias repair after giving informed written consent and counselling the patients about the possibility of urethral stenting or non-stenting.

Surgery was performed under general anesthesia by a more or less uniform surgical team where repair was done via TIP repair as described by Snodgrass [7] with minimal modification [8] with dorsal Dartos covering flap in those with satisfying glandular width (>14 mm) and adequate urethral plate depth (>7 mm). The decision whether to insert a urethral stent or not was left to the surgeon's preference. Patients in good condition were discharged on the 5<sup>th</sup> postoperative day after removal of the dressing and stent if present. Unless complications occurred, patients usually were scheduled for follow-up visits weekly during the first two months, then monthly during the first postoperative year. Early postoperative complications e.g. hematoma, urinary retention, edema/extravasation, wound dehiscence, bladder spasm, soaking was managed and documented. Ultimately, we obtained 44 patients who had urethral stent as the only post-operative drainage and were included into Group A, while the remaining 28 patients who had neither urethral or suprapubic drainage were included in Group B.

Patients were scheduled for post-void residual urine (PVR) assessment using bladder scan to confirm absence of a significant PVR. Patients were then interviewed during the following visit for assessment using the Hypospadias Objective Penile Evaluation (HOPE) questionnaire [9]. HOPE was scored by three senior consultants other than the operator who was blinded regarding operative details. HOPE score consists of 5 domains: the 1<sup>st</sup> directed to neomeatus site, the 2<sup>nd</sup> domain assessed meatal size, the 3<sup>rd</sup> domain evaluates glans shape, the 4<sup>th</sup> domain evaluates penile skin cosmeses and the 5<sup>th</sup> domain included two questions to assess the penis orientation (torsion & curvature). The evaluation by each investigator alone with a reference to a picture map and the average result were calculated.

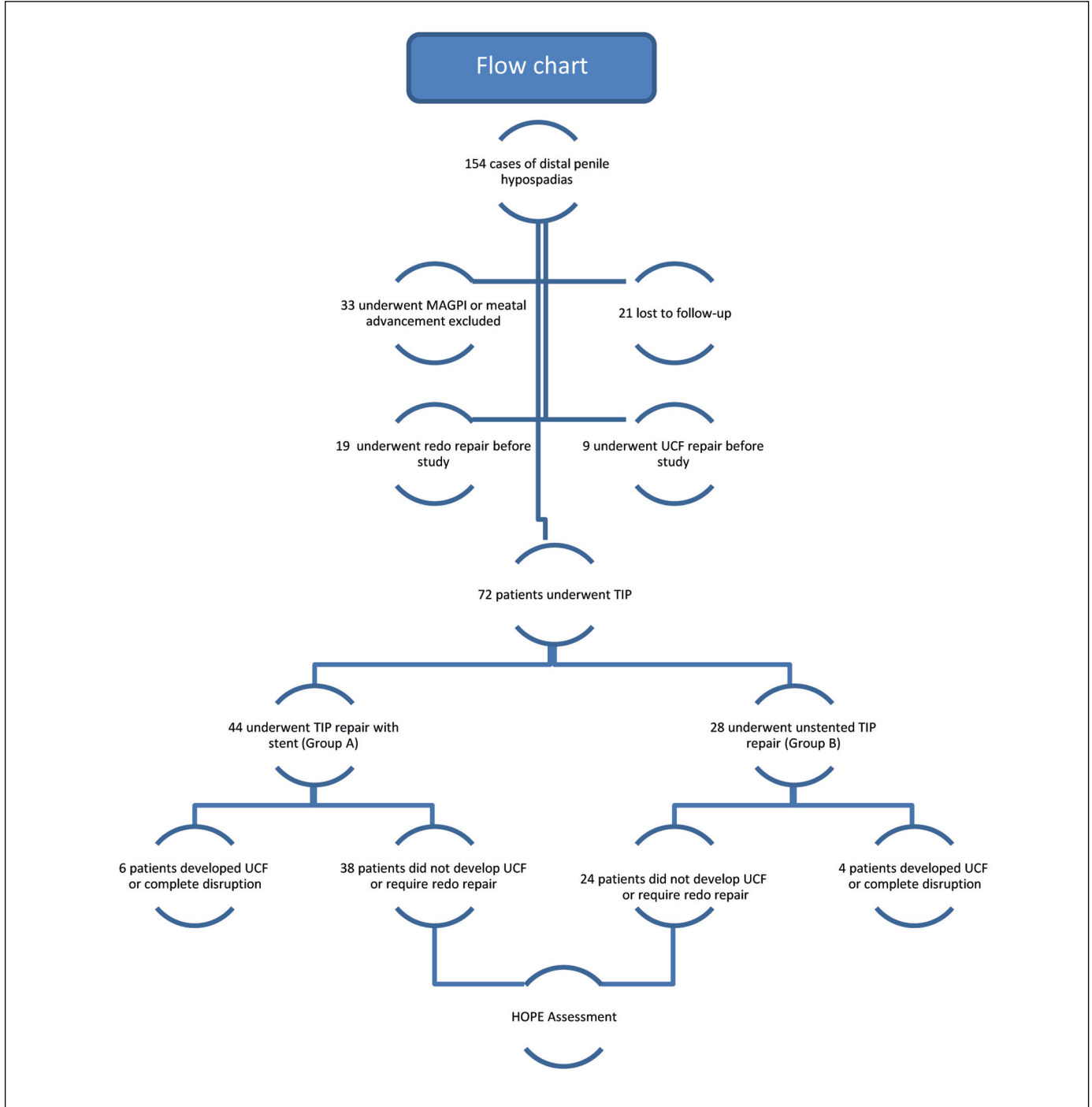
### Statistical analysis

All data were analyzed using SPSS software version 18.0 (SPSS Inc., Chicago, IL, USA). Normally distributed descriptive data are expressed as means  $\pm$ SD; medians and interquartile range were used for non-normally distributed variables. Normally distributed data were compared using Student t test. A complications analysis was conducted with the Fishers exact test to compare the stented and unstented groups. A p-value <0.05 was considered significant.

**RESULTS**

A total of 72 patients were included in our study; 44 patients in Group A and 28 patients in Group B. Patients in Group A were interviewed at a mean of 16 months after repair while Group B patients were followed up at a mean of 17 months postoperatively (Table 1).

A review of our patients showed that there was no statistically significant difference between the study groups regarding age at repair. All patients had their meatus located subcoronally or at the distal shaft of the penis, as documented by the surgeon intraoperatively, with no statistically significant differences between study groups regarding the distribution



**Figure 1.** Flow chart of patients involved in the study.

MAGPI – Meatal Advancement and Glanuloplasty; UCF – urethrocutaneous fistula; TIP – tubularized incised plate

of different meatal location during repair. Total events which occurred early (up to one-year postoperatively) showed no statistically significant differences between the study groups (Table 1).

Significant bladder spasm associated with periurethral leakage and need for premature redressing occurred in 4 patients in Group A only. On the other hand, urine retention occurred in 4 patients in Group B; 3 of the cases were associated with extravasation and were managed with early suprapubic diversion in the 1<sup>st</sup> 3 days after repair and one case was managed by urethral drainage. Only one case with dislodged urethral stent in the 3<sup>rd</sup> post-operative day in Group A developed urine retention that was managed by reinsertion of urethral catheter. All auxiliary maneuvers were done under light sedation (Table 1). Wound infection occurred in 6 cases in Group A patients; 2 of them had significant bladder spasm associated with soaked dressing and premature redressing twice within 5 days. Two out of six cases with wound infection in Group A developed UCF later on, while the other 2 cases developed complete disruption with complete failure. In Group B; 4 cases developed wound infections that were managed conser-

**Table 1.** Patients demographics, perioperative data and post-operative complications

Variable	Group A (n = 44)	Group B (n = 28)	P Value	
Age at repair (months)	(9–31) 19.7 ±6.1	(10–29) 18.2 ±5.7	0.3	
Age at interview (months)	(18–48) 31.4 ±8.5	(15–48) 31.8 ±7.8	0.1	
Follow up duration (months)	(2–19) 15.7 ±4.6	(3–21) 17.3 ±5.5	0.8	
Site of meatus	Sub-coronal	12 (27.3%)	10 (35.7%)	0.6
	Distal penile	32 (72.7%)	18 (64.3%)	
Complication events	12 (27.3%)	7 (25%)	0.7	
Bladder spasm	4 (9.1%)	0 (0%)	0.1	
Urine retention	1 (2.3%)	4 (14.3%)	0.07	
Hematoma	0 (0%)	0 (0%)	0.9	
Early suprapubic diversion	0 (0%)	3 (10.7%)	0.05	
Postoperative wound infection			0.8	
Resolved	2 (4.5%)	2 (7.1%)		
Unresolved	4 (9.1%)	2 (7.1%)		
Urethrocutaneous fistula (UCF)	4 (9.1%)	2 (7.1%)	0.9	
Meatal stenosis	1 (2.3%)	0 (0%)	0.9	
Urethral stricture	0 (0%)	0 (0%)	1	
Disruption	2 (4.5%)	2 (7.1%)	0.6	
Success (no UCF or no need for redo repair)	38 (86.4%)	24 (85.7%)	0.9	

n – number

**Table 2.** Hypospadias Objective Penile Evaluation Score

Question	HOPE assessment	Group A (n = 38) Mean ±SD	Group B (n = 24) Mean ±SD	P Value
Q1	Meatal position	8.4 ±1.6	9.1 ±1.1	0.09
Q2	Meatal shape	6.7 ±2.5	7.1 ±2.4	0.5
Q3	Glans shape	6.6 ±2.6	6.5 ±2.8	0.8
Q4	Skin	6.3 ±2.7	6.8 ±2.9	0.4
Q5.1	Penile torsion	7.9 ±2	7.4 ±2.1	0.3
Q5.2	Penile curvature	7.6 ±2.1	8.1 ±2.1	0.3
Totals		43.3 ±5.4	44.8 ±6.1	0.4

HOPE – Hypospadias Objective Penile Evaluation Score; n – number; SD – standard deviation

vatively except in 2 cases who had early suprapubic diversion and later one of them developed complete disruption and awaited redo repair. An additional 2 cases in Group B developed UCF that was repaired successfully. However, there was no statistically significant difference in the incidence of wound infection between study groups (Table 1).

Concerning the long-term results, no cases of urethral stricture were reported and only 1 case developed meatal stenosis in Group A, treated by meatotomy, with no statistically significant difference between study groups. UCF fistula occurred in 4 versus 2 cases in Group A and B respectively and complete disruption and need for redo repair occurred in 4 cases; 2 in each group. However, there was no statistically significant difference between study groups regarding occurrence of UCF ( $p = 0.9$ ) or complete disruption ( $p = 0.6$ ) or even on the total success in either group (88.6% vs 89.3%) in Group A & B respectively ( $p = 0.9$ ) (Table 1).

After exclusion of cases with UCF or those in need for redo repair, all patients voided freely with no PVR. There was no statistically significant difference between study groups regarding total mean of HOPE score ( $p = 0.4$ ) or any individual domain of HOPE (Table 2).

## DISCUSSION

Nowadays, hypospadias repair is challenging with great controversy about different techniques used for postoperative urinary diversion and its methods, aiming at gaining best postoperative results with minimal complications [4]. Also, there is mild to moderate evidence that stent-free repair poses a good outcome and there is need for more studies to strengthen that hypothesis [10]. Meatal stenosis, urethrocutaneous fistula and unsuccessful repair are the most common problems within the first 6 months postoperatively [11]. Making the decision whether

to insert a stent or not when repairing hypospadias is a major task with the goal to obtain an excellent outcome and avoid the previously mentioned complications. The main purpose of indwelling urethral stents is to maintain a dry suture line, but it has been associated with catheter related postoperative problems [5, 12, 13, 14]. However, urethral stenting has shown to reduce the incidence of complications and for preservation of the repair [15].

We chose to compare our study with recently published 5 prospective randomized or quasi-randomized controlled studies, except one study designed as a retrospective cohort. All of these studies compared the outcome of TIP repair in a total 741 cases of distal hypospadias between unstented (377 cases) and stented (364 cases) patients except for 7 cases in one study where MAGPI repair was done (which were excluded from our study group) [5, 16–19].

Meatal location was distal shaft in the majority (278 cases), followed by subcoronal position in 207 cases, mid-shaft location in 71 cases, coronal position in 46 cases and glandular in 46 cases. In our study, hypospadias opening located at distal shaft constituted the majority, 72.7% and 64.3% in stented and unstented groups respectively. The remaining cases were subcoronal in position with no significant difference between study groups [5, 16–19]. In our study, there was no significant difference between study groups regarding the mean age at repair or at follow-up with a mean duration  $\pm$ SD of follow-up after repair  $10.7 \pm 4.6$  vs  $12.3 \pm 5.5$  in Group 1 and 2 respectively. Median age in the same 5 studies mentioned above ranged from 2.5 up to 7.4 years. None of the previously described studies reported significant differences regarding distribution of age between their groups [5, 16–19].

Bladder spasm was an event consistently related to stented groups; where a total of 61 cases were reported to have bladder spasm in the previously described studies where 49 cases of them occurred in stented cases with a statistically significant difference. In our study, significant bladder spasm occurred in 4 children (9%) of the stented group. Despite the inherent stent related pain, there was no significant difference regarding the occurrence of bladder spasm between study groups among the above-mentioned studies and including our study. Decreased incidence of bladder spasm in our study in comparison to the 5 studies mentioned before were because we only reported cases with significant bladder spasm refractory to anticholinergics (oxybutynin i.v. 5 mg/5 ml twice daily) and associated with soaking and early dressing [5, 16–19].

Acute postoperative urinary retention was documented in 17 patients in 4 out of 5 of the previously

described studies and all of them were in the unstented groups with a statistical significance. In our study, 4 cases of acute urinary retention occurred in the unstented group versus only one case in the stented group, which was due to catheter malfunction. However, there was no statistically significant difference ( $p = 0.07$ ). This difference may be due to lack of reporting of incident catheter malfunction/replacement in stented cases which is largely dependent on catheter properties. Urinary retention was associated with suprapubic diversion in 4 cases only reported in one out of 5 studies described while remaining cases was treated by insertion of urethral catheter. Suprapubic urinary diversion was needed in 3 cases in the unstented group only in our study with nearly statistical significance ( $p = 0.05$ ).

There was no statistically significant difference in the incidence of hematoma, wound infection and wound dehiscence in the reported cases in the 5 studies described before in our study. The same applied for our study [5, 16–19].

In the long-term, the follow-up duration reported by the other 5 studies described, ranged from 3 up to 11.8 months, while in our study we followed up our patients for longer, up to nearly 18 months postoperatively. None of these 5 studies mentioned a significant difference regarding the occurrence of meatal stenosis or urethral stricture in stented versus unstented groups [5, 16–19]. Karakaya et al., stated that meatal stenosis may occur as a result of individual variation in wound healing or operative technical problems such as advancement of the external meatus to the tip of the glans [21].

Urethrocutaneous fistula occurred in 53 cases in the 5 studies previously described (28 cases in unstented groups), statistically significant difference was reported in 2 [18, 19] out of 5 studies [5, 16–19]. In our study there was no significant difference in the occurrence of UCF between study groups.

We used the HOPE score to evaluate the long-term outcome of hypospadias repair between study groups and we found no statistically significant difference between total mean of the HOPE score between stented versus unstented cases, even on the individual domain levels of the HOPE score. In 1 out of the previously described 5 studies; hypospadias repair success was based on the Hypospadias Objective Score Evaluation (HOSE) of more than 14 points which was reported in 91% of stented versus 85% of unstented cases. On comparing column proportion this difference was not statistically significant. However, success in this study was based on a HOSE score of more than 14 points and did not compare the mean score between study groups [16]. Also, failed cases with UCF or glans dehiscence was not excluded



from the comparison as it is included in HOSE score [20]. Despite those cases with UCF or wound disruptions has been unsuccessful and required reoperation. Also, subjective evaluation of the HOSE score represented a major limitation. In our study, HOPE score represented a more objective score being investigated by three senior pediatric urologists and scoring is done by correlation with a picture guide independent of parent or guardian which may be variable due to disproportionate expectations.

Karakaya et al., compared the results of TIPU in distal hypospadias with and without the use of a urethral stent. Based on HOSE scoring scale, total HOSE scores were ( $\geq 14$ ) in both groups, with no significant difference ( $p = 0.622$ ). The stented

and unstented groups also, had acceptable and near similar outcomes in terms of postoperative slit-like meatus, and urinary stream [21].

## CONCLUSIONS

Early complications after TIP repair of distal hypospadias, especially postoperative urinary retention, still represent a postoperative problem that can jeopardize the final outcome and lead to a need for emergency diversion. This is an additional burden especially in unstented repair.

## CONFLICTS OF INTEREST

The authors declare no conflicts of interest.

## References

- Hardwicke JT, Bechar JA, Hodson J, Osmani O, Park AJ. Fistula after single-stage primary hypospadias repair- A systematic review of the literature. *J Plast Reconstr Aesthet Surg.* 2015; 68: 1647-1655
- Snodgrass WT. Tubularized incised plate hypospadias repair: indications, technique, and complications. *Urology.* 1999; 54: 6-11.
- Hafez AT, Herz D, Bägli D, Smith CR, McLorie G, Khoury AE. Healing of unstented tubularized incised plate urethroplasty: an experimental study in a rabbit model. *BJU Int.* 2003; 91: 84-88.
- Oesterling JE, Gearhart JP, Jeffs RD. Urinary diversion in hypospadias surgery 1987. *Urology.* 1987; 29: 513-516.
- El-Sherbiny MT. Tubularized incised plate repair of distal hypospadias in toilet-trained children: should a stent be left? *BJU Int.* 2003; 92: 1003-1005.
- Chua M, Welsh C, Amir B, et al. Non-Stented versus Stented Urethroplasty for Distal Hypospadias Repair: A Systematic Review and Meta-Analysis. *J Pediatr Urol.* 2018; 14: 212-219.
- Snodgrass WT, Bush N, Cost N. Tubularized incised plate hypospadias repair for distal hypospadias. *J Pediatr Urol.* 2010; 6: 408-413.
- Abdel-Hamid Mohamid El-Hawy M. Minimal modifications could decrease fistula rate during tubularized incised plate procedure in distal hypospadias repair. *J Pediatr Urol.* 2013; 9 (6 Pt A): 789-792.
- van der Toorn F, de Jong TP, de Gier RP, et al. Introducing the HOPE (Hypospadias Objective Penile Evaluation)-score: a validation study of an objective scoring system for evaluating cosmetic appearance in hypospadias patients. *J Pediatr Urol.* 2013; 9 (6 Pt B): 1006-1016.
- Chua M, Welsh C, Amir B, et al. Non-stented versus stented urethroplasty for distal hypospadias repair: A systematic review and meta-analysis. *J Pediatr Urol.* 2018; 14: 212-219.
- Elbakry A. Further experience with the tubularized- incised urethral plate technique for hypospadias repair. *BJU Int.* 2002; 89: 291-294.
- Leclair MD, Camby C, Battisti S, Renaud G, Plattner V, Heloury Y. Unstented tubularized incised plate urethroplasty combined with foreskin reconstruction for distal hypospadias. *Eur Urol.* 2004; 46: 526-530.
- Almodhen F, Alzahrani A, Jednak R, Capolicchio JP, El Sherbiny MT. Nonstented tubularized incised plate urethroplasty with Y-to-I spongioplasty in non-toilet trained children. *Can Urol Assoc J.* 2008; 2: 110-114.
- Lorenz C, Schmedding A, Leutner A, Kolb H. Prolonged stenting does not prevent obstruction after TIP repair when the glans was deeply incised. *Eur J Pediatr Surg.* 2004; 14: 322-327.
- Arda IS, Mahmutoglu M. Urethral catheterization in hypospadias surgery: Should the device enter the bladder or be made a urethral stent? *J Pediatr Surg.* 2001; 36: 1829-1831.
- El-Karamany TM, Al-Adl AM, Omar RG, Abdel Aal AM, Eldakhkhny AS, Abdelbaki SA. A Critical Analysis of Stented and Unstented Tubularized Incised Plate Urethroplasty Through a Prospective Randomized Study and Assessment of Factors Influencing the Functional and Cosmetic Outcomes. *Urology.* 2017; 107: 202-208.
- Chalmers DJ, Siparsky GL, Wiedel CA, Wilcox DT. Distal hypospadias repair in infants without a postoperative stent. *Pediatr Surg Int.* 2015; 31: 287-290.
- Li X, Xu N, Xue X, et al. One-stage nonstented tubularized incised plate urethroplasty for pain and complication after hypospadias repair. *Zhongguo Xiu Fu Chong Jian Wai Ke Za Zhi.* 2014; 28: 1505-1508.
- Naveed A, Iftikhar A, Fraz O, et al. Comparison between urethroplasty with and without stent for hypospadias in terms of postoperative retrocutaneous fistula formation. *Pak Armed Forces Med J.* 2018; 68: 1511-1516
- Holland AJ, Smith GH, Ross FI, Cass DT. HOSE: an objective scoring system for evaluating the results of hypospadias surgery. *BJU Int.* 2001; 88: 255-258.
- Karakaya AE, Doğan AB, Güler AG. Use of a Stent in Distal Hypospadias Repaired by Tubularized Incised Plate Urethroplasty: A Comparative Study. *Urol Int.* 2019; 102: 336-340. ■