

A predicted model for postoperative seizure outcomes after the surgical resection of supratentorial cavernous malformations

Chun Wang (MD), Xiaobo Yu (MD), Sudeep Shrestha (MD), Cong Qian (MD), Lin Wang (MD), Gao Chen (MD)*

Abstract

To explore a predicted model for postoperative seizure outcomes after the surgical resection of supratentorial cavernous malformations.

This study was a retrospective review of consecutive patients with cerebral supratentorial cavernous malformations presenting with seizures. All patients underwent surgical resection of CCMs. Univariate and multivariate analyses were performed to determine the predictive value of the preoperative seizure frequency, seizure type, seizure duration, lesion location, lesion size, and the presence of residual hemosiderin.

A total of 43 patients met the inclusion criteria. After a mean follow-up period of 40.95 months, 34 patients who were free from postoperative seizures were classified into Engel class I, and the remaining 9 patients were classified into Engel classes II–IV. A univariate analysis showed that the seizure frequency ($\chi^2=13.440$, $P=0.004$) and seizure duration ($\chi^2=5.145$, $P=0.023$) prior to surgery were associated with a worse postoperative seizure prognosis. Other covariates including age at onset, gender, a history of the medications taken, smoking status, family history, lesion characteristics, and the role of hemosiderin were not related to seizure outcomes. Logistic regression results demonstrated that the preoperative seizure frequency was an effective predictor ($P=0.004$). The receiver operating characteristic curve indicated that area under the curve for the preoperative seizure frequency test was 0.833 (95% confidence interval 0.709–0.957, $P=0.002$).

The preoperative seizure frequency was a prognostic factor for postoperative seizure outcomes after surgical resection of supratentorial cavernous malformations. To obtain a favorable prognosis for CCM patients with preoperative seizures, early intervention might be a better choice.

Abbreviations: AUC = area under the curve, CCMs = cerebral cavernous malformations, EEG = electroencephalogram, MRI = magnetic resonance image, ROC = receiver operating characteristic.

Keywords: cerebral cavernous malformations, Engel class, seizure frequency, surgery

1. Introduction

Cerebral cavernous malformations (CCMs), which are a special type of cerebrovascular abnormality, occur in approximately 0.2% to 0.5% of the population.^[1] Although CCMs are regarded as benign brain lesions,^[2] 40% to 70% of patients with supratentorial CCMs suffer seizures, which could decrease their quality of life.^[3] Blood breakdown products affecting adjacent brain tissue is considered the main cause of seizures.^[4] Approximately 35% to 40% of all patients with CCM-related seizures may experience chronic or even drug-resistant seizures.^[5]

For these cases, surgical removal of the lesion is regarded to be the most effective management of intractable seizures.^[6] However, recently, postoperative seizures are still a tough problem in clinical practice and in research.

A critical issue regarding postoperative seizure control is to manage the prognostic factors prior to surgery. Previous studies have indicated that some characteristics were shown to consistently correlate with favorable postoperative seizure outcome.^[7] Complete removal of the hemosiderin rim was reported to be the most effective approach to improving postoperative seizures^[5,8]; however, this was not the determining factor because some of the patients still presented with postoperative seizures, even if they underwent complete resection of CCM and the adjacent hemosiderin rim.^[9] Sporadic seizures and a shorter duration of the seizures were also considered crucial prognostic factors for postoperative seizure outcomes after surgical resection of both the cavernous malformations and the hemosiderin rim.^[10,11] A retrospective study of 163 patients who underwent pure CCM lesionectomy indicated that 98.4% of patients were seizure-free postoperatively in the preoperative sporadic seizure group compared with 68.7% of patients who were in the chronic epilepsy group.^[11] Similarly, Baumann et al^[12] reported that patients with simple seizures were significantly more likely to be seizure-free postoperatively than those with secondarily generalized seizures in a 3-year follow-up period. Moreover, previous studies have also demonstrated that patients with a seizure duration of <1 or 2 years had improved postoperative seizure outcomes compare to patients with a longer seizure duration.^[13,14] However, there was no study focusing on

Editor: Perbinder Grewal.

CW and XY have contributed equally to this work.

The authors have no conflicts of interest to disclose.

Department of Neurosurgery, The Second Affiliated Hospital of Zhejiang University School of Medicine, Hangzhou, China.

* Correspondence: Gao Chen, Department of Neurosurgery, The Second Affiliated Hospital of Zhejiang University School of Medicine, 88 Jiefang Road, Hangzhou, Zhejiang 310009, China (email: d-chengao@zju.edu.cn).

Copyright © 2016 the Author(s). Published by Wolters Kluwer Health, Inc. All rights reserved.

This is an open access article distributed under the terms of the Creative Commons Attribution-Non Commercial License 4.0 (CCBY-NC), where it is permissible to download, share, remix, transform, and buildup the work provided it is properly cited. The work cannot be used commercially.

Medicine (2016) 95:26(e4078)

Received: 9 March 2016 / Received in final form: 7 June 2016 / Accepted: 7 June 2016

<http://dx.doi.org/10.1097/MD.0000000000004078>

an effective comprehensive evaluation model for postoperative seizure outcomes after surgical resection of supratentorial cavernous malformations.

Our present retrospective study aimed to examine prognostic factors for postoperative seizure outcomes after surgical resection of supratentorial CCMs and produce an effective model to help clinical doctors determine the best time for treatment and predict the prognosis in supratentorial CCM patients to a certain extent.

2. Methods

2.1. Ethical review

Clinical ethics committee approval of the Second Affiliated Hospital of Zhejiang University School of Medicine was obtained for the study.

2.2. Patients

Between January 2009 and January 2014, 43 patients were recruited in the study by the Department of Neurosurgery of the Second Affiliated Hospital of Zhejiang University School of Medicine. Inclusion criteria of this study were as follows: diagnosis of supratentorial CCMs confirmed with histological examination; a preoperative electroencephalogram (EEG) confirming the diagnosis of seizures; a hemosiderin rim detected by preoperative magnetic resonance image (MRI); the surgical resection of CCMs; and a follow-up of more than 1 year. Exclusion criteria of this study were as follows: patients complicated with other brain lesions such as meningioma; patients with severe systemic disorders.

2.3. Study design

After strict selection and systematic evaluation, patients in accordance with the inclusion criteria were divided into the postoperative seizure and seizure-free groups according to the Engel classification. Data collection included gender; age; medicines taken; family history; smoking status; seizure type; seizure duration; seizure frequency; lesion location, size, and numbers; hemorrhage; and residual hemosiderin. All the patients had pre- and postoperative MRI to detect the hemosiderin rim and a preoperative EEG with MRI to confirm the location of the CCM. Complete surgical removal of the CCM was performed in all the patients by a senior neurosurgeon. Follow-up was conducted by telephone interviews for more than 1 year after surgery. Postoperative seizure outcomes were determined as follows using the Engel classification^[15]: class I, seizure-free or residual aura (Engel class I); class II, rare disabling seizures (<3 complex partial seizures per year) (Engel class II); class III, worthwhile seizure reduction (Engel class III); and class IV, no worthwhile improvement (Engel class IV).

2.4. Statistical analysis

Statistical analysis was performed using SPSS version 20.0 (SPSS, Inc., Chicago, IL) and RStudio version 0.99.891. Descriptive statistics were used to describe the baseline demographics in our study population. Two-sample *t* tests were used for associations between seizure outcome and a continuous variable (age and seizure size). Univariate nonparametric analyses were performed using the Pearson chi-squared test, continuity correction or Fisher exact test for unadjusted associations between seizure outcome and categorical variables (patient gender, medicine taken, family

history, smoking, seizure type, duration and frequency, lesion location and numbers, hemorrhage, and residual hemosiderin). Multivariate statistical analysis was performed using logistic regression to determine the independent predictive value of several variables on seizure outcome. The receiver operating characteristic (ROC) curve was then plotted using RStudio. Tests were 2-tailed, and a *P* value of <0.05 was considered to be significant for all analyses.

3. Results

3.1. Demographics and clinical data

A total of 43 consecutive patients met our inclusion criteria. After a mean follow-up period of 40.95 months, 34 patients who were free from postoperative seizures were classified into Engel class I, and the remaining 9 patients were classified into Engel classes II–IV. The demographics and clinical data were shown in Table 1.

Table 1
Demographics and clinical data.

Variables	Engel class I (n = 34)	Engel classes II–IV (n = 9)	Statistics <i>P</i>
Onset age, y (SD)	37.059 (5.744)	37.889 (13.779)	0.886
Gender, n (%)			0.964
Female	14 (41.2)	3 (33.3)	
Male	20 (58.8)	6 (66.7)	
Medicine taken, n (%)			0.718
Yes	7 (20.6)	3 (33.3)	
No	27 (79.4)	6 (66.7)	
Family history, n (%)			1.000
Yes	1 (2.9)	0 (0.0)	
No	33 (97.1)	9 (100.0)	
Smoke, n (%)			1.000
Yes	4 (11.8)	1 (11.1)	
No	30 (88.2)	8 (88.9)	
Lesion size, cm (SD)	1.832 (0.855)	1.578 (0.773)	0.428
Seizure duration, n (%)			0.023
<2 y	27 (79.4)	3 (33.3)	
≥2 y	7 (20.6)	6 (66.7)	
Seizure frequency, n (%)			0.004
1	18 (52.9)	0 (0.0)	
2–5	10 (29.4)	3 (33.3)	
6–10	1 (2.9)	1 (11.1)	
>10	5 (14.7)	5 (55.6)	
Seizure type, n (%)			0.552
Partial	2 (5.9)	0 (0.0)	
Generalized	30 (88.2)	8 (88.9)	
Multiple kinds	2 (6.8)	1 (11.1)	
Seizure location, n (%)			1.000
Temporal	14 (41.2)	4 (44.4)	
Nontemporal	20 (58.8)	5 (55.6)	
Seizure side, n (%)			0.606
Left	17 (50.0)	6 (66.7)	
Right	17 (50.0)	3 (33.3)	
Lesion number, n (%)			0.515
1	32 (94.1)	8 (88.9)	
2	2 (5.9)	1 (11.1)	
Hemorrhage, n (%)			0.515
Yes	32 (94.1)	8 (88.9)	
No	2 (5.9)	1 (11.1)	
Residual hemosiderin, n (%)			0.319
Yes	12 (35.3)	1 (11.1)	
No	22 (64.7)	8 (88.9)	

SD = standard deviation.

Table 2

Logistic regression results examining the risk factors of postoperative cerebral cavernous malformations seizure prognosis.

	B	SE	Wald	P
Seizure frequency	1.054	0.367	8.243	0.004
Constant	-3.952	1.129	12.257	0.000

B = coefficient of regression, SE = standard error, Wald = Wald test value.

As for the seizure itself, only 1 patient had a family history of CCM. Generalized tonic-clonic seizures were present in 30 patients, and the rest had partial onset or presented with many different types of seizures. The median interval between seizure onset and surgery was 6 months (range: 1 day - 40 years), and only 5 patients (11.6%) had more than 10 seizures before surgery.

Regarding to the lesion, temporal (n=18, 41.9%) and frontal (n=18, 41.9%) lobes were the most common areas for CCMs, followed by the parietal (n=4, 9.3%) and occipital lobes (n=3, 7.0%). The probability of the occurrence of a CCM was almost the same in the left and right brain hemispheres (left: right=53.5%:46.5%). Most patients had only 1 lesion in the brain, and 3 patients (7.0%) had 2 CCMs. The average diameter of the lesions was 1.78 cm (range: 0.50–4.30 cm). The hemorrhage rate was 93.0% in all patients. The total removal rate of the hemosiderin rim was 64.7% in the Engel class I group versus 88.9% in the Engel classes II to IV group (P=0.319).

3.2. Factors affecting postoperative seizure outcomes

The aforementioned covariates including age at onset; gender; family history; smoking status; seizure type; seizure frequency and duration prior to surgery; lesion location, size, and number; hemorrhage; and residual hemosiderin were analyzed. Univariate analysis showed that seizure frequency ($\chi^2=13.440$, $P=0.004$) and seizure duration ($\chi^2=5.145$, $P=0.023$) prior to surgery were associated with a worse postoperative seizure prognosis (Table 1). Logistic regression was then performed using the preoperative seizure frequency and seizure duration as 2 possible predictors. The logistic regression results demonstrated that the preoperative seizure frequency was an effective predictor ($P=0.004$, Table 2). The predicted model was

$$\text{Pre} = f(x) = \frac{1}{1 + e^{3.952 - 1.054x}}$$

In this equation, x=1 for a seizure that occurs once prior to surgery, x=2 for a seizure that occurs 2 to 5 times prior to surgery, x=3 for a seizure that occurs 6 to 10 times prior to surgery, and x=4 for a seizure that occurs more than 10 times prior to surgery. Pre was the predicted value of this model. The ROC curve analysis indicated that the area under the curve (AUC) for the preoperative seizure frequency test was 0.833 (95% confidence interval [CI] 0.709–0.957, $P=0.002$; Fig. 1), indicating that this equation had a high efficiency of predicting postoperative seizure outcomes. The optimal cutoff point of Pre was 0.052 (data not shown, calculated by RStudio). If the Pre value was larger than 0.052, patients would more likely to obtain an outcome of Engel classes II to IV, and if the Pre value was <0.052, patients would have a good outcome. We found that f(1) was the optimal cutoff point value as it indicated that if the patient had a seizure more than once before the surgery, there would be a great probability for him (or her) to have a poor outcome (Engel classes II–IV).

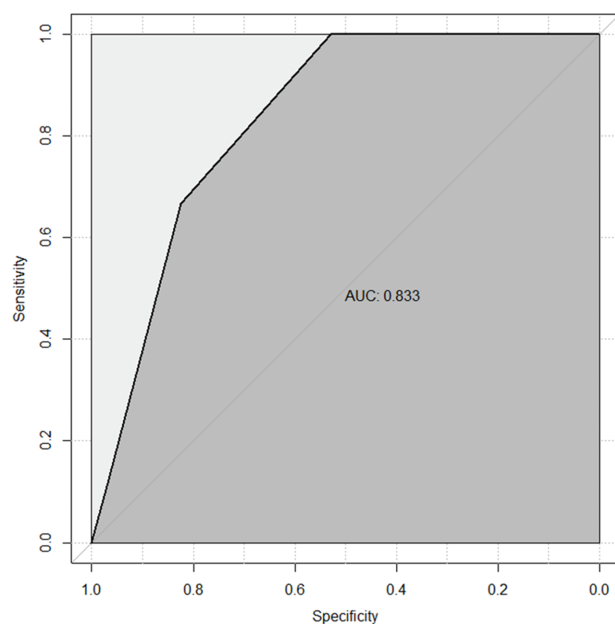


Figure 1. Receiver operating characteristic curve of the predicted model. AUC = area under the curve.

4. Discussion

Some previous clinical researchers had focused on detecting positive predictors of postoperative seizures after CCM surgery,^[10–12] but the predictors varied between these studies. In addition, there was also a review^[7] of articles published between 1985 and 2009 regarding the extensive resection of CCM along with the hemosiderin rim, single or sporadic seizures, short seizure duration, and small size of the lesion as the 4 main positive predictors of a more favorable postoperative seizure-free outcome. However, this result had limitations in the heterogeneity of inclusion criteria, surgical procedures and selection bias. Until now, no effective model had been established to forecast the postoperative condition of CCM surgical treatment. This was the first study to establish an effective predictive model to help clinical doctors to determine the best time for treatment and predict the prognosis in CCM patients to a certain extent.

The main finding of our present study was that preoperative seizure frequency was a prognostic factor for postoperative seizure outcomes after surgical resection of supratentorial CCMs. With fewer preoperative seizure times, especially <2, patients could achieve better postoperative seizure control status. This outcome was supported by Ferroli et al's^[11] study, which consistently reported that patients with a single preoperative seizure showed better postoperative seizure outcomes compared to patients with the diagnosis of chronic seizure. Since higher preoperative seizure frequency at some level was correlated with longer seizure duration prior to surgery, and our univariate analysis showed that the preoperative seizure duration was a prognostic factor (although not significant in our logistic regression analysis). Therefore, secondary epileptogenicity caused by longer seizure duration could be an important explanation for our present results. One hypothesis that had been proposed was that primary epileptogenic lesions, if untreated for an extended period, might create pathological changes in adjacent or remote sites, and aberrant electrical

discharges from secondary seizure sites made the patient unlikely to be postoperative seizure-free if the patient only underwent surgical removal of the primary lesions.^[16] This finding was supported by Stavrou et al's study,^[8] which reported that patients with a short preoperative seizure history showed a significantly better seizure outcome. However, many neurosurgeons prefer to choose conservative medicine management on patients with a short duration of seizure, considering surgical resection might injure the surrounding normal brain tissue.^[17] Based on the above-mentioned evidence, earlier surgical resection might be needed in CCM patients to gain a better postoperative seizure outcome.

The effect of residual hemosiderin was another important covariate that we needed to be concerned about. Surgical removal of the CCM and the hemosiderin rim was regarded as the treatment of choice for patients with intractable seizures.^[4] One hypothesis that had gained broad acceptance was that the hemosiderin surrounding CCM induced pathologic changes of adjacent brain tissues, increased excitatory amino acid levels, and triggered the abnormal excitability of adjacent neurons.^[18] However, the value of completely resecting the hemosiderin rim remained inconsistent in previous studies. Some studies have demonstrated that an extensive resection of CCM along with the hemosiderin rim led to a better postoperative seizure control and improved quality of life compared to pure CCM lesionectomy.^[8,19,20] However, other studies indicated that approximately one-third of patients with preoperative intractable seizures were not seizure-free after surgery.^[17] In nonbleeding cases, CCMs could also induce seizures through their effects on the surrounding brain tissues. These effects might include ischemia, venous hypertension, gliosis, and cellular and humoral inflammatory responses.^[3] Our study showed that complete resection of the hemosiderin rim had no significant predictive value for postoperative seizures.

Furthermore, the multilesion was also a crucial factor worth mentioning. According to our data, the postoperative refractory seizure was not related to multiple lesions (Fisher exact test, $P = 0.515$). And we found the EEG patterns of refractory patients had no significant difference with the EEG patterns of nonrefractory patients. However, in our database, only 3 patients had multiple lesions, so this result should be carefully interpreted. And more patients with multiple lesions should be enrolled to draw a more precise conclusion.

Seizure is a common clinical symptom of CCM patients and is directly relevant to the quality of patients' life, so dealing with seizure is a necessary and urgent task. Given the role of stereotactic radiosurgery in the management of CCMs remains controversial, currently surgery is the main approach to cope with refractory CCMs. However, with the development of the technology of radiosurgery, a predicted model for postoperative seizure outcomes after the radiosurgery of CCMs may come out in the future, thus will help us to determine the best treatment method for a specific patient.

There were several limitations in this retrospective study. First, this was a single-center retrospective study with limited patients. However, with a homogenous patient population with a histological diagnosis of supratentorial CCM, a clear definition of seizures by EEG, and a uniform surgical method by a neurosurgeon, the bias was minimized. And with an AUC of 0.833 (95% CI 0.709–0.957, $P = 0.002$), our predictive model was efficient at predicting postoperative seizure outcomes, so based on our current data, it was appropriate to draw that the preoperative seizure frequency was a prognostic factor for

postoperative seizure outcomes after the surgical resection of CCMs. In addition, we would take advantage of more covariates in our future studies to explore a more powerful predictive model. Second, through our model, we could determine the postoperative seizure outcome; however, our result was semiquantitative as we divided seizure frequency into only 4 categories, including "once," "2 to 5 times," "6 to 10 times," and "more than 10 times," which might lead to a loss of detailed evidence on the association between the preoperative seizure frequency and postoperative seizure outcomes. Third, since supratentorial CCMs tend to cause seizures, we only considered supratentorial CCMs as our study objects. We might also lack data in some brain areas. For example, we found that all the patients with CCMs in basal ganglia (5 patients) did not have seizures before surgery, so we just excluded these cases from our study. In order to draw a more convinced conclusion about the relationship between the location and the prognosis, a larger database with comprehensive location information should be used to test our result. Fourth, postoperative seizure outcomes were all based on the feedbacks of telephone interviews. This might add some recall biases in our study. All the patients tended not to do further EEG examinations, because there were only 9 patients in the Engel classes II to IV group, and most of them belonged to class II, which meant that they got rare seizures (e.g., twice a year) or worthwhile seizure deductions postoperatively.

5. Conclusions

Based on our data, the preoperative seizure frequency was a prognostic factor for postoperative seizure outcomes after the surgical resection of CCMs. With fewer preoperative seizures, especially <2 , CCM patients could achieve better seizure control status after surgery. Hence, to obtain a favorable prognosis for CCM patients with preoperative seizures, early intervention might be a better choice. Further larger prospective randomized controlled trials should be performed to confirm these findings.

References

- [1] Al-Holou WN, O'Lynnner TM, Pandey AS, et al. Natural history and imaging prevalence of cavernous malformations in children and young adults. *J Neurosurg Pediatr* 2012;9:198–205.
- [2] Vale FL, Vivas AC, Manwaring J, et al. Temporal lobe epilepsy and cavernous malformations: surgical strategies and long-term outcomes. *Acta Neurochir* 2015;157:1887–95.
- [3] Awad I, Jabbour P. Cerebral cavernous malformations and epilepsy. *Neurosurg Focus* 2006;21:e7.
- [4] Jin Y, Zhao C, Zhang S, et al. Seizure outcome after surgical resection of supratentorial cavernous malformations plus hemosiderin rim in patients with short duration of epilepsy. *Clin Neurol Neurosurg* 2014;119:59–63.
- [5] Chang EF, Gabriel RA, Potts MB, et al. Seizure characteristics and control after microsurgical resection of supratentorial cerebral cavernous malformations. *Neurosurgery* 2009;65:31–7. discussion 37–38.
- [6] Baumann CR, Schuknecht B, Lo Russo G, et al. Seizure outcome after resection of cavernous malformations is better when surrounding hemosiderin-stained brain also is removed. *Epilepsia* 2006;47:563–6.
- [7] Kim W, Stramotas S, Choy W, et al. Prognostic factors for post-operative seizure outcomes after cavernous malformation treatment. *J Clin Neurosci* 2011;18:877–80.
- [8] Stavrou I, Baumgartner C, Frischer JM, et al. Long-term seizure control after resection of supratentorial cavernomas: a retrospective single-center study in 53 patients. *Neurosurgery* 2008;63:888–96. discussion 897.
- [9] Cohen DS, Zubay GP, Goodman RR. Seizure outcome after lesionectomy for cavernous malformations. *J Neurosurg* 1995;83:237–42.
- [10] Yeon JY, Kim JS, Choi SJ, et al. Supratentorial cavernous angiomas presenting with seizures: surgical outcomes in 60 consecutive patients. *Seizure* 2009;18:14–20.

- [11] Ferroli P, Casazza M, Marras C, et al. Cerebral cavernomas and seizures: a retrospective study on 163 patients who underwent pure lesionectomy. *Neurol Sci* 2006;26:390–4.
- [12] Baumann CR, Acciarri N, Bertalanffy H, et al. Seizure outcome after resection of supratentorial cavernous malformations: a study of 168 patients. *Epilepsia* 2007;48:559–63.
- [13] Zevgaridis D, van Velthoven V, Ebeling U, et al. Seizure control following surgery in supratentorial cavernous malformations: a retrospective study in 77 patients. *Acta Neurochir* 1996;138:672–7.
- [14] Cappabianca P, Alfieri A, Maiuri F, et al. Supratentorial cavernous malformations and epilepsy: seizure outcome after lesionectomy on a series of 35 patients. *Clin Neurol Neurosurg* 1997;99:179–83.
- [15] Wieser HG, Blume WT, Fish D, et al. ILAE Commission Report. Proposal for a new classification of outcome with respect to epileptic seizures following epilepsy surgery. *Epilepsia* 2001;42:282–6.
- [16] D'Angelo VA, De Bonis C, Amoroso R, et al. Supratentorial cerebral cavernous malformations: clinical, surgical, and genetic involvement. *Neurosurg Focus* 2006;21:e9.
- [17] Englot DJ, Han SJ, Lawton MT, et al. Predictors of seizure freedom in the surgical treatment of supratentorial cavernous malformations. *J Neurosurg* 2011;115:1169–74.
- [18] Williamson A, Patrylo PR, Lee S, et al. Physiology of human cortical neurons adjacent to cavernous malformations and tumors. *Epilepsia* 2003;44:1413–9.
- [19] Bernotas G, Rastenyte D, Deltuva V, et al. Cavernous angiomas: an uncontrolled clinical study of 87 surgically treated patients. *Medicina (Kaunas)* 2009;45:21–8.
- [20] Ruan D, Yu XB, Shrestha S, et al. The role of hemosiderin excision in seizure outcome in cerebral cavernous malformation surgery: a systematic review and meta-analysis. *PLoS ONE* 2015;10:e0136619.