



## Revista Brasileira de Hematologia e Hemoterapia Brazilian Journal of Hematology and Hemotherapy

www.rbhh.org



### Letter to the Editor

## Diagnostic approach to hemolytic anemias in the adult



Dear Sir,

Even though hemolytic anemias (HAs) are not very common, their diagnosis remains a big challenge for hematologists and clinicians. We hope that this summary will contribute with valuable information about a subject that has been little described in the medical literature, and will help to clarify the diagnostic approach to guide specific treatment depending on the causative condition.

It is known that HAs are a group of disorders characterized by a premature red blood cell (RBC) destruction (less than 120 days),<sup>1,2</sup> that exceeds the compensatory capacity of the bone marrow to increase RBC production and keep up with the loss.<sup>1-3</sup> Usually HAs are diagnosed through laboratory tests, however, the patient's history and physical examination are crucial as they provide important information about the presence of hemolysis and its probable etiology.<sup>3,4</sup> For example, if in addition to the classic symptoms of anemia (paleness, fatigue, dyspnea, palpitations), findings such as familial or personal history of jaundice, exposure to toxics, leg ulcers, lymphadenopathies, hepatomegaly or splenomegaly may help to elucidate the cause of the anemia.<sup>1,3,4</sup>

Regarding the etiology, HAs can be classified as inherited or acquired and when considering the site of hemolysis, RBCs can be destroyed in the circulation (intravascular) or within macrophages in the spleen or liver (extravascular). From the clinical perspective, HAs can be acute or chronic and according to the location of the abnormality responsible for the hemolysis, they may be due to intrinsic (intracorpuscular) or extrinsic (extracorpuscular) defects.<sup>2-4</sup> It is important to mention that most intrinsic defects are inherited, and most extrinsic ones are acquired,<sup>2</sup> however, there are some exceptions to this rule. For example, paroxysmal nocturnal hemoglobinuria (PNH) is an acquired HA produced by an intrinsic defect<sup>4</sup> and glucose-6-phosphate dehydrogenase (G6PD) deficiency is an inherited intrinsic defect that is triggered by an external factor.<sup>2</sup>

Although there are different ways of approaching the diagnosis of HAs, it is first necessary to identify the patient with HA and collect data on hemolysis. The destruction of RBCs in HAs is characterized by an increased breakdown of hemoglobin

which results in unconjugated hyperbilirubinemia clinically evidenced by jaundice, increased lactate dehydrogenase (cellular destruction), and reticulocytosis, which is a normal compensatory response of the bone marrow to the RBC loss. Additionally, decreased levels of plasma haptoglobin, a marker of RBC destruction, are evidenced<sup>1-3</sup> regardless the site of hemolysis (intravascular or extravascular).<sup>5</sup> In cases of severe acute intravascular HAs, the haptoglobin-binding capacity reaches its saturation point, and free hemoglobin is filtered by the glomerulus and hemoglobinuria is seen.<sup>3,6</sup> Also, hemosiderinuria may be present in long-term intravascular hemolysis.<sup>3,6</sup> On the other hand, if the hemolysis is extravascular, urobilinogen may appear in the urine or feces.<sup>6</sup>

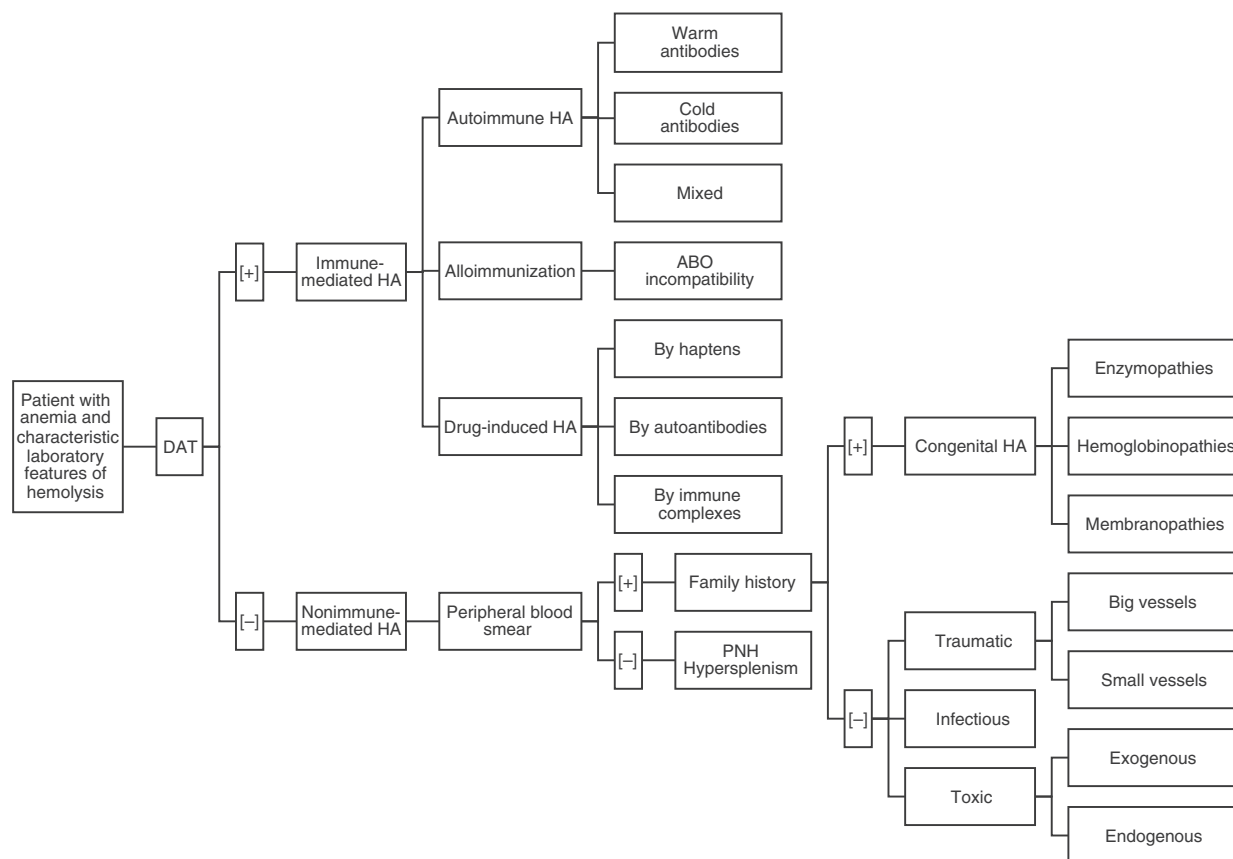
Once we have a presumptive diagnosis, a multi-step procedure is required,<sup>4</sup> beginning with a direct antiglobulin test (DAT) or direct Coombs test.<sup>6,7</sup> This is the exam of choice because it will classify the hemolysis into an immune or non-immune etiology.<sup>6,7</sup> Although DAT helps to categorize HAs into two groups, results must be interpreted in the context of the clinical conditions as some conditions may be incorrectly classified.<sup>7,8</sup> This is why the DAT should be followed by a peripheral blood smear (PBS) and an investigation of the family history.<sup>6</sup> A simple approach to identify and classify HAs based on the works of González Mesones et al.<sup>6</sup> and others<sup>3,4,8</sup> is presented in [Figure 1](#).

In cases of immune HAs (DAT positive), the diagnostic possibilities are limited to the presence of autoantibodies (warm, cold or mixed), alloimmunization (as in transfusion incompatibility), or drug-related (hemolysis by haptens, autoantibodies or immune complexes). Reviewing the PBS is a critical step in the evaluation of non-immune HAs (DAT negative). Certain morphological abnormalities of RBCs correlate with different pathologies. For example, schistocytes are related to thrombotic microangiopathies or cardiac prosthetic valves, spherocytes with hereditary spherocytosis, sickle cells with sickle cell disease, elliptocytes with hereditary elliptocytosis, echinocytes with pyruvate kinase deficiency, Heinz bodies with G6PD deficiency, and basophilic stipplings with lead poisoning, thalassemia, and Wilson's disease, among others.<sup>4</sup> Thus, if the PBS is abnormal, the family history may identify

**Table 1 – The most common causes of hemolysis classified by type.**

Defect	Etiology	Abnormality	Examples	Site of hemolysis		
Intrinsic	Inherited	Enzymopathies	G6PD deficiency, pyruvate kinase deficiency	EV		
		Hemoglobinopathies	Thalassemia, sickle cell anemia			
		Membranopathies	Hereditary spherocytosis, elliptocytosis			
Extrinsic	Acquired		Nocturnal paroxysmal hemoglobinuria	IV		
		Immune-mediated	Autoimmune hemolytic anemia	Warm antibodies [IgG] • Idiopathic, lymphoproliferative (CLL, NHL), SLE, non-lymphoid malignancies	EV	
				Cold antibodies [IgG] • Idiopathic, <i>M. pneumoniae</i> , mononucleosis, lymphoproliferative (Waldenstroms), paroxysmal cold hemoglobinuria	IV (also EV)	
				Mixed [warm and cold antibodies] • Idiopathic, SLE, lymphoma	IV or EV	
			Alloimmunization	ABO incompatibility	IV	
		Drug-induced hemolytic anemia		By haptens • Penicillin, cephalosporin	EV	
				By autoantibodies • Alpha-methyl dopa, L-dopa, ibuprofen, diclofenac	EV	
				By immune complexes • Quinidine, hydrochlorothiazide, sulfonamides, tetracycline	IV	
		Traumatic		Big Vessels	Prostheses • Valves, TIPS	IV
				Small Vessels	Microangiopathic hemolytic anemia • TTP, HUS, HELLP, DIC	IV
		Infectious			Bartonella, Babesia, Plasmodium	EV
					Clostridium	IV
		Toxic		Exogenous	Arsenic, lead or copper poisoning Snake or spider bite	EV
Endogenous	Wilson disease			IV		
		Entrapment	Hypersplenism	EV		

G6PD: glucose-6-phosphate dehydrogenase; CLL: chronic lymphocytic leukemia; NHL: non-Hodgkin lymphoma; SLE: systemic lupus erythematosus; TIPS: transjugular intrahepatic portosystemic shunt; TTP: thrombotic thrombocytopenic purpura; HUS: hemolytic uremic syndrome; HELLP: hemolysis, elevated liver enzyme levels, and low platelet levels; DIC: disseminated intravascular coagulation; EV: extravascular; IV: intravascular.



**Figure 1 – A simple approach to identify and classify hemolytic anemias. DAT: direct antiglobulin test; HA: hemolytic anemia; PNH: paroxysmal nocturnal hemoglobinuria.**

a congenital HA including disorders of enzymes (G6PD deficiency, pyruvate kinase deficiency) hemoglobin (thalassemia, sickle cell anemia) or of the membrane (hereditary spherocytosis, elliptocytosis). Likewise, traumatic hemolysis (of big or small vessels), infectious (*Bartonella*, *Babesia*, *Plasmodium*) or toxic (exogenous or endogenous) pathologies should be taken into account if there is an abnormal PBS in the absence of family history. In contrast, if the PBS is normal, hypersplenism or PNH should be considered. A detailed list of the most common causes of hemolysis classified by type is presented in Table 1.

### Conflicts of interest

The authors declare no conflicts of interest.

### REFERENCES

1. Evans ER. Diagnosis of the hemolytic anemias. *Calif Med.* 1951;75(4):271-5.
2. Ucar K. Clinical presentation and management of hemolytic anemias. *Oncology (Williston Park).* 2002;16 9 (Suppl 10):163-70.
3. Dhaliwal G, Cornett PA, Tierney LM Jr. Hemolytic anemia. *Am Fam Physician.* 2004;69(11):2599-606.
4. Guillaud C, Loustau V, Michel M. Hemolytic anemia in adults: main causes and diagnostic procedures. *Expert Rev Hematol.* 2012;5(2):229-41.

5. Shih AW, McFarlane A, Verhovsek M. Haptoglobin testing in hemolysis: measurement and interpretation. *Am J Hematol.* 2014;89(4):443-7.
6. González Mesones B, González de Villambrosia A, Batlle A, Insunza A. Protocolo diagnóstico de las anemias hemolíticas. *Medicine.* 2012;11(20):1246-9.
7. Zantek ND, Koepsell SA, Tharp DR Jr, Cohn CS. The direct antiglobulin test: a critical step in the evaluation of hemolysis. *Am J Hematol.* 2012;87(7):707-9.
8. Bass GF, Tuscano ET, Tuscano JM. Diagnosis and classification of autoimmune hemolytic anemia. *Autoimmun Rev.* 2014;13(4-5):560-4.

Eloy F. Ruiz\*, Miguel A. Cervantes

Universidad Peruana Cayetano Heredia, Lima, Peru

\*Corresponding author at: Av. El Polo 740, Edificio C, Oficina 313, Santiago de Surco, Lima, Peru.  
E-mail address: [eloy.ruiz.m@upch.pe](mailto:eloy.ruiz.m@upch.pe) (E.F. Ruiz).

Received 26 June 2015

Accepted 19 August 2015

Available online 9 October 2015

<http://dx.doi.org/10.1016/j.bjhh.2015.08.008>

1516-8484/© 2015 Associação Brasileira de Hematologia, Hemoterapia e Terapia Celular. Published by Elsevier Editora Ltda. All rights reserved.