

# Ultrasound-guided dorsal penile nerve block is a safe block in hypospadias surgery

## A retrospective clinical study

Doğakan Yiğit<sup>a,\*</sup>, Volkan Özen<sup>b</sup>, Aliye Kandıncı<sup>a</sup>, Ali İhsan Dokucu<sup>a</sup>

### Abstract

Caudal and dorsal penile nerve blocks are commonly used regional anesthesia methods in hypospadias surgery. Some studies have reported that regional anesthesia methods are risk factor for the development of postoperative complications following hypospadias surgery. The aim of the current study is to evaluate the relationship between postoperative complications and regional anesthesia methods used in distal hypospadias surgery.

Forty-nine distal hypospadias patients were included. Patients had either received caudal or ultrasound (US)-guided dorsal penile nerve block. The age, type of hypospadias, regional anesthesia method, operation time, and postoperative complications were recorded. Fisher exact test and Mann-Whitney *U* tests were used to compare the data.

Caudal epidural block was used in 25 (51%) patients and US-guided dorsal penile nerve block in 24 (49%) patients. There was no statistically significant difference between the groups regarding the types of hypospadias, operation time, and age. Fistula developed in 4 (16%) patients in the caudal block group and in none of the patients in the dorsal penile nerve block group. Fistula rates were statistically significantly different between the groups ( $P = .030$ ).

Conflicting data are found in the literature on the long-term postoperative complications of the regional anesthesia techniques used in hypospadias surgery. In our study, all patients with urethrocutaneous fistula were in the caudal block group. We believe that our study will contribute to the literature as it is the only study comparing caudal block with US-guided dorsal penile nerve block using in-plane technique in terms of postoperative complications in hypospadias surgery.

**Abbreviations:** CB = caudal block, DPNB = dorsal penile nerve block, TIPU = tubularized incised plate urethraplasty.

**Keywords:** anesthesia, caudal, dorsal penile nerve, hypospadias, fistula

## 1. Introduction

Hypospadias is the most common penile anomaly in children with an incidence of approximately 1 in 250.<sup>[1]</sup> The condition is classified as distal, mid-penile, or proximal according to the localization of the urethral meatus, and 70% to 85% of the patients have the distal type.<sup>[2]</sup> Several different techniques, which are variations of each other, are used for distal hypospadias surgery. One of the most commonly used surgical methods is the tubularized incised plate urethraplasty (TIPU) technique, as it provides satisfactory results.<sup>[3]</sup> Although some studies report that the complications following hypospadias surgery are related to patient age and chordee presence, others have reported that the regional anesthesia method used is also important.<sup>[4]</sup> Regional anesthesia methods are commonly used for hypospadias surgery in order to effectively control postoperative pain. It is possible to find studies in the literature which report that both caudal

block (CB) and dorsal penile nerve block (DPNB) are associated with higher complication rates following hypospadias surgery.<sup>[4]</sup>

CB is one of the regional anesthesia methods that have long been used for this purpose. However, various articles have reported its negative influence on the postoperative complications of hypospadias surgery in addition to the potential side effects related to the central nervous system.<sup>[5,6]</sup> This has resulted in the more common use of alternative regional anesthesia methods such as the pudendal nerve block and DPNB for patients undergoing penile surgery.<sup>[7]</sup>

The DPNB was first described as a blind technique in patients undergoing circumcision in 1972.<sup>[8]</sup> Sandeman and Dilley<sup>[9]</sup> have then reported DPNB use with ultrasound (US) using an out-of-plane technique for the first time. Suleman et al have been the first to define DPNB accompanied by US with the in-plane technique. The technique has been reported to enable imaging of the neurovascular structures with accompanying

The datasets generated during and/or analyzed during the current study are not publicly available, but are available from the corresponding author on reasonable request.

Ethical approval is obtained from Prof. Dr Cemil Taşçıoğlu City Hospital Ethics Committee (approval number is 2021/360).

The authors have no funding and conflict of interest to disclose.

<sup>a</sup> Department of Pediatric Surgery and Pediatric Urology, Medical Doctor, Health Sciences University, Prof. Dr. Cemil Taşçıoğlu City Hospital, Istanbul, Turkey,

<sup>b</sup> Department of Anesthesiology, Health Sciences University, Prof. Dr. Cemil Taşçıoğlu City Hospital, Istanbul, Turkey.

\*Correspondence: Doğakan Yiğit, Department of Pediatric Surgery and Pediatric Urology, Prof. Dr. Cemil Taşçıoğlu City Hospital, Darülaceze Caddesi, Kaptanpaşa Mahallesi, Şişli, İstanbul 34100, Turkey (e-mail: dogakanyigit@gmail.com).

Copyright © 2022 the Author(s). Published by Wolters Kluwer Health, Inc. This is an open-access article distributed under the terms of the Creative Commons Attribution-Non Commercial License 4.0 (CCBY-NC), where it is permissible to download, share, remix, transform, and buildup the work provided it is properly cited. The work cannot be used commercially without permission from the journal.

How to cite this article: Yiğit D, Özen V, Kandıncı A, Dokucu AI. Ultrasound-guided dorsal penile nerve block is a safe block in hypospadias surgery: a retrospective clinical study. *Medicine* 2022;101:26(e29700).

Received: 16 March 2022 / Received in final form: 27 April 2022 / Accepted: 13 May 2022

<http://dx.doi.org/10.1097/MD.0000000000029700>

US and to create a longer-lasting local anesthesia block with shorter onset.<sup>[10]</sup> However, there are also studies reporting a possible relationship between DPNB and the postoperative complications following hypospadias surgery, as reported for CB.<sup>[4,11]</sup>

The aim of the current study is to evaluate the relationship between CB and US-guided DPNB with in-plane technique used for postoperative analgesia in distal hypospadias surgery, with postoperative surgical complications. Our hypothesis is that patients who underwent US-guided dorsal penile block with in-plane technique had fewer surgical complications following hypospadias surgery compared to CB.

## 2. Patients and methods

A total of 49 distal hypospadias patients who had undergone distal hypospadias surgery at Prof Dr Cemil Taşçıoğlu City Hospital's Pediatric Surgery Department between 2017 and 2020 and who had received a caudal or US-guided DPNB were retrospectively reviewed. The age, type of hypospadias, regional anesthesia method used, and postoperative complications were recorded. All patients underwent surgery with the TIPU method by the same surgeon. The general and regional anesthesia procedures were performed by the same anesthesiologist.

### 2.1. Surgical technique

The standard TIPU technique was used for hypospadias surgery in all patients. Following placement of a traction suture to the glans, the circumcision incision was merged into a U shape ventrally underneath the urethral meatus and the penis degloved. A deep midline incision was made and the urethral plate was tubularized as a double layer over a no. 6 feeding catheter using 6/0 polydioxanone sutures. After urethroplasty completion, the neourethra was covered with a single-layer dartos flap and fixed with 6/0 polydioxanone sutures. All patients were prescribed oral antibiotics and oxybutynin. The urethral stent was removed on the postoperative 7th day in all patients.

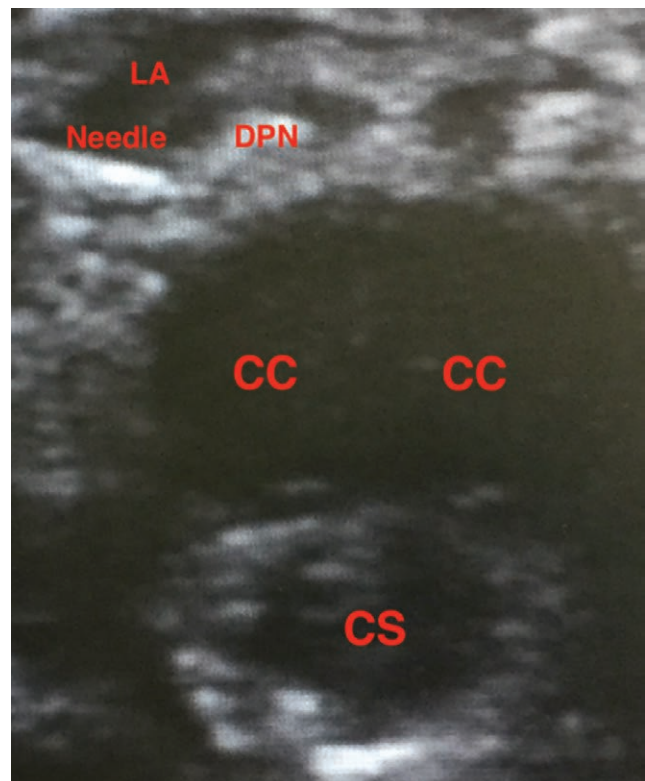
### 2.2. Block procedures

#### 2.2.1. Caudal epidural block.

General anesthesia induction was followed by placing the patient into the left lateral decubitus position. Povidone iodine was used to sterilize the skin. The sacral hiatus was found by palpating the sacral cornu and a 22-G needle was placed through it. After passing through the sacrococcygeal membrane by using the loss of resistance method, the caudal epidural space was entered. Negative aspiration was used to make sure there was no blood or cerebrospinal fluid present and 0.25% bupivacaine was administered at a dose of 0.2 ml/kg. Once the procedure was completed, the patient was placed into the supine position.

#### 2.2.2. US-guided DPNB with in-plane technique.

General anesthesia induction was followed by skin sterilization using 70% alcohol in 2% chlorhexidine. The 5-10 MHz linear probe was placed at the penis root, making it possible to observe the corpus cavernosum, corpus spongiosum, dorsal artery and vein, and the deep penile fascia (Buck's fascia) on the transverse plane with gentle penile traction. The in-plane technique was then used to insert a 50-mm block needle (Stimuplex® Ultra 360®, 22-G; B. Braun, Melsungen, Germany) toward the dorsal penile section from the lateral part of the penis root. The needle was then advanced from the hyperechoic superficial penile fascia (Dartos fascia) and the superficial sheath was passed. After advancing the needle into Buck's fascia, the needle was placed lateral to the dorsal artery, at a position between Buck's



**Figure 1.** Real time image of ultrasound guided dorsal penile nerve block with in plane technique. CC = corpus cavernosum, CS = corpus spongiosum, DPN = dorsal penile nerve, LA = local anesthetic.

fascia and tunica albuginea. Negative aspiration was performed. US was then used to observe the distribution of the anesthetic while half of the total 0.25% bupivacaine dose (0.2 mL/kg) was administered (Fig. 1). Afterward, the same procedure was also performed on the other side of the penis.

### 2.3. Statistical method

The IBM SPSS Version 26.0 Statistical Package Software (IBM Corp. Released 2019. IBM SPSS Statistics for Windows, Version 26.0, IBM Corp, Armonk, NY) was used to analyze the study data. Continuous variables were presented as mean  $\pm$  standard deviation (median, minimum–maximum) and categorical variables as numbers and percentages. The urethral meatus location, complication rate, and fistula rate values in the 2 groups were compared with Fisher exact test. Mann–Whitney *U* test was used to compare the operation times of the groups and the ages of patients with and without fistula. The statistical significance level used was “ $P < .05$ .”

## 3. Results

The study included 49 patients operated for distal hypospadias with the TIPU technique. Caudal epidural block was used in 25 (51%) patients and US-guided DPNB with in-plane technique in 24 (49%) patients. The mean age was  $2.5 \pm 1.2$  (1–5) years in CB group and  $2.5 \pm 1.3$  (1–5) years in DPNB group with no statistically significant difference between the groups for age distribution ( $P = .967$ ). The mean follow-up duration was 7.9 (3–14) months. The urethral meatus location was coronal in 4 patients in the CB group and 3 patients in the DPNB group, and subcoronal in all the other patients. There was no statistically significant difference between the groups regarding the types of hypospadias ( $P = .999$ ). A penile chordee over 30 degrees was not present in any patient and all chordees were found to have

been corrected following degloving when a chordee test was performed with saline solution. Plication was not performed on any patient.

Postoperative complications developed in a total of 6 (12%) patients in this study, consisting of 5 (20%) patients in the CB group and 1 (2%) patient in the DPNB group. Meatal stenosis developed in 1 patient in each group, for a total of 2 (4%) patients, and neither patient had a fistula. Fistula developed in 4 (16%) patients in the CB group and in none of the patients in the DPNB group. Individual evaluation of complications revealed statistically significant differences between the groups for fistula ( $P = .03$ ). No wound infection, glans dehiscence, unintended removal of the feeding tube before the planned date, or urinary tract infection has occurred in any patient. Information about complication rates and type of hypospadias are listed in Table 1.

Operation times were also compared between the groups. Mean operation time in CB group was  $98 \pm 8.9$  minutes (90–130) and in DPNB group was  $102.1 \pm 11.8$  minutes (90–120). There was no statistically significant difference between the groups in terms of operation times ( $P = .479$ ).

Patients with fistula and without fistula were also compared in terms of operation times and ages. Mean age and operation time of patients with fistula was  $2.3 \pm 1.3$  ages and  $100 \pm 7.1$  minutes, and mean age and operation time of patients without fistula was  $2.6 \pm 1.3$  and  $98.6 \pm 9.4$  minutes, respectively. Neither age nor operation time was statistically significantly different between patients with and without fistula ( $P = .646$ ,  $P = .617$ ). Information about ages and operation times of patients with and without fistula are listed in Table 2.

#### 4. Discussion

Regional anesthesia methods are commonly used for hypospadias surgery in order to decrease the exposure to the drugs and postoperative pain. Although various studies on the postoperative pain status, analgesic requirement, and the block-related complications following DPNB are present in the literature, but as far as we know, there is no study evaluating the postoperative complications of patients who had either US-guided DPNB with in-plane technique or CB for hypospadias surgery.<sup>[10,12,13]</sup>

**Table 1**  
Hypospadias type and postoperative complications.

	CB group (n = 25)	DPNB group (n = 24)	P value*
Meatus location			
Coronal	4 (16%)	3 (12.5%)	.999
Subcoronal	21 (84%)	21 (87.5%)	
Complications			
Stenosis	1 (4%)	1 (4.1%)	.999
Fistula	4 (16%)	0	.030

CB = caudal block, DPNB = dorsal penile nerve block.

\*Fisher exact test.

**Table 2**  
Age and operation times of patients with and without fistula.

	Mean $\pm$ SD		P value*
	Fistula (n = 4)	Without fistula (n = 21)	
Age (yr)	$2.3 \pm 1.3$	$2.6 \pm 1.3$	.646
Operation time (min)	$100.0 \pm 7.1$	$98.6 \pm 9.4$	.617

SD = standard deviation.

\*Mann-Whitney *U* test.

CB is a common neuroaxial block technique that is frequently used for surgery on the lower abdominal region, inguinal region, and urogenital region in children. CBs have also been in use for hypospadias surgery for a long time.<sup>[7]</sup> In our department, CB is widely used for penile and inguinal surgeries.

The DPNB was described in 1970s and is frequently administered in a blind manner with the landmark technique. It is possible to identify the dorsal nerve and demonstrate the infra-pubic region, penile structures and vessels, and Buck's fascia when US-guided DPNB is used with in-plane technique. Such a block protects the penile structures during administration and it is possible to advance the needle into Buck's fascia and demonstrate the distribution of the anesthetic agent in real time.<sup>[14]</sup> Türkyılmaz et al have shown that US-guided DPNB was more successful, decreased the local anesthetic toxicity risk as less local anesthetic is used, and was safer to use as the vascular structures and urethra could be protected.<sup>[13]</sup> US, with its several benefits, is also used for other various interventions.<sup>[15,16]</sup> In our department, landmark technique had been used for DPNB before 2017, but since 2017, penile block is being performed mostly with US guidance.

The 2 most common complications following hypospadias surgery are urethrocutaneous fistula and meatal stenosis.<sup>[17]</sup> Fistula development has been reported to be generally dependent on the hypospadias type, the surgical technique, child's age, the surgeon's experience, the postoperative edema, local infection, and local ischemia.<sup>[5]</sup> In a cross-sectional study by Mohammed et al, it was reported that the proximal type of hypospadias has been shown to have 29% higher chance of developing long-term complications compared with middle and distal types.<sup>[18]</sup> Another study revealed that the overall postsurgery complication rate involving fistulas or strictures was 13%, but higher (33%) for proximal cases and boys with proximal or middle hypospadias were at increased risk of complications.<sup>[19]</sup>

The urethrocutaneous fistula complication of hypospadias surgery can have an especially negative effect on both the child and the family.<sup>[20]</sup>

Kundra et al<sup>[5]</sup> have demonstrated an increase in the intraoperative penis volume in patients who received a CB and reported that this increased volume could result with fistula by affecting the safety of the sutures on the urethroplasty line. Kundra et al have also compared patients who have received caudal epidural block or penile block for hypospadias surgery in the same study and found that all the patients with fistula development had received CB, as in our study. All these patients had been specified as undergoing distal hypospadias surgery in the study by Kundra et al. but the actual surgical method used had not been provided. In our study, all patients were operated with TIPU technique.

Kim et al<sup>[21]</sup> evaluated hypospadias patients in his study and found that postoperative complication rate was 24.5% in the CB group and 15.1% in the group that did not receive CB. This difference in the surgical complication rates between the groups that received and did not receive CB was reported to be statistically significant. All the hypospadias surgeries were performed by the same surgeon in the current study, similar to the study by Kim et al, but Kim et al had also included the mid-penile and proximal hypospadias types in their study. The mid-penile and proximal hypospadias types were found to be independent risk factors, and CB administration increased the risk of postoperative surgical complication development 2.1 times. Our study has a more homogenous study group that only included patients with distal hypospadias.

Taicher et al<sup>[22]</sup> have compared caudal epidural block and DPNB in their study where all hypospadias types were operated. CBs were performed by the anesthetist and the DPNB by the anesthetist or the surgeon. The analysis revealed statistically significant relationship between caudal epidural block and

**Table 3**  
**Hypospadias type, regional anesthesia methods, and complication rates in our and previous studies.**

	Hypospadias type N (%)			Regional anesthesia method N (%)	
	Distal	Mid-penile	Proximal	Caudal	USG-PNB*
Yiğit et al	49	–	–	25	24
Complications N (%)	6	–	–	-51%	-49%
P = .03†	-12.20%			5	1
				-20%	-2%
	Hypospadias type N (%)			Regional anesthesia method N (%)	
	Distal	Mid-penile	Proximal	Caudal	No caudal
Kim et al <sup>[21]</sup>	143 (41.8%)	159 (46.5%)	40 (11.7%)	216	126
Complications N (%)	14	28	11	-63%	-37%
P = .04†	-6.50%	-13%	-5.10%	53	19
				-24.50%	-15.10%
	Hypospadias type N (%)			Regional anesthesia method N (%)	
	Distal	Mid-penile	Proximal	Caudal	PNB‡
Ngoo et al <sup>[4]</sup>	188	–	–	74	114
Complications N (%)	31	–	–	-39.40%	-60.60%
P = .04†	-16.40%			7	24
				-9.50%	-21.10%
	Hypospadias type, N (%)			Regional anesthesia method, N (%)	
	Distal	Mid-penile	Proximal	Caudal	PNB‡
Taicher et al <sup>[22]</sup>	326	24	45	230	165
Complications N (%)	-82.50%	-6%	-11.50%	-58.20%	-41.80%
P < .001†	9	–	13	21	1
	-2%		-28.80%	-9%	-0.60%
	Hypospadias type, N (%)			Regional anesthesia method, N (%)	
	Distal	Mid-penile	Proximal	Caudal	PNB‡
Saavedra-Belaunde et al <sup>[6]</sup>	192	–	–	91	101
				-48%	-52%

PNB = penile nerve block. USG = USG-PNB = ultrasound guided penile nerve block.

\*Ultrasound-guided dorsal penile nerve block with in-plane technique.

†P value for relationship between complications and regional anesthesia method.

‡Penile nerve block.

postoperative complications. They also found that proximal hypospadias, prolonged surgery, and surgical experience were associated with complications.

There are also studies reporting the opposite of the above. Ngoo et al<sup>[4]</sup> have reported that caudal epidural block prevents ischemia by increasing blood flow with arterial vasodilation and has beneficial effect on healing. The distal hypospadias repairs in this study were performed with one of the TIPU, meatal advancement and glanduloplasty, or onlay flap methods. The complication rate among all patients was 16.5% and there was no relationship between the surgical technique and postoperative complications. The analyses conducted in the same study revealed that the only parameter with a significant relationship with the complication rates was DPNB. No relationship was found between the presence of complications and the surgeon's experience, the patient's age, or the presence of chordee. Ngoo et al have reported that DPNB can cause fistula development due to the trauma created by the needle on the penile tissues and the resultant compromised healing. However, it must be noted that their study was performed with the classical blind technique without the aid of US for the DPNB, in contrast to our study. Table 3 shows the hypospadias type, regional anesthesia method, and complication rates of our study and other similar studies mentioned above.

In our study, all surgeries were performed by the same surgeon and all blocks were performed by the same anesthetist. There was no statistical difference in terms of age and operation time, between the groups. Our study revealed that, as mentioned in the similar studies, CB can be associated with fistula formation following hypospadias surgery. In our study, postoperative fistula was only seen in CB group and statistically significant difference was found between the 2 groups in terms of postoperative fistula formation. We believe that with the ability to evaluate the anatomy of the whole penis in the sagittal plane and real-time visualization of the whole needle and the spread of the anesthetic drug during block administration, without any harm to the penile structures, US-guided DPNB with in-plane technique is a tissue friendly regional anesthesia method and that can be used in hypospadias surgery.

There are studies in the literature which have evaluated both block types for postoperative pain and analgesic use. Our recent study has compared CB with US-guided DPNB using in-plane technique and found that the US-guided DPNB provided good postoperative analgesia in both hypospadias surgery and circumcision and also patients, who had received a DPNB, required lower amount of analgesics.<sup>[14]</sup>



We believe that our study will contribute to the literature as it is the only study comparing CB with US-guided DPNB using in-plane technique in order to compare the long-term postoperative complications in hypospadias surgery.

However, our study also has some limitations. One of these is that the number of patients was low as a result of the decreased number of outpatient appointments and surgeries during the coronavirus disease 2019 pandemic. In addition, the study design was retrospective and future long-term prospective randomized controlled studies are needed.

## 5. Conclusion

According to the results of our retrospective study, which was conducted with homogeneous patient groups who had only distal type hypospadias, with a single anesthesiologist, single surgeon, and single surgical technique, patients who underwent US-guided dorsal penile block had better outcomes than those who underwent CB in terms of postoperative complications. US-guided dorsal penile block with in-plane technique may be preferred to CB in patients who undergo distal hypospadias surgery.

## Author contributions

Doğakan Yiğit: Constructing the hypothesis, planning methodology, analysing results, writing the article.

Volkan Özen: Data collection, literature review.

Aliye Kandırcı: Data collection, analysis of the results.

Ali İhsan Dokucu: Supervision and critical review.

## References

- [1] Elliot CS, Halpern MS, Paik J, et al. Epidemiologic trends in penile anomalies and hypospadias in the state of California, 1985-2006. *J Pediatr Urol.* 2011;7:294-8.
- [2] Long CJ, Zaontz MR, Canning DA. Hypospadias. In: Partin AW, Dmochowski RR, Kavoussi LR, eds. *Campbell-Wallsh-Wein Urology.* 12 ed. Philadelphia, PA: Elsevier. 2021:905-948.
- [3] Marte A, Pintozzi L. Tubularized proximally-incised plate in distal/mid-shaft hypospadias repair. *Pediatr Med Chir.* 2017;39:151.
- [4] Ngoo A, Borzi P, McBride CA, et al. Penile nerve block predicts higher revision surgery rate following distal hypospadias repair when compared with caudal epidural block: a consecutive cohort study. *J Pediatr Urol.* 2020;16:439.e1-6.
- [5] Kundra P, Yuvaraj K, Agraval K, et al. Surgical outcome in children undergoing hypospadias repair under caudal epidural vs penile block. *Paediatr Anaesth.* 2012;22:707-12.
- [6] Saavedra-Belaunde JA, Soto-Aviles O, Jorge J, et al. Can regional anesthesia have an effect on surgical outcomes in patients undergoing distal hypospadias surgery? *J Pediatr Urol.* 2017;13:45.e1-4.
- [7] Aksu C, Akay MA, Şen MC, et al. Ultrasound-guided dorsal penile nerve block vs neurostimulator-guided pudendal nerve block in children undergoing hypospadias surgery: a prospective, randomized, double-blinded trial. *Paediatr Anaesth.* 2019;29:1046-52.
- [8] Bateman DV. An alternative block for the relief of pain of circumcision. *Anaesthesia.* 1975;30:101-2.
- [9] Sandeman DJ, Dilley AV. Ultrasound guided dorsal penile nerve block in children. *Anaesth Intensive Care.* 2007;35:266-9.
- [10] Suleman MI, Akbar Ali AN, Kanarek V, et al. Ultrasound guided in-plane penile nerve block for circumcision: a new, modified technique suggests lower anesthetic volume and narcotic use. *Middle East J Anaesthesiol.* 2016;23:647-53.
- [11] Tanesco PP, Randhawa H, Chua ME, et al. Postoperative complications of hypospadias repair in patients receiving caudal block vs. non-caudal anesthesia: a meta-analysis. *Can Urol Assoc J.* 2018;13:E249-57.
- [12] O'Sullivan MJ, Mislovic B, Alexander E. Dorsal penile nerve block for male pediatric circumcision-randomized comparison of ultrasound-guided vs anatomical landmark technique. *Paediatr Anaesth.* 2011;21:1214-8.
- [13] Türkyılmaz N, Gürkan Y, Cesur S. Pediatrik hipospadias cerrahisinde ultrason rehberliğinde penil blok uygulaması. *Agri.* 2018;30:97-8.
- [14] Özen V, Yiğit D. A comparison of the postoperative analgesic effectiveness of low dose caudal epidural block and US-guided dorsal penile nerve block with in-plane technique in circumcision. *J Pediatr Urol.* 2020;16:99-106.
- [15] Han DS, Wu WT, Hsu PC, et al. Sarcopenia is associated with increased risks of rotator cuff tendon diseases among community-dwelling elders: a cross-sectional quantitative ultrasound study. *Front Med (Lausanne).* 2021;8:630009.
- [16] Hsu PC, Chang KV, Wu WT, et al. Effects of ultrasound-guided peritendinous and intrabursal corticosteroid injections on shoulder tendon elasticity: a post hoc analysis of a randomized controlled trial. *Arch Phys Med Rehabil.* 2021;102:905-13.
- [17] Hardwicke JT, Beehar JA, Hodson J, et al. Fistula after single-stage primary hypospadias repair—a systematic review of the literature. *J Plast Reconstr Aesthet Surg.* 2015;68:1647-55.
- [18] Mohammed M, Bright F, Mteta A, et al. Long-term complications of hypospadias repair: a ten-year experience from northern zone of Tanzania. *Res Rep Urol.* 2020;12:463-9.
- [19] Schneuer FJ, Holland JA, Pereira G, et al. Prevalence, repairs and complications of hypospadias: an Australian population-based study. *Arch Dis Child.* 2015;100:1-6.
- [20] Özen V, Yiğit D. Caudal epidural block versus ultrasound-guided dorsal penile nerve block for pediatric distal hypospadias surgery: a prospective, observational study. *J Pediatr Urol.* 2020;16:438.e1-8.
- [21] Kim MH, Im YJ, Kil HK. Impact of caudal block on postoperative complications in children undergoing tubularised incised plate urethroplasty for hypospadias repair: a retrospective cohort study. *Anaesthesia.* 2016;71:773-8.
- [22] Taicher BM, Routh JC, Eck JB, et al. The association between caudal anesthesia and increased risk of postoperative surgical complications in boys undergoing hypospadias repair. *Paediatr Anaesth.* 2017;27:688-94.