

## Effect of half adult dose of oral Rifampicin (300mg) in patients with idiopathic central serous chorioretinopathy

Muhammad Saim Khan<sup>1</sup>, Murtaza Sameen<sup>2</sup>, Arshad Ali Lodhi<sup>3</sup>, Munawar Ahmed<sup>4</sup>,  
Noman Ahmed<sup>5</sup>, Mustafa Kamal<sup>6</sup>, Sameen Afzal Junejo<sup>7</sup>

### ABSTRACT

**Objectives:** To evaluate the effect of half adult dose of oral Rifampicin on mean change in best corrected visual acuity and central macular thickness in patients with central serous chorioretinopathy.

**Methods:** Thirty-eight eyes of 31 patients with idiopathic central serous chorioretinopathy (CSCR) were registered. Unaided Visual acuity, best corrected visual acuity was documented and detailed slit lamp examination along with dilated ophthalmoscopy was performed. All subjects were treated with oral Rifampicin 300 mg (half adult dose) daily for 03 months. Patients underwent a complete ocular and systemic examination as well as central macular thickness (CMT) measurement by optical coherence tomography (OCT) every month after starting treatment until four months. Fundus fluorescein angiography (FFA) was performed in recurrent cases. Liver function tests were carried out prior to the treatment and during follow up period.

**Results:** A total of 38 eyes of 31 patients (24 males, 07 females) were included in the study. Mean age of patients was 36.16±3.19 years (range 30-44). Mean best corrected visual acuity (BCVA) before treatment was 0.56±0.11 and improved to 0.47±0.14 at 04 weeks (P<0.001) of treatment. The mean CMT at the time of presentation was 494.39±96.29 um and was decreased to 306.90±50.71 um after 04 weeks of treatment (P<0.001). The mean induced reduction in CMT was 187.48±122 um (P<0.001) while that in BCVA 0.41±0.16 at 04 weeks of treatment (P<0.001). Liver function tests were within normal range before and after the treatment.

**Conclusion:** Half adult dose rifampicin (300mg) is effective and safe in treatment of central serous chorioretinopathy without causing any systemic imbalance.

**KEY WORDS:** Central serous chorioretinopathy, Macular thickness, OCT, Rifampicin.

doi: <http://dx.doi.org/10.12669/pjms.325.10755>

### How to cite this:

Khan MS, Sameen M, Lodhi AA, Ahmed M, Ahmed N, Kamal M, et al. Effect of half adult dose of oral Rifampicin (300mg) in patients with idiopathic central serous chorioretinopathy. *Pak J Med Sci.* 2016;32(5):1158-1163.

doi: <http://dx.doi.org/10.12669/pjms.325.10755>

This is an Open Access article distributed under the terms of the Creative Commons Attribution License (<http://creativecommons.org/licenses/by/3.0>), which permits unrestricted use, distribution, and reproduction in any medium, provided the original work is properly cited.

### INTRODUCTION

Central serous retinopathy (CSR), also known as central serous chorioretinopathy (CSCR), a common retinal disorder which causes visual

impairment was first introduced by Albrecht von Graefe in 1866 as 'recurrent central retinitis' (von Graefe, 1866) and later Donald Gass coined the term 'central serous chorioretinopathy' for its typical clinical presentation.<sup>1,2</sup> It is characterized by the development of neurosensory retinal detachment from retinal pigment epithelium (RPE) mainly underneath macula with accumulation of sub retinal serous fluid secondary to a single, multifocal or diffuse area of leakage in RPE.<sup>3,4</sup> Young healthy males with age ranging from 30-50 years are more commonly affected and male to female ratio varies from 2.32:1 to 6:1 in various global populations.

#### Correspondence:

Dr. Sameen Afzal Junejo,  
Professor and Chairman Department of Ophthalmology,  
Liaquat University of Medical and Health Sciences,  
Hyderabad, Pakistan.  
E-mail: [sameenafzal1@gmail.com](mailto:sameenafzal1@gmail.com)

- \* Received for Publication: June 8, 2016
- \* Revision Received: July 4, 2016
- \* Accepted for Publication: August 12, 2016

The incidence of CSCR is higher in Asians than Caucasians and Hispanics, whereas African Americans are affected to a lesser extent.<sup>5-6</sup> The disease is usually unilateral.

Patients of CSCR usually present with mild deterioration of central vision, metamorphosis, scotoma and/or induced hypermetropia secondary to central macular elevation.<sup>7</sup> The exact mechanism involved in the etiology and evolution of CSCR remains unclear, however various risk factors have been associated with its development. Studies have shown the association of psychological stress, type A personality, endogenous/exogenous steroids, respiratory tract infection with *elicobacter pylori*, pregnancy and untreated hypertension with CSCR.<sup>8-10</sup> Although diagnosis of CSCR is made by clinical examination, various investigation modalities such as Optical coherence tomography (OCT), and fundus fluorescein angiography (FFA) are used to confirm the diagnosis and monitor the disease. The advent of indocyaninegreen angiography (ICG) has revolutionized the understanding of CSCR pathogenesis and can be useful in making a treatment decision. It is by virtue of ICG that choroidal vascular system compromise and leakage has been considered as a fundamental event in the pathogenesis of this disorder, which was once considered as merely an RPE defect.<sup>11</sup>

Central serous chorioretinopathy resolves spontaneously within 3-6 months with good visual outcome and usually patients with first episode are observed. However 50% of the patients have recurrences and 15-20% progress to chronic form which has relatively poor visual outcome.<sup>12</sup> Various treatment modalities such as standard laser photocoagulation, micro-pulse diode laser photocoagulation, trans-pupillary thermotherapy (TTT), photodynamic therapy (PDT) and multiple anti-corticosteroids agents have been proposed for the treatment of CSCR.<sup>13</sup> A recent study documented mineralocorticoid receptors in choroidal tissue, and hypothesized that glucocorticoids activate mineralocorticoid receptors and may cause or aggravate CSCR manifestations [Zhao M et al 2012].<sup>14</sup> As glucocorticoids are implicated in the development of CSCR, glucocorticoid inhibition with rifampicin has been suggested as a potential treatment modality.

Rifampicin, an antibacterial drug widely used in the treatment of tuberculosis and leprosy, is known to induce cytochrome P4503A4, therefore, having the potential to alter the metabolism of

steroids [Guengerich FP, 1999], and may lead to an improvement in CSCR manifestations. Rifampicin can effectively overcome CSCR by inducing catabolism of endogenous steroids, however the normal dose 600mg daily has been associated with complications such as hepatotoxicity.<sup>13</sup>

The rationale of conducting this study was the possible risk of complications associated with normal full dose rifampicin. Rifampicin 300 mg twice daily has been used in a small series to treat chronic CSCR with success.<sup>15</sup>

The aim of this study was to evaluate the effect of half daily dose of oral rifampicin (300mg) treatment for a period of three months in patients with idiopathic CSCR with visual impairment. The primary outcome measures included change in BCVA and change in the choroidal thickness after treatment.

## METHODS

This clinical observational study was carried out at the department of Ophthalmology Liaquat University of Medical and Health Sciences (LUMHS), Hyderabad, Pakistan between Jan 2013 and June 2015. A total of 38 eyes of 31 patients with age ranging from 30 to 44 years, and diagnosed as having idiopathic CSCR were included in the study by non-probability (purposive) sampling. Idiopathic CSCR was defined as a localized neurosensory retinal detachment associated with a focal leak or leaks at the level of the retinal pigment epithelium by fluorescein angiography. Patients with evidence of serous elevations secondary to other ocular conditions such as optic disc pit, multifocal choroiditis, posterior scleritis, choroidal mass or associated systemic illnesses were excluded from the study.

The study was approved by the local ethical committee and carried out in accordance with the Declaration of Helsinki. Informed verbal/written consent was taken from all registered subjects. Demographic details and blood group were noted. Unaided distant visual acuity (UDVA), visual acuity by using plus one convex spherical lens and best-corrected visual acuity (BCVA) was documented followed by detailed slit lamp examination after pharmacological dilation. Optical coherence tomography (OCT) an imaging technique was performed to confirm the diagnosis and note the central macular thickness (CMT). Fundus Fluorescein Angiography was done in recurrent cases. The registered subjects were started with an

oral 300 mg daily dose of Rifampicin for 3 months. Patients were reviewed at 4 weeks, 8 weeks, and 4 months for detailed ocular and systemic examination as well as measurement of central macular thickness by OCT. Liver function tests such as Alanine aminotransferase (ALT), Aspartate aminotransferase (AST) and Alkaline phosphatase (ALP) were carried out before starting the treatment and every four weeks treatment follow up.

**Laboratory tests:** Systemic laboratory work-up included a complete blood count and liver function tests at baseline and at 1, 2, and 3 months post treatment initiation. Following the confirmation of normal liver function tests at baseline, the patients were included in the study and received oral Rifampicin at a dosage of 300 mg daily for 3 months. **Statistical analysis:** We carried out the statistical analysis using statistical package for social sciences (SPSS 21.0) for windows. Continuous data such as Age, BCVA, CMT were described in terms of mean  $\pm$  SD (standard deviation). The induced change in BCVA and CMT after comparing the pre-treatment and 04 weeks, 08 weeks and 04 months after starting the treatment were evaluated statistically with paired sample test ( $p \leq 0.05$  significance level). Frequency distribution of categorical variables was also analyzed statistically ( $P < 0.05$  significance level).

**Ethics Approval:** Ethics and research committee of Liaquat University of Medical and Health Sciences/Jamshoro, Hyderabad, Pakistan approved the study.

## RESULTS

A total of forty-one (41) subjects (30 [73.1%] male, 11[26.9%] female) were enrolled. Four (9.75%) were lost to follow up. Six (14.63%) patients showed

significant abnormal liver function tests and thus were referred to medical consultant for further investigation and treatment.

Thirty eight eyes of 31 patients (24 males, 7 females) were registered. Of these, seven patients had bilateral involvement, while the rest were unilateral cases, 14 were right and 10 were left eyes. Ten patients belonged to rural background while 21 were from urban areas. Table-I shows the frequency distribution of various categorical variables. Liver function tests of all the registered subjects were within normal range before starting the treatment (Mean ALT=  $32 \pm 2$  IU/L, AST=  $35 \pm 2$  IU/L, ALP =  $86 \pm 12$  IU/L) and remained so after treatment at 4 weeks (Mean ALT=  $30 \pm 3$  IU/L, AST=  $31 \pm 4$  IU/L, ALP =  $90 \pm 6$  IU/L), 8 weeks (Mean ALT=  $34 \pm 3$  IU/L, AST=  $34 \pm 3$  IU/L, ALP =  $84 \pm 10$  IU/L) and 4 months (Mean ALT=  $30 \pm 3$  IU/L, AST=  $36 \pm 2$  IU/L, ALP =  $81 \pm 11$  IU/L).

Blood grouping assessment revealed B<sup>+</sup> in 64.5% subjects, O<sup>+</sup> in 25.8% and remaining 9.7% were A<sup>+</sup>. Mean age of patients was  $36.16 \pm 3.19$  years with a range from 31 to 42 years.

Mean best corrected visual acuity (BCVA) was  $0.56 \pm 0.116$  with a range of 0.00 to 0.77 before starting the treatment while after treatment at 04 weeks visual acuity was of  $0.47 \pm 0.148$ . The mean CMT at the time of presentation was  $494.39 \pm 96.2$   $\mu$ m while it was 306.90 after 04 weeks of starting half dose (300 mg daily) Rifampicin. The mean induced reduction in CMT was  $187.48 \pm 122$   $\mu$ m while that in BCVA was  $0.41 \pm 0.16$  (Table-II). The mean change in best corrected visual acuity and central macular thickness over a period of 04 months of treatment is shown in Fig.1 and Fig.2 respectively.

Table-I: Frequency distribution of various categorical variables: n=31.

Variables		Frequency	Percentage (%)
Gender	Males	24	77.4
	Females	07	22.6
Laterality	Right	14	45.2
	Left	10	32.3
	Bilateral	07	22.6
Primary/Recurrent	Primary	23	74.2
	Recurrent	07	22.6
Blood Groups	O+ve	08	25.8
	B+ve	20	64.5
	A+ve	03	9.7

Table-II: Mean, standard deviation and induced change of BCVA and CMT before and after treatment at 04 weeks.

	Mean $\pm$ SD	P - value
Pre-treatment BCVA	$0.56 \pm 0.11$	$P < 0.001$
Pre-treatment CMT	$494.39 \pm 96.29$	$P < 0.001$
Post-treatment BCVA	$0.47 \pm 0.14$	$P < 0.001$
Post-treatment CMT	$306.90 \pm 50.71$	$P < 0.001$
Induced Change in BCVA at 04 weeks	$0.41 \pm 0.16$	$P = 0.001$
Induced change in CMT at 04 weeks	$187.48 \pm 122.01$	$P = 0.001$

BCVA = Best Corrected Visual Acuity,  
CMT = Central Macular Thickness.

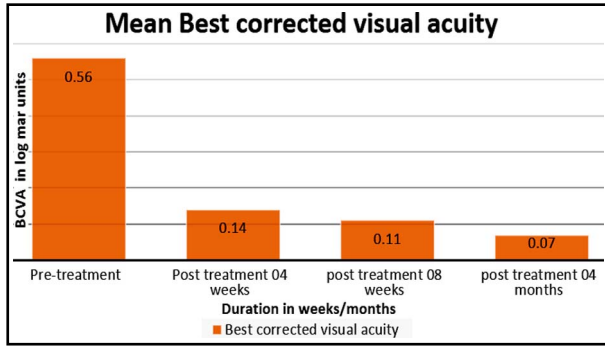


Fig.1: Best corrected Visual acuity (BCVA) before and after treatment at four months.

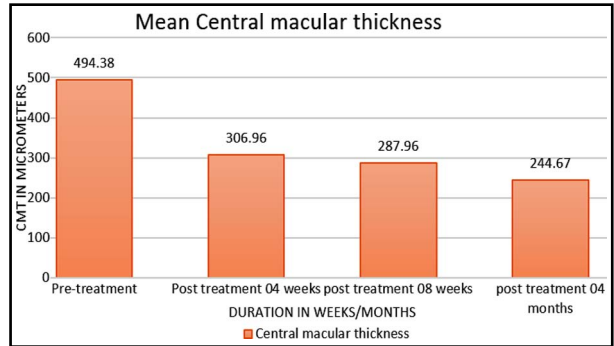


Fig.2: Central Macular thickness (CMT) before and after treatment at four months.

DISCUSSION

Rifampicin is an antibiotic that has been widely used as first line drug in treatment of tuberculosis along with Isoniazid, Pyrazinamide and Ethambutol.<sup>14</sup> The drug has also been known to have anti-oxidative, and anti-apoptotic properties and to induce cytochrome P-450 enzyme in liver. The role of Rifampicin in CSCR was introduced by Ravage and Packo when they found resolution of CSCR in a patient with tuberculosis.<sup>15-17</sup> This was followed by first ever case report published by Seinle NC and

his colleagues who also proposed the metabolism of endogenous steroids by Rifampicin induced cytochrome P450 as basic mechanism involved in improvement of CSCR patients.<sup>15</sup>

Shulman et al, in their study of 12 patients with chronic CSCR revealed significant improvement in vision as well as resolution of subretinal fluid at one month and this improvement was maintained over a period of 3-6 months. However, 16.6 % of patients developed adverse effects secondary to deranged liver functions and treatment was prematurely stopped in these patients.<sup>18</sup> Drug induced liver

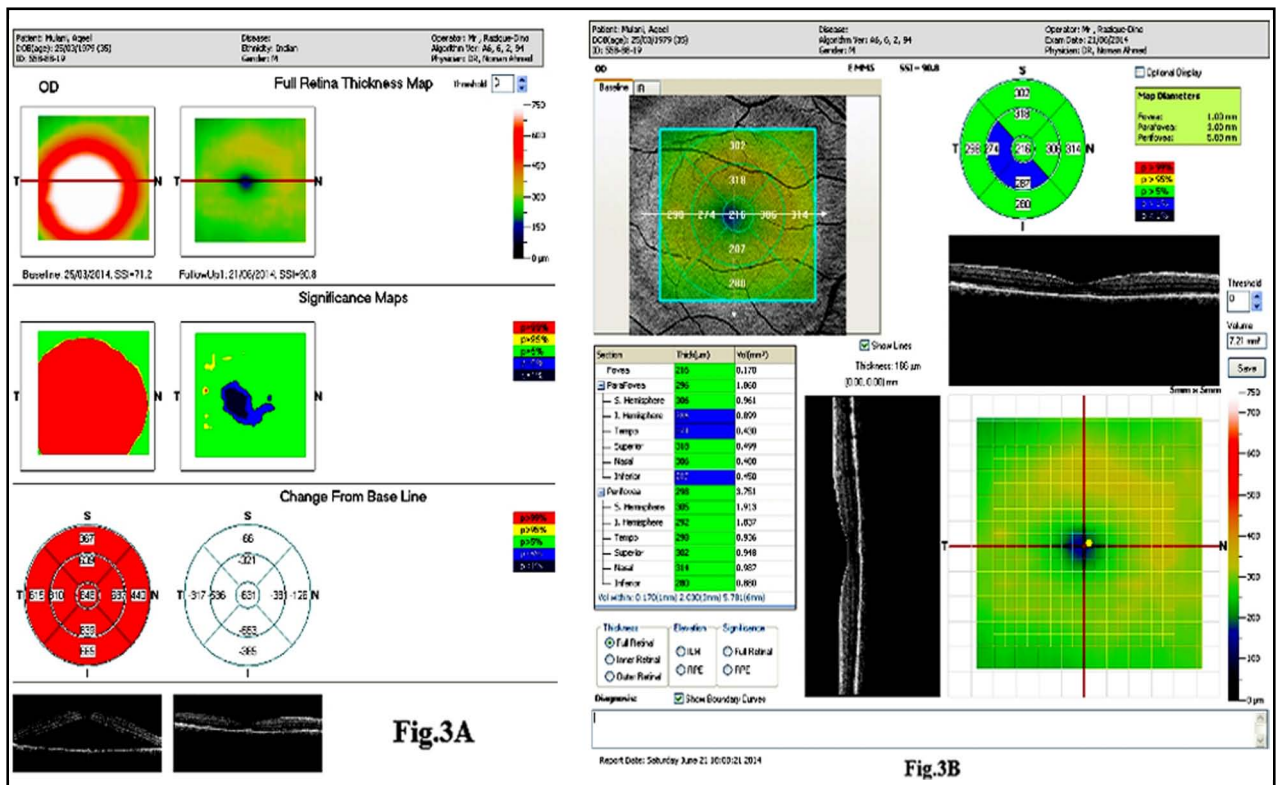


Fig.3: A and B: OCT and Fundus photograph of a patient before treatment (CMT=848 microns) (Fig:3A) and 3 months of commencement of treatment (CMT= 216 microns) (Fig:3B) with oral rifampicin 300 mg half adult dose daily.

Table-III: Multivariate analysis of various risk factors.

Variables	Frequency (n=31)	Percentage (%)
Systemic steroids intake	0	0.00 %
Sytsemic antibiotics intake	01	3.22 %
Pregnancy	0	0.00
Systemic hypertension	01	3.22%
Diabetes	01	3.22%
Type A personality	0	0%
Psycological stress	0	0%

injury (DILI) has been regarded as a potential side effect of Rifampicin. The mechanism involved is oxidative stress induced by Rifampicin that leads to hepatocyte injury and raised liver enzymes in serum.<sup>19,20</sup>

We, like Shulman et al, found significant improvement in vision as well as central retinal thickness at 4 weeks after starting the treatment with half daily dose of Rifampicin. The improvement in vision as well as CMT was seen in 89.4% (34 out of 38 eyes) in our study, which was much higher than what Shulman et al has concluded.<sup>18</sup> This difference can be due to different patient selection; most of our patients (74.2%) were recent onset cases of CSCR, while Shulman and his colleagues included all cases of chronic CSCR in their study. We did not find statistically significant improvement in 10.5% (4 out of 38 eyes) of our patients. In this study, we also found high prevalence of B+ve blood group in our patients (Table-III).

Hepatotoxicity, which is a known adverse effect of systemic Rifampicin therapy at a dose of 600 mg per day,<sup>19,20</sup> was not seen in any of our patients having daily dose of 300mg. Liver function tests which were performed before and during the follow up period remained within normal range.

In our study, we used half daily dose of rifampicin, which has not been reported in the literature so far except in a single case report. The results in new as well as recurrent cases of CSCR at the end of 3 months were statistically and clinically significant (Fig.3 A and B). There was marked improvement in the visual acuity and complete resolution of subretinal fluid was seen in around 90% of the patient as evidenced by optical coherence tomography. Moreover, we did not observe any side effects or complications with this treatment. Our study showed significant positive results and our findings are important and worth reporting. Whether to use half daily dose of Rifampicin in all cases of central serous retinopathy or recurrent/chronic cases is an area that needs to be further

evaluated. Furthermore, studies on a larger cohort and for a longer period of time, considering all the risk factors and confounding variables should be carried out to generate more comprehensive results. In conclusion, half daily dose of Rifampicin is an effective and safe treatment in patients with central serous chorioretinopathy without affecting the normal hepatic function.

**Limitations of the study:** This includes the fact that new cases of CSCR were major proportion of our sample, making around 74% in comparison to recurrent cases that were only 26%. Therefore, we could not consider the natural time for disease resolution that is supposed to occur in more than 50% of the cases. Secondly we could not rule out the confounding role of stress therapy, lifestyle changes and anxiety related management that patients may also be undergoing. Thirdly we could only follow the patients for a relatively shorter period of four months after the treatment.

#### ACKNOWLEDGEMENTS

We are grateful to Imran A. Bhutto MD, PhD for the critical assessment of the final manuscript and helpful comments.

**Declaration of interest:** The authors did not have any conflict of interest regarding publication of article.

**Source of funding:** Self - funded.

#### REFERENCES

1. vonGraefe A: Überzentralereizdivierende Retinitis. Graefes Arch Clin Exp Ophthalmol. 1866;12:211-215.
2. Gass JD. Bullous retinal detachment. An unusual manifestation of idiopathic central serouschoroidopathy. Am J Ophthalmol. 1973;75(5):810-821.
3. Gemenetzi M, De Salvo G, Lotery AJ. Central serous chorioretinopathy: An update on pathogenesis & treatment. Eye (Lond) 2010;24(12):1743-1756. doi: 10.1038/eye.2010.130.
4. Ross A, Ross AH, Mohamed Q. Review and update of central serous chorioretinopathy. Curr Opin Ophthalmol. 2011;22(3):166-173. doi: 10.1097/ICU.0b013e3283459826.
5. Said-Ahmed K, Moustafa G, Fawzy M. Incidence and natural course of symptomatic central serous chorioretinopathy in pregnant women in a maternity hospital in Kuwait. Middle East Afr J Ophthalmol. 2012;19(3):273-276.
6. Eom Y, Oh J, Kim SW. Systemic factors associated with central serous chorioretinopathy in Koreans. Korean J Ophthalmol. 2012;26(4):260-264. doi: 10.3341/kjo.2012.26.4.260.
7. Shahin MM. Angiographic characteristics of central serous chorioretinopathy in an Egyptian population. Int J Ophthalmol. 2013;6(3):342-345.
8. Tsai DC, Chen SJ, Huang CC. Risk of central serous chorioretinopathy in adults prescribed oral corticosteroids: a population-based study in Taiwan. Retina. 2014;34(9):1867-1874. doi: 10.1097/IAE.0000000000000159

9. Chang YS, Weng SF, Chang C. Associations Between Topical Ophthalmic Corticosteroids and Central Serous Chorioretinopathy: A Taiwanese Population-Based Study. *Invest Ophthalmol Vis Sci.* 2015;56(6):4083-4089. doi: 10.1167/iovs.14-16360.
10. Sahin A, Bez Y, Kaya MC. Psychological distress and poor quality of life in patients with central serous chorioretinopathy. *Semin Ophthalmol.* 2014;29(2):73-76. doi: 10.3109/08820538.2013.793728.
11. Hua R, Yao K, Xia F. The hyper-fluorescent transitional bands in ultra-late phase of indocyanine green angiography in chronic central serous chorioretinopathy. *Lasers Surg Med.* 2016;48(3):260-263.
12. Mudvari SS, Goff MJ, Fu AD. The natural history of pigment epithelial detachment associated with central serous chorioretinopathy. *Retina.* 2007;27(9):1168-1173.
13. Abouammoh MA. Advances in the treatment of central serous chorioretinopathy. *Saudi J Ophthalmol.* 2015;29(4):278-286.
14. Zhao M, Celerier I, Bousquet E, Jeanny JC, Jonet L, Savoldelli M, et al. Mineralocorticoid receptor is involved in rat and human ocular chorioretinopathy. *J Clin Invest.* 2012;122(7):2672-2679. doi: 10.1172/JCI61427
15. Steinle NC, Gupta N, Yuan A. Oral rifampin utilisation for the treatment of chronic multifocal central serous retinopathy. *Br J Ophthalmol.* 2012;96(1):10-13. doi: 10.1136/bjophthalmol-2011-300183.
16. Nelson J, Saggau DD, Nielsen JS. Rifampin induced hepatotoxicity during treatment for chronic central serous chorioretinopathy. *Retin Cases Brief Rep.* 2014;8(1):70-72. doi: 10.1097/ICB.0000000000000007.
17. Pouw AE, Olmos de Koo LC. Oral rifampin for central serous retinopathy: a strategic approach in three patients. *Ophthalmic Surg Imaging Lasers Retina.* 2015;46(1):98-102. doi: 10.3928/23258160-20150101-19.
18. Shulman S, Goldenberg D, Schwartz R. Oral Rifampin treatment for longstanding chronic central serous chorioretinopathy. *Graefes Arch Clin Exp Ophthalmol* 2016;254(1):15-22. doi: 10.1007/s00417-015-2989-z
19. Wu ZR, Bai ZT, Sun. Protective effects of the bioactive natural product N-trans-Caffeoyldopamine on hepatotoxicity induced by isoniazid and rifampicin. *Bioorg Med Chem Lett.* 2015;25(22):5424-5426. doi: 10.1016/j.bmcl.2015.09.003.
20. Gaude GS, Chaudhury A, Hattiholi J. Drug-induced hepatitis and the risk factors for liver injury in pulmonary tuberculosis patients. *J Family Med Prim Care.* 2015;4(2):238-243. doi: 10.4103/2249-4863.154661.

#### **Authors' Contributions:**

**Prof. Dr. Sameen Afzal Junejo:** Conception and Final approval of version to be published.

**Dr. Muhammad Saim Khan and Dr. Murtaza Sameen:** Drafting and statistical analysis.

**Dr. Arshad Ali Lodhi, Dr. Munawar Ahmed, Dr. Noman Ahmed and Dr. Mustafa Kamal:** Designing and Data collection.

---

#### Authors:

1. Muhammad Saim Khan,
2. Murtaza Sameen,
3. Arshad Ali Lodhi,
4. Munawar Ahmed,
5. Noman Ahmed,
6. Mustafa Kamal,
7. Sameen Afzal Junejo,
- 1, 2: Department of Ophthalmology,  
Armed Forces Institute of Ophthalmology (AFIO),  
Rawalpindi, Pakistan.
- 3-7: Department of Ophthalmology,  
Liaquat University of Medical and Health Sciences,  
Jamshoro,  
Hyderabad, Pakistan.