



OPEN ACCESS

H-type tracheoesophageal fistula diagnosed on video fluoroscopy swallowing study

Shu Yi Sonia Lee,¹ Ehab Shaban Mahmoud Hamouda²

¹Department of Radiology, Changi General Hospital, Singapore, Singapore

²Department of Diagnostic and Interventional Imaging, KK Women's and Children's Hospital, Singapore, Singapore

Correspondence to

Dr Shu Yi Sonia Lee, sonia.lee@mohh.com.sg

Accepted 15 November 2018

DESCRIPTION

Our patient is a 15-month-old Caucasian girl with antenatally diagnosed chromosome 13 trisomy mutation. She was born full-term with a birth weight of 2600 g and APGAR scores of 9 at 1 and 5 min of life with no significant perinatal illness. Our patient presented to the hospital frequently for recurrent respiratory infections. She also suffered from mild oropharyngeal dysphagia with weak swallows and coughing on feeding of fluids since birth. These were initially attributed to poor respiratory health and an antenatally diagnosed aberrant right subclavian artery resulting in oesophageal compression and chronic microaspiration.

As part of work-up for her swallowing dysfunction, a video fluoroscopy swallowing (VFS) study was conducted by the speech therapist and radiologist. In one of the images for which thin fluids was administered, a thin sliver of contrast medium is seen to enter the upper trachea from the upper oesophagus. A H-type tracheoesophageal fistula was suspected and the study was aborted. The paediatric pulmonologist and surgeon were emergently informed of this finding.

Subsequent bronchoscopy and oesophagogastroduodenoscopy (OGD) performed confirmed the presence of the tracheoesophageal fistula approximately 4 cm inferior to the level of the vocal cords (figure 1). Orogastric tube feeding was started to prevent further aspiration. Surgical repair of the fistula was later performed.

The 'H' type is a rare form of tracheoesophageal fistulae with a prevalence of 4%.¹ Early diagnosis of tracheoesophageal fistula is critical in guiding feeding, surgical repair and preventing further complications which include recurrent respiratory infections and death.

Although patients consistently experience coughing or choking episodes on feeding since birth and suffer from recurrent respiratory infections, diagnosis remains a challenge due to multiple factors. The fistulae are commonly small and inconsistently patent. The oblique configuration of the H-shaped tracheoesophageal fistula and close apposition of the trachea and oesophagus makes it difficult to appreciate radiologically. This may also be contributed to by the redundant nature of normal oesophageal mucosa which may transiently occlude the fistula.²

As a result, repeated radiological investigations using oesophagram studies may be required to make a definitive diagnosis.³ Special positioning and contrast delivery techniques have been described to aid in radiological diagnosis of this condition.² In patients with typical symptoms with associated congenital anomalies such as the VACTREL sequence and chromosomal anomalies, a high degree of suspicion should be employed and timely bronchoscopy and/or OGD needs to be considered to exclude a tracheoesophageal fistula.

Although VFS studies are performed primarily to evaluate oral, pharyngeal and upper oesophageal swallowing function, our case report illustrates the importance of careful review of the images to ensure that uncommon diagnoses such as a tracheoesophageal fistula are not missed.

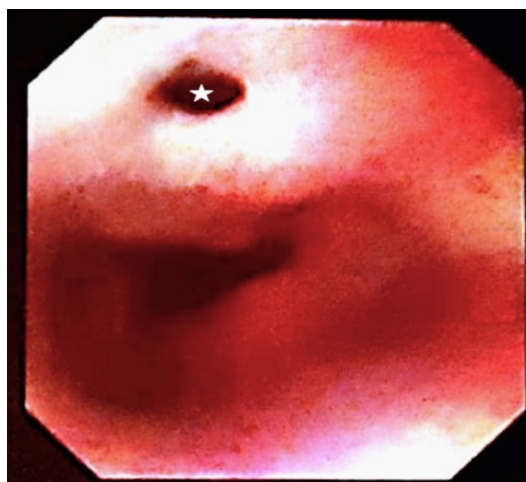
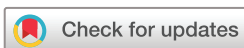

Figure 1 Endoscopic photo taken during subsequent oesophagogastroduodenoscopy confirming the site of communication between the trachea and oesophagus (star).



© BMJ Publishing Group Limited 2018. Re-use permitted under CC BY-NC. No commercial re-use. See rights and permissions. Published by BMJ.

To cite: Lee SYS, Hamouda ESM. *BMJ Case Rep* 2018;**11**:e227794. doi:10.1136/bcr-2018-227794

Learning points

- ▶ A high degree of clinical suspicion to evaluate for tracheoesophageal fistulation should be employed in patients with feeding difficulties and recurrent respiratory infections with associated congenital anomalies.
- ▶ H-type tracheoesophageal fistulae are rare, challenging to diagnose radiologically, and may require repeated investigations.
- ▶ Although endoscopic evaluation remains the gold standard for diagnosis of tracheoesophageal fistulae, care on review of other imaging modalities (eg, video fluoroscopy swallowing) should be made to ensure uncommon diagnoses are not missed.

Contributors SYSL: contributed to conception, interpretation, drafting and revision of work. ESMH: contributed to conception, interpretation and final approval of work. The first author, SYSL, agrees to be accountable for all aspects of the work in ensuring that questions related to the accuracy or integrity of any part of the work are appropriately investigated and resolved.

Funding The authors have not declared a specific grant for this research from any funding agency in the public, commercial or not-for-profit sectors.

Competing interests None declared.

Patient consent Parental/guardian consent obtained.

Provenance and peer review Not commissioned; externally peer reviewed.

Open access This is an open access article distributed in accordance with the Creative Commons Attribution Non Commercial (CC BY-NC 4.0) license, which

permits others to distribute, remix, adapt, build upon this work non-commercially, and license their derivative works on different terms, provided the original work is properly cited and the use is non-commercial. See: <http://creativecommons.org/licenses/by-nc/4.0/>

REFERENCES

- 1 Jaiswal AA, Garg AK, Mohanty MK. 'H' type tracheo-oesophageal fistula – Case reports with review of the literature. *Egyptian Journal of Ear, Nose, Throat and Allied Sciences* 2014;15:143–8.
- 2 Botwe BO, Mensah YB, Kekesi K, *et al.* Fluoroscopic technique used to diagnose missed H-type tracheo-oesophageal fistula: Case report. *World J Med Med Sci Res* 2014;2:118–22.
- 3 Karnak İbrahim, Şenocak ME, Hiçsönmez A, *et al.* The diagnosis and treatment of H-type tracheoesophageal fistula. *J Pediatr Surg* 1997;32:1670–4.

Copyright 2018 BMJ Publishing Group. All rights reserved. For permission to reuse any of this content visit <https://www.bmj.com/company/products-services/rights-and-licensing/permissions/>
BMJ Case Report Fellows may re-use this article for personal use and teaching without any further permission.

Become a Fellow of BMJ Case Reports today and you can:

- ▶ Submit as many cases as you like
- ▶ Enjoy fast sympathetic peer review and rapid publication of accepted articles
- ▶ Access all the published articles
- ▶ Re-use any of the published material for personal use and teaching without further permission

For information on Institutional Fellowships contact consortiasales@bmjgroup.com

Visit casereports.bmj.com for more articles like this and to become a Fellow