



Contents lists available at ScienceDirect

## International Journal of Surgery Case Reports

journal homepage: [www.casereports.com](http://www.casereports.com)Pancreatitis from intra-gastric balloon insertion: Case report and literature review<sup>☆</sup>Neel Gore<sup>a</sup>, Praveen Ravindran<sup>a,b,\*</sup>, Daniel Leonard Chan<sup>a</sup>, Kamalakanta Das<sup>a</sup>, Peter H. Cosman<sup>a,b</sup><sup>a</sup> Department of Surgery, Liverpool Hospital, Liverpool, NSW, Australia<sup>b</sup> University of Western Sydney, School of Surgery, Australia

## ARTICLE INFO

## Article history:

Received 17 February 2018

Received in revised form 5 March 2018

Accepted 7 March 2018

Available online 16 March 2018

## Keywords:

Intragastric balloon

Pancreatitis

Obesity surgery

## ABSTRACT

**INTRODUCTION:** Intra-Gastric Balloon (IGB) is increasingly used as a non-operative management strategy in bariatric patients. However, as IGB use has become more prevalent, new potentially life-threatening adverse effects have emerged. We report a case of IGB-related acute pancreatitis from a tertiary referral hospital. A literature review of electronic databases was conducted to identify other cases

**PRESENTATION OF CASE:** A 20-year-old female presented to the emergency department with acute onset of epigastric pain on day-1 post-insertion of an IGB (Orbera<sup>®</sup>). The diagnosis of acute pancreatitis was made on the basis of the clinical picture, with radiological and serological confirmation. Complete resolution of symptoms promptly followed endoscopic removal of the balloon.

**DISCUSSION:** We examine all prior reported cases of IGB associated pancreatitis in the literature, as well as the impact of the particular balloon subtypes. Mass effect of the device on the pancreas or dislodgement of the rigid catheter into the second part of the duodenum appear to be the underlying cause in all cases. While there were no deaths reported, major sequelae have been noted, including presence of mucosal ischemia and failure to retrieve the balloon endoscopically, necessitating laparotomy.

**CONCLUSION:** Although the incidence of IGB-induced pancreatitis is still rare, this complication which must be highlighted as a potentially serious adverse outcome.

© 2018 The Author(s). Published by Elsevier Ltd on behalf of IJS Publishing Group Ltd. This is an open access article under the CC BY-NC-ND license (<http://creativecommons.org/licenses/by-nc-nd/4.0/>).

## 1. Introduction

Intra-Gastric Balloon (IGB) has been a controversial short-term strategy for rapid weight loss since its introduction. Multiple systematic reviews and meta-analyses have been performed to elucidate the complication rates of IGB. Pancreatitis is only a recently recognised complication of IGB [1].

There are only thirteen reported cases in the literature. We present a case report of iatrogenic acute pancreatitis in a 20-year-old female following insertion of an IGB along with a review of the literature. Our work has been reported in line with the SCARE criteria [2].

## 2. Case report

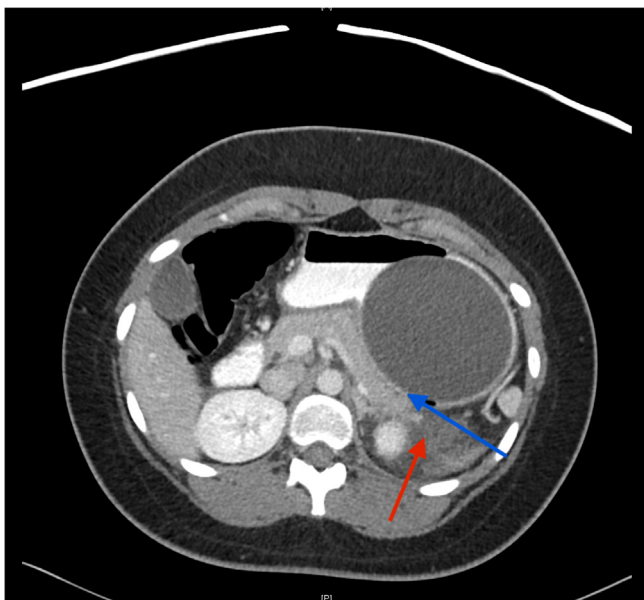
A 20-year-old female with a BMI of 41 kg/m<sup>2</sup> presented to our emergency department with generalised abdominal pain and vomiting one day after insertion of an IGB (Orbera<sup>®</sup>; Allergan Inc., Santa Barbara, California, USA) filled with 500 ml of saline. The insertion of the IGB was noted by the clinician to be smooth with no intraoperative difficulties. Her medical history was otherwise unremarkable, with no other clear risk factors for pancreatitis. She was afebrile (37.3 °C) with a normal pulse rate (83). She had isolated epigastric tenderness and an otherwise soft abdomen. Full blood count demonstrated leucocytosis (WCC 24.7 × 10<sup>9</sup>/L) and serum studies confirmed raised lipase (900 U/ml) and a C-Reactive Protein (CRP) level of 247 mg/L, with normal electrolytes, renal function, liver function and triglycerides.

A formal abdominal ultrasound was negative for cholelithiasis, as well as for any intra or extra hepatic duct dilatation. An intravenous and oral contrast enhanced abdominal CT demonstrated evidence of pancreatitis with pancreatic stranding, peri-pancreatic oedema, and a trace of free intra-peritoneal fluid. The IGB could be seen compressing the distal body and tail of the pancreas with associated stranding of the tail of the pancreas (Fig. 1). A consultant radiologist felt these appearances to be most consistent with

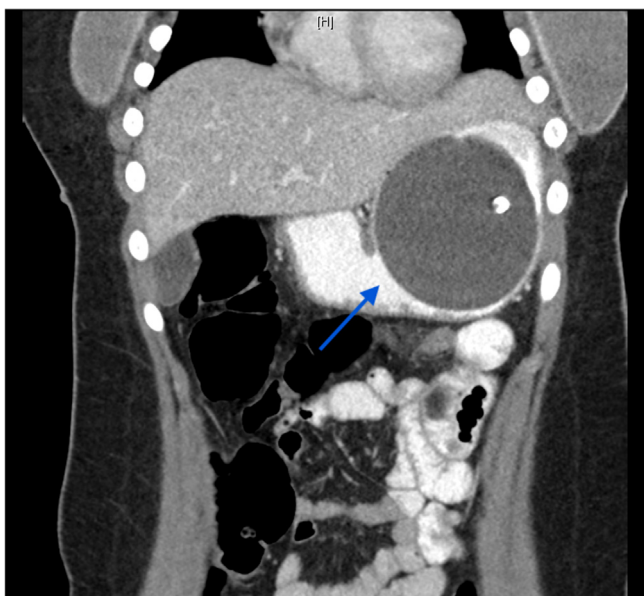<sup>☆</sup> This paper is based on: Poster presentation accepted at the 2016 at ANZGOSA /SUGSS “Surgeons and the Upper GI Tract” Meeting 2016 Sydney.

\* Corresponding author at: Liverpool Hospital, Department of Surgery, Liverpool, New South Wales, 2170, Australia.

E-mail address: [Praveen.Ravindran@health.nsw.gov.au](mailto:Praveen.Ravindran@health.nsw.gov.au) (P. Ravindran).



**Fig. 1.** Axial CT showing IGB compressing tail of the pancreas (blue arrow) with peripancreatic oedema and stranding (red arrow).



**Fig. 2.** Coronal CT showing IGB position and oral contrast distal to IGB (blue arrow).

acute pancreatitis. Oral contrast could be seen flowing freely into the proximal jejunum, excluding gastric outlet obstruction (Fig. 2).

The IGB was endoscopically removed two days after admission by the treating surgeon, and endoscopic inspection revealed no gastric mucosal ischemia. The patient's clinical course dramatically improved following removal of the IGB, and her WCC and CRP normalised. She was discharged home two days later. Given all the other tests, including autoimmune screens, triglyceride and calcium levels were normal, and the patient did not have a prior history of trauma, a known history of cystic fibrosis, any recent attempts to cannulate her ampulla of Vater or a family history of pancreatitis, the diagnosis of acute pancreatitis due to IGB compression of the pancreas was made. Two years following this episode, the patient had no further episodes of pancreatitis.

### 3. Discussion

Endoscopic insertion of IGB has been used as it provides a less invasive and potentially safer option for short term weight loss [3]. One meta-analysis found a weighted mean reported incidence of serious adverse events (AE) across eight studies was 10.5% [1]. Four IGB associated deaths have been reported, but they have been related to gastric perforation or aspiration, with none being associated with pancreatitis [4].

The theory driving IGB use is that the space-occupying device not only results in early satiety, but also induces several hormonal changes which result in weight-loss [5]. It has primarily been implemented as a temporary measure to assist bariatric patients in becoming more suitable candidates for surgery, or for those patients in which surgery is not an option. The Garren-Edward Gastric Bubble (GEGB) was the inaugural IGB to be granted FDA approval in 1984. Constructed from polyurethane, the cylindrical device contained a hollow central channel and was to be filled with 200 ml of air. Sub-optimal weight loss resulted, coupled with serious side effects including gastric erosion, small bowel obstruction and gastric perforation led to its removal from the market [6]. This resulted in design changes aiming for a safer IGB: silicone balloons, spherical in shape and saline filled, with a smooth surface, and a radiopaque marker [6].

This case illustrates acute pancreatitis can follow insertion of IGB. To our knowledge, this is the earliest reported case of pancreatitis post IGB insertion. Table 1 outlines the key aspects of the other thirteen cases [7–15]. The complication of pancreatitis appears to occur more commonly in recent years. There were only three cases reported between 2008 and 2012, but 10 cases reported since 2014.

A review of the other cases suggests that the cases of pancreatitis were due to the mass effect by the balloon on the pancreas, or by dislodgement of the catheter into the second part of the duodenum. All these cases involved filling the balloon with the recommended amount, between 400 and 700 ml of saline. After prompt removal of the balloon via endoscopy, all patients clinically improved without development of serious sequelae.

All reported cases involved the adjustable and non-adjustable single balloon systems, while there have been none yet reported on the dual-balloon systems. Of note is that endoscopic failure to retrieve the balloon often occurs once the catheter has been dislodged into the second part of the duodenum. This appears to have occurred two times in the reported cases [9,13] with involvement of the adjustable single balloon system (Spatz ABS®; Spatz Medical, Great Neck, NY). These two reported cases required laparotomy for balloon retrieval, and at least one case showed signs of gastric mucosal ischaemia at endoscopy which necessitated laparotomy to exclude full thickness ischaemia. This system has a non-collapsible catheter that is intended to lower the risk of balloon migration. However, these two cases demonstrated that catheter migration can occur with this device even in the absence of deflation and with life-threatening sequelae.

Furthermore, not all the cases of pancreatitis were mild. Four cases [7,9,12,13] demonstrated evidences of local peripancreatic fluid collections or pancreatic necrosis. This further highlights that when left unrecognised, potentially severe sequelae of pancreatitis may result from IGB balloon related pancreatitis.

The dual-balloon device (Reshape Duo Integrated DBS®; Reshape, San Clemente, CA) was developed to address the issues of excessive compression and intestinal migration. The dual balloons were designed to reduce intestinal migration, without the use of a rigid catheter. It occupies more space than its predecessors and can distribute the pressure throughout a greater longitudinal axis. Each of the two balloons has an independent channel so that unintended deflation in one balloon will not lead to deflation of the other balloon, but rather the inflated balloon will keep the deflated

**Table 1**  
Author.

|                       | Age/Sex | Time after insertion | Severity                                     | Balloon type              | IGB removal method  |
|-----------------------|---------|----------------------|--|---------------------------|---|
| Mohammed [15]         | 31 F    | 10 weeks             | Mild   | Single Balloon            | Endoscopic  |
| Shelton [14]          | 32 M    | 10 weeks             | Mild   | Single Balloon            | Endoscopic  |
| Vongsuvanah [13]      | 30 F    | 11 months            | Severe with pancreatic necrosis              | Single Adjustable Balloon | Laparotomy due to failure to retrieve endoscopically and concern about ischaemic stomach on endoscopy |
| Geffrier [12]         | 47 F    | 15 days              | Moderate with peripancreas fluid collections | Single Balloon            | Endoscopic  |
| Issa [11]             | 26 F    | 2 days               | Mild   | Single Balloon            | Endoscopic  |
| Navajas (2015) [17]   | 28 M    | 4 months             | Mild   | Single Balloon            | Endoscopic  |
| Ozturk [9]            | 38 F    | 1 month              | Moderate with peripancreas fluid collections | Single Adjustable Balloon | Laparotomy due to endoscopic failure with gastrostomy used to retrieve balloon.                       |
| Said [8]              | 27 F    | 5 weeks              | Mild   | Not specified             | Endoscopic  |
| Selfa-Munoz [7]       | 20 F    | 5 months             | Moderate with focal necrosis of tail         | Not specified             | Not performed during admission  |
| Al-jiffry (2017) [16] | 24 M    | 4 months             | Mild   | Not specified             | Endoscopic  |
|                       | 26 M    | 1 month              | Mild   | Not specified             | Endoscopic  |
|                       | 27 M    | 2 months             | Mild   | Not specified             | Endoscopic  |
|                       | 31 F    | 2 months             | Mild   | Not specified             | Endoscopic  |
| Gore (2017)           | 19F     | 1 day                | Mild   | Single Balloon            | Endoscopic  |

balloon from migrating. While our literature review was unable to find any published cases of pancreatitis involving the dual-balloon devices, we do note the recent FDA warning to providers on the risk of pancreatitis in both the Orbera® and Reshape® balloons.

**4. Conclusion**

Pancreatitis associated with IGB insertion is a rare but increasingly recognised clinical entity. The experience in the literature suggests that patients can be at risk of this complication anytime between 1 day–11 months after insertion. Diagnosis is usually made after confirming the compression on cross sectional imaging and by exclusion of other causes of pancreatitis. Prompt endoscopic removal of the balloon usually results in resolution of the problem, while simultaneously allowing for internal examination of gastric mucosa for signs of ulceration or necrosis. While death from IGBs is rare, and the incidence of pancreatitis is low, prompt intervention minimizes the risk of severe clinical sequelae.

**Conflicts of interest**

None.

**Funding**

None.

**Ethical approval**

As this was a case report, ethical approval was exempted by our institution, however patient permission was given prior to publication.

**Consent**

Written informed consent was obtained from the patient for publication of this case report and accompanying images. A copy of the written consent is available for review by the Editor-in-Chief of this journal on request

**Authors contribution**

Praveen Ravindran was involved in the study design and writing of the paper

Neel Gore was involved in the study design and writing of the paper.

Daniel Chan was involved in the study design and writing of the paper.

Kamalakanta Das was involved in the study design and writing of the paper.

Peter Cosman was involved in the study design and writing of the paper.

**Guarantor**

Praveen Ravindran is the Guarantor of this work.

**References**

- [1] C.M. Tate, A. Geliebter, Intra-gastric balloon treatment for obesity: review of recent studies, *Adv. Ther.* 34 (8) (2017) 859–1875.
- [2] R.A. Agha, A.J. Fowler, A. Saeta, I. Barai, S. Rajmohan, D.P. Orgill, et al., The SCARE statement: consensus-based surgical case report guidelines, *Int. J. Surg.* 34 (2016) 180–186.
- [3] ABET Force, AT Committee, B.K. Abu Dayyeh, N. Kumar, S.A. Edmundowicz, S. Jonnalagadda, et al., ASGE Bariatric Endoscopy Task Force systematic review and meta-analysis assessing the ASGE PIVI thresholds for adopting endoscopic bariatric therapies, *Gastrointest. Endosc.* 82 (3) (2015) 425–438.
- [4] C. Hill, M.A. Khashab, A.N. Kalloo, V. Kumbhari, Endoluminal weight loss and metabolic therapies: current and future techniques, *Ann. N. Y. Acad. Sci.* 1411 (1) (2017) 36–52.
- [5] R.J. Phillips, T.L. Powley, Gastric volume rather than nutrient content inhibits food intake, *Am. J. Physiol.* 271 (3 Pt. 2) (1996) 766–769.
- [6] J.J. Gleysteen, A history of intra-gastric balloons, *Surg. Obes. Relat. Dis.* 12 (2) (2016) 430–435.
- [7] A. Selfa Munoz, S.F. Calzado Baeza, A. Palomeque Jimenez, F.J. Casado Caballero, Acute pancreatitis associated with the intra-gastric balloon, *Gastroenterol. Hepatol.* 39 (9) (2016) 603–604.
- [8] F. Said, S. Robert, E.K. Mansour, Pancreatitis and intra-gastric balloon insertion, *Surg. Obes. Relat. Dis.* 12 (3) (2016) e33–e34.
- [9] A. Ozturk, Y. Yavuz, T. Atalay, A case of duodenal obstruction and pancreatitis due to intra-gastric balloon, *Balkan Med J.* 32 (3) (2015) 323–326.
- [10] M. Navajas-Laboa, L. Bridet, A. Orive-Calzada, J.L. Cabriada-Nuno, Intra-gastric balloon and epigastric pain: beware of the pancreas, *Turk. J. Gastroenterol.* 26 (1) (2015) 87–88.
- [11] I. Issa, A. Taha, C. Azar, Acute pancreatitis caused by intra-gastric balloon: a case report, *Obes. Res. Clin. Pract.* 10 (3) (2016) 340–343.
- [12] C. Geffrier, E. Samaha, H. Duboc, Acute balloon pancreatitis, *Endoscopy* 46 (Suppl. 1) (2014) (UCTN:E383).

- [13] R. Vongsuvan, H. Pleass, D. van der Poorten, Acute necrotizing pancreatitis, gastric ischemia, and portal venous gas complicating intragastric balloon placement, *Endoscopy* 46 (Suppl. 2) (2012) (UCTN:E383–4).
- [14] E. Shelton, P. Froomes, M.A. Fink, Education and imaging gastrointestinal: balloon pancreatitis, *J. Gastroenterol. Hepatol.* 27 (5) (2012) 986.
- [15] A.E. Mohammed, A. Benmoussa, Acute pancreatitis complicating intragastric balloon insertion, *Case Rep. Gastroenterol.* 2 (3) (2008) 291–295.
- [16] M. Aljiffry, R. Habib, E. Kotbi, A. Ageel, M. Hassanain, Y. Dahlan, Acute pancreatitis: a complication of intragastric balloon, *Surg. Laparosc. Endosc. Percutan. Tech.* (2017).
- [17] M. Navajas-Laboa, L. Bridet, A. Orive-Calzada, J.L. Cabriada-Nuno, Intragastric balloon and epigastric pain: beware of the pancreas, *Turk. J. Gastroenterol.* 26 (1) (2015) 87–88.

#### Open Access

This article is published Open Access at [sciencedirect.com](https://www.sciencedirect.com). It is distributed under the [IJSCR Supplemental terms and conditions](#), which permits unrestricted non commercial use, distribution, and reproduction in any medium, provided the original authors and source are credited.