

# White-Eyed Blowout Fracture

Cheruvathur Prasad, M. Arulmozhi, J. Balaji, M. P. Nilopher Nisha<sup>1</sup>

Department of Oral and Maxillofacial Surgery, Government Dental College and Hospital, <sup>1</sup>Department of Oral and Maxillofacial Surgery, The Tamil Nadu Dr. MGR Medical University, Chennai, Tamil Nadu, India

## Abstract

White-eyed blowout fracture is often found in pure orbital floor blowout fracture among pediatric patients. Unlike common orbital blowout fractures with apparent clinical signs, the diagnosis of white-eyed orbital blowout fractures is difficult because of minimal soft-tissue signs. This report describes an early missed-out diagnosis of a white-eyed blowout fracture in a 7-year-old child, due to negligible soft-tissue manifestation.

**Keywords:** Binocular diplopia, fat entrapment, trapdoor, white-eyed blowout fracture

## INTRODUCTION

White-eyed blowout fracture was first termed by Jordan *et al.* in individuals sustaining a blow to the periocular area and presenting with ocular symptoms, with minimal soft-tissue signs of trauma.<sup>[1]</sup> In pediatric patients, it is often found as pure orbital floor fractures, and it could manifest as a linear or hinge-like trapdoor deformity. White-eyed blowout fractures are rarer than the open orbital blowout fractures, which are more common. The open orbital blowout fractures have distinct diagnostic clinical signs, whereas the diagnosis of white-eyed blowout fracture can be easily missed, subsequently costing an optimal time window for surgical intervention. This is critical as better outcomes are found with earlier release of entrapments.<sup>[1]</sup> The diagnosis of white-eyed orbital blowout fracture was made 4 days after trauma in this case, and surgical release of entrapped muscle was done under general anesthesia. Full range of movements of the eyeball was achieved within 6 months postoperatively.

## CASE REPORT

A healthy 7-year-old boy was referred to the Department of Oral and Maxillofacial Surgery (OMFS), of a tertiary hospital with a complaint of pain over the left cheek region.

History revealed that he had trauma 4 days back. He refused to do homework and keeps his head in the tilted position.

On examination, mild tenderness over the left zygoma was noted, and the left eyeball movement was restricted without periorbital edema, ecchymosis, and subconjunctival

hemorrhage.

On visual examination, the left eye revealed binocular diplopia on direct upward and temporal gaze. He also had upward movement restriction of the left eye, suggesting left inferior rectus muscle entrapment [Figure 1].

Computed tomography (CT) finding confirmed left orbital floor fracture with entrapment [Figure 2].

The diagnosis of white-eyed orbital blowout fracture was made and planned for the release of entrapped muscle under general anesthesia.

## Diagnostic methods

1. Conventional water's projection
2. Tomography
3. CT scanning
4. Magnetic resonance imaging
5. Forced duction test
6. Electromyography
7. Orbitography
8. Sinuscopy.<sup>[2]</sup>

**Address for correspondence:** Dr. M. Arulmozhi,  
No. 2, Kannagi Street, Kamaraj Nagar, Avadi, Chennai - 600 071,  
Tamil Nadu, India.  
E-mail: dr.r.arulmozhimds1977@gmail.com

Received: 27-06-2019

Revised: 06-11-2019

Accepted: 01-02-2020

Published: 08-06-2020

### Access this article online

Quick Response Code:



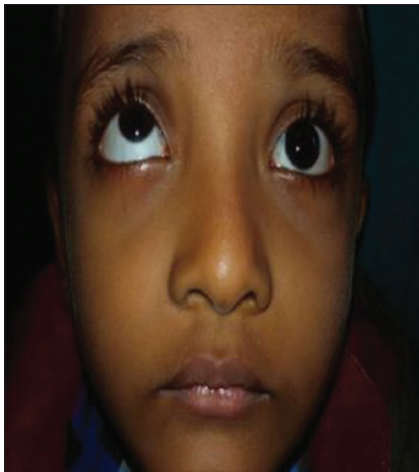Website:  
www.amsjournal.com

DOI:  
10.4103/ams.ams\_150\_19

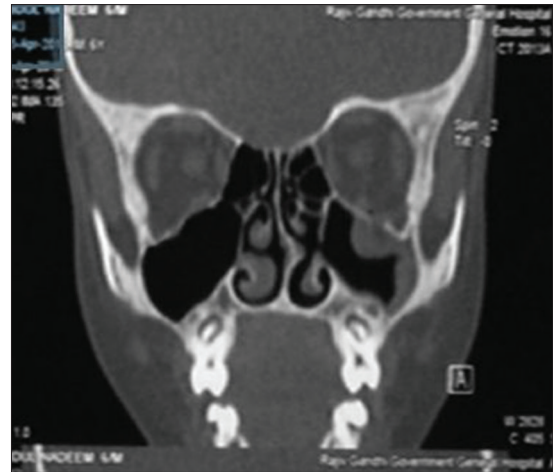This is an open access journal, and articles are distributed under the terms of the Creative Commons Attribution-NonCommercial-ShareAlike 4.0 License, which allows others to remix, tweak, and build upon the work non-commercially, as long as appropriate credit is given and the new creations are licensed under the identical terms.

For reprints contact: WKHLRPMedknow\_reprints@wolterskluwer.com

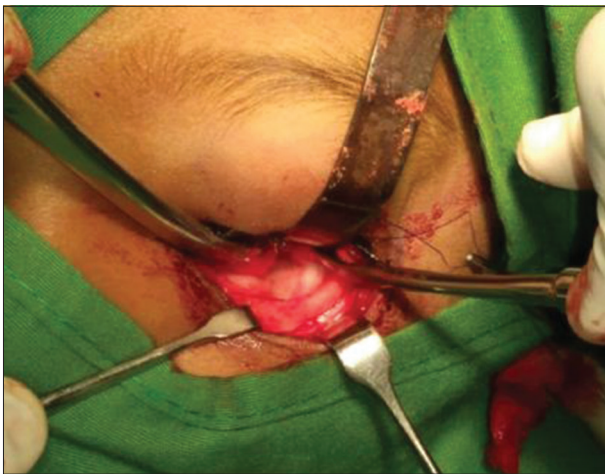
**How to cite this article:** Prasad C, Arulmozhi M, Balaji J, Nilopher Nisha MP. White-eyed blowout fracture. *Ann Maxillofac Surg* 2020;10:217-9.



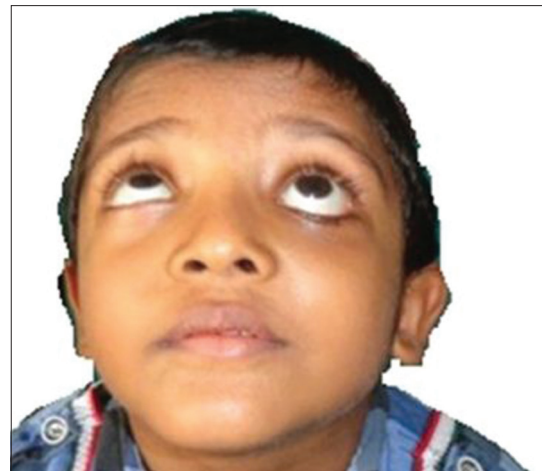**Figure 1:** Upward movement restriction in the left eye



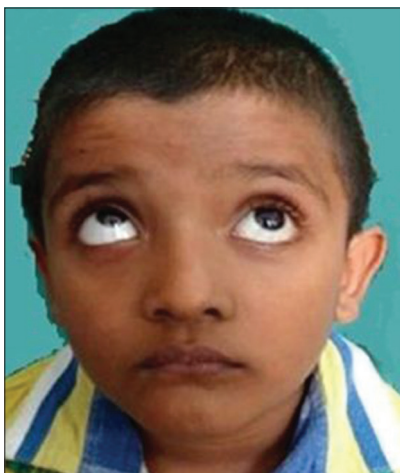**Figure 2:** Coronal computed tomography – left orbital floor fracture with entrapment



**Figure 3:** Intact infraorbital rim with entrapped orbital content



**Figure 4:** One-week postoperatively



**Figure 5:** Six-month postoperatively

### Surgical procedure

Under general anesthesia, the patient was painted and draped, subciliary incision was placed, and layer-wise dissection was done. An intact infraorbital rim was noted [Figure 3].

Muscle and fat entrapment were identified and released. Forced duction test was done by holding the inferior rectus muscle by a forceps and checked for upward movement. There was no restriction in the upward movement.

Layer-wise closure was done with 5-0 Vicryl and 5-0 Ethilon.

### DISCUSSION

Although the thickness of the medial orbital wall is 0.2–0.4 mm and that of the floor is 0.5 mm, orbital floor fracture is common because of the presence of inferior orbital fissure and lack of buttressing effect from septate ethmoidal air sinuses. A fracture of the orbital wall without the involvement of the orbital rim is called blowout fracture. Open type and trapdoor type are the two variants of blowout fracture. In the trapdoor variant, displacements of fractures are usually linear with an increased chance for muscle entrapment. Trapdoor variant of blowout fracture, which is devoid of soft-tissue manifestation, is called white-eyed blowout fracture.<sup>[3]</sup>

The clinical features of pediatric white-eyed blowout fractures are different from that of adult. The elastic nature of the pediatric bone can absorb high impact, yet sustain minimal damage. In children, the skeletal morphology, thicker periosteum and incomplete fused sutural lines, and increased soft-tissue thickness over the malar region are the reasons for no soft-tissue manifestation.<sup>[4-6]</sup>

The fracture mechanism in white-eyed blowout fracture is explained by the interaction of both hydraulic and buckling theories.<sup>[5,7]</sup> The assessment of inferior rectus muscle vulnerability in CT was described by Neinstein *et al.* They found that inferior rectus muscle approximation to the orbital floor makes the muscle susceptible to injuries and mechanically weaken the superior oblique muscle.<sup>[3,6,8]</sup>

Delayed or missed-out diagnosis of white-eyed blowout fracture can lead to extraocular muscle necrosis, permanent diplopia, blindness, restricted gaze, and life-threatening oculocardiac reflex complications.<sup>[9]</sup>

In some cases, vomiting, bradycardia, and ocular pain (oculocardiac reflex) will be present, which should be treated as an emergency.<sup>[10]</sup> The initial symptoms are usually that of vague pain rather than diplopia, so every OMFS surgeon should have a thorough knowledge about the pattern of orbital fracture and clinical examination. In this case, the diagnosis was made 3 days after trauma.

The most common complication in white-eyed blowout fracture is persistent diplopia.<sup>[11]</sup> The recovery period ranges from 25 days to 18 months with longer recovery time in younger age (<9 years).<sup>[8,12,13]</sup> We achieved the full range of movements at 6 months [Figures 4 and 5].

## CONCLUSION

This case reported to our department within 4 days of trauma and was taken up for surgery immediately. Due to early intervention, full range of eye movements in all 9 gazes was achieved within 6 months postoperatively. The role of maxillofacial surgeon is very important in the diagnosis of white eyed blowout fracture as he/she might be the first person to identify the ophthalmic signs, since the initial symptoms are that of vague pain in the maxillofacial region rather than diplopia. The importance of early intervention is reiterated and can avoid further permanent damage to the eye.

## Declaration of patient consent

The authors certify that they have obtained all appropriate patient consent forms. In the form, the patient's mother has given her consent for the child's images and other clinical information to be reported in the journal. The patient's mother understands that the child's name and initial will not be published, and due efforts will be made to conceal identity, but anonymity cannot be guaranteed.

## Financial support and sponsorship

Nil.

## Conflicts of interest

There are no conflicts of interest.

## REFERENCES

- Jordan DR, Allen LH, White J, Harvey J, Pashby R, Esmali B. Intervention within days for some orbital floor fractures: The white-eyed blowout. *Ophthalmic Plast Reconstr Surg* 1998;14:379-90.
- Gussack GS. Rowe and Williams' maxillofacial injuries. 2<sup>nd</sup> ed. J. LL. Williams, Churchill Livingstone; New York, 1994. 1,087 pp. *Head Neck* 1995;17:552-3.
- Waterhouse N, Lyne J, Urdang M, Garey L. An investigation into the mechanism of orbital blowout fractures. *Br J Plast Surg* 1999;52:607-12.
- Kwon JH, Moon JH, Kwon MS, Cho JH. The differences of blowout fracture of the inferior orbital wall between children and adults. *Arch Otolaryngol Head Neck Surg* 2005;131:723-7.
- Cobb AR, Jeelani NO, Ayliffe PR. Orbital fractures in children. *Br J Oral Maxilla Fac Surg* 2013;51:41-6.
- Neinstein RM, Phillips JH, Forrest CR. Pediatric orbital floor trapdoor fractures: Outcomes and CT-based morphologic assessment of the inferior rectus muscle. *J Plast Reconstr Aesthet Surg* 2012;65:869-74.
- Nagasao T, Miyamoto J, Shimizu Y, Jiang H, Nakajima T. What happens between pure hydraulic and buckling mechanisms of blowout fractures? *J Craniomaxillofac Surg* 2010;38:306-13.
- Yew CC, Shaari R, Rahman SA, Alam MK. White-eyed blowout fracture: Diagnostic pitfalls and review of literature. *Injury* 2015;46:1856-9.
- Saggese NP, Mohammadi E, Cardo VA. The 'White-eyed' orbital blowout fracture: An easily overlooked injury in maxillofacial trauma. *Cureus* 2019;11:e4412.
- Pham CM, Couch SM. Oculocardiac reflex elicited by orbital floor fracture and inferior globe displacement. *Am J Ophthalmol Case Rep* 2017;6:4-6.
- Wei LA, Durairaj VD. Pediatric orbital floor fractures. *J Am Assoc Pediatr Ophthalmol Strabismus* 2011;15:173-80.
- Yang JW, Woo JE, An JH. Surgical outcomes of orbital trapdoor fracture in children and adolescents. *J Craniomaxillofac Surg* 2015;43:444-7.
- Cope MR, Moos KF, Speculand B. Does diplopia persist after blow-out fractures of the orbital floor in children? *Br J Oral Maxillofac Surg* 1999;37:46-51.