

Vertically Set Sombrero-shaped Abdominal Flap for Asian Breast Reconstruction after Skin-sparing Mastectomy

Hirokazu Uda, MD
 Kotaro Yoshimura, MD
 Rintaro Asahi, MD
 Syunji Sarukawa, MD
 Ataru Sunaga, MD
 Hideaki Kamochi, MD
 Yasushi Sugawara, MD

Background: Immediate autologous breast reconstruction after skin-sparing mastectomy is an esthetically superior method, and a free abdominal flap is often used. However, in Asian patients, little redundant abdominal skin and thin subcutaneous tissue are common, necessitating the development of a more suitable flap design and setting. We devised a narrow flap, the sombrero-shaped flap (S-flap), set vertically, to reduce postoperative abdominal morbidity without sacrificing cosmetic results.

Methods: To assess this new flap design and setting, the recipient- and donor-site complications of consecutive patients treated by S-flap (n = 40) and conventional flap (C-flap) (n = 22) were retrospectively investigated. Postoperative abdominal pain, stiffness, and patient activity were also assessed in each group with our original grading scale.

Results: Compared with the C-flap group, the S-flap group had a significantly lower skin paddle vertical height (mean, 14.0 and 10.2 cm, respectively; $P < 0.001$), lower abdominal stiffness ($P = 0.023$), and higher rate of double-pedicled flap use (27.3% and 52.5%, respectively; $P < 0.048$). The rates of donor and recipient site complications, postoperative abdominal pain, and activity did not significantly differ between the groups.

Conclusions: For immediate breast reconstruction after skin-sparing mastectomy in Asian patients, our newly designed S-flap and vertical flap setting achieved cosmetically good, consistent results with low abdominal morbidity, even though the abdominal flap was thin and narrow. The viability of the S-flap, including medial fan-shaped adipose flap, was reliable, even though the flap often required elevation with double pedicles. (*Plast Reconstr Surg Glob Open* 2016;4:e1123; doi: 10.1097/GOX.0000000000001123; Published online 7 December 2016.)

Immediate autologous breast reconstruction after skin-sparing mastectomy (SSM) is an esthetically superior method because the skin envelope of the breast re-

mains mostly intact, scarring is less visible, and surgeons can focus on recreating the 3D shape of the breast by autologous flap transfer.¹⁻⁵ After SSM, a free abdominal flap, such as deep inferior epigastric perforator flap or muscle-sparing transverse abdominal flap (MS flap), is often used because it is easy for handling and has sufficient volume to fill the breast, with low donor morbidity. This trend is similar worldwide, including in Asia. However, generally in Asian patients, mean body mass index (BMI) is lower and the abdominal subcutaneous tissue is thinner than in Western populations. In addition, the

From the Department of Plastic Surgery, Jichi Medical University, Tochigi, Japan.

Received for publication July 29, 2016; accepted September 16, 2016.

Name of Clinical Trial database registered: Investigation about the influence on trunk flexion after free abdominal flap elevation in breast reconstruction. Registration number and date registered: A14-060.

Copyright © 2016 The Authors. Published by Wolters Kluwer Health, Inc. on behalf of The American Society of Plastic Surgeons. All rights reserved. This is an open-access article distributed under the terms of the Creative Commons Attribution-Non Commercial-No Derivatives License 4.0 (CCBY-NC-ND), where it is permissible to download and share the work provided it is properly cited. The work cannot be changed in any way or used commercially without permission from the journal.

DOI: 10.1097/GOX.0000000000001123

Disclosure: The authors have no financial interest to declare in relation to the content of this article. The Article Processing Charge was paid for by the authors.

Supplemental digital content is available for this article. Clickable URL citations appear in the text.

laxity and elasticity of the skin are low, the abdomen has little redundant tissue, and there is a tendency for hypertrophic abdominal scarring.⁶⁻⁹ Thus, it is often difficult to harvest a vertically wide flap, and the absolute volume of the flap tends to be insufficient for breast reconstruction.¹⁰ Therefore, in many Asian patients, it is necessary to devise a suitable flap design and setting for this patient population (Fig. 1).

In flap settings for Asians, to use a thin and narrow flap effectively, we generally rotate the flap nearly 90 degrees and mount it vertically on the breast mound. In addition, we devised a flap design involving an extended abdominal free flap with the addition of a fan-shaped adipose flap to the central cephalic portion, which fills the B area of the breast fully to reduce the vertical width of the skin paddle (Fig. 2).

In this report, we describe our flap setting method and the design and harvesting technique of the flap for breast reconstruction in Asian patients after SSM. We also evaluated the effectiveness of this sombrero-shaped flap (S-flap) in comparison with the conventional flap (C-flap) with regard to recipient and donor site morbidities.

MATERIALS AND METHODS

We conducted a retrospective review of 62 consecutive patients who underwent autologous immediate breast reconstruction with abdominal free flap after SSM at Jichi Medical University Hospital performed by a single surgeon (H.U.). Twenty-two and 40 patients underwent breast reconstruction with a C-flap from August 2007 to April 2012 and with an S-flap from April 2012 to April 2014, respectively.

The characteristics of each patient, vertical height of the flap used, and number of pedicles (single or double) were recorded from clinical charts and operation records (Table 1). Information was also compiled on the incidence of complications after C-flap and S-flap at the recipient site, including total and partial flap loss, partial fat necrosis, infection and hematoma, and mastectomy flap necrosis, and at the donor site, including problems with wound healing and seroma (Table 2). All study participants provided informed consent, and the study was approved by the appropriate ethics review boards at Jichi Medical University.

Flap Design and Elevation

All patients underwent routine preoperative contrast multidetector row computed tomography of the abdomen to determine the dominant perforators and the course of the deep inferior epigastric artery. Based on this information, the dominant perforators were chosen. First, we generally chose the dominant perforators and pedicle on the ipsilateral side of the affected breast. The vertical height of the C-flap was designed to match the horizontal width of the resected breast mound (Fig. 2A). For the S-flap, the vertical height was narrower, designed to cover the distance from medial of the resected nipple to lateral of the defect of breast mound (Fig. 2B). A fan-shaped adipose flap was also added to the central cephalic portion of the S-flap to fill the B area of the breast. The adipose flap was elevated just below the superficial fascia, Scarpa's fascia, and the superficial fat layer was preserved to prevent postoperative unevenness of the abdomen. After completing dissection of the ipsi-

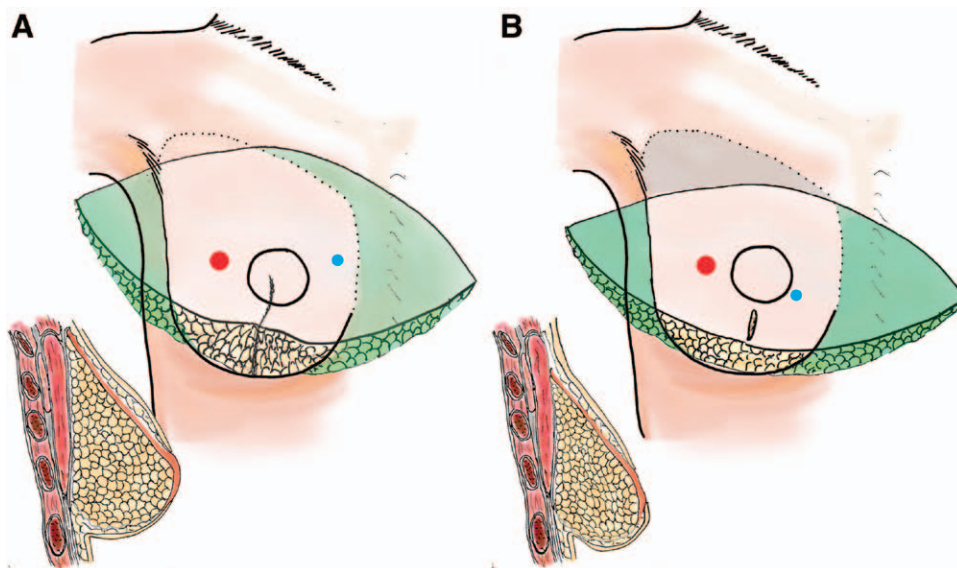


Fig. 1. Transverse flap settings. A, In Western patients: the flap is rotated nearly 180 degrees, and a coning procedure is performed to achieve sufficient projection of the center of the breast. A large vertical width is necessary to fill the AC area of the breast. In many cases, a contralateral single pedicle is sufficient to maintain the viability of the grafted flap. B, In Asian patients: the flap is narrow, and the defect of the AC area remains. The coning procedure is also ineffective because the flap is thin and inelastic. Therefore, the defect of décolleté remains, and the breast is flat with low projection. (Green: discarded area; red: perforator of the contralateral pedicle; blue: perforator of the ipsilateral pedicle.)

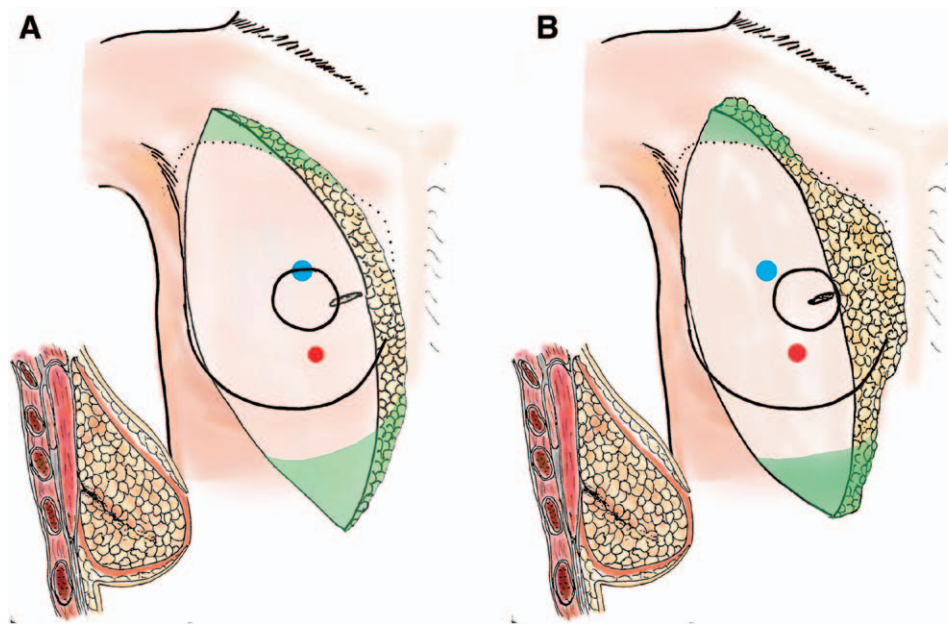


Fig. 2. Vertical flap settings. A, With the conventional flap: all defects of the breast are well filled, and good projection and lower pole fullness of the breast are achieved by the contralateral part of the flap folded inside. The flap often requires a double pedicle. B, With the S-flap: by adding a fan-shaped adipose flap just above the center of the flap, keeping the same cosmetic result, the skin paddle can be narrower than a conventional flap. In many cases, the flap must be elevated with a double pedicle. (Green: discarded area, red: perforator of the contralateral pedicle, blue: perforator of the ipsilateral pedicle.)

Table 1. Patient Demographics and History

Patient Characteristics	Sombrero Flap (n = 40) (%)	Conventional Flap (n = 22) (%)	P
Age			
Mean (range)	48 (33–61)	50 (37–60)	0.381*
BMI			
Mean (range)	23.3 (17.9–30.9)	22.2 (16.8–27.2)	0.218*
Postoperative radiation therapy	2 (5.0)	2 (9.1)	0.447†
Tobacco use	0 (0)	0 (0)	0.574†
Previous abdominal surgery	16 (40.0)	8 (36.4)	0.499†
Systemic disease	1 (2.5)	3 (13.6)	0.124†
Vertical height of the flap (cm)			
Mean (range)	10.2 (9–12)	13.8 (12–15)	<0.001*
Double pedicled flap	21 (52.5)	6 (27.3)	0.048†

*The 2-sample *t* test.

†The chi-square test.

Bold value indicates statistically significant differences.

lateral dominant perforators and pedicle, the contralateral dominant perforators, generally 1 to 3 in number, were detected just above the anterior sheath of the rectus muscle and clamped with microvascular clips. The umbilicus was then removed from the flap. Next, a total of 3 mL of indocyanine green was administered through the patient’s peripheral IV catheter, and the viability of all zones of the flap was estimated with a Photodynamic Eye infrared camera system (Hamamatsu Photonics, Hamamatsu, Japan). When the necessary portion of the flap for reconstruction was well visualized, the flap was elevated as an ipsilateral single pedicled flap, and then the unnecessary portion of the flap was discarded.

Table 2. Complications

Complication	Sombrero Flap (n = 40) (%)	Conventional Flap (n = 22) (%)	P*
Breast			
Total flap loss	2 (5.0)	0	0.412
Deformity by partial flap loss	1 (2.5)	2 (9.1)	0.285
Induration by partial fat necrosis	4 (10.0)	4 (18.2)	0.294
Infection	2 (5.0)	1 (4.5)	0.715
Hematoma	3 (7.5)	0	0.261
Mastectomy flap necrosis	1 (2.5)	1 (4.5)	0.588
Abdomen			
Wound-healing problems	1 (2.5)	1 (4.5)	0.588
Seroma after drain removal	11 (27.5)	3 (13.6)	0.177
Hernia	0	0	0.574
Bulging	2 (5.0)	3 (13.6)	0.765

*Fisher’s exact test.

If nearly the entire flap (from zone I to zone IV) was necessary for reconstruction or the viability of the necessary portion of the flap was poor, the flap was elevated as a double-pedicled flap with preserved contralateral perforators.

In all patients, internal mammary vessels (IMVs) were chosen as recipient vessels. In recipients of double-pedicled flaps, we performed intraflap crossover anastomosis before anterograde end-to-end anastomosis with IMVs or chose anterograde and retrograde double end-to-end anastomosis with IMVs.

Vertical Flap Setting

For effective use of the horizontal width of the vertically narrow flap, we generally rotate the flap nearly 90 degrees medially and mount it vertically on the thoracic mound. By doing so, the thickest portion of the flap around the umbilicus is set at the nipple and areolar region, which generally creates the top projection of the breast, and the ipsilateral lateral portion of the flap can adequately fill the defect of décolleté (AC area) and axillary tail (C' area). To create lower pole fullness of the breast (BD area) and to achieve good projection with the thin flap, the contralateral portion of the flap is folded inward. When the volume of the contralateral portion of the flap is excessive, it is discarded. In all patients, the skin paddle of the flap was deepithelized, except for the defect of the areolar portion of the breast (Fig. 2).

Postoperative Complications and Donor Site Morbidity

Using our prospectively maintained clinical database, information was compiled on the incidence of flap complications after S-flap and C-flap, including total flap loss, partial flap loss, partial fat necrosis, infection, hematoma, and mastectomy flap necrosis. Partial flap loss was defined as a significant portion of the flap becoming necrotic due to impaired blood flow and fat lysis, which ultimately induces prominent deformation of the reconstructed breast. Partial fat necrosis was defined as a small portion of the fat within the flap becoming necrotic, with palpable induration occurring postoperatively but not influencing the overall proportions of the reconstructed breast. Donor site complications such as wound-healing problems, seroma, and abdominal infection were also assessed. In addition, to estimate abdominal morbidity, patients in each group were assessed using our original grading scale, the abdominal pain, stiffness, and activity scale, at 6-months postoperative follow-up at the outpatient clinic (Table 3).^{11,12}

Statistical Analysis

The 2-sample *t* test was used to compare age, BMI, and flap height between the S-flap and C-flap groups. The chi-

square test was used to compare the rates of postoperative radiation therapy, tobacco use, previous abdominal surgery, systemic disease, and double-pedicled flap. Fisher's exact test was used to examine differences in the occurrence of each complication after surgery between the 2 groups. The Mann-Whitney *U* test was used to calculate statistically significant differences in grading scores for abdominal pain and stiffness and patient activity. For all statistical analyses, differences with a *P* value <0.05 were considered statistically significant.

RESULTS

Patient demographics and history are summarized in Table 1. The mean patient age was 48 years (range, 33–61 y) in the S-flap group and 50 years (range, 37–60 y) in the C-flap group. The mean patient BMI was 23.3 kg/m² (range, 17.9–30.9 kg/m²) and 22.2 kg/m² (range, 16.8–27.2 kg/m²) in the S-flap and C-flap groups, respectively. There was no significant difference in age or BMI between the groups. The rates of postoperative radiation therapy, tobacco use, previous abdominal surgery, and systemic disease, which are thought to influence the incidence of flap and donor site complications, also did not statistically differ. The mean height of the S-flap was 10.2 cm (range, 9–12 cm), and that of the C-flap was 14.0 cm (range, 12–15). Twenty-one of 40 (52.5%) and 6 of 22 (27.3%) S-flaps and C-flaps, respectively, employed a double-pedicled flap. The mean vertical height of S-flaps was significantly smaller than that of C-flaps (*P* < 0.001). By contrast, the rate of double-pedicled flap use was significantly higher in the S-flap group than in the C-flap group (*P* = 0.048).

Postoperative Complications

Complications of the S-flap and C-flap groups were as follows: total flap loss in 2 (5.0%) and zero patients, partial flap loss in 1 (2.5%) and 2 (9.1%) patients, partial fat necrosis in 4 (10.0%) and 4 (18.2%) patients, infection in 2 (5.0%) and 1 (4.5%) patient, hematoma in 3 (7.5%) and zero patients, mastectomy flap necrosis in 1 (2.5%) and 1 (4.5%) patient, abdominal wound healing problems in 1 (2.5%) and 1 (4.5%) patient, abdominal seroma in 11 (27.5%) and 3 (13.6%) patients, and bulging in 2 (5.0%)

Table 3. The APSA Scale

Abdominal Pain and Stiffness	Score	Patient's Activity	Score
Pain at just after surgery		In daily life at 6 mo after surgery	
Painful even when resting in bed	1	Major obstacle and strong limitation	1
Painful only when moving	2	Moderate obstacle and mild limitation	2
Mild and I could move than I thought	3	Minor obstacle but no limitation	3
Almost no pain and I could move well	4	Almost no obstacle and no limitation	4
Pain at 6 mo after surgery		In light sports at 6 mo after surgery	
Severely painful and very concerned	1	Major obstacle and strong limitation	1
Painful and concerned	2	Moderate obstacle and mild limitation	2
Mild and barely-troublesome	3	Minor obstacle but no limitation	3
Almost no pain	4	Almost no obstacle and no limitation	4
Stiffness at 6 mo after surgery		In hard sports at 6 mo after surgery	
Severely stiff and very concerned	1	Major obstacle and strong limitation	1
Stiff and concerned	2	Moderate obstacle and mild limitation	2
Mild and barely troublesome	3	Minor obstacle but no limitation	3
Almost no stiffness	4	Almost no obstacle and no limitation	4

APSA, abdominal pain, stiffness, and activity after surgery scale.

and 3 (13.6%) patients, respectively. There were no cases of hernia in either group. No statistically significant differences were noted for any complications (Fig. 1). In all 8 patients (4 [10.0%] in the S-flap group and 4 [18.2%] in the C-flap group) who had palpable induration due to partial fat necrosis after surgery, the flap was elevated as a single-pedicled flap, and the indurations existed in the medial portion of the lower pole of the breast (B area), where the cephalic portion of zone II of the flap was folded inside and inserted. In the S-flap group, this area coincided with the fan-shaped adipose flap.

Postoperative Abdominal Pain, Stiffness, and Patient Activity

There was no significant difference in abdominal pain between the groups immediately after surgery or 6 months after surgery. However, abdominal stiffness in the C-flap group was significantly greater than that in the S-flap group. By contrast, there was no significant difference in patient activity 6 months after surgery between the groups (Table 4).

DISCUSSION

In Asian patients, 2 important considerations must be recognized to achieve good cosmetic results of autologous breast reconstruction with reduced abdominal morbidity. First, Asian patients tend to be more slender than Western patients, and the abdominal flap is generally thin and inelastic. According to data from the Organization for Economic Co-operation and Development, the mean BMIs in the United States and Japan were 28.40 kg/m² and 22.69 kg/m², respectively.¹³ Recreating the rounded fullness of the lower pole and sufficient top projection of the breast are cosmetic keys to optimal breast reconstruction. However, when the thickness and volume of the flap are insufficient, these aims cannot be achieved. These are major disadvantages for breast reconstruction in Asians. Second, the abdominal skin of Asians is generally not highly distensible, with little redundancy.^{8,10} Therefore, in many Asian patients, harvesting a vertically sufficient wide flap tends to be difficult. In our experience, when the vertical width exceeds 13 cm, the intraoperative tension needed to

close the abdominal wound increases rapidly, and patients tend to complain of long-lasting and bothersome abdominal stiffness postoperatively. The risk of hypertrophic scar formation can also increase at abdominal donor site.⁸ Paik et al¹⁴ reported that vertical flap width was a significant risk factor for overall abdominal donor-site morbidity in Asians. Xu et al¹⁰ also reported that the vertical height of the flap should be kept below 10 cm. "Less than 10 cm" may be unnecessarily stringent, but these findings further emphasize that harvesting vertically tall and thick abdominal flaps is often difficult in Asian patients.

If a thin and narrow flap is set transversely with nearly 180-degree rotation, as recommended by Blondeel et al,¹⁵ the reconstructed breast tends to become flat and unattractive because it is not sufficiently thick and elastic to create a good projection and lower pole fullness. Furthermore, due to the lower vertical width of the flap, the AC area of the breast cannot be filled, and defect of décolleté remains (Fig. 1B). Thus, in many Asian patients, the transverse flap setting is inefficient, and the cosmetic results of breast reconstruction also tend to be poor. In addition, both lateral ends of the flap are trimmed substantially even though the entire volume of the flap is insufficient (Fig. 1B). Therefore, in Asian patients, we generally recommend the vertical flap setting. Use of the vertical setting can achieve sufficient top projection, good lower pole fullness, and good contour of the décolleté area even though the flap is thin and narrow (Fig. 2). Nevertheless, to fully cover the transverse width of the breast mound, it was still necessary to harvest C-flaps with mean vertical width exceeding 13 cm (mean 13.8 cm, range: 12–15 cm), which is thought to be too wide for most Asian patients.^{10,14}

In immediate breast reconstruction after SSM, the entire breast skin envelope except the nipple and areolar complex is maintained, and it is not necessary to fill the entire defect with deepithelialized skin paddle of the C-flap. Thus, we developed the S-flap. The adipose tissue under Scarpa's fascia added just above the umbilicus of the S-flap can fill the B area of the breast fully (Figs. 2B, 3). With this S-flap design, the vertical height of the skin paddle could be significantly reduced (mean 10.2 cm, range: 9–12 cm), and abdominal stiffness was significantly relieved at 6 months after surgery, even though the rate of donor site complications, abdominal pain, and patient activity did not significantly differ.

Considering our strategy critically, the vertical flap setting has some drawbacks. Generally, we have to use nearly the entirety of zone II and sometimes zone IV in the vertical flap setting. Therefore, the flap must often be elevated as a double-pedicled flap to maintain good viability.^{10,16} In our series, fat necrosis was found only in single-pedicled flap cases both in the C-flap group and S-flap group. Particularly in the S-flap, the fan-shaped adipose flap does not have subdermal vascular plexus just under skin paddle, which is thought to be an important vascular network.^{17,18} In addition, as previously reported,¹⁹ in zone II of the transverse abdominal flap, the cephalic portion above the umbilicus has a poorer vascular supply. Therefore, it is logical that a double pedicle was required more often in cases of the S-flap reconstruction than in the C-flap recon-

Table 4. Mean Scores of Abdominal Pain and Stiffness, and Patients' Activity

	Sombrero Flap	Conventional Flap	P*
Abdominal pain and stiffness			
Pain at just after surgery	2.25	2.55	0.185
Pain at 6 mo after surgery	3.83	3.64	0.092
Stiffness at 6 mo after surgery	3.44	3.05	0.023*
Patient's activeness			
In daily life at 6 mo after surgery	3.92	3.95	0.584
In light sports at 6 mo after surgery	3.78	3.77	0.894
In hard sports at 6 mo after surgery	3.56	3.59	0.743

*The Mann-Whitney U test.

Bold value indicate statistically significant differences.

struction (52.5% and 27.3%, respectively). Shafiqhi et al.²⁰ reported an extended deep inferior epigastric perforator flap, which is very similar to our S-flap, and emphasized the hemodynamic safety of the cranial adipose flap based on their clinical results even with a single pedicle. This finding is not consistent with our results. However, we examined flap viability by intraoperative indocyanine green angiography in all patients and confirmed poor vascularity in the contralateral half of the adipose flap in many single-pedicle S-flap cases (Fig. 3). (See video, Supplemental Digital Content 1, which displays intraoperative indocyanine green angiogram of the S-flap. With only a single pedicle (right side), the circulation of the adipose flap of the contralateral side was poor, <http://links.lww.com/PRSGO/A287>)

Therefore, we believe a double pedicle to be preferable in most S-flap cases. As other authors have reported, the vascular network in the vertical direction of the transverse abdominal flap is richer than that in the horizontal direction, and direct linking vessels are developed especially in the midline region.²¹⁻²³ We speculate that the viability of the adipose flap of the double-pedicle S-flap is entirely maintained despite the lack of subdermal vascular plexus (Fig. 3). (See video, Supplemental Digital Content 2, which displays adding blood flow from a contralateral pedicle (left side), entire part of the adipose flap became viable, <http://links.lww.com/PRSGO/A288>)

An additional drawback of this method is the high position of the abdominal scar after elevation of the S-flap. In harvesting the narrow S-flap, the abdominal scar must

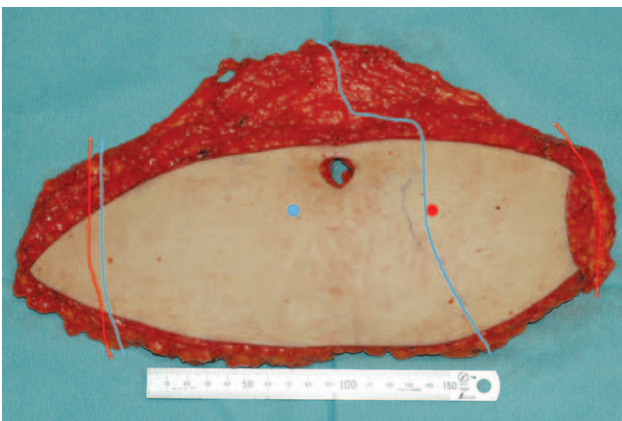




Fig. 3. S-flap. Viability of the S-flap: with only a single pedicle (right side), the adipose flap of the contralateral side had generally poor vascularity. (See video, Supplemental Digital Content 1, which displays intraoperative indocyanine green angiogram of the sombrero-shaped flap. With only a single pedicle (right side), the circulation of the adipose flap of the contralateral side was poor, <http://links.lww.com/PRSGO/A287>) (Blue spot: perforator, blue line: boundary line of adequate flap circulation with single pedicle.) By adding a contralateral pedicle and its perforator, the circulation of the adipose flap of the contralateral side became viable. (See video, Supplemental Digital Content 2, which displays adding blood flow from a contralateral pedicle (left side), entire part of the adipose flap became viable, <http://links.lww.com/PRSGO/A288>). (Red spot: contralateral perforator, red line: new boundary line of adequate flap circulation with double pedicles.)



Video Graphic 1. See video, Supplemental Digital Content 1, which displays intraoperative indocyanine green angiogram of the sombrero-shaped flap. With only a single pedicle (right side), the circulation of the adipose flap of the contralateral side was poor, <http://links.lww.com/PRSGO/A287>.



Video Graphic 2. See video, Supplemental Digital Content 2, which displays adding blood flow from a contralateral pedicle (left side), entire part of the adipose flap became viable, <http://links.lww.com/PRSGO/A288>.

be placed higher than that of the C-flap, which is an inevitable disadvantage of the S-flap. However, the scar is still at a sufficient height to be covered by normal underwear and swimwear, and we think the benefits of the S-flap outweigh this drawback (Fig. 4).

Despite these limitations, we believe this vertical setting with S-flap is very useful for immediate breast reconstruction after SSM in many Asian patients because of its superiority in terms of cosmetic results with reduced postoperative abdominal stiffness. However, considering its indications, the S-flap is not optimal for patients who have breasts with high projection of the B area despite having a very low BMI. In such patients, the adipose flap at the middle of the S-flap is too thin to fill the B area of the breast sufficiently. In such patients, the C-flap should be chosen, and a sufficient volume of deepithelized flap must be inserted into the B area. By contrast, in patients with more body fat who have a good abdominal condition, as are more common in Western populations, a vertically wide

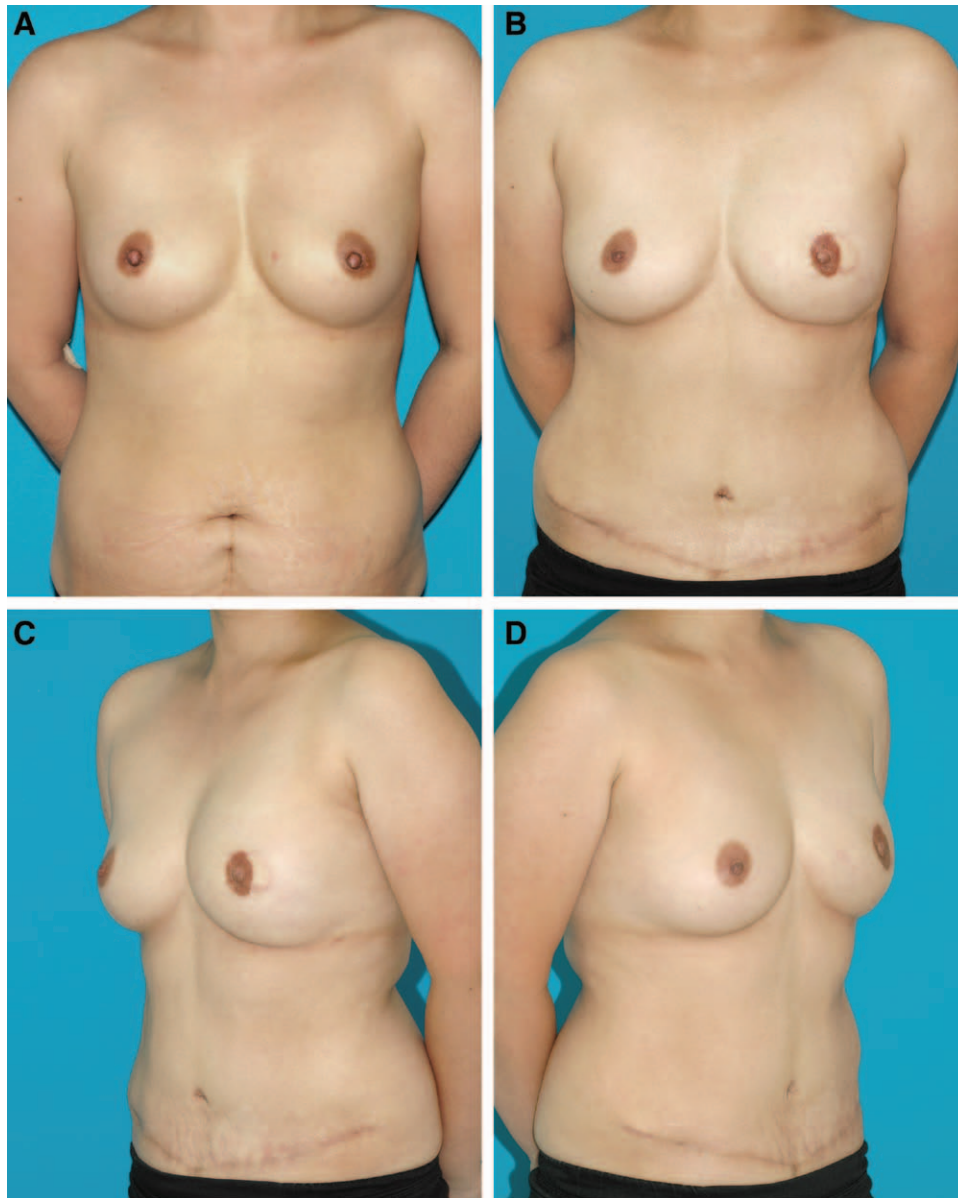

Fig. 4. A, A 40-year-old woman suffered from left breast cancer (BMI was 21.67 kg/m²). She underwent immediate breast reconstruction with vertical setting of an S-flap after SSM. B,C, The images illustrate the patient's appearance 24 months after surgery.

and thick flap can be harvested, and there is no need to use a vertical flap setting. In such cases, the transverse flap setting is superior because it is simple and usually has no need for elevation as a double-pedicle flap. Thus, before breast reconstruction, the surgeon should observe each patient's body and breast type carefully and then select a flap design and setting based on individual characteristics.

CONCLUSIONS

For immediate breast reconstruction after SSM in Asian patients, who tend to have less redundant abdominal skin and thinner subcutaneous tissue than Western counterparts, we developed the vertical flap setting with newly designed abdominal S-flap and

achieved cosmetically good results with low abdominal morbidity. Reliable viability of the S-flap including a medial fan-shaped adipose flap was also indicated, even though double pedicles were often required. However, the S-flap was not superior to the conventional flap under all circumstances and was unfit for slender patients who have breasts with high projection of the B area. The vertical flap setting would be also unnecessary for patients who have a more favorable abdominal condition, as is common in Western populations. To achieve good cosmetic results in all types of patients, the surgeon should observe each patient's body and breast type carefully and select a flap design and setting based on individual characteristics.

Hirokazu Uda, MD

Department of Plastic Surgery
Jichi Medical University
331-1-1 Yakushiji, Shimotuke
Tochigi, 329-0498, Japan
E-mail: uदारare@jichi.ac.jp

REFERENCES

- Carlson GW. Skin sparing mastectomy: anatomic and technical considerations. *Am Surg.* 1996;62:151–155.
- Hidalgo DA. Aesthetic refinement in breast reconstruction: complete skin-sparing mastectomy with autogenous tissue transfer. *Plast Reconstr Surg.* 1998;102:63–70; discussion 71.
- Slavin SA, Schnitt SJ, Duda RB, et al. Skin-sparing mastectomy and immediate reconstruction: oncologic risks and aesthetic results in patients with early-stage breast cancer. *Plast Reconstr Surg.* 1998;102:49–62.
- Foster RD, Esserman LJ, Anthony JP, et al. Skin-sparing mastectomy and immediate breast reconstruction: a prospective cohort study for the treatment of advanced stages of breast carcinoma. *Ann Surg Oncol.* 2002;9:462–466.
- Patani N, Mokbel K. Oncological and aesthetic considerations of skin-sparing mastectomy. *Breast Cancer Res Treat.* 2008;111:391–403.
- Deurenberg P, Deurenberg-Yap M, Guricci S. Asians are different from Caucasians and from each other in their body mass index/body fat per cent relationship. *Obes Rev.* 2002;3:141–146.
- WHO expert consultation. Appropriate body-mass index for Asian populations and its implications for policy and intervention strategies. *Lancet.* 2004;363:157–163.
- Yap YL, Lim J, Yap-Asedillo C, et al. The deep inferior epigastric perforator flap for breast reconstruction: is this the ideal flap for Asian women? *Ann Acad Med Singapore.* 2010;39:680–686.
- Butzelaar L, Soykan EA, Galindo Garre F, et al. Going into surgery: risk factors for hypertrophic scarring. *Wound Repair Regen.* 2015;23:531–537.
- Xu H, Dong J, Wang T. Bipedicle deep inferior epigastric perforator flap for unilateral breast reconstruction: seven years' experience. *Plast Reconstr Surg.* 2009;124:1797–1807.
- Uda H, Tomioka YK, Sarukawa S, et al. Comparison of abdominal wall morbidity between medial and lateral row-based deep inferior epigastric perforator flap. *J Plast Reconstr Aesthet Surg.* 2015;68:1550–1555.
- Uda H, Tomioka YK, Sarukawa S, et al. Abdominal morbidity after single- versus double-pedicled deep inferior epigastric perforator flap use. *J Plast Reconstr Aesthet Surg.* in press.
- OECD. Graph 2.9. Fit or fat? In: *Trends Shaping Education 2013*. Paris: OECD Publishing; 2013. DOI: http://dx.doi.org/10.1787/trends_edu-2013-graph23-en
- Paik JM, Lee KT, Jeon BJ, et al. Donor site morbidity following DIEP flap for breast reconstruction in Asian patients: is it different? *Microsurgery.* 2015;35:596–602.
- Blondeel PN, Hijjawi J, Depypere H, et al. Shaping the breast in aesthetic and reconstructive breast surgery: an easy three-step principle. Part II—Breast reconstruction after total mastectomy. *Plast Reconstr Surg.* 2009;123:794–805.
- Bailey SH, Saint-Cyr M, Wong C, et al. The single dominant medial row perforator DIEP flap in breast reconstruction: three-dimensional perforasome and clinical results. *Plast Reconstr Surg.* 2010;126:739–751.
- Rozen WM, Murray AC, Ashton MW, et al. The cutaneous course of deep inferior epigastric perforators: implications for flap thinning. *J Plast Reconstr Aesthet Surg.* 2009;62:986–990.
- Wong C, Saint-Cyr M, Arbiq G, et al. Three- and four-dimensional computed tomography angiographic studies of commonly used abdominal flaps in breast reconstruction. *Plast Reconstr Surg.* 2009;124:18–27.
- Ohjimi H, Era K, Fujita T, et al. Analyzing the vascular architecture of the free TRAM flap using intraoperative ex vivo angiography. *Plast Reconstr Surg.* 2005;116:106–113.
- Shafiqhi M, Constantinescu MA, Huemer GM, et al. The extended diep flap: extending the possibilities for breast reconstruction with tissue from the lower abdomen. *Microsurgery.* 2013;33:24–31.
- Boyd JB, Taylor GI, Corlett R. The vascular territories of the superior epigastric and the deep inferior epigastric systems. *Plast Reconstr Surg.* 1984;73:1–16.
- Moon HK, Taylor GI. The vascular anatomy of rectus abdominis musculocutaneous flaps based on the deep superior epigastric system. *Plast Reconstr Surg.* 1988;82:815–832.
- Wong C, Saint-Cyr M, Mojallal A, et al. Perforasomes of the DIEP flap: vascular anatomy of the lateral versus medial row perforators and clinical implications. *Plast Reconstr Surg.* 2010;125:772–782.