



Smaller volume of posterior thalamic nuclei in patients with obsessive–compulsive disorder

Jinhyung Jurng^a, Hyungyou Park^b, Taekwan Kim^b, Inkyung Park^b, Sun-Young Moon^{c,d},
Silvia Kyungjin Lho^{c,d,*}, Minah Kim^{c,d,*}, Jun Soo Kwon^{b,c,d,e}

^a Department of Medicine, Seoul National University College of Medicine, Seoul, Republic of Korea

^b Department of Brain and Cognitive Sciences, Seoul National University College of Natural Sciences, Seoul, Republic of Korea

^c Department of Neuropsychiatry, Seoul National University Hospital, Seoul, Republic of Korea

^d Department of Psychiatry, Seoul National University College of Medicine, Seoul, Republic of Korea

^e Institute of Human Behavioral Medicine, SNU-MRC, Seoul, Republic of Korea

ARTICLE INFO

Keywords:

Age of onset
Clinical attribute
Obsessive–compulsive disorder
Subregional volume
Thalamus

ABSTRACT

Aim: Although the thalamus is a key structure in the pathophysiology of obsessive–compulsive disorder (OCD), reports regarding thalamic volume alterations in OCD patients have been inconsistent. Because the thalamus has a complex structure with distinct functions, we investigated subregional volume changes in the thalamus and their relationship with clinical attributes in a large sample of medication-free OCD patients.

Methods: We collected T1-weighted magnetic resonance imaging data from 177 OCD patients and 152 healthy controls (HCs). Using FreeSurfer, we segmented the thalamus into 12 nuclei groups; subregional volumes were compared between groups using an analysis of covariance. The relationships between altered thalamic volumes and OC symptom severity and OCD onset age were investigated.

Results: Compared to HCs, OCD patients showed a smaller volume of the left posterior thalamic nuclei. Other thalamic subregions did not show significant group differences. There was a significant negative correlation between the volume of the left posterior thalamic nuclei and the age of OCD onset but no significant correlation with OC symptom severity.

Conclusions: This is the first study to report reduced volume of the posterior thalamic nuclei in a large sample of medication-free OCD patients. Our results suggest that the volume of posterior thalamic nuclei may reflect different pathophysiological mechanisms of OCD subtypes related to the age of onset. Additional studies with pediatric samples are required to clarify the relationship between thalamic alterations and the onset age of OCD.

1. Introduction

Obsessive-compulsive disorder (OCD) is a psychiatric disorder that significantly lowers the quality of life of patients and is diagnosed in approximately 2.5%–3% of the whole population (Eisen et al., 2006; Robbins et al., 2019). Patients with OCD are bothered by intrusive and undesirable thoughts, impulses, or specific images that are followed by repetitive behaviors to relieve anxiety (Stein et al., 2019). Cortico-striato-thalamo-cortical (CSTC) circuit dysfunction is a pathophysiological model of OCD that explains impairments in self-regulation and behavioral inhibition (Peters et al., 2016; Robbins et al., 2019; Stein et al., 2019). Among the brain regions included in the CSTC circuit, the thalamus plays a crucial role because it has extensive connections with

various brain regions and is involved in both cognitive functions and behavioral patterns (Carrera and Bogousslavsky, 2006; Lacerda et al., 2003; Mori, 2001; Saalman and Kastner, 2015). Although the thalamus is comprised of separate nuclei groups with distinct anatomical locations and neurocognitive functions (Morel, 2007; Sherman, 2007, 2016; Sherman and Guillery, 2002), thalamic subregional disruption in OCD patients has not yet been sufficiently studied.

Several structural magnetic resonance imaging (MRI) studies with relatively small sample sizes have provided inconsistent findings of thalamic volume in adult OCD patients. While many studies have reported intact thalamic structures (Gilbert et al., 2008; Hoexter et al., 2012; Kang et al., 2004; Liu et al., 2019; Valente et al., 2005; Zhang et al., 2019), other studies have observed larger thalamic volumes in

* Corresponding author at: Department of Neuropsychiatry, Seoul National University Hospital, 101 Daehak-no, Chongno-gu, Seoul 03080, Republic of Korea.
E-mail address: verte82@snu.ac.kr (M. Kim).

<https://doi.org/10.1016/j.nicl.2021.102686>

Received 4 February 2021; Received in revised form 15 April 2021; Accepted 17 April 2021

Available online 21 April 2021

2213-1582/© 2021 The Author(s).

Published by Elsevier Inc.

This is an open access article under the CC BY-NC-ND license

(<http://creativecommons.org/licenses/by-nc-nd/4.0/>).

OCD patients (Atmaca et al., 2006; Hou et al., 2013; Kim et al., 2001; Lv et al., 2017; Shaw et al., 2015). Only one study by Tang et al. (2016) has reported smaller thalamic volume in OCD. In addition, mega- and meta-analyses have also been performed: the ENIGMA-OCD working group (Boedhoe et al., 2017) and de Wit et al. (2014) did not reveal statistically significant differences in adult OCD patients. The OCD Brain Imaging Consortium (OBIC) (Fouche et al., 2017) reported that compared to healthy controls (HCs), adult patients with OCD showed a trend toward larger left and smaller right thalamic volumes before correcting for multiple comparisons. These inconsistencies, especially for the studies that used surface-based analyses, may be explained by their measurements of whole thalamic volumes. Whole-thalamic analyses are considered insufficient to detect volume changes that are limited to specific subregions because all subregional volumes are summed and the variation at the subregional level would be relatively subtle (Kwon et al., 2003). Because the thalamus is a complex structure that has different connectivity and function based on the particular subregion, subregional analysis will further help to understand the role of the thalamus in the pathophysiology of OCD (Kong et al., 2020; Stein et al., 2019).

In addition to the inconsistent results regarding thalamic volume, its relationship to clinical attributes are also unclear despite the importance of the thalamus in OCD pathophysiology. Studies examining the association between OC symptom severity and thalamic volume in OCD patients have shown inconsistent results. Some studies did not report the association (Christian et al., 2008; Hoexter et al., 2012; Kang et al., 2004; Lv et al., 2017), while others observed positive (Atmaca et al., 2007; 2016; 2018;; Hou et al., 2013) or negative (Hirose et al., 2017; Valente et al., 2005; Zarei et al., 2011) correlations between thalamic volume and OC symptom severity. Furthermore, there is a need to investigate the relationship between thalamic volume and the age of OCD onset, which has been reported to have associations with some clinical features (Kim et al., 2020; Robbins et al., 2019; Taylor, 2011). Structural MRI studies, including our previous study, have found relationships between the age of onset and volume of several brain regions in adult OCD patients (Boedhoe et al., 2017; 2018;; Exner et al., 2012; Kim et al., 2020). Considering these prior results, age of onset may also be associated with thalamic volumes. Since it is still unclear whether clinical attributes, such as OC symptom severity and age of onset, are associated with thalamic subregional volumes in OCD patients, this relationship needs to be clarified with a large sample of medication-free OCD patients.

In the present study, we aimed to investigate volumetric alterations in thalamic subregions in a large sample of medication-free adult OCD patients. We hypothesized that OCD patients, compared to HCs, would exhibit volume differences in thalamic subregions. In addition, we hypothesized that there would be an association of thalamic volume with clinical attributes such as OC symptom severity or onset age in OCD patients. In particular, we expected that earlier age of onset would be associated with larger thalamic subregional volume in adult OCD patients, considering consistently reported larger thalamic volumes in pediatric OCD studies (Boedhoe et al., 2017; Gilbert et al., 2000; Rosenberg et al., 2000; Weeland et al., 2020).

2. Material and methods

2.1. Subjects

A total of 177 medication-free adult OCD patients and 152 HCs participated in this study. T1 MRI data of 101 OCD patients and 103 HCs were used in our previous study (Kim et al., 2020). The age range of the participants was between 17 and 45 years in both the OCD and HC groups. All participants with OCD were recruited from the inpatient and outpatient clinics at the Department of Neuropsychiatry in the Seoul National University Hospital (SNUH) and were diagnosed with OCD according to the Diagnostic and Statistical Manual of Mental Disorders, fourth edition (DSM-IV) criteria. Among the OCD patients, 78 patients

were drug-naïve, and 99 patients had been unmedicated for more than 4 weeks before MRI acquisition. For the psychiatric comorbidities, 6 OCD patients had a diagnosed comorbidity of major depressive disorder; 2 patients had dysthymic disorder; 41 patients had depressive disorder, not otherwise specified (NOS); 2 patients had bipolar II disorder; 3 patients had bipolar disorder, NOS; 4 patients had tic disorder; and 7 patients had personality disorders. The Yale-Brown Obsessive Compulsive Scale (Y-BOCS) (Padhi et al., 2010), Hamilton Rating Scale for Anxiety (HAM-A) (Thompson, 2015), and Hamilton Rating Scale for Depression (HAM-D) (Orbell et al., 2013) were used for the assessment of psychiatric symptom severity. HCs were recruited via internet advertisement, and they were shown not to have a lifetime history of psychiatric disorder after screening using the Structured Clinical Interview for the Diagnostic and Statistical Manual of Mental Disorders, Fourth Edition, Axis I disorders Nonpatient Edition (SCID-NP). The HCs were excluded if they had a family member with a psychotic disorder among third-degree relatives. The exclusion criteria for all participants were a lifetime history of neurological disorders, clinically severe head trauma, substance use disorder (except nicotine), and intellectual disability (intelligence quotient [IQ] < 70).

Written informed consent was received from all participants after they were given a thorough explanation of the study procedure (IRB nos. H-1201-008-392, H-1110-009-380, and H-1503-045-655). For the minors, informed consent was obtained from both the participants themselves and their parents. This study was conducted in accordance with the Declaration of Helsinki and was approved by the Institutional Review Board of SNUH (IRB no. H-2012-162-1184).

2.2. Image acquisition

T1-weighted images of all participants were obtained at SNUH using a 3 T MRI scanner (MAGNETOM Trio, Siemens, München, Germany) and 12-channel head coil, with imaging parameters of echo time = 1.89 ms, repetition time = 1670 ms, flip angle = 9°, voxel size = 1.0 × 1.0 × 1.0 mm³, and 208 slices. To reduce motion artifacts, we used head cushions and instructed participants to minimize their movements.

2.3. Thalamic segmentation

The acquired images were automatically processed using FreeSurfer version 7.1 (<http://surfer.nmr.mgh.harvard.edu/>). The processing pipeline included motion correction, signal intensity normalization, automated Talairach transformation, removal of nonbrain tissue, automated topology correction, cortical parcellation and subcortical segmentation (Collins et al., 1994; Dale et al., 1999; Fischl and Dale, 2000; Fischl et al., 1999a; 1999b; 2002; 2004). Estimated total intracranial volume (eTIV) data were obtained by exploiting the relationship between intracranial volume (ICV) and the linear transform to Talairach space (Buckner et al., 2004). Then, thalamic segmentation was performed using Bayesian interference based on a probabilistic atlas derived from ex vivo MRI and histologic data (Iglesias et al., 2018).

The output provided a volume of 25 regions of interest (ROIs) for both the right and left thalamus. To validate thalamic segmentation, the results of each thalamic segment were visually inspected by independent researchers (i.e., J.J. and H.P.). In addition, statistical outliers were determined when a subject's thalamic subregional volume was 3 standard deviations away from the mean of each thalamic subregional volume. Supplementary Fig. 1 in the supplementary material presents the volume distribution of the individual thalamic nuclei groups with their statistical outliers, which were few in number, and none of them were excluded from the analysis. We summed the volume of each nucleus to calculate the volume of the following nuclei groups: anterior, lateral, ventral, intralaminar, medial, and posterior parts. Nuclei groups are shown in Fig. 1. The individual nuclei that comprised each group were based on the atlas that Iglesias et al. (2018) provided, and they are shown in Supplementary Table 1 in the supplementary material.

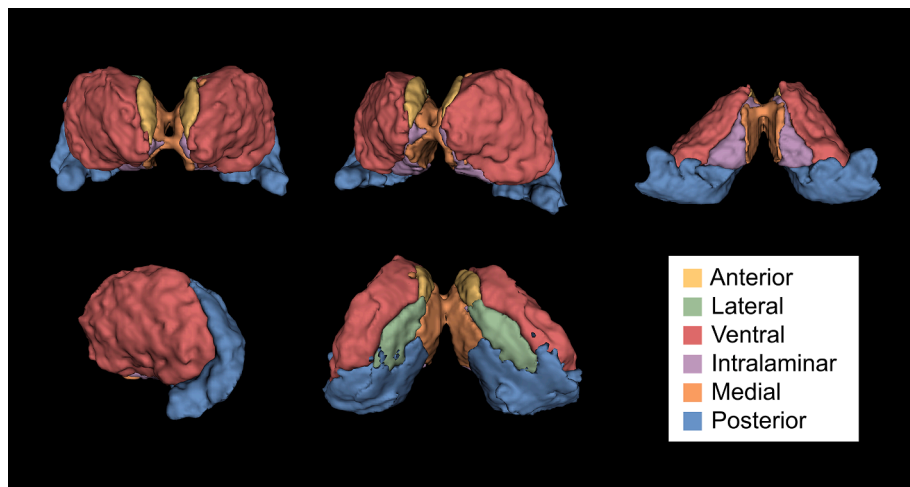


Fig. 1. A 3D view of the thalamic nuclei groups obtained from thalamic segmentation.

2.4. Statistical analyses

All statistical analyses were conducted using IBM SPSS Statistics 26 (SPSS, Inc., Chicago, IL, USA). To compare demographic and clinical data between the OCD patients and HCs, we performed independent *t*-tests and chi-square tests. Then, we conducted one-way analysis of covariance (ANCOVA) with age, sex, and eTIV as covariates to investigate group differences in thalamic subregional volumes. We applied Bonferroni correction to address the issue of multiple ANCOVA tests. For the thalamic subregion that had a significant volumetric difference, partial correlation analyses were performed to examine the relationship between thalamic volumes and Y-BOCS scores in the OCD patients, controlling for HAM-A and HAM-D scores. For the same subregion, we also performed Pearson’s correlation analysis between the volume and age of onset in the OCD group.

3. Results

There were no significant differences in the demographic data of the OCD patients and HCs. The demographic and clinical characteristics of the participants are described in Table 1. For the patients, the mean

Table 1 Demographic and clinical characteristics of patients with obsessive–compulsive disorder (OCD) and healthy controls (HCs).

	OCD (n = 177)	HCs (n = 152)	Statistical analyses ^a	
			T/ χ^2	P
Age (years)	25.1 ± 7.0	24.1 ± 6.1	1.372	0.176
Sex (male/female)	119/58	100/52	0.076	0.782
IQ	110.9 ± 11.6	112.8 ± 11.9	-1.403	0.162
Handedness (left/right) ^b	13/150	12/140	0.001	0.979
Education (years)	14.1 ± 2.2	14.7 ± 1.7	0.327	0.748
Duration of illness (years)	6.7 ± 5.6	NA	-	-
Age of onset (years)	18.4 ± 6.7	NA	-	-
Y-BOCS				
Total score	25.2 ± 6.5	NA	-	-
Obsession score	13.4 ± 3.4	NA	-	-
Compulsion score	11.8 ± 4.2	NA	-	-
HAM-A score	9.8 ± 5.9	NA	-	-
HAM-D score	10.7 ± 6.4	NA	-	-

Abbreviations: IQ, intelligence quotient; Y-BOCS, Yale-Brown Obsessive Compulsive Scale; HAM-A, Hamilton Rating Scale for Anxiety; HAM-D, Hamilton Rating Scale for Depression.

^a Independent *t*-tests for continuous variables, chi-square tests for categorical variables.

^b Data was missing from 14 participants in the OCD group.

duration of illness (DOI) was 6.71 years, and the mean age of onset was 18.37 years. The mean Y-BOCS total score of the patients was 25.18.

The volumes of the left posterior nuclei ($F = 8.431, p = 0.004$) and right anterior nuclei ($F = 5.333, p = 0.022$) of the thalamus were smaller in the OCD patients than in the HCs. However, only the left posterior thalamic nuclei (Bonferroni-corrected $p = 0.048$) showed statistical significance after multiple comparison corrections (Table 2 and Fig. 2). There was no significant group by age interaction ($F = 0.898, p = 0.344$) for the left posterior thalamic nuclei. However, a significant group by sex interaction ($F = 10.098, p = 0.002$) and a group by eTIV interaction ($F = 65.168, p < 0.001$) was observed for the left posterior thalamic nuclei. The exploratory group comparison results of the volume of the individual nuclei comprising the left posterior thalamic subregion revealed that the patients with OCD showed smaller volumes in the

Table 2 Volumes of thalamic nuclei groups in patients with obsessive–compulsive disorder (OCD) and healthy controls (HCs).

Thalamic nuclei group	OCD (n = 177)	HC (n = 152)	Statistical analyses ^a		
			F	Uncorrected P	Bonferroni-corrected P
Left					
Anterior	147.5 ± 18.7	149.5 ± 20.4	2.739	0.099	1.000
Lateral	180.1 ± 26.1	180.0 ± 22.4	0.125	0.724	1.000
Ventral	3294.2 ± 330.9	3310.6 ± 328.9	2.571	0.110	1.000
Intralaminar	469.3 ± 52.1	474.9 ± 50.5	3.806	0.052	0.624
Medial	1240.0 ± 138.0	1245.1 ± 141.8	0.092	0.762	1.000
Posterior	2318.2 ± 243.6	2367.1 ± 235.5	8.431	0.004	0.048
Right					
Anterior	153.0 ± 21.7	156.2 ± 20.8	5.333	0.022	0.264
Lateral	181.5 ± 25.7	181.2 ± 25.2	0.010	0.921	1.000
Ventral	3394.2 ± 367.2	3410.5 ± 340.6	1.789	0.182	1.000
Intralaminar	487.7 ± 57.9	492.2 ± 54.3	2.227	0.137	1.000
Medial	1283.7 ± 141.5	1286.5 ± 141.2	0.016	0.900	1.000
Posterior	2858.9 ± 312.5	2855.4 ± 283.2	0.273	0.602	1.000

^a Analysis of covariance with age, sex, and estimated total intracranial volume as covariates.

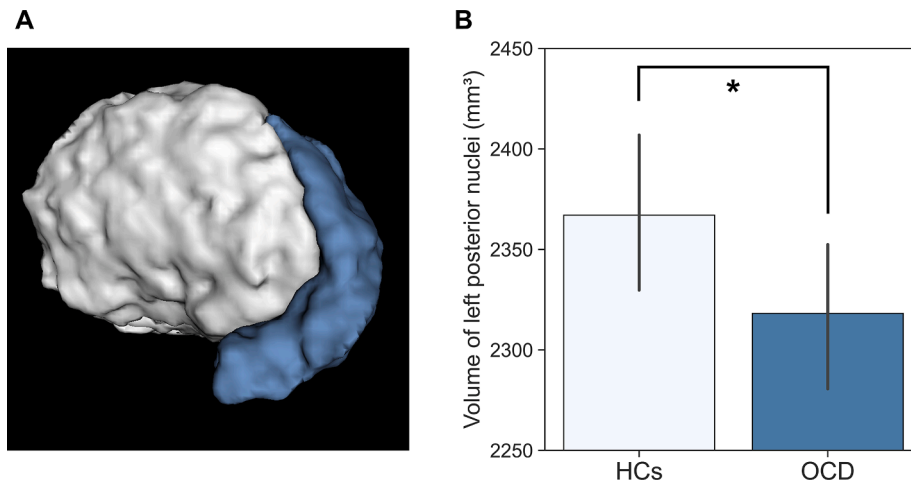


Fig. 2. Volume of left posterior thalamic nuclei was smaller in patients with obsessive-compulsive disorder (OCD) than healthy controls (HCs). (A) Left posterior thalamic nuclei is shown in blue. (B) Bar chart shows the volume of the left posterior thalamic nuclei in OCD patients and HCs, controlling for age, sex, and estimated total intracranial volume.

pulvinar, lateral geniculate nucleus (LGN), and medial geniculate nucleus (MGN) subregions than the HCs (Supplementary Table 2). The whole thalamic volumes of the left and right hemispheres were not significantly different between the OCD and HC groups (Supplementary Table 3).

As shown in Fig. 3, there was a negative correlation between the left posterior thalamic volume and age of onset ($r = -0.223$, Bonferroni-corrected $p = 0.012$). However, we found no significant correlation between thalamic volume and Y-BOCS scores.

4. Discussion

In the present study, we investigated volume differences in the thalamus at the subregional level in a large sample of medication-free OCD patients using atlas-based automatic segmentation. We observed that the volume of the left posterior thalamic nuclei was smaller in the

OCD patients than in the HCs. This region consists of the pulvinar, lateral geniculate nucleus (LGN), medial geniculate nucleus (MGN), and suprageniculate nucleus. Furthermore, a smaller volume of the left posterior thalamic nuclei was related to later onset of disease. To our knowledge, this is the first study to report volume alterations in a specific thalamic subregion and their relationship with the age of onset in OCD patients.

Among the regions that showed differences in the OCD patients compared to the HCs, we focused mostly on pulvinar, one of the higher-order thalamic nuclei that constitutes approximately one-third of the whole thalamus (Sherman, 2007). The pulvinar has widespread connections to several regions: superior colliculus and visual cortices, inferior parietal and prefrontal cortices, several association areas, amygdala, and cingulate cortex (Benarroch, 2015). Hence, it not only plays a critical role in visual processing, such as exploring, coding, and modulating the transmission of visual information (Halassa and Kastner, 2017; Petersen et al., 1987; Purushothaman et al., 2012; Robinson and Petersen, 1992; Saalman and Kastner, 2011; Zhou et al., 2016), but also is involved in attention and salience (Robinson and Petersen, 1992; Saalman et al., 2012; Zhou et al., 2016), which are frequently impaired in OCD patients (Abramovitch et al., 2012; de Geus et al., 2007; Hollander et al., 1990; Muller and Roberts, 2005; Shin et al., 2014; Tukul et al., 2012; Viard et al., 2005; Yovel et al., 2005). In addition, deformity (Kang et al., 2008; Shaw et al., 2015) and altered functional activity (Viard et al., 2005) of the pulvinar in OCD patients have been observed in previous studies. Thus, the altered volume of pulvinar found in the current study may be related to dysfunctional visuospatial memory and abnormal attention accompanied by OCD.

In addition to the pulvinar, the left posterior thalamic nuclei, which showed significantly smaller volumes in the OCD patients in the current study, also includes the LGN and MGN regions, which are well known for directly receiving sensory information from the periphery. The LGN is not only understood to be a gateway for the visual pathway (Usrey and Alitto, 2015) but also known to be involved in the modulation of attentional responses to visual stimuli (Kastner et al., 2004; O'Connor et al., 2002). Therefore, structural alterations in the LGN may also be related to abnormalities in visuospatial dysfunction in OCD patients (Hollander et al., 1990; Shin et al., 2014; Tukul et al., 2012; Viard et al., 2005; Yovel et al., 2005). In addition, the MGN is another well-known relay center for auditory information (Henkel, 2018). However, since there are only a handful of studies that observed auditory dysfunction in OCD patients, more research is required to examine the association between the MGN and OCD pathophysiology.

One interesting point is that while the smaller volume of the left

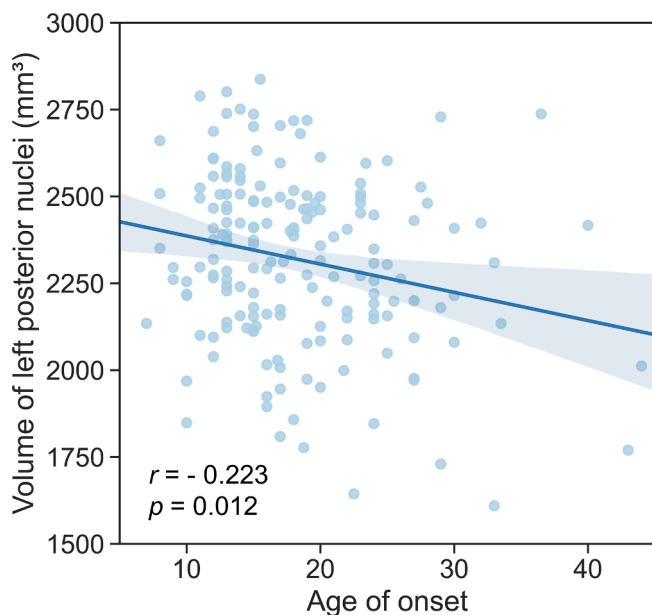


Fig. 3. Correlation analysis between the volume of the thalamic subregion and age of onset in patients with obsessive-compulsive disorder (OCD). The volume of left posterior thalamic nuclei was negatively correlated with age of onset in OCD patients.

posterior thalamic nuclei had no correlation with OC symptom severity, it was significantly associated with a later age of onset. These findings may suggest that the left posterior thalamic nuclei are neural substrates that underlie the pathophysiology of OCD related to the age of onset rather than the current symptom severity, which fluctuates with time. Furthermore, our results support prior studies that have reported relationships between the volume of brain structures and age of onset in OCD patients (Boedhoe et al., 2017; Exner et al., 2012; Kim et al., 2020; Koprivova et al., 2009). The ENIGMA-OCD working group (Boedhoe et al., 2017) reported that early-onset patients had a larger pallidum, while late-onset patients had a smaller hippocampus, than controls. In addition, Kim et al. (2020) found larger volumes of several cortical areas in early-onset OCD patients, suggesting biological evidence for clinical and neurocognitive differences related to age of onset. Other studies have also reported cortical volumetric differences related to the onset age (Exner et al., 2012; Koprivova et al., 2009).

This study has several limitations. First, since our MRI resolution (i. e., 3 T) was suboptimal for accurate segmentation of individual thalamic nuclei to the smallest level, we calculated and analyzed the volumes of the nuclei groups. Second, the segmentation pipeline used in this study relies on a probabilistic algorithm that produces a degree of uncertainty to a quality of thalamic segmentation. Although we performed a thorough visual inspection of the segmentation results and checked the statistical outliers to confirm the quality of the segmentation results, the current study results should be interpreted with caution regarding the limitation of the segmentation pipeline. Third, information on symptom dimensions was not provided in the current study, which makes it hard to draw relevant conclusions about the neurobiological correlates of symptom heterogeneity in OCD. Fourth, although we suggested an association between thalamic subregional volume and age of onset, our sample included adult patients whose age of onset was older than that of pediatric OCD patients. Because many previous studies regarding the onset age of OCD included pediatric participants with earlier onset than our participants, future studies that include pediatric OCD patients are needed to confirm the results of the current study.

5. Conclusions

To our knowledge, this is the first study that investigated thalamic subregional volumes in a large sample of medication-free OCD patients. The present study observed that OCD patients had a smaller volume of the left posterior thalamic nuclei than HCs, which might be related to impaired neurocognitive functions in individuals with OCD. In addition, our results indicate that the volume of the posterior thalamic nuclei in OCD patients may reflect the different pathophysiological mechanisms of OCD related to the age of onset. Future studies with pediatric samples would help to clarify the relationship between thalamic alterations and onset age.

Funding

This study was supported by the Basic Research Laboratory Program and the Basic Science Research Program through the National Research Foundation of Korea (NRF) (Grant nos. 2018R1A4A1025891 and 2019R1A2B5B03100844).

CRediT authorship contribution statement

Jinhyung Jurng: Conceptualization, Methodology, Formal analysis, Data curation, Writing - original draft, Visualization. **Hyungyou Park:** Formal analysis, Investigation, Data curation, Writing - review & editing, Visualization. **Taekwan Kim:** Investigation, Writing - review & editing. **Inkyung Park:** Investigation, Writing - review & editing. **Sun-Young Moon:** Investigation, Writing - review & editing. **Silvia Kyungjin Lho:** Investigation, Writing - review & editing. **Minah Kim:** Conceptualization, Methodology, Writing - review & editing,

Supervision, Project administration. **Jun Soo Kwon:** Conceptualization, Methodology, Writing - review & editing, Supervision, Project administration.

Declaration of Competing Interest

The authors declare that they have no known competing financial interests or personal relationships that could have appeared to influence the work reported in this paper.

Appendix A. Supplementary data

Supplementary data to this article can be found online at <https://doi.org/10.1016/j.nicl.2021.102686>.

References

- Abramovitch, A., Dar, R., Hermesh, H., Schweiger, A., 2012. Comparative neuropsychology of adult obsessive-compulsive disorder and attention deficit/hyperactivity disorder: implications for a novel executive overload model of OCD. *J. Neuropsychol.* 6, 161–191. <https://doi.org/10.1111/j.1748-6653.2011.02021.x>.
- Atmaca, M., Mermi, O., Yildirim, H., Gurok, M.G., 2016. Orbito-frontal cortex and thalamus volumes in obsessive-compulsive disorder before and after pharmacotherapy. *Brain Imaging Behav.* 10, 669–674. <https://doi.org/10.1007/s11682-015-9426-0>.
- Atmaca, M., Yildirim, B.H., Ozdemir, B.H., Aydin, B.A., Tezcan, A.E., Ozler, A.S., 2006. Volumetric MRI assessment of brain regions in patients with refractory obsessive-compulsive disorder. *Prog. Neuropsychopharmacol. Biol. Psychiatry* 30, 1051–1057. <https://doi.org/10.1016/j.pnpbp.2006.03.033>.
- Atmaca, M., Yildirim, H., Ozdemir, H., Tezcan, E., Poyraz, A.K., 2007. Volumetric MRI study of key brain regions implicated in obsessive-compulsive disorder. *Prog. Neuropsychopharmacol. Biol. Psychiatry* 31, 46–52. <https://doi.org/10.1016/j.pnpbp.2006.06.008>.
- Atmaca, M., Yildirim, H., Yilmaz, S., Caglar, N., Mermi, O., Korkmaz, S., Akaslan, U., Gurok, M.G., Kekilli, Y., Turkcapar, H., 2018. Orbito-frontal cortex and thalamus volumes in the patients with obsessive-compulsive disorder before and after cognitive behavioral therapy. *Int. J. Psychiatry Med.* 53, 243–255. <https://doi.org/10.1177/0091217415621038>.
- Benarroch, E.E., 2015. Pulvinar: associative role in cortical function and clinical correlations. *Neurology* 84, 738–747. <https://doi.org/10.1212/WNL.0000000000001276>.
- Boedhoe, P.S., Schmaal, L., Abe, Y., Ameis, S.H., Arnold, P.D., Batistuzzo, M.C., Benedetti, F., Beucke, J.C., Bolletini, I., Bose, A., Brem, S., Calvo, A., Cheng, Y., Cho, K.I., Dall'aspezia, S., Denys, D., Fitzgerald, K.D., Fouché, J.P., Gimenez, M., Gruner, P., Hanna, G.L., Hibar, D.P., Hoexter, M.Q., Hu, H., Huyser, C., Ikari, K., Jahanshad, N., Kathmann, N., Kaufmann, C., Koch, K., Kwon, J.S., Lazaro, L., Liu, Y., Lochner, C., Marsh, R., Martinez-Zalacain, I., Mataix-Cols, D., Menchon, J.M., Minuzzi, L., Nakamae, T., Nakao, T., Narayanaswamy, J.C., Piras, F., Piras, F., Pittenger, C., Reddy, Y.C., Sato, J.R., Simpson, H.B., Soreni, N., Soriano-Mas, C., Spalletta, G., Stevens, M.C., Szeszko, P.R., Tolin, D.F., Venkatasubramanian, G., Walitza, S., Wang, Z., van Wingen, G.A., Xu, J., Xu, X., Yun, J.Y., Zhao, Q., ENIGMA OCD Working Group, Thompson, P.M., Stein, D.J., van den Heuvel, O.A., 2017. Distinct subcortical volume alterations in pediatric and adult OCD: a worldwide meta- and mega-analysis. *Am. J. Psychiatry* 174, 60–69. doi: 10.1176/appi.ajp.2016.16020201.
- Boedhoe, P.S.W., Schmaal, L., Abe, Y., Alonso, P., Ameis, S.H., Anticevic, A., Arnold, P.D., Batistuzzo, M.C., Benedetti, F., Beucke, J.C., Bolletini, I., Bose, A., Brem, S., Calvo, A., Calvo, R., Cheng, Y., Cho, K.I.K., Ciullo, V., Dall'aspezia, S., Denys, D., Feusner, J.D., Fitzgerald, K.D., Fouché, J.P., Fridgeirsson, E.A., Gruner, P., Hanna, G.L., Hibar, D.P., Hoexter, M.Q., Hu, H., Huyser, C., Jahanshad, N., James, A., Kathmann, N., Kaufmann, C., Koch, K., Kwon, J.S., Lazaro, L., Lochner, C., Marsh, R., Martinez-Zalacain, I., Mataix-Cols, D., Menchon, J.M., Minuzzi, L., Morer, A., Nakamae, T., Nakao, T., Narayanaswamy, J.C., Nishida, S., Nurmi, E., O'Neill, J., Piacentini, J., Piras, F., Piras, F., Reddy, Y.C.J., Reess, T.J., Sakai, Y., Sato, J.R., Simpson, H.B., Soreni, N., Soriano-Mas, C., Spalletta, G., Stevens, M.C., Szeszko, P.R., Tolin, D.F., van Wingen, G.A., Venkatasubramanian, G., Walitza, S., Wang, Z., Yun, J.Y., ENIGMA OCD Working Group, Thompson, P.M., Stein, D.J., van den Heuvel, O.A., 2018. Cortical abnormalities associated with pediatric and adult obsessive-compulsive disorder: findings from the ENIGMA obsessive-compulsive disorder working group. *Am. J. Psychiatry* 175, 453–462. doi: 10.1176/appi.ajp.2017.17050485.
- Buckner, R.L., Head, D., Parker, J., Fotenos, A.F., Marcus, D., Morris, J.C., Snyder, A.Z., 2004. A unified approach for morphometric and functional data analysis in young, old, and demented adults using automated atlas-based head size normalization: reliability and validation against manual measurement of total intracranial volume. *Neuroimage* 23, 724–738. <https://doi.org/10.1016/j.neuroimage.2004.06.018>.
- Carrera, E., Bogousslavsky, J., 2006. The thalamus and behavior: effects of anatomically distinct strokes. *Neurology* 66, 1817–1823. <https://doi.org/10.1212/01.wnl.0000219679.95223.4c>.
- Christian, C.J., Lencz, T., Robinson, D.G., Burdick, K.E., Ashtari, M., Malhotra, A.K., Betensky, J.D., Szeszko, P.R., 2008. Gray matter structural alterations in obsessive-

- compulsive disorder: relationship to neuropsychological functions. *Psychiatry Res.* 164, 123–131. <https://doi.org/10.1016/j.psychres.2008.03.005>.
- Collins, D.L., Neelin, P., Peters, T.M., Evans, A.C., 1994. Automatic 3D intersubject registration of MR volumetric data in standardized Talairach space. *J. Comput. Assist. Tomogr.* 18, 192–205. <https://doi.org/10.1097/00004728-199403000-00005>.
- Dale, A.M., Fischl, B., Sereno, M.I., 1999. Cortical surface-based analysis. I. Segmentation and surface reconstruction. *Neuroimage* 9, 179–194. <https://doi.org/10.1006/nimg.1998.0395>.
- de Geus, F., Denys, D.A., Sitskoorn, M.M., Westenberg, H.G., 2007. Attention and cognition in patients with obsessive-compulsive disorder. *Psychiatry Clin. Neurosci.* 61, 45–53. <https://doi.org/10.1111/j.1440-1819.2007.01609.x>.
- de Wit, S.J., Alonso, P., Schweren, L., Mataix-Cols, D., Lochner, C., Menchon, J.M., Stein, D.J., Fouché, J.P., Soriano-Mas, C., Sato, J.R., Hoexter, M.Q., Denys, D., Nakamae, T., Nishida, S., Kwon, J.S., Jang, J.H., Busatto, G.F., Cardoner, N., Cath, D.C., Fukui, K., Jung, W.H., Kim, S.N., Miguel, E.C., Narumoto, J., Phillips, M.L., Pujol, J., Remijnse, P.L., Sakai, Y., Shin, N.Y., Yamada, K., Veltman, D.J., van den Heuvel, O.A., 2014. Multicenter voxel-based morphometry mega-analysis of structural brain scans in obsessive-compulsive disorder. *Am. J. Psychiatry* 171, 340–349. <https://doi.org/10.1176/appi.ajp.2013.13040574>.
- Eisen, J.L., Mancebo, M.A., Pinto, A., Coles, M.E., Pagano, M.E., Stout, R., Rasmussen, S.A., 2006. Impact of obsessive-compulsive disorder on quality of life. *Compr. Psychiatry* 47, 270–275. <https://doi.org/10.1016/j.comppsych.2005.11.006>.
- Exner, C., Zetsche, U., Martin, V., Rief, W., Jansen, A., 2012. Regional gray matter changes in obsessive-compulsive disorder: relationship to clinical characteristics. *Psychiatry Res.* 202, 74–76. <https://doi.org/10.1016/j.psychres.2011.10.007>.
- Fischl, B., Dale, A.M., 2000. Measuring the thickness of the human cerebral cortex from magnetic resonance images. *Proc. Natl. Acad. Sci. U. S. A.* 97, 11050–11055. <https://doi.org/10.1073/pnas.200033797>.
- Fischl, B., Salat, D.H., Busa, E., Albert, M., Dieterich, M., Haselgrove, C., van der Kouwe, A., Killiany, R., Kennedy, D., Klaveness, M., Montillo, A., Makris, N., Rosen, B., Dale, A.M., 2002. Whole brain segmentation: automated labeling of neuroanatomical structures in the human brain. *Neuron* 33, 341–355. [https://doi.org/10.1016/s0896-6273\(02\)00569-x](https://doi.org/10.1016/s0896-6273(02)00569-x).
- Fischl, B., Sereno, M.I., Dale, A.M., 1999a. Cortical surface-based analysis. II: inflation, flattening, and a surface-based coordinate system. *Neuroimage* 9, 195–207. <https://doi.org/10.1006/nimg.1998.0396>.
- Fischl, B., Sereno, M.I., Tootell, R.B., Dale, A.M., 1999b. High-resolution intersubject averaging and a coordinate system for the cortical surface. *Hum. Brain Mapp.* 8, 272–284. [https://doi.org/10.1002/\(sici\)1097-0193\(1999\)8:4<272::aid-hbm10>3.0.co;2-4](https://doi.org/10.1002/(sici)1097-0193(1999)8:4<272::aid-hbm10>3.0.co;2-4).
- Fischl, B., van der Kouwe, A., Destrieux, C., Halgren, E., Segonne, F., Salat, D.H., Busa, E., Seidman, L.J., Goldstein, J., Kennedy, D., Caviness, V., Makris, N., Rosen, B., Dale, A.M., 2004. Automatically parcellating the human cerebral cortex. *Cereb. Cortex* 14, 11–22. <https://doi.org/10.1093/cercor/bhg087>.
- Fouché, J.P., du Plessis, S., Hattigh, C., Roos, A., Lochner, C., Soriano-Mas, C., Sato, J.R., Nakamae, T., Nishida, S., Kwon, J.S., Jung, W.H., Mataix-Cols, D., Hoexter, M.Q., Alonso, P., OCD Brain Imaging Consortium, de Wit, S.J., Veltman, D.J., Stein, D.J., van den Heuvel, O.A., 2017. Cortical thickness in obsessive-compulsive disorder: multisite mega-analysis of 780 brain scans from six centres. *Br. J. Psychiatry* 210, 67–74. doi: 10.1192/bjp.115.164020.
- Gilbert, A.R., Mataix-Cols, D., Almeida, J.R., Lawrence, N., Nutche, J., Diwadkar, V., Keshavan, M.S., Phillips, M.L., 2008. Brain structure and symptom dimension relationships in obsessive-compulsive disorder: a voxel-based morphometry study. *J. Affect. Disord.* 109, 117–126. <https://doi.org/10.1016/j.jad.2007.12.223>.
- Gilbert, A.R., Moore, G.J., Keshavan, M.S., Paulson, L.A., Narula, V., Mac Master, F.P., Stewart, C.M., Rosenberg, D.R., 2000. Decrease in thalamic volumes of pediatric patients with obsessive-compulsive disorder who are taking paroxetine. *Arch. Gen. Psychiatry* 57, 449–456. <https://doi.org/10.1001/archpsyc.57.5.449>.
- Halassa, M.M., Kastner, S., 2017. Thalamic functions in distributed cognitive control. *Nat. Neurosci.* 20, 1669–1679. <https://doi.org/10.1038/s41593-017-0020-1>.
- Henkel, C.K., 2018. The auditory system, in: Haines, D.E., Mihailoff, G.A. (Eds.), *Fundamental Neuroscience for Basic and Clinical Applications*. Elsevier, Philadelphia, PA, pp. 306–319.e1.
- Hirose, M., Hirano, Y., Nemoto, K., Sutoh, C., Asano, K., Miyata, H., Matsumoto, J., Nakazato, M., Matsumoto, K., Masuda, Y., Iyo, M., Shimizu, E., Nakagawa, A., 2017. Relationship between symptom dimensions and brain morphology in obsessive-compulsive disorder. *Brain Imaging Behav.* 11, 1326–1333. <https://doi.org/10.1007/s11682-016-9611-9>.
- Hoexter, M.Q., de Souza Duran, F.L., D'Alcante, C.C., Dougherty, D.D., Shavitt, R.G., Lopes, A.C., Diniz, J.B., Deckersbach, T., Batistuzzo, M.C., Bressan, R.A., Miguel, E.C., Busatto, G.F., 2012. Gray matter volumes in obsessive-compulsive disorder before and after fluoxetine or cognitive-behavior therapy: a randomized clinical trial. *Neuropsychopharmacology* 37, 734–745. <https://doi.org/10.1038/npp.2011.250>.
- Hollander, E., Schifman, E., Cohen, B., Rivera-Stein, M.A., Rosen, W., Gorman, J.M., Fyer, A.J., Papp, L., Liebowitz, M.R., 1990. Signs of central nervous system dysfunction in obsessive-compulsive disorder. *Arch. Gen. Psychiatry* 47, 27–32. <https://doi.org/10.1001/archpsyc.1990.01810130029005>.
- Hou, J., Song, L., Zhang, W., Wu, W., Wang, J., Zhou, D., Qu, W., Guo, J., Gu, S., He, M., Xie, B., Li, H., 2013. Morphologic and functional connectivity alterations of corticostriatal and default mode network in treatment-naive patients with obsessive-compulsive disorder. *PLoS One* 8, e83931. <https://doi.org/10.1371/journal.pone.0083931>.
- Iglesias, J.E., Insausti, R., Lerma-Usabiaga, G., Bocchetta, M., van Leemput, K., Greve, D.N., van der Kouwe, A., Initiative, A.D.N., Fischl, B., Caballero-Gaudes, C., Paz-Alonso, P.M., 2018. A probabilistic atlas of the human thalamic nuclei combining ex vivo MRI and histology. *Neuroimage* 183, 314–326. <https://doi.org/10.1016/j.neuroimage.2018.08.012>.
- Kang, D.H., Kim, J.J., Choi, J.S., Kim, Y.I., Kim, C.W., Youn, T., Han, M.H., Chang, K.H., Kwon, J.S., 2004. Volumetric investigation of the frontal-subcortical circuitry in patients with obsessive-compulsive disorder. *J. Neuropsychiatry Clin. Neurosci.* 16, 342–349. <https://doi.org/10.1176/jnp.16.3.342>.
- Kang, D.H., Kim, S.H., Kim, C.W., Choi, J.S., Jang, J.H., Jung, M.H., Lee, J.M., Kim, S.I., Kwon, J.S., 2008. Thalamus surface shape deformity in obsessive-compulsive disorder and schizophrenia. *Neuroreport* 19, 609–613. <https://doi.org/10.1097/WNR.0b013e3282fa6db9>.
- Kastner, S., O'Connor, D.H., Fukui, M.M., Fehd, H.M., Herwig, U., Pinski, M.A., 2004. Functional imaging of the human lateral geniculate nucleus and pulvinar. *J. Neurophysiol.* 91, 438–448. <https://doi.org/10.1152/jn.00553.2003>.
- Kim, J.J., Lee, M.C., Kim, J., Kim, I.Y., Kim, S.I., Han, M.H., Chang, K.H., Kwon, J.S., 2001. Grey matter abnormalities in obsessive-compulsive disorder: statistical parametric mapping of segmented magnetic resonance images. *Br. J. Psychiatry* 179, 330–334. <https://doi.org/10.1192/bjp.179.4.330>.
- Kim, T., Kwak, S., Hur, J.W., Lee, J., Shin, W.G., Lee, T.Y., Kim, M., Kwon, J.S., 2020. Neural bases of the clinical and neurocognitive differences between early and late-onset obsessive-compulsive disorder. *J. Psychiatry Neurosci.* 45, 234–242. <https://doi.org/10.1503/jpn.190028>.
- Kong, X.Z., Boedhoe, P.S.W., Abe, Y., Alonso, P., Ameis, S.H., Arnold, P.D., Assogna, F., Baker, J.T., Batistuzzo, M.C., Benedetti, F., Beucke, J.C., Bollettini, I., Bose, A., Brem, S., Brennan, B.P., Buitelaar, J., Calvo, R., Cheng, Y., Cho, K.I.K., Dallaspezia, S., Denys, D., Ely, B.A., Feusner, J., Fitzgerald, K.D., Fouché, J.P., Fridgeirsson, E.A., Glahn, D.C., Gruner, P., Gursel, D.A., Hauser, T.U., Hirano, Y., Hoexter, M.Q., Hu, H., Huyser, C., James, A., Jaspers-Fayer, F., Kathmann, N., Kaufmann, C., Koch, K., Kuno, M., Kvale, G., Kwon, J.S., Lazaro, L., Liu, Y., Lochner, C., Marques, P., Marsh, R., Martinez-Zalacain, I., Mataix-Cols, D., Medland, S.E., Menchon, J.M., Minuzzi, L., Moreira, P.S., Morer, A., Morgado, P., Nakagawa, A., Nakamae, T., Nakao, T., Narayanaswamy, J.C., Nurmii, E.L., O'Neill, J., Pariente, J.C., Perriello, C., Piacentini, J., Piras, F., Piras, F., Pittenger, C., Reddy, Y.C.J., Rus-Oswald, O.G., Sakai, Y., Sato, J.R., Schmaal, L., Simpson, H.B., Soreni, N., Soriano-Mas, C., Spalletta, G., Stern, E.R., Stevens, M.C., Stewart, S.E., Szeszkó, P.R., Tolin, D.F., Tsuchiyagaito, A., van Rooij, D., van Wingen, G.A., Venkatasubramanian, G., Wang, Z., Yun, J.Y., ENIGMA OCD Working Group, Thompson, P.M., Stein, D.J., van den Heuvel, O.A., Francks, C., 2020. Mapping cortical and subcortical asymmetry in obsessive-compulsive disorder: findings from the ENIGMA consortium. *Biol. Psychiatry* 87, 1022–1034. doi: 10.1016/j.biopsych.2019.04.022.
- Kopřivova, J., Horáček, J., Tintera, J., Prasko, J., Raszka, M., Ibrahim, I., Hoschl, C., 2009. Medial frontal and dorsal cortical morphometric abnormalities are related to obsessive-compulsive disorder. *Neurosci. Lett.* 464, 62–66. <https://doi.org/10.1016/j.neulet.2009.08.012>.
- Kwon, J.S., Shin, Y.W., Kim, C.W., Kim, Y.I., Youn, T., Han, M.H., Chang, K.H., Kim, J.J., 2003. Similarity and disparity of obsessive-compulsive disorder and schizophrenia in MR volumetric abnormalities of the hippocampus-amygdala complex. *J. Neurol. Neurosurg. Psychiatry* 74, 962–964. <https://doi.org/10.1136/jnnp.74.7.962>.
- Lacerda, A.L., Dalgallarrondo, P., Caetano, D., Haas, G.L., Camargo, E.E., Keshavan, M.S., 2003. Neuropsychological performance and regional cerebral blood flow in obsessive-compulsive disorder. *Prog. Neuro-psychopharmacol. Biol. Psychiatry* 27, 657–665. [https://doi.org/10.1016/S0278-5846\(03\)00076-9](https://doi.org/10.1016/S0278-5846(03)00076-9).
- Liu, W., Gan, J., Fan, J., Zheng, H., Li, S., Chan, R.C.K., Tan, C., Zhu, X., 2019. Associations of cortical thickness, surface area and subcortical volumes with insight in drug-naive adults with obsessive-compulsive disorder. *Neuroimage Clin.* 24, 102037. <https://doi.org/10.1016/j.nicl.2019.102037>.
- Lv, Q., Wang, Z., Zhang, C., Fan, Q., Zhao, Q., Zelijic, K., Sun, B., Xiao, Z., Wang, Z., 2017. Divergent structural responses to pharmacological interventions in orbitofronto-striato-thalamic and premotor circuits in obsessive-compulsive disorder. *EBioMedicine* 22, 242–248. <https://doi.org/10.1016/j.ebiom.2017.07.021>.
- Morel, A., 2007. *Stereotactic Atlas of the Human Thalamus and Basal Ganglia*. Informa Healthcare, New York, NY.
- Mori, E., 2001. Behavioral and cognitive changes following thalamic and basal ganglionic lesions. In: Miyoshi, K., Shapiro, C., Gaviira, M., Morita, Y. (Eds.), *Contemporary Neuropsychiatry*. Springer, Tokyo, Japan, pp. 78–83.
- Muller, J., Roberts, J.E., 2005. Memory and attention in obsessive-compulsive disorder: a review. *J. Anxiety Disord.* 19, 1–28. <https://doi.org/10.1016/j.janxdis.2003.12.001>.
- O'Connor, D.H., Fukui, M.M., Pinski, M.A., Kastner, S., 2002. Attention modulates responses in the human lateral geniculate nucleus. *Nat. Neurosci.* 5, 1203–1209. <https://doi.org/10.1038/nn957>.
- Orbell, S., Schneider, H., Esbitt, S., Gonzalez, J.S., Gonzalez, J.S., Shreck, E., Batchelder, A., Gidron, Y., Pressman, S.D., Hooker, E.D., Wiebe, D.J., Rinehart, D., Hayman, L.L., Meneghini, L., Kikuchi, H., Kikuchi, H., Desouky, T.F., McAndrew, L.M., Mora, P.A., Bruce, B., Luger, T.M., Allebeck, P., Allebeck, P., Allebeck, P., Carrasquillo, O., McAlister, A.L., Molina, K.M., Birch, S., Gafni, A., Baumann, L.C., Karel, A., Sollins, H., Hjortsberg, C., Sanders, L., Gidron, Y., Marcus, E.N., Carrasquillo, O., Tran, V., Allebeck, P., Wit, M., Hajos, T., Gidron, Y., Rarback, S., Wallhagen, M., Wallhagen, M., Ye, S., Newman, J., Whang, W., Hamer, M., Smith, T.W., DeBerard, S., Shapiro, P.A., Chida, Y., Sabol, V., Ginty, A.T., Thayer, J.F., Kanda, Y., Newman, J., Brintz, C., Whittaker, T., Wessel, J., Rodriguez-Murillo, L., Salem, R.M., Matsuyama, Y., Turner, J.R., Schneiderman, N., Ruiz, J., Garza, M., Smith, L., DeBerard, S., Overstreet, N., Mitchell, J.W., Carrasquillo, O., Rodriguez, O., Gaab, J., Ye, S., Rodriguez-Murillo, L., Salem, R.M., Gidron, Y., Wolf, O.T., Croom, A., Pellosmaa, H.B., Desouky, T.F., Palmer, S.C., Henderson, K.M., Everson-Rose, S.A., Clark, C.J., Everson-Rose, S.A., Clark, C.J., Henderson, K.M., Everson-Rose, S.A., Clark, C.J., Henderson, K.M., Henderson, K.M., Everson-Rose, S.A., Clark, C.J., Bakdash, J.Z., Drews, F.A., Salem, R.M., Rodriguez-Murillo, L.,

- García, L.I., Roane, L., Coons, M.J., Parker, A., Flannery, K., Carroll, D., Rosenberg, L., Clark, M.S., Fortenberry, K.T., Jansen, K.L., Parker, A., Heaney, J., Beaton, E.A., Turner, J.R., 2013. Hamilton rating scale for depression (HAM-D). In: Gellman, M.D., Turner, J.R. (Eds.), *Encyclopedia of Behavioral Medicine*. Springer, New York, NY, pp. 887–888.
- Padhi, A., Fineberg, N.A., Chudasama, Y., 2010. Yale–Brown obsessive–compulsive scale, in: Stolerman, I.P. (Ed.), *Encyclopedia of Psychopharmacology*. Springer, Berlin, Heidelberg, pp. 1377–1377.
- Peters, S.K., Dunlop, K., Downar, J., 2016. Cortico-striatal-thalamic loop circuits of the salience network: a central pathway in psychiatric disease and treatment. *Front. Syst. Neurosci.* 10, 104. <https://doi.org/10.3389/fnsys.2016.00104>.
- Petersen, S.E., Robinson, D.L., Morris, J.D., 1987. Contributions of the pulvinar to visual spatial attention. *Neuropsychologia* 25, 97–105. [https://doi.org/10.1016/0028-3932\(87\)90046-7](https://doi.org/10.1016/0028-3932(87)90046-7).
- Purushothaman, G., Marion, R., Li, K., Casagrande, V.A., 2012. Gating and control of primary visual cortex by pulvinar. *Nat. Neurosci.* 15, 905–912. <https://doi.org/10.1038/nn.3106>.
- Robbins, T.W., Vaghi, M.M., Banca, P., 2019. Obsessive-compulsive disorder: puzzles and prospects. *Neuron* 102, 27–47. <https://doi.org/10.1016/j.neuron.2019.01.046>.
- Robinson, D.L., Petersen, S.E., 1992. The pulvinar and visual salience. *Trends Neurosci.* 15, 127–132. [https://doi.org/10.1016/0166-2236\(92\)90354-b](https://doi.org/10.1016/0166-2236(92)90354-b).
- Rosenberg, D.R., Benazon, N.R., Gilbert, A., Sullivan, A., Moore, G.J., 2000. Thalamic volume in pediatric obsessive-compulsive disorder patients before and after cognitive behavioral therapy. *Biol. Psychiatry* 48, 294–300. [https://doi.org/10.1016/s0006-3223\(00\)00902-1](https://doi.org/10.1016/s0006-3223(00)00902-1).
- Saalmann, Y.B., Kastner, S., 2011. Cognitive and perceptual functions of the visual thalamus. *Neuron* 71, 209–223. <https://doi.org/10.1016/j.neuron.2011.06.027>.
- Saalmann, Y.B., Kastner, S., 2015. The cognitive thalamus. *Front. Syst. Neurosci.* 9, 39. <https://doi.org/10.3389/fnsys.2015.00039>.
- Saalmann, Y.B., Pinsk, M.A., Wang, L., Li, X., Kastner, S., 2012. The pulvinar regulates information transmission between cortical areas based on attention demands. *Science* 337, 753–776. <https://doi.org/10.1126/science.1223082>.
- Shaw, P., Sharp, W., Sudre, G., Wharton, A., Greenstein, D., Raznahan, A., Evans, A., Chakravarty, M.M., Lerch, J.P., Rapoport, J., 2015. Subcortical and cortical morphological anomalies as an endophenotype in obsessive-compulsive disorder. *Mol. Psychiatry* 20, 224–231. <https://doi.org/10.1038/mp.2014.3>.
- Sherman, S.M., 2007. The thalamus is more than just a relay. *Curr. Opin. Neurobiol.* 17, 417–422. <https://doi.org/10.1016/j.conb.2007.07.003>.
- Sherman, S.M., 2016. Thalamus plays a central role in ongoing cortical functioning. *Nat. Neurosci.* 19, 533–541. <https://doi.org/10.1038/nn.4269>.
- Sherman, S.M., Guillery, R.W., 2002. The role of the thalamus in the flow of information to the cortex. *Philos. Trans. R. Soc. Lond. B Biol. Sci.* 357, 1695–1708. <https://doi.org/10.1098/rstb.2002.1161>.
- Shin, N.Y., Lee, T.Y., Kim, E., Kwon, J.S., 2014. Cognitive functioning in obsessive-compulsive disorder: a meta-analysis. *Psychol. Med.* 44, 1121–1130. <https://doi.org/10.1017/S0033291713001803>.
- Stein, D.J., Costa, D.L.C., Lochner, C., Miguel, E.C., Reddy, Y.C.J., Shavitt, R.G., van den Heuvel, O.A., Simpson, H.B., 2019. Obsessive-compulsive disorder. *Nat. Rev. Dis. Primers* 5, 52. <https://doi.org/10.1038/s41572-019-0102-3>.
- Tang, W., Zhu, Q., Gong, X., Zhu, C., Wang, Y., Chen, S., 2016. Cortico-striato-thalamo-cortical circuit abnormalities in obsessive-compulsive disorder: a voxel-based morphometric and fMRI study of the whole brain. *Behav. Brain Res.* 313, 17–22. <https://doi.org/10.1016/j.bbr.2016.07.004>.
- Taylor, S., 2011. Early versus late onset obsessive-compulsive disorder: evidence for distinct subtypes. *Clin. Psychol. Rev.* 31, 1083–1100. <https://doi.org/10.1016/j.cpr.2011.06.007>.
- Thompson, E., 2015. Hamilton rating scale for anxiety (HAM-A). *Occup. Med.* 65, 601. <https://doi.org/10.1093/occmed/kqv054>.
- Tukel, R., Gurvit, H., Ertekin, B.A., Oflaz, S., Ertekin, E., Baran, B., Kalem, S.A., Kandemir, P.E., Ozdemiroglu, F.A., Atalay, F., 2012. Neuropsychological function in obsessive-compulsive disorder. *Compr. Psychiatry* 53, 167–175. <https://doi.org/10.1016/j.comppsy.2011.03.007>.
- Usrey, W.M., Allitto, H.J., 2015. Visual functions of the thalamus. *Annu. Rev. Vis. Sci.* 1, 351–371. <https://doi.org/10.1146/annurev-vision-082114-035920>.
- Valente Jr., A.A., Miguel, E.C., Castro, C.C., Amaro Jr., E., Duran, F.L., Buchpiguel, C.A., Chitnis, X., McGuire, P.K., Busatto, G.F., 2005. Regional gray matter abnormalities in obsessive-compulsive disorder: a voxel-based morphometry study. *Biol. Psychiatry* 58, 479–487. <https://doi.org/10.1016/j.biopsych.2005.04.021>.
- Viard, A., Flament, M.F., Artiges, E., Dehaene, S., Naccache, L., Cohen, D., Mazet, P., Mouren, M.C., Martinot, J.L., 2005. Cognitive control in childhood-onset obsessive-compulsive disorder: a functional MRI study. *Psychol. Med.* 35, 1007–1017. <https://doi.org/10.1017/s0033291704004295>.
- Weeland, C.J., White, T., Vriend, C., Muetzel, R.L., Starreveld, J., Hillegers, M.H.J., Tiemeier, H., van den Heuvel, O.A., 2020. Brain morphology associated with obsessive-compulsive symptoms in 2,551 children from the general population. *J. Am. Acad. Child Adolesc. Psychiatry*. <https://doi.org/10.1016/j.jaac.2020.03.012>.
- Yovel, I., Reville, W., Mineka, S., 2005. Who sees trees before forest? The obsessive-compulsive style of visual attention. *Psychol. Sci.* 16, 123–129. <https://doi.org/10.1111/j.0956-7976.2005.00792.x>.
- Zarei, M., Mataix-Cols, D., Heyman, I., Hough, M., Doherty, J., Burge, L., Winmill, L., Nijhawan, S., Matthews, P.M., James, A., 2011. Changes in gray matter volume and white matter microstructure in adolescents with obsessive-compulsive disorder. *Biol. Psychiatry* 70, 1083–1090. <https://doi.org/10.1016/j.biopsych.2011.06.032>.
- Zhang, L., Hu, X., Li, H., Lu, L., Li, B., Hu, X., Bu, X., Tang, S., Tang, W., Liu, N., Yang, Y., Gong, Q., Huang, X., 2019. Characteristic alteration of subcortical nuclei shape in medication-free patients with obsessive-compulsive disorder. *Neuroimage Clin.* 24, 102040. <https://doi.org/10.1016/j.nicl.2019.102040>.
- Zhou, H., Schafer, R.J., Desimone, R., 2016. Pulvinar-cortex interactions in vision and attention. *Neuron* 89, 209–220. <https://doi.org/10.1016/j.neuron.2015.11.034>.