

## Scleral- fixated intraocular lens implantation in microspherophakia

Sujata Subbiah, Philip A Thomas, CA Nelson Jesudasan

**Background:** In microspherophakia, abnormal laxity of the lenticular zonules leads to development of a spherical lens and possible subluxation. We evaluated long-term results of lens removal with scleral-fixated intraocular lens (SFIOL) implantation in microspherophakia. **Materials and Methods:** Case series. SF IOLs were implanted in four consecutive patients with bilateral microspherophakia (eight eyes [three with pupillary block and secondary glaucoma who underwent immediate surgery and five with only subluxation who underwent elective surgery]). Post-operative best-corrected visual acuity (BCVA), intraocular pressure (IOP) and lens position were evaluated periodically from day 1 to 18 months. **Results:** All patients were females (mean age  $28 \pm 7.03$  years). In group 1 eyes (three eyes that presented with pupillary block), the mean BCVA improved from 0.008 decimals (preoperative) to 0.50 decimals (final post-operative visit); in group 2 eyes (the other five eyes), the mean BCVA improved from  $0.12 \pm 0.21$  decimals to  $0.73 \pm 0.14$  decimals. The preoperative mean IOP ( $54.53 \pm 7.33$  mmHg) in group 1 eyes was significantly ( $P = 0.03$ ) higher than that ( $16 \pm 4.30$  mm Hg) in group 2 eyes. At final post-operative visit, the mean IOP ( $11.67 \pm 2.88$  mmHg) in group 1 eyes was not significantly different from that in group 2 eyes ( $13.0 \pm 3.08$  mmHg). All SFIOLs were well-centred at the final visit. None of the patients encountered any peroperative or postoperative complications. **Conclusions:** SFIOLs may be an option for surgical management of microspherophakia.

**Key words:** Ectopia lentis, microspherophakia, pupillary block, Scleral-fixated intraocular lenses

Patients with microspherophakia are generally at high risk of developing acute angle-closure glaucoma (ACG) or chronic ACG due to a narrow anterior chamber angle consequent to weakness of lens zonules and an excessively curved anterior lenticular surface.<sup>[1,2]</sup> Surgical interventions described include pars plana lensectomy with scleral-fixated intraocular lens (SFIOL)<sup>[1]</sup> implantation, phacoemulsification with removal of the capsular bag and anterior chamber IOL implantation,<sup>[1]</sup> lenticular aspiration with posterior chamber (PC) IOL implantation<sup>[2]</sup> and phacoemulsification with acrylic lens implantation.<sup>[3]</sup> In microspherophakia with subluxation and raised intraocular pressure (IOP), additional glaucoma surgery<sup>[1,4-6]</sup> is indicated.

We herein report long-term results of lens removal followed by SFIOL implantation in eight eyes with microspherophakia.

### Materials and Methods

In this prospective non-randomized interventional case series over a period of 40 months (January 2008 to April 2011) at a tertiary eye care hospital, four patients with bilateral microspherophakia (eight eyes) underwent lens removal and subsequent SFIOL implantation (performed by a single surgeon). Each patient provided informed written consent prior to enrolment in the study for surgery, while the study itself was performed per the tenets of the Declaration of Helsinki and was approved by the Institutional Review Board.

Institute of Ophthalmology Joseph eye Hospital, Tiruchirappalli, Tamil Nadu, India

**Correspondence to:** Dr. Sujata Subbiah, Institute of Ophthalmology, Joseph Eye Hospital, Melapudur, Tiruchirappalli, Tamil Nadu, India. E-mail: umasujata@yahoo.com

**Manuscript received:** 08.07.13; **Revision accepted:** 15.08.13

Access this article online

Website:

www.ijo.in

DOI:

10.4103/0301-4738.129787

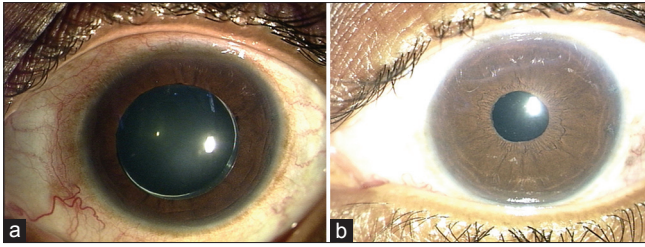
Quick Response Code:



All four patients underwent preoperative clinical and ophthalmic examination, that included assessment of the best-corrected visual acuity (BCVA), slit lamp biomicroscopy, measurement of IOP by applanation tonometry, indirect ophthalmoscopy, ultrasound biomicroscopy, keratometry and biometry and posterior segment evaluation by B-Scan (in eyes with hazy media).

### Surgical technique

Before surgery, patients with a pupillary block were treated medically and the elevated IOP was brought under control (Fig: 1a). Tablet acetazolamide (250 mg) and syrup glycerol (30 oz) were each administered orally three times daily. Topical 0.5% timolol was administered twice daily. Pupils were dilated with tropicamide and phenylephrine drops. Preoperatively 20% mannitol was infused intravenously (1 gm/kg body weight) to dehydrate the vitreous. Each eye was anesthetized by a peribulbar block, using 3 cc each of 0.5% bupivacaine and 2% lidocaine hydrochloride. Conjunctival periotomy was done at the limbus (11 o'clock to 1 o'clock positions and at the 2 o'clock and 8 o'clock positions in the right eye and at the 10 o'clock and 4 o'clock positions in the left eye) followed by cauterization. Two partial thickness scleral grooves were made 1.5 mm behind the limbus, and small, partial thickness tunnels were constructed with a crescent knife at the 2 o'clock and 8 o'clock positions in the right eye and at the 10 o'clock and 4 o'clock positions in the left eye. A three planar corneoscleral tunnel was constructed from 11 o'clock to 1 o'clock position. A keratome was used to enter the anterior chamber. A Sinsky hook was used to ensure that the lens was free from the surrounding zonules. Following this the lens was carefully expressed with viscoelastic, and extraction was assisted by a wire vectis [Fig. 2a]. Automated anterior vitrectomy was performed to clear the anterior chamber of vitreous. A "guard" suture was applied to the corneoscleral tunnel after the lens had been delivered.



**Figure 1:** (a) Photograph showing microspherophakic lens with a pupillary block. (b) Postoperative photograph showing a well-centered scleral-fixated intraocular lens in situ (3 months postoperative)

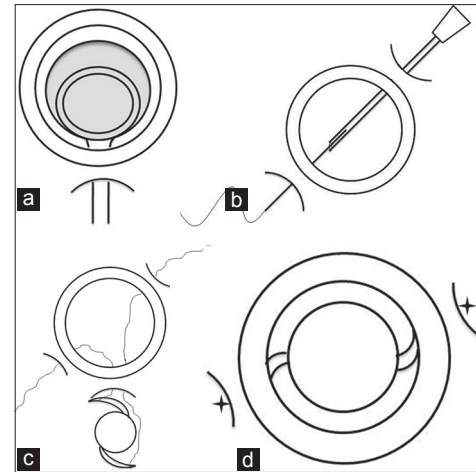
A 26-G needle was introduced from the temporal scleral wound and a straight needle on 10.0 prolene (10-0 polypropylene, Aurole® double armed with a straight spatulated needle at one end and curved needle at the other end) from the nasal scleral wound 1 mm posterior to the limbus exactly 180 degrees apart. The needle was directed to enter perpendicular to the scleral surface and, once at the ciliary sulcus, it was directed toward the opposite scleral bed, hugging the posterior surface of the iris. The straight needle on 10.0 prolene was then docked into the lumen of the 26-G needle [Fig. 2b]. The 26-G needle was retrieved from the temporal scleral bed along with the prolene suture that was then seen to be stretched across the posterior chamber. The 'guard' suture was then cut. A McPherson's forceps was used to loop the 10.0 prolene suture out from the section and it was cut and the ends tied to the eyelets on the haptics of a single piece 6.5 mm polymethyl methacrylate SFIOL (PMMA Aurole® single piece IOL with optic size 6.5 mm and overall diameter 13.0 mm UV absorbing equiconvex with 0.4 mm steep vault, modified "C" Loop for scleral fixing [Fig. 2c]. The suture from the left scleral bed was tied to the trailing haptic and from the right scleral bed to the leading haptic. The SFIOL was placed in the sulcus and the prolene suture holding the IOL was made taut, to ensure centration of the IOL. The straight spatulated needle was bent at the junction of the proximal one third to the distal two thirds and, with this, the sutures were anchored and knotted in the bed of the scleral tunnel [Fig. 2d]. The curved needle at the other end helped in anchoring the other end and the knot was buried in the scleral bed, following that the tunnel was covered by the conjunctiva and the edges cauterized.

#### Post-operative review

Postoperatively, the patients were reviewed on the first and seventh day, at the fourth and sixth week and every month periodically for 18 months. At each visit, the following procedures were performed: assessment of BCVA (converted to decimals); refraction; IOP measurement; slit lamp biomicroscopy for corneal status, anterior chamber reaction and SFIOL status; and detailed fundus examination by indirect ophthalmoscopy.

#### Statistical analysis

Data were analyzed using the Statistical Program for Scientific Studies (SPSS) for Windows software (SPSS version 11.1 Inc, Chicago II USA). A comparison was made between preoperative data and data obtained at each postoperative visit. Visual acuity data were converted to decimal values to calculate the mean and standard deviation. The IOP and decimal visual acuity values obtained at each visit were compared (one-way



**Figure 2:** (a) Expression of a microspherophakic lens assisted by a wire vectis. (b) The straight needle on 10.0 prolene being docked into the lumen of the 26-G needle. (c) Ends of a prolene suture tied to the eyelets on the haptics of a single piece 6.5 mm polymethyl methacrylate SFIOL. (d) Sutures anchored and knotted within the bed of the scleral tunnel

analysis of variance followed by *post-hoc* testing). A *P* value less than 0.05 was considered statistically significant.

## Results

In the four patients (all females [mean age  $28 \pm 7.03$  yrs {range 17-34 yrs}] with bilateral microspherophakia (eight eyes), three eyes presented with pupillary block, (group-1) necessitating immediate surgery (lens removal followed by SFIOL implantation); in the other five eyes, surgery was performed as an elective procedure (group-2) since only subluxation (without pupillary block) was noted at presentation. The mean period of follow up was  $20.3 \pm 2.6$  months (range 18.6-22.4 months).

The preoperative mean BCVA in group-1 (0.008 decimals) was not significantly different ( $P = 0.33$ ) from that in group-2 ( $0.12 \pm 0.21$  decimals) [Table 1]. However, the preoperative mean IOP in group-1 ( $54.53 \pm 7.33$  mmHg [range 50-63]) was significantly ( $P = 0.03$ ) higher than that in group-2 ( $16 \pm 4.30$  mmHg [range 12-21]) [Table 2].

On the first post-operative day, in group-1, the mean BCVA was  $0.14 \pm 0.09$  decimals (range 0.08-0.25) [Table 1] and the mean IOP was  $17.33 \pm 4.04$  mmHg (range 15-22 mmHg) [Table 2], whereas in group-2, the mean BCVA was  $0.46 \pm 0.14$  decimals (range 0.33-0.67) [Table 1] and the mean IOP was  $12.20 \pm 1.48$  mmHg (range 10-14) [Table 2] Although the differences between the mean BCVA in the two groups were statistically significant ( $P = 0.001$ ) [Table 1], the differences between the mean IOP in the two groups were not statistically significant ( $P = 0.085$ ) [Table 2].

At 2 months after surgery, the mean BCVA in group-1 ( $0.20 \pm 0.08$  decimals [range 0.1-0.25]) was significantly less ( $P = 0.001$ ) than that in group-2 ( $0.60 \pm 0.09$  decimals [range 0.5-0.67]) [Table 1]. However, at this visit, the mean IOP in group-1 ( $15.67 \pm 6.02$  mmHg [range 10-22]) was not significantly different from that in group-2 ( $13.60 \pm 4.39$  mmHg [range 6-17]) [Table 2]. At the 6 month post-operative review, the mean

**Table 1: Mean best corrected visual acuity in eyes with microspherophakia**

Category of eyes (number)	Mean best corrected visual acuity (in decimals) at					Statistical analysis (one-way analysis of variance)*
	Presentation (preoperative)	One-day post-operative	Two months post-operative	Six months post-operative	18 months post-operative	
Group-1 (3)	0.008	0.14±0.09	0.20±0.08	0.3±0.41	0.5±0.0	F=2.8 P=0.085
Group-2 (5)	0.12±0.21	0.46±0.14	0.60±0.09	0.66±0.2	0.73±0.14	F=11.1 P<0.001
All eyes (8)	0.08±0.17	0.34±0.20	0.45±0.22	0.53±0.24	0.64±0.16	F=9.11 P<0.001
Statistical analysis** (student 't')	P>0.05	P=0.001	P=0.001	P>0.05	P>0.05	

\*Statistical analysis of differences between values across all visits in eyes in Group-1, Group-2 and all eyes. \*\*Statistical analysis of differences between values in Group-1 and Group-2 at different examination times

**Table 2: Mean intraocular pressure in eyes with microspherophakia**

Category of eyes (number)	Mean intraocular pressure (mm Hg) at					Statistical analysis (one-way analysis of variance)*
	Presentation (pre-operative)	One day post-operative	Two months post-operative	Six months post-operative	18 months post-operative	
Group-1 (3)	54.53±7.33	17.33±4.04	15.67±6.02	14.33±4.04	11.67±2.88	F=36.8; P<0.0001
Group-2 (5)	16.0±4.3	12.20±1.48	13.60±4.39	13.8±3.11	13.0±3.08	F=0.85; P=0.81
All eyes (8)	30.45±20.58	14.13±3.6	14.38±4.74	14.0±3.2	12.5±2.87	F=4.7; P=0.004
Statistical analysis**	P=0.03	P=0.085	P=0.37	P=0.093	P=0.19	

\*Statistical analysis of differences between values across all visits in eyes in Group 1, Group 2 and all eyes. \*\*Statistical analysis of differences between values in eyes in Group-1 and Group-2 at different examination times

BCVA in group-1 ( $0.30 \pm 0.4$  decimals [range 0.25-0.33]) was not significantly different ( $P = 0.093$ ) from that in group-2 ( $0.66 \pm 0.20$  decimals [range 0.5-1]) [Table 1]; similarly, at this visit, the mean IOP in group-1 ( $14.33 \pm 4.04$  mmHg [range 10-18]) was not significantly different from that ( $13.80 \pm 3.11$  mmHg [range 10-17]) in group-2 [Table 2].

At the final review visit (18 months after surgery), the mean BCVA in group-1 was 0.50 decimals while that in group-2 was  $0.73 \pm 0.14$  decimals (range 0.67-1.0), this difference was not statistically significant ( $P > 0.05$ ) [Table 1]. Similarly, at this visit, the mean IOP ( $11.67 \pm 2.88$  mmHg [range 10-15]) in group-1 was not significantly different ( $P = 0.19$ ) from that in group-2 ( $13.0 \pm 3.08$  mmHg [range 10-17]) [Table 2].

Differences between the mean BCVA values and mean IOP values within each group (group-1; group-2; all eyes) at presentation and at different post-operative visits were also subjected to statistical analysis to determine whether these intergroup differences were statistically significant (Tables 1 and 2).

In eyes in group-1, differences in mean BCVA values noted at the different visits were not statistically significant; however, in group-2 and in all eyes, differences in mean BCVA values noted at the different visits were statistically significant (one-way ANOVA,  $F = 11.1$  ( $P < 0.001$ ) and  $F = 9.1$  ( $P = 0.001$ ), respectively) [Table 1]. *Post-hoc* testing (Tukey method) revealed that differences between presentation (pre-operative) values and all post-operative values, and those between first post-operative day values and first post-operative year values formed the basis of the significant differences.

In eyes in group-1 and in all eyes, differences in mean IOP values noted at the different visits were statistically significant (one-way ANOVA,  $F = 36.8$  ( $P < 0.0001$ ) and  $F = 4.72$  ( $P = 0.004$ ), respectively) [Table 2]; however, in eyes in group-2, differences in mean IOP values noted at the different visits were not statistically significant [Table 2]. *Post-hoc* testing (Tukey method) revealed that differences between presentation (pre-operative) values and all post-operative values formed the basis of the significant differences. At the final review visit, the SFIOL was found to be well centered in all eight eyes (Fig. 1b).

None of the patients encountered any preoperative or postoperative complications.

## Discussion

Microspherophakia is an uncommon bilateral condition in which there is abnormal laxity of the zonules of the lens, which leads to the development of a spherical lens,<sup>[7]</sup> with a strong possibility of glaucoma supervening, particularly if the small lens is displaced.<sup>[8]</sup> The patient experiences visual problems due to myopia, astigmatism and loss of accommodative power and forward movement of the lens.<sup>[9]</sup>

In addition to causing acute ACG, a spherophakic lens may lead to chronic ACG due to narrowing of the angle of the anterior chamber. Iris bowing may also lead to formation of peripheral anterior synechiae.<sup>[10]</sup> Chronic pupillary block without complete angle closure may occur because of forward displacement of the lens, and can result in crowding of the trabeculae by the spherophakic lens.<sup>[11]</sup> Unrelieved pupillary

block may lead to peripheral anterior synechiae and irreversible trabecular damage.<sup>[11]</sup> Bilateral acute ACG secondary to isolated microspherophakia in an adult has been reported.<sup>[11]</sup>

Some investigators<sup>[12,13]</sup> have tried to correct high myopia in microspherophakia by using iris-fixated phakic lenses. Management of microspherophakia with lenticular subluxation is a great surgical challenge, since the combined effects of a small capsular bag, an average lenticular equatorial diameter of 6.75 to 7.5 mm and zonular instability predispose to intraoperative and postoperative complications.<sup>[14]</sup> Removal of the lens, which is indicated only if the lens is cataractous, yields unsatisfactory results;<sup>[7]</sup> other indications for lenticular extraction include corneo-lenticular touch, high myopia, intermittent pupillary block and secondary glaucoma. Visual rehabilitation poses a challenge to the clinician as implantation of a conventional PCIOL is not convenient since the lens is spherical in shape and the zonules of the lens are weaker.<sup>[7]</sup> A capsular tension ring probably reduces the risk of capsular shrinkage and IOL subluxation and has been described as being beneficial in microspherophakia;<sup>[15]</sup> A PCIOL, in addition to a capsular tension ring, has been successfully implanted in such cases.<sup>[15]</sup> Other surgical interventions described for microspherophakia are phacoemulsification with acrylic lens implantation;<sup>[3,7,16]</sup> in addition, iris hooks to stabilize the capsular bag have been used.<sup>[7]</sup> Pars plana lensectomy with implantation of a SFIOL<sup>[14]</sup> and phacoemulsification with removal of the capsular bag and implantation of an anterior chamber IOL have also been described.<sup>[14]</sup>

The management of glaucoma in microspherophakia is still controversial, with various surgical options having been tried. Willi *et al.*<sup>[17]</sup> observed that Nd: YAG laser peripheral iridotomy was a safe initial procedure to relieve pupillary block; however, the rate of complications was found to be high. Vitreous loss occurred frequently since the vitreous face was unprotected by the periphery of the lens. Ritch *et al.*<sup>[18]</sup> were of the opinion that if laser PI failed, surgical peripheral iridectomy could be performed. According to Dagi and Walton,<sup>[4]</sup> since the primary mechanism of angle closure is angle crowding, peripheral iridectomy may not suffice to control a rise in IOP; these authors opined that early detection and prophylactic lensectomy alone could control IOP, and, thus, could be considered a reliable treatment. Asaoka *et al.*<sup>[19]</sup> suggested that trabeculectomy alone could control IOP in spherophakia with open angles.

In contrast, Yasar<sup>[20]</sup> described a patient in whom lensectomy initially controlled IOP; subsequently, the patient required mitomycin C-augmented trabeculectomy in both eyes. Kanamori *et al.*<sup>[10]</sup> reported successful control of IOP by goniosynechialysis with lens aspiration and PCIOL implantation in both eyes, followed by peripheral iridoplasty three days later. By restructuring the physiologic aqueous outflow route, goniosynechialysis safely and effectively treated secondary glaucoma in microspherophakia. Based on their experience with treating two siblings (four eyes) with Weill-Marchesani syndrome, Harasymowycz and Wilson<sup>[5]</sup> advocated a combination of lensectomy, anterior vitrectomy, sutured IOL and Molteno tube shunt to successfully control IOP in advanced chronic angle-closure glaucoma in this syndrome; however, they stressed that in early cases, prophylactic peripheral iridotomies needed to be performed. Fan<sup>[6]</sup> successfully performed lensectomy and scleral fixation of IOL with satisfactory outcome in an isolated case of bilateral microspherophakia.

Considering the options available, we performed removal of the lens with SFIOL implantation. The location of the lens in SFIOL is a major advantage. Complications of anterior chamber IOLs include irreversible corneal endothelial loss, pseudophakic bullous keratopathy, peripheral anterior synechiae and glaucoma caused by long-term anterior chamber irritation.<sup>[21]</sup> Scleral-fixated PC IOLs have been favored over other alternatives due to the reduced risk for corneal endothelial pathology, peripheral anterior synechiae and glaucoma.<sup>[21]</sup> McAllister *et al.* in a long-term study on scleral-fixated PC IOLs, reported ocular hypertension in 30.5%, suture breakage in 6%, retinal detachment in 4.9%, cystoid macular edema in 7.3% and suture erosion in 1.2%.<sup>[21]</sup> SFIOL implantation poses a different set of perioperative and postoperative problems. Technically, it is a difficult procedure and takes a longer time to complete than other procedures. As there is a suture track into the eye and greater surgical manipulation in the region of the ciliary body, perioperative hemorrhage may occur. Serious post-operative complications, such as erosion or breakage of the knot and suture, tilting of the IOL, endophthalmitis, retinal detachment, choroidal hemorrhage, elevated IOP and open angle glaucoma, are well-documented.<sup>[21]</sup>

Analysis of the data generated in the present study suggests that significantly better mean BCVA values occurred in the eyes that underwent elective surgery than in the eyes with pupillary block (underwent immediate surgery) at the first post-operative day and second post-operative month visits [Table 1]; however, there were no significant differences noted at presentation, and at the 6<sup>th</sup> post-operative month and at 18 months post-operative visits. Analysis of the IOP data suggests that there was no significant difference in mean IOP values at all visits, except at presentation, between group-1 (underwent immediate surgery) and group-2 that underwent elective surgery [Table 2].

A meticulous vitrectomy is required in all eyes with SFIOLs to decrease the probability of vitreous traction leading to subsequent retinal detachment. Traction on the peripheral retina or vitreous during suture placement in the sulcus may increase the risk of retinal detachment.<sup>[22]</sup> A careful anterior vitrectomy through the limbal section with a slow rate of irrigation, accompanied by a slight gentle scleral indentation, is advocated. Preoperative administration of intravenous mannitol further reduces vitreous loss. In the present study, we ensured that the lens was free from all zonular attachments before delivering the lens using a wire vectis. No case of retinal detachment was encountered in our series.

In the present study, corneoscleral tunnel and partial thickness scleral flaps for anchoring scleral sutures were constructed prior to the anterior chamber entry wound. Erosion of the suture, due to gradual wearing away of trans-scleral sutures holding the IOL in place through the conjunctiva, is the most common complication of trans-scleral sutured IOLs. Common to all techniques for scleral fixation is the need to cover, bury or rotate suture knots created for fixation, to prevent conjunctival erosion and subsequent endophthalmitis.<sup>[22]</sup> Sutures may erode through the scleral flaps and cause irritation. They may also become loose or break, causing either tilting or dislocation of the optic. A persistent suture extending between the intraocular and extraocular environments may provide a track for bacteria to enter the eye and establish endophthalmitis.<sup>[22]</sup> We did not

encounter these complications as we had the knots buried under scleral flaps. No case of IOL tilt was encountered in our series.

Severe intraocular hemorrhage while passing scleral sutures due to inadvertent injury to the ciliary body during intraoperative manipulation has been reported in a few cases.<sup>[22]</sup> We did not encounter this complication in our series, possibly due to accurate suture placement in the sulcus. The use of SFIOL is also reported to be associated with an increased incidence of ocular hypertension after surgery,<sup>[21]</sup> which may be secondary to incorrect placement of scleral sutures at the time of surgery, or which may develop later due to formation of peripheral anterior synechiae. None of our patients developed secondary glaucoma.

Many techniques for management of ectopia lentis in microspherophakia have been proposed.<sup>[5,12-20]</sup> In our experience, implantation of SFIOL in patients with microspherophakia managed both subluxation and glaucoma and gave excellent optical results. The procedure is technically challenging, with a learning curve to achieve a good visual outcome. Patients reported increased satisfaction as they were corrected to an emmetropic refractive status.

An obvious limitation of this study includes the small study population, reflecting the rarity of the condition. A long-term review is required to study the outcome of the procedure.

## References

1. Kaushik S, Sachdev N, Pandav SS, Gupta A, Ram J. Bilateral acute angle closure glaucoma as a presentation of isolated microspherophakia in an adult: Case report. *BMC Ophthalmol* 2006;7:6:29.
2. Haddad CA, Khatib L. Vitrectorhexis and lens aspiration with posterior chamber intraocular lens implantation in spherophakia. *J Cataract Refract Surg* 2012;38:1123-6.
3. Bhattacharjee H, Bhattacharjee K, Medhi J, DasGupta S. Clear lens extraction and intraocular lens implantation in a case of microspherophakia with secondary angle closure glaucoma. *Indian J Ophthalmol* 2010;58:67-70.
4. Dagi LR, Waiton DS. Anterior axial lens subluxation, progressive myopia and angle closure glaucoma: recognition and treatment of atypical presentation of ectopia lentis. *J AAPOS* 2006;10:345-50.
5. Harasymowycz P, Wilson R. Surgical treatment of advanced chronic angle closure glaucoma in Weill-Marchesani syndrome. *J Pediatr Ophthalmol Strabismus* 2004;4:295-9.
6. Fan DS, Young AL, Yu CB, Chiu TY, Chan NR, Lam DS. Isolated microspherophakia with optic disc colobomata. *J Cataract Refract Surg* 2003;29:1448-52.
7. Khokhar S, Pangtey MS, Sony P, Panda A. Phacoemulsification in a case of microspherophakia. *J Cataract Refract Surg* 2003;29:845-7.
8. Chan RT, Collin HB. Microspherophakia. *Clin Exp Optom* 2002;85:294-9.
9. Chu BS. Weill-Marchesani syndrome and secondary glaucoma associated with ectopia lentis. *Clin Exp Optom* 2006;89:95-9.
10. Kanamori A, Nakamura M, Matsui N, Tomimori H, Tanase M, Seya R, *et al.* Goniosynechialysis with lens aspiration and posterior chamber intraocular lens implantation for glaucoma in spherophakia. *J Cataract Refract Surg* 2004;30:513-6.
11. Johnson GJ, Bosanquet RC. Spherophakia in a New-Foundland family: 8 year experience. *Can J Ophthalmol* 1983;18:159-64.
12. Burakgazi AZ, Ozbek Z, Rapuano CJ, Rhee DJ. Long- term complications of iris- claw phakic intraocular lens implantation in Weill Marchesani syndrome. *Cornea* 2006;25:361-3.
13. Moshirfar M, Meyer JJ, Schliesser JA, Espandar L, Chang JC. Iris-fixated phakic intraocular lens implantation for correction of high myopia in microspherophakia. *J Cataract Refract Surg* 2010;36:682-5.
14. Willoughby CE, Wishart PK. Lensectomy in the management of glaucoma in spherophakia. *J Cataract Refract Surg* 2002;28:1061-4.
15. Groessl SA, Anderson CJ. Capsular tension ring in a patient with Weill- Marchesani syndrome. *J Cataract Refract Surg* 1998;24:1164-5.
16. Behding A. Phacoemulsification in spherophakia with corneal touch. *J Cataract Refract Surg* 2002;28:189-91.
17. Willi M, Kut L, Cotlier E. Pupillary-block glaucoma in the Marchesani syndrome. *Arch Ophthalmol* 1973;90:504-8.
18. Ritch R, Wand M. Treatment of the Weill-Marchesani syndrome. *Ann Ophthalmol* 1981;13:665-7.
19. Asaoka R, Kato M, Suami M, Usami Y, Hotta Y, Sato M. Chronic angle closure glaucoma secondary to frail zonular fibres and spherophakia. *Acta Ophthalmol Scand* 2003;81:533-5.
20. Yasar T. Lensectomy in the management of glaucoma in spherophakia: is it enough? *J Cataract Refract Surg* 2003;29:1052-3.
21. McAllister AS, Hirst LW. Visual outcomes and complications of scleral-fixated. Posterior chamber intraocular lenses. *J Cataract Refract Surg* 2011;37:1263-9.
22. Rajpa RK, Carney MD, Weinberg RS, Guerry RK, Combs JL. Complications of transscleral sutured posterior chamber intraocular lenses. *Ophthalmology* 1991;98(Suppl): S144.

**Cite this article as:** Subbiah S, Thomas PA, Nelson Jesudasan CA. Scleral-fixated intraocular lens implantation in microspherophakia. *Indian J Ophthalmol* 2014;62:596-600.

**Source of Support:** Nil. **Conflict of Interest:** All the authors have completed and signed the copyright transfer form and have no conflict of interest.