

Noninvasive method for retrieval of broken dental implant abutment screw

JAGADISH REDDY GOOTY, SUNIL KUMAR PALAKURU, VIKRAM REDDY GUNTAKALLA, MAHIPAL NERA

Abstract

Dental implants made of titanium for replacement of missing teeth are widely used because of ease of technical procedure and high success rate, but are not free of complications and may fail. Fracturing of the prosthetic screw continues to be a problem in restorative practice and great challenge to remove the fractured screw conservatively. This case report describes and demonstrates the technique of using an ultrasonic scaler in the removal of the fracture screw fragment as a noninvasive method without damaging the hex of implants.

Keywords: Dental implants, dental restoration failure, osseointegration

Introduction

Oral implantology is an ever growing field that is reaching the practice of general dentist due to the simplification of technical procedures.

Implant treatment is considered as a safe technique with high rates of success.^[1] Titanium endosteal implants are widely used due to the advantages offered by their mechanical properties and excellent anchorage in the jawbone, known as “osseointegration.”^[2] This type of anchorage of the implant in bone is considered as essential criteria for a successful dental implant. Nevertheless, it has, as every surgical procedure, several complications that can occur and that must be known in order to prevent or solve them.

The failure of dental implants is due not only to biological factors, such as unsuccessful osseointegration or the development of periimplantitis, but it may also result from technical complications.^[3,4] These complications are relatively rare. In contrast, prosthetic complications are not uncommon.^[5]

In general, these complications can be grouped into the following five categories:^[6]

1. Veneering material fracture
2. Prosthetic screw loosening
3. Prosthetic screw fracture
4. Implant fracture
5. Framework fracture.

Failures of implant-supported restorations result from technical problems and can be divided into two groups: those relating to implant components, and those relating to the prosthesis.^[7-9] Technical problems related to implant components include abutment screw fracture.^[9] Jung *et al.*, 2004 reported that prosthetic screw fracture has an incidence rate of 3.9% and the rate for prosthetic screw loosening is 6.7%.^[10] Fracture of prosthetic retaining screws is more common than implant fracture and it is normally due to a metal fatigue following an overload of materials. Though several systems from different manufacturers are available, a simple and unique non-invasive technique to retrieve the broken abutment screw is described in this case report.


Case Report

A 36-year-old male presented for treatment, reporting the detachment of an implant-supported crown in the region of the lower left first molar. The patient stated that the implant and crown had been placed 3 years earlier. Clinical examination of the patient revealed a missing tooth at the location of lower left first molar with no sign of an implant. The patient brought the abutment with cemented crown.

Radiographic examination of the area showed the presence of a root-form cylindrical implant, consistent in appearance with an 11.5 mm long, 4.2 mm diameter abutment with an internal hex. The implant appeared to be well-positioned in all three-dimensions (mesiodistal, buccolingual and apico-coronal) and the radiographic examination did not indicate any damage to the implant body.

Department of Periodontics and Implantology, Kamineni Institute of Dental Sciences, Narketpally, Andhra Pradesh, India

Correspondence: Dr. Jagadish Reddy Gooty,
Department of Periodontics and Implantology, Kamineni Institute of Dental Sciences, Narketpally - 508 254, Andhra Pradesh, India.
E-mail: drjagadishreddy@gmail.com

Access this article online	
Quick Response Code: 	Website: www.contempclindent.org
	DOI: 10.4103/0976-237X.132382

The apical part of the abutment screw remained threaded into the implant [Figure 1], but had fractured below the level of the hexagonal lock. Although the implant was osseointegrated, there were radiographic signs of periimplantitis with some crestal bone loss having occurred.

After anesthetizing the area, using the tissue punch, the implant was exposed. Using a ¼ round bur in a high-speed hand piece, a 1 mm deep pit was made across the most occlusal portion of the broken screw fragment [Figure 2]. The hand piece is held with both hands to avoid having the bur inadvertently jump into the implant body. Using ultrasonic scaler with no 3 tip placed in the pit prepared moving in anticlockwise direction slowly the broken abutment screw was retrieved [Figure 3]. Using close tray transfer impression was made and the model with implant analog and the abutment was sent to the lab for prosthesis preparation. Metal ceramic prosthesis was cemented to the abutment in position which was tightened to the implant body with screw which was torque to 35 N [Figure 4].

Discussion

The abutment screw fracture presents a rare, but quite unpleasant failure and can be a serious problem as the fragment remaining inside the implant may prevent the implant from functioning efficiently as an anchor.^[11] The primary reason for screw fracture is undetected screw loosening which can be due to bruxism, an unfavorable superstructure, overloading or malfunction.^[3] Fractures of the implant abutment or of the abutment screw have been observed as a consequence of screw loosening and undetected micro-movements of the abutment under functional loading^[12] and consequently, it is advised that the repeated loosening of an abutment screw should alert the clinician to possible significant contributing causes [Figure 5].

However, the behavior of the implant/abutment joint components with respect to critical bending force is still unclear.^[12] Studies show that implant abutment failure occurs when lateral forces exceed 370 N for abutment with a joint depth of at least 2.1 mm and 530 N with a joint depth of at least 5.5 mm.^[13]

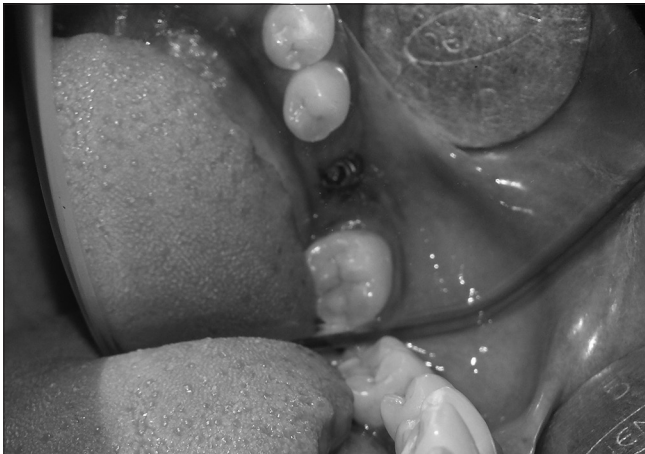


Figure 1: Broken abutment screw

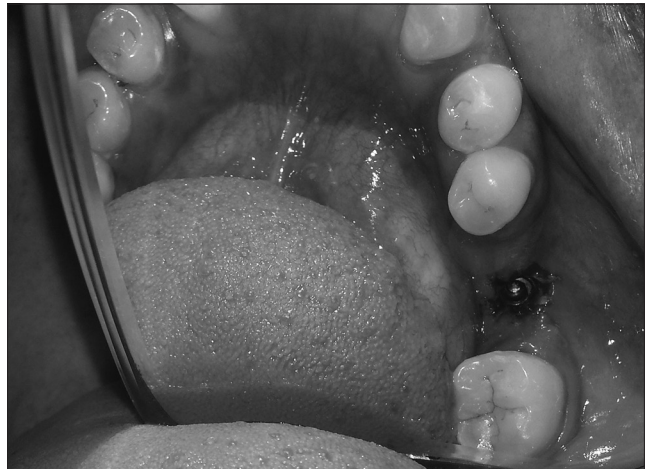

Figure 2: Slot prepared on the fractured screw

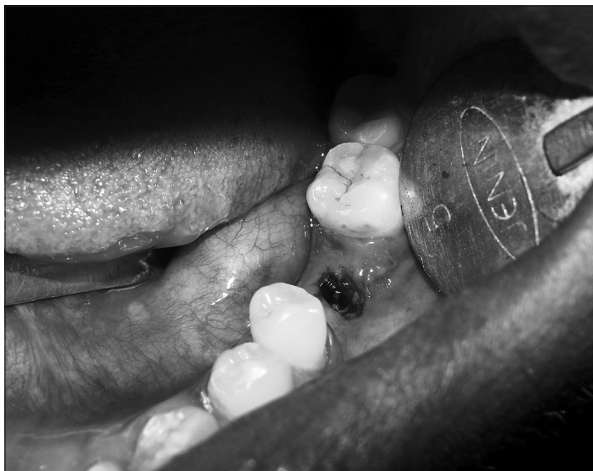

Figure 3: Abutment screw retrieved

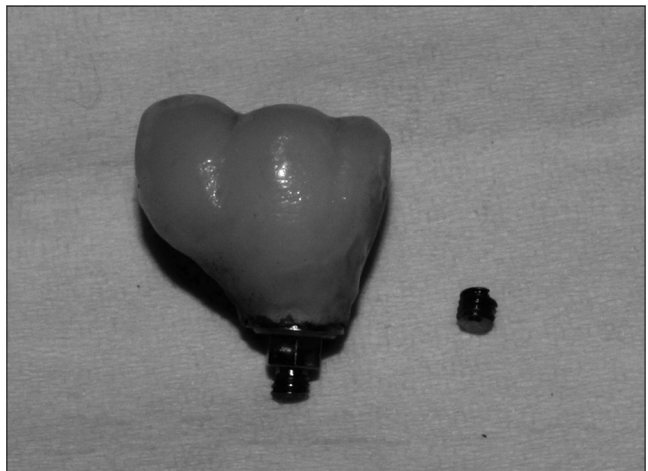


Figure 4: Cemented crown showing the broken screw part

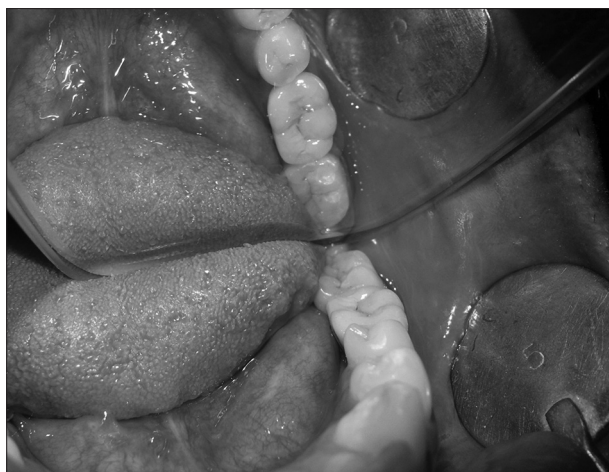

Figure 5: Final prosthesis placed

The number, position, dimension and design of implants, as well as the design of the prosthesis are critical factors to be considered during the treatment planning phase.^[14] To withstand high bending stresses, implants should be as long and as wide as possible, used in adequate numbers, and be positioned such as to allow axial loading.^[15,16] Implant components are known to fracture more frequently in the posterior region and in partially dentate patients compared to completely edentulous patients.^[16] Retightening an abutment screw 10 min after the initial torque applications should be routinely performed, and increasing the torque value for abutment screws above 30 N can be beneficial for the abutment, implant stability and to decrease the possibility of the screw becoming loose.^[17]

The methods employed to grasp the broken fragments or screw are determined according to the location of the fracture abutment-above or below the head of the implant. If an abutment screw fractures above the head of the implant, an explorer, a straight probe or hemostats might be successful.^[18] The tip of the instrument is moved carefully in a counter-clockwise direction over the surface of the screw segment until it loosens.^[3] If the screw fracture occurs below the head of the implant, other methods are required. There are several available implant repair kits:

- ITI® Dental Implant System (Institut Straumann AG, Switzerland), consists of drills, two drill guides and six manual tapping instruments^[8]
- IMZ® TwinPlus Implant System1 (Dentsply Friadent, Germany)
- Screw Removal Kit Replace (Nobel Biocare™, Yorba Linda, California, USA)
- Certain®-Screw Removal Kit (Biomet 3i™, Florida, USA).

Prosthesis screw fracture was noted almost equally with fixed complete dentures (3%) and fixed partial dentures (5%). The mean incidence was 4% but was found to range from 0.0% to 19%. Of 7094 screws evaluated, 282 fractured.^[7]

Conclusion

Abutment screw fracture, although uncommon, occurs in clinical practice. In most circumstances, the fractured end can be retrieved and replaced by a new abutment screw. However, sometimes the screw cannot be removed conservatively. By using rotary instruments, internal threads of the screw hole may be damaged and the implant rendered useless.

The use of osseointegrated implant-supported prostheses in the replacement of missing natural teeth has become an accepted clinical protocol in dentistry. Success in this area is enhanced through correct diagnosis, treatment planning, and maintenance; however, complications often occur, which may be significant and compromise the long-term success of the implant abutment and associated prosthesis. The management of such complications has given rise to several techniques to address failings, such as component fracture and bacterial contamination.

References

1. Wennström JL, Ekestubbe A, Gröndahl K, Karlsson S, Lindhe J. Implant-supported single-tooth restorations: A 5-year prospective study. *J Clin Periodontol* 2005;32:567-74.
2. Brånemark PI. Osseointegration and its experimental background. *J Prosthet Dent* 1983;50:399-410.
3. Nergiz I, Schmage P, Shahin R. Removal of a fractured implant abutment screw: A clinical report. *J Prosthet Dent* 2004;91:513-7.
4. el Askary AS, Meffert RM, Griffin T. Why do dental implants fail? Part II. *Implant Dent* 1999;8:265-77.
5. Brägger U, Aeschlimann S, Bürgin W, Hämmerle CH, Lang NP. Biological and technical complications and failures with fixed partial dentures (FPD) on implants and teeth after four to five years of function. *Clin Oral Implants Res* 2001;12:26-34.
6. Carlson B, Carlsson GE. Prosthodontic complications in osseointegrated dental implant treatment. *Int J Oral Maxillofac Implants* 1994;9:90-4.
7. Goodacre CJ, Bernal G, Rungcharassaeng K, Kan JY. Clinical complications with implants and implant prostheses. *J Prosthet Dent* 2003;90:121-32.
8. Behr M, Lang R, Leibrock A, Rosentritt M, Handel G. Complication rate with prosthodontic reconstructions on ITI and IMZ dental implants. *Internationales Team für Implantologie. Clin Oral Implants Res* 1998;9:51-8.
9. Luterbacher S, Fourmoussis I, Lang NP, Brägger U. Fractured prosthetic abutments in osseointegrated implants: A technical complication to cope with. *Clin Oral Implants Res* 2000;11:163-70.
10. Jung RE, Pjetursson BE, Glauser R, Zembic A, Zwahlen M, Lang NP. A systematic review of the 5-year survival and complication rates of implant-supported single crowns. *Clin Oral Implants Res* 2008;19:119-30.
11. Scarano A, Quaranta M, Traini T, Piattelli M, Piattelli A. SEM and fractography analysis of screw thread loosening in dental implants. *Int J Immunopathol Pharmacol* 2007;20(Suppl):19-22.
12. Bakaeen LG, Winkler S, Neff PA. The effect of implant diameter, restoration design, and occlusal table variations on screw loosening of posterior single-tooth implant restorations. *J Oral Implantol* 2001;27:63-72.
13. Möllersten L, Lockowandt P, Lindén LA. Comparison of strength and failure mode of seven implant systems: An *in vitro* test. *J Prosthet Dent* 1997;78:582-91.

14. Khraisat A. Stability of implant-abutment interface with a hexagon-mediated butt joint: Failure mode and bending resistance. *Clin Implant Dent Relat Res* 2005;7:221-8.
15. Sato Y, Shindoi N, Hosokawa R, Tsuga K, Akagawa Y. A biomechanical effect of wide implant placement and offset placement of three implants in the posterior partially edentulous region. *J Oral Rehabil* 2000;27:15-21.
16. Ashley ET, Covington LL, Bishop BG, Breault LG. Ailing and failing endosseous dental implants: A literature review. *J Contemp Dent Pract* 2003;4:35-50.
17. Piattelli A, Piattelli M, Scarano A, Montesani L. Light and scanning electron microscopic report of four fractured implants. *Int J Oral Maxillofac Implants* 1998;13:561-4.
18. Stevens PJ, Frederickson DJ, Gress ML. *Implant Prosthodontics: Clinical and Laboratory Procedures*. 2nd ed. St. Louis, (MO): Mosby, Inc.; 2000. p. 153-65.

How to cite this article: Gooty JR, Palakuru SK, Guntakalla VR, Nera M. Noninvasive method for retrieval of broken dental implant abutment screw. *Contemp Clin Dent* 2014;5:264-7.

Source of Support: Nil. **Conflict of Interest:** None declared.