




Efficacy of tantalum rod insertion for preventing femoral head collapse in osteonecrosis in a paediatric population: a pilot study

Muqtasid Hussaini ^{*}, Jitendra Balakumar and David Slattery

Department of Orthopaedics, Royal Children's Hospital Melbourne, 50 Flemington Road, Parkville, VIC 3052, Australia.

*Correspondence to: M. Hussaini. E-mail: worldmuq@gmail.com

ABSTRACT

Femoral head osteonecrosis in the paediatric population is difficult to treat, with the primary goals of management being prevention of subchondral collapse and the avoidance of early total hip replacement. This study aims to describe the use of a porous tantalum rod implant to provide mechanical support in preventing femoral head collapse in a paediatric population. A retrospective chart-based analysis of patients with osteonecrosis of the hip was performed at our institution to identify those who had undergone tantalum rod insertion. A total of 10 patients (fives males and five females, median age 12.5 years, 9–18) had tantalum rods implanted between December 2013 and February 2018. One patient was excluded due to follow-up at a different institution. The radiographic degree of osteonecrosis was characterized according to the Ficat classification and the Kerboul angle. Radiographic assessment of pre- and post-operative plain films was performed. The outcome measures were Tonnis grade and percentage collapse of the femoral head. Nine patients with a mean follow-up time of 18.4 months were included in the analysis. There was no significant increase in the femoral head collapse percentage post tantalum rod insertion compared to pre-operatively ($P = 0.63$). There was a significant increase in the Tonnis grade post-operatively ($P < 0.05$), with sub-group analysis showing minimal increase in Ficat Stage I patients. This study is the first to examine the role of tantalum rod insertion in preventing femoral head collapse in a paediatric population, with results suggesting potential benefit in a subset of patients.

INTRODUCTION

Avascular necrosis (AVN) is a challenging condition arising in both adult and paediatric populations. The femoral head is the most common site for this pathology [1]. The natural history of the condition is commonly progression to collapse of the femoral head [2–6]. Without effective treatment, this will result in loss of congruity between the femoral head and acetabulum with degeneration of the hip joint and osteoarthritis [2–7]. Thus AVN leads to pain, restricted mobility and often an early requirement for arthroplasty.

Common causes of AVN in children include trauma, slipped capital femoral epiphysis (SCFE), corticosteroid treatments, sickle cell disease, septic arthritis and chemotherapy treatments [8–10]. Idiopathic AVN has also been reported [8].

Treatment of AVN aims to prevent the progression of the disease and the need for total hip arthroplasty (THA) [11]. Non-surgical treatment has been described including non-weight bearing, physiotherapy and medications such as bisphosphonates and anti-hypercholesterolaemia agents [12, 13]. Surgical joint preserving techniques that have been described are decompression, decompression and non-vascularized or vascularized

bone grafting, trapdoor grafting, rotational osteotomies, tantalum rod insertion and various arthroscopic techniques [14, 15]. More recently this has involved the use of growth factors, stem cells, bone marrow aspirate concentrate and platelet-rich plasma as adjuncts to surgical techniques [16, 17].

Tantalum is a transition metal which has been manufactured into porous biomaterial for various orthopaedic applications. It has been demonstrated to have desirable characteristics for bone ingrowth in animal models [18]. A cylindrical tantalum rod of 10 mm diameter has been manufactured by Zimmer (NJ, USA) as an implant for AVN intervention.

Previous studies have explored the potential for tantalum rod insertion to prevent femoral head collapse in adult populations, with mixed results [7, 12, 14]. There has been minimal exploration into its use in a paediatric population. This study aims to assess the efficacy of tantalum rod insertion in preventing femoral head collapse in AVN in a paediatric population.

MATERIALS AND METHODS

A retrospective chart-based analysis of patients with avascular necrosis of the hip was performed at our institution to identify

Table I. Demographic characteristics and aetiology of included patients

No.	Age	Sex	Aetiology
1	11	F	Femoral neck fracture
2	13	M	SCFE
3	18	M	Septic arthritis
4	8	F	SCFE
5	12	F	SCFE
6	14	F	Chemotherapy
7	14	M	SCFE
8	12	F	SCFE
9	13	M	Femoral neck fracture

those who had undergone tantalum rod insertion. All patients who were identified with a minimum of 6 months of follow-up with X-rays were included in the study. A total of 10 patients (fives males and five females) with a median age of 12.5 years (range, 9–18 years) at the time of surgery had tantalum rods implanted between December 2013 and February 2018. One patient was excluded due to follow-up at a different institution. Five implants were in patients with AVN secondary to previous SCFEs, two in AVN due to femoral neck fractures, one in AVN following septic arthritis and one in AVN post-chemotherapy treatment (Table I). The operations were performed by four different fellowship trained surgeons (L.D., M.J., J.B. and D.S.). All nine were unilateral cases.

The degree of AVN was staged according to the modified Ficat classification outlined by Ficat in 1985 [19] and the Kerboul angle. This angle which was described by Kerboul *et al.* in 1974 was used to determine the extent of osteonecrosis by measuring the arc of the femoral head involved in necrosis on an AP as well as lateral radiograph, and calculating the sum of the two angles [20]. Kerboul angles were categorized as small (<150°), moderate (151–200°) or large (>200°). Of the nine patients, three were Ficat Stage I, three were Stage II and three were Stage III (Table II). Six patients had a large Kerboul angle, two patients had a moderate Kerboul angle and one patient had a small Kerboul angle (Table II). Patients were assessed radiologically for the progression of femoral head collapse and the progression of radiographic arthrosis. The most recent post-operative X-ray available at the time of data collection was used in the analysis.

Radiographic outcomes recorded included the Tonnis grade and percentage collapse of the femoral head seen.

Radiographic evaluation was performed by the authors of this study—two fellowship trained orthopaedic surgeons and a resident. In cases of a difference in scores, a discussion was had until consensus was reached.

Ethics

The study was classified as a clinical audit and ethics approval was obtained through the Royal Children's Hospital Human Research Ethics Committee with reference number QA/58895/RCHM-2019.

Surgical technique

All surgeons involved followed the same technique. Patients were placed in the supine position on a radiolucent table. A lateral approach to the proximal femur was utilized. Any existing metalware was identified and removed with intra-operative X-ray guidance. The entry point and rod trajectory in the femoral cortex was proximal to the lesser trochanter to reduce the risk of an iatrogenic fracture Fig. 1.

Statistics

Wilcoxon signed ranks test was used to compare pre-operative and post-operative collapse percentage and Tonnis grade. Analysis of variance was used to assess for any differences in pre- and post-operative collapse percentage and Tonnis grade according to Ficat stage. A *P* value of <0.05 was considered significant. Analyses were conducted using Stata version 12.0.

RESULTS

Nine patients were included in the final analysis with a mean follow-up of 18.4 months (range 6–48 months). Comparing collapse percentage of the femoral head pre- and post-operatively, there was an increase from a mean of 7.78 ± 15.22 to 10.66 ± 16.83 (Table II) which was not significant (*P* = 0.63). Sub-group analysis indicated that most of the increase in collapse percentage was in Ficat Stage II hips and there was minimal increase in Ficat Stage I, but this did not reach statistical significance (*P* = 0.06).

Comparing the Tonnis grade pre- and post-operatively, there was an increase from a mean of 0.56 ± 0.73 to 1.33 ± 1.22

Table II. Avascular necrosis classification and radiographic measurements of included patients

No.	Ficat	Kerboul angle	Pre-operative collapse %	Post-operative collapse %	Pre-operative Tonnis grade	Post-operative Tonnis grade
1	1	Large	0	4.9	1	2
2	3	Large	41.7	7.5	2	2
3	3	Small	3	2.5	0	1
4	2	Large	0	26	1	3
5	3	Moderate	25	50	1	1
6	1	Moderate	0	0	0	0
7	2	Large	0	5	0	1
8	2	Large	0	0	0	1
9	1	Large	0	0	0	0
		Mean	7.78	10.66	0.56	1.33
		Standard deviation	15.22	16.83	0.73	1.22

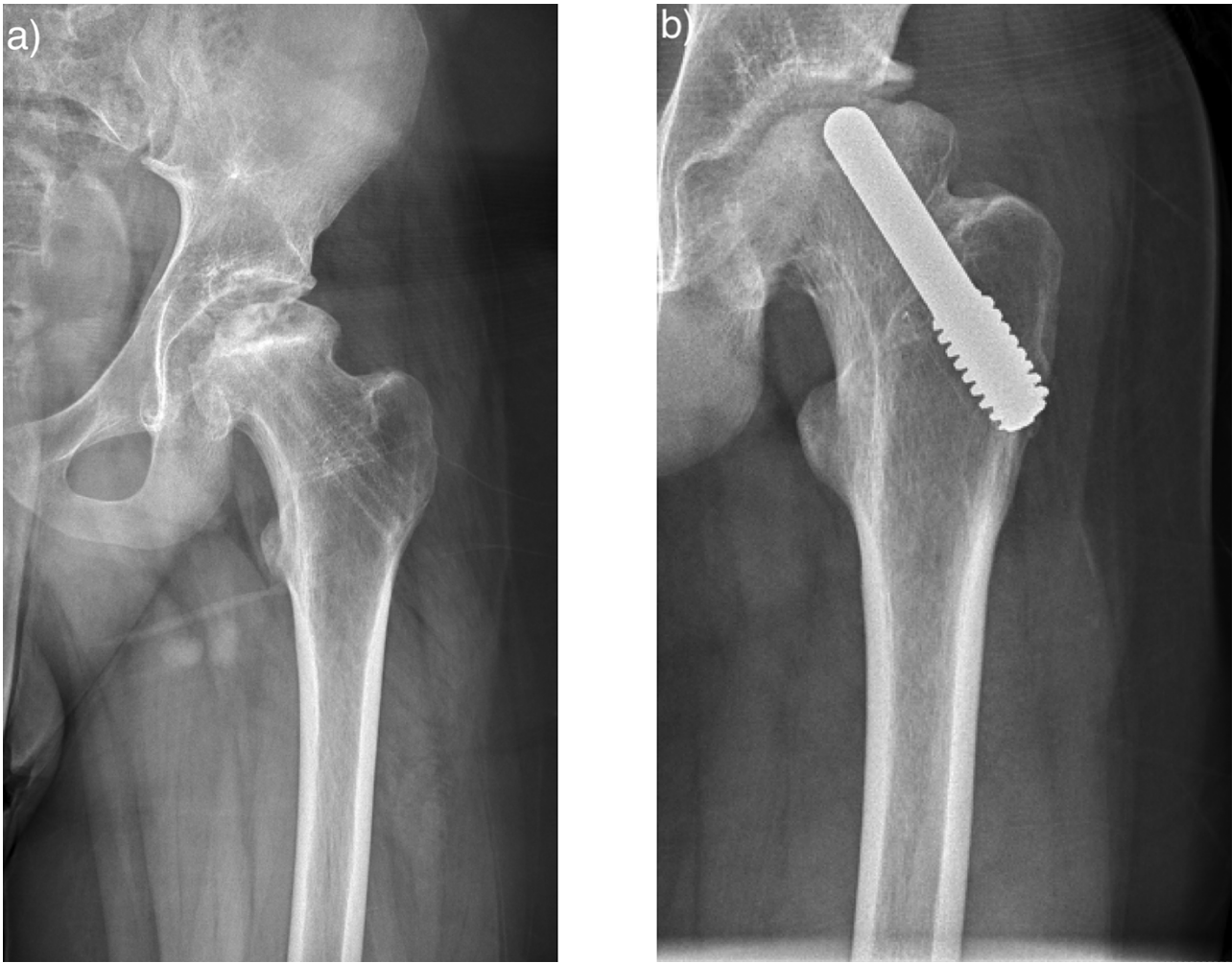


Fig. 1. Pre-operative radiograph prior to tantalum rod insertion (a) and post-operative radiograph at 14 months with tantalum rod *in situ* (b).

(Table II) which was significant ($P < 0.05$). Sub-group analysis indicated that most of the increase in Tonnis grade was in Ficat Stage II hips and there was minimal increase in Ficat Stage I, but this did not reach statistical significance ($P = 0.57$).

DISCUSSION

Femoral head AVN presents a difficult problem to manage in paediatric populations, where preservation of the native head and delay of THA is the goal of treatment. The aim in treatment with tantalum rod insertion is to provide support to the subchondral bone as well as the opportunity for bone ingrowth to help prevent progression to femoral head collapse.

The results of this study demonstrated that there was no significant worsening in collapse percentage overall with tantalum rod insertion, particularly in Ficat Stage I patients. While the Tonnis grade did increase overall, this occurred mainly in Ficat Stages II and III. The results indicate that there may be a role for tantalum rod insertion in preventing femoral head collapse in AVN, particularly in the pre-collapse stages. To the author's knowledge, this is the first study to examine the efficacy of tantalum rods in a paediatric population.

Our findings are in line with previous studies of tantalum rods in adult populations. Aldegheri *et al.* [12] examined Harris hip scores pre- and post-operatively in a series of 10 implants in patients with a mean age of 42 years and found that 90% showed a marked improvement with tantalum rod insertion with no further progression on MRI. Similarly, Vatrimeidis *et al.* [14] in a study of 26 hips found a significant clinical improvement as measured by Harris hip score post-operatively following tantalum rod insertion. Additionally, 50% of patients did not have radiographic progression of disease and the outcome was significantly better in patients with pre-collapse stages of disease. A recent systematic review which included 550 hips across 10 studies found a significant clinical improvement with tantalum rod insertion as measured by Harris hip score [21]. Additionally, they found that 77.9% of patients had stable lesions radiographically over a mean of 3.1 years.

In contrast, Ma *et al.* [7] concluded from a study of 104 hips that tantalum rod insertion with autologous bone grafting from the iliac crest was not a viable treatment option for osteonecrosis of the femoral head due to a significant worsening in Harris hip score, radiographic progression and conversion to THA. However, the authors did note that there was a significant difference

in radiographic progression between Association Research Circulation Osseous (ARCO) Stage II and III hips.

Tantalum rod insertion does not appear to have inferior outcomes when compared to other treatment methods. A meta-analysis by Zhang *et al.* [22] of six studies, three of which included data on Harris hip score, found that tantalum rod insertion improved scores significantly more than bone grafting with autogenous vascularized or non-vascularized bone. The meta-analysis included five studies which assessed post-operative femoral head collapse and found that it occurred significantly more in patients who underwent bone grafting compared to tantalum rod insertion [22]. Miao *et al.* [23] compared another common treatment, that of core decompression, against tantalum rod insertion for femoral head osteonecrosis. In a randomized prospective study of 60 patients, they found a significant improvement in the Harris hip score post tantalum rod insertion, but no significant difference in the score or in the radiographic stage when comparing the two treatment groups.

The potential need for future THA is an important consideration in the use of tantalum rods. Olsen *et al.* [11] examined 21 patients that required conversion to THA following previous tantalum rod insertion. When compared to a matched control group of patients that underwent THA for AVN without previous tantalum rod insertion, they found no significant difference in Harris hip scores or linear wear rates between the groups. Although there was a high rate of retained tantalum debris post-operatively, this did not impact outcomes in the short term (mean follow-up 4.2 years).

There were limitations to this study including its retrospective nature. The sample size made it difficult to extrapolate findings to a larger population; however, it may be considered a pilot study and future studies with a larger cohort size can build upon the findings with further sub-group analysis. The relatively short follow up period with a mean of 18.4 months was a limitation as it may have prevented potential progression to collapse at a later stage in some patients from being included in the analysis.

Due to the small sample size it was not possible to analyse for difference between the various aetiologies of AVN, surgeon involved and follow-up durations which may have been potential confounding variables. Additionally, due to the retrospective nature no clinical outcomes were measured and these may differ from the radiological outcomes. Future studies should consider incorporating this as an outcome measure.

CONCLUSION

Tantalum rods are one of a number of treatment options aimed at preventing femoral head collapse in AVN. Previous adult studies of tantalum rod insertion have demonstrated positive results in this regard [12, 14, 21]. To our knowledge, this is the first study involving paediatric patients. The results are in line with adult studies, indicating a potential role for tantalum rod insertion as part of treatment to prevent progression to femoral head collapse in AVN, particularly in pre-collapse stages. Future studies in a paediatric population should include a larger cohort size with clinical outcomes and monitoring for progression to THA with longer follow-up to allow for generalizability and comparison to existing studies.

DATA AVAILABILITY

The data underlying this article will be shared on reasonable request to the corresponding author.

FUNDING

No funding was received for this study.

CONFLICT OF INTEREST STATEMENT

None declared.

REFERENCES

1. Aaron RK, Voisin A, Racine J *et al.* Corticosteroid-associated avascular necrosis: dose relationships and early diagnosis. *Ann N Y Acad Sci* 2011; **1240**: 38–46.
2. Meyers MH. Osteonecrosis of the femoral head: pathogenesis and long-term results of treatment. *Clin Orthop Relat Res* 1988; **231**: 51–61.
3. Mont MA, Hungerford DS. Non-traumatic avascular necrosis of the femoral head. *J Bone Joint Surg* 1995; **77**: 459–74.
4. Hungerford DS. Osteonecrosis: avoiding total hip arthroplasty. *J Arthroplasty* 2002; **17**: 121–4.
5. Belmar CJ, Steinberg ME, Hartman-Sloan KM. Does pain predict outcome in hips with Osteonecrosis? *Clin Orthop Relat Res* 2004; **425**: 158–62.
6. Hungerford DS, Jones LC. Asymptomatic Osteonecrosis: should it be treated? *Clin Orthop Relat Res* 2004; **429**: 124–30.
7. Ma J, Sun W, Gao F *et al.* Porous tantalum implant in treating Osteonecrosis of the femoral head: still a viable option? *Sci Rep* 2016; **6**: 28227.
8. Assouline-Dayan Y, Chang C, Greenspan A *et al.* Pathogenesis and natural history of osteonecrosis. *Semin Arthritis Rheum* 2002; **32**: 94–124.
9. Boss JH, Misselevich I. Osteonecrosis of the femoral head of laboratory animals: the lessons learned from a comparative study of Osteonecrosis in man and experimental animals. *Vet Pathol* 2003; **40**: 345–54.
10. Larson AN, McIntosh AL, Trousdale RT *et al.* Avascular necrosis most common indication for hip arthroplasty in patients with slipped capital femoral epiphysis. *J Pediatr Orthop* 2010; **30**: 767–73.
11. Olsen M, Lewis PM, Morrison Z *et al.* Total hip arthroplasty following failure of core decompression and tantalum rod implantation. *Bone Joint J* 2016; **98-B**: 1175–9.
12. Aldegheri R, Tagliavero G, Berizzi A. The tantalum screw for treating femoral head necrosis: rationale and results. *Strategies Trauma Limb Reconstr* 2007; **2**: 63–8.
13. Cohen-Rosenblum A, Cui Q. Osteonecrosis of the femoral head. *Orthopedic Clin N Am* 2019; **50**: 139–49.
14. Varitimidis SE, Dimitroulias AP, Karachalios TS *et al.* Outcome after tantalum rod implantation for treatment of femoral head osteonecrosis: 26 hips followed for an average of 3 years. *Acta Orthop* 2009; **80**: 20–5.
15. Zhu J, Chen K, Peng J *et al.* Femoral neck rotational osteotomy: a modified method for treating necrotic femoral heads with large and laterally located lesions. *J Hip Preserv Surg* 2021; **7**: 713–20.
16. Houdek MT, Wyles CC, Collins MS *et al.* Stem cells combined with platelet-rich plasma effectively treat corticosteroid-induced Osteonecrosis of the hip: a prospective study. *Clin Orthop Relat Res* 2018; **476**: 388–97.
17. Kumar P, Shetty VD, Dhillon MS. Efficacy of orthobiologic adjuvants to core decompression for hip preservation in avascular necrosis hip. *J Hip Preserv Surg* 2021; **7**: 423–38.
18. Bobynd JD, Stackpool GJ, Hacking SA *et al.* Characteristics of bone ingrowth and interface mechanics of a new porous tantalum biomaterial. *J Bone Joint Surg Br* 1999; **81-B**: 907–14.

19. Ficat R. Idiopathic bone necrosis of the femoral head. Early diagnosis and treatment. *J Bone Joint Surg Br* 1985; **67-B**: 3–9.
20. Kerboul M, Thomine J, Postel M *et al*. The conservative surgical treatment of idiopathic aseptic necrosis of the femoral head. *J Bone Joint Surg Br* 1974; **56**: 291–6.
21. Onggo JR, Nambiar M, Onggo JD *et al*. Outcome of tantalum rod insertion in the treatment of osteonecrosis of the femoral head with minimum follow-up of 1 year: a meta-analysis and systematic review. *J Hip Preserv Surg* 2020; **7**: 329–39.
22. Zhang Y, Li L, Shi Z *et al*. Porous tantalum rod implant is an effective and safe choice for early-stage femoral head necrosis: a meta-analysis of clinical trials. *Eur J Orthop Surg Traumatol* 2013; **23**: 211–7.
23. Miao H, Ye D, Liang W *et al*. Effect of Osteonecrosis intervention rod versus core decompression using multiple small drill holes on early stages of necrosis of the femoral head: a prospective study on a series of 60 patients with a minimum 1-year-follow-up. *Open Orthop J* 2015; **9**: 179–84.