

## Armored Brain Associated with Secondary Craniostenosis Development at 7-year following Ventriculoperitoneal Shunt Surgery during Infancy: Extremely Unusual Association and Review

### Abstract

Calcification is uncommon in chronic subdural hematoma and popularly known as calcified chronic subdural hematoma (CCSDH), and about hundred cases are reported in the form of isolated cases report. The calcified inner membrane of chronic subdural hematoma gets adherent to underlying cerebral cortex preventing re-expansion of the brain and producing mass effect. Calcification can develop in chronic subdural hematoma of traumatic origin or postmeningitic effusion or extremely rarely after shunt surgery. CCSDH is also known as armored brain or Matrioska head and those related to cerebrospinal fluid diversion ventriculoperitoneal (VP) shunt surgery, constitute one of the rare complications of shunt, and development is attributed to overdrainage of shunt. Authors report a unique case with bilateral calcified chronic subdural hematoma in an 8-year-old boy, who had VP shunt surgery for obstructive hydrocephalus at the age of 1 year of life, presented with feature of nonlocalized raised intracranial pressure; a diagnosis of suspected VP shunt malfunction was also considered; however, cranial computed tomography scan on current admission revealed the presence of bilateral calcified chronic subdural hematoma with secondary craniostenosis and managed successfully with burr-hole craniostomy and drainage of CCSDH. In a detailed PubMed and Medline search, authors could not get any publication regarding CCSDH associated with secondary craniostenosis developing following VP shunt surgery in infancy. The current case represents the first case in the Western literature developing secondary craniostenosis-associated CCSDH following shunt surgery in infancy, requiring surgical management. The clinical features, neuroimaging, and management of such rare case along with pertinent literature are reviewed briefly.

**Keywords:** *Armored brain, bilateral calcification of chronic subdural hematoma, infancy, management, ventriculoperitoneal shunt surgery*

### Introduction

Chronic subdural hematoma is commonly seen in neurosurgical practice; however, calcification in the membrane of such hematoma is an extremely uncommon. Calcification is considered uncommon in chronic subdural hematoma and observed in about 0.3%–2.7% of cases of chronic subdural hematoma.<sup>[1,2]</sup> This complication has been rarely reported in cases suffering with hydrocephalus treated with shunt surgery.<sup>[1,3,4]</sup>

It involves calcification of the membranes of the subdural hematoma and typically form envelopes the brain like “armor,” which limits re-expansion and accordingly called an “armored brain” syndrome. CCSDH also produces mass effect on underlying brain parenchyma producing with its focal neurological deficits as

well as features of nonlocalized raised intracranial pressure; only few cases may warrant surgical intervention for relief of neurological deficit.<sup>[5]</sup> Authors report a unique case bilateral calcified chronic subdural hematoma in an 8-year-old boy underwent shunt surgery for hydrocephalus at the age of 1 year and developed secondary craniostenosis and managed with burr-hole craniostomy with drainage of CCSDH.

### Case Report

An 8-year-old boy presented with insidious headache, vomiting, and difficulty in walking and diminution of the vision for the past 6 months. Previous important history included medium pressure ventriculoperitoneal (VP) shunt surgery as he was diagnosed as congenital

**Guru Dutta  
Satyarthee,  
Sanjeev Lalwani<sup>1</sup>**

*Department of Neurosurgery,  
Neurosciences Centre, AIIMS,  
<sup>1</sup>Department of Forensic  
Medicine, AIIMS, New Delhi,  
India*

**Address for correspondence:**  
*Dr. Guru Dutta Satyarthee,  
Department of Neurosurgery,  
Room No 714, Neurosciences  
Centre, AIIMS,  
New Delhi - 110 029, India.  
E-mail: duttaguru2002@  
yahoo.com*

#### Access this article online

**Website:** [www.asianjns.org](http://www.asianjns.org)

**DOI:** 10.4103/ajns.AJNS\_263\_16

#### Quick Response Code:



**How to cite this article:** Satyarthee GD, Lalwani S. Armored brain associated with secondary craniostenosis development at 7-year following ventriculoperitoneal shunt surgery during infancy: Extremely unusual association and review. *Asian J Neurosurg* 2018;13:1175-8.

This is an open access journal, and articles are distributed under the terms of the Creative Commons Attribution-NonCommercial-ShareAlike 4.0 License, which allows others to remix, tweak, and build upon the work non-commercially, as long as appropriate credit is given and the new creations are licensed under the identical terms.

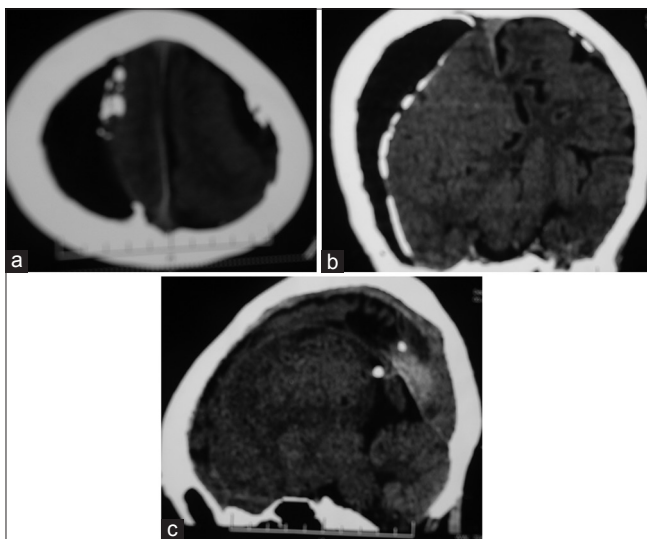
**For reprints contact:** [reprints@medknow.com](mailto:reprints@medknow.com)

hydrocephalus, for which he underwent right parietal burr hole and shunt insertion at the age of 1 year. Examination at current admission revealed vital stable; neurological examination revealed mild impairment of recent memory, left-sided upper motor neuron seventh nerve paresis, and left-sided hemiparesis of grade 4/5. Noncontrast computed tomography (CT) scan revealed asymmetrical bilateral frontoparietal calcified CCSDH with relatively larger sizes on the right side [Figure 1a-c]. The tip of VP shunt was lying in the lateral ventricle and presents *in situ* with well-decompressed ventricles [Figure 2]. Three-dimensional reconstruction of the skull revealed the presence of craniostenosis [Figure 3]. Although cerebral decongestant was prescribed, it did not respond. VP shunt chamber was well compressible and refilling suggesting well functioning VP shunt. Hence, plan was made to carry our burr-hole craniostomy and drainage of subdural collection under general anesthesia.

He underwent right frontal burr hole and evacuation of subdural collection. He tolerated surgical procedure well. His headache completely subsided but had only partial improvement of the visual acuity in the postoperative period. He was doing well at the last follow-up 1 year following drainage of chronic subdural hematoma. However, parents were not willing for any kind of surgical intervention for management for craniostenosis.

## Discussion

A calcified chronic subdural hematoma (CCSDH) is extremely uncommon occurrence.<sup>[1-18]</sup> Calcification in a traumatic subdural hematoma is relatively more common than the subdural collections of postmeningitic and VP shunt origin. It is more frequently seen in children though

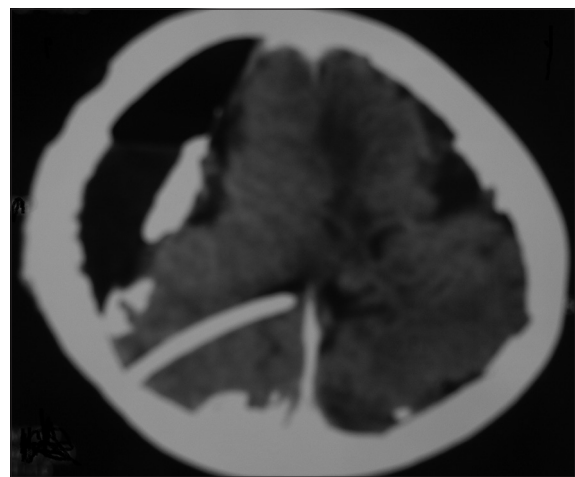


**Figure 1:** Computed tomography scan of the head of an 8-year-old boy showing asymmetrical bilateral frontoparietal calcified chronic subdural hematoma following ventriculoperitoneal shunt surgery. The calcification was more marked on the right side compared to the left-sided (a) axial section (b) coronal section formatted image, and (c) sagittal reconstruction

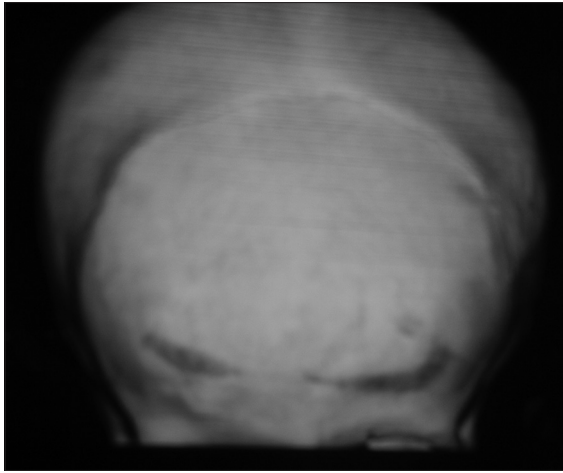
it has been described in all age groups.<sup>[6]</sup> The time interval required for the development of calcification following hematoma formation has been reported to vary from 6 months to many years. It can occur following head trauma, postmeningitic or shunt surgery. The CCSDH developing following cerebrospinal fluid (CSF) diversion surgery is caused and attributed to overdrainage of CSF.<sup>[5,7,8]</sup>

Calcified Chronic Subdural hematoma (CCSDH) is also called armored brain. In 2012, Taha could able to collect only ten cases of isolated CCSDH, occurring following shunt surgery, in his detailed literature search, who developed during the very first decade of life, but none of the analyzed cases had additional association of secondary craniostenosis.<sup>[2]</sup> The exact mechanism of osseous transformation is lacking. Many postulates are put forward to explain the pathogenesis of CCSDH including injury to the highly vascular tissues, i.e., dura matter, skull bones provoking inflammatory response and although healing is comparatively more rapid in children than the adult counterpart. The shunted side, lateral ventricle used to be continuously draining CSF, hence ipsilateral brain fails to re-expand, and this could promote the persistence of subdural hematoma cavity for a prolonged period, and prolonged stasis of subdural collection may initiate and promote future calcification.<sup>[8]</sup>

Sarkar *et al.* observed eosinophilic infiltration in the vascularized and hyalinized granulation tissue of the subdural membrane in approximately half of the specimens removed during operative procedure.<sup>[10]</sup> The connective tissue growth extending from hematoma margin to the cranial vault, which ultimately gets hyalinized with calcium deposition subsequently under poor circulation or malabsorption of the subdural hematoma content.<sup>[9,10]</sup> However, microscopic calcium deposits noticed after month, may progress to extensive calcification and eventually ossifications in few cases. An underlying poor circulation, metabolic abnormality, and craniostenosis are possible hypothesis for development.<sup>[1,2]</sup>



**Figure 2:** Cranial computed tomography scan showing ventricular catheter tip of ventriculoperitoneal shunt *in situ* with well-decompressed lateral ventricles



**Figure 3: Three-dimensional reconstruction image of the skull showing the presence of craniostenosis and fused bilateral coronal sutures with ridge-like appearance**

Patients are usually asymptomatic and those symptomatic cases may develop symptoms many years following surgical shunt placement. It can present with features of raised intracranial tensions such as headache, vomiting, failure to thrive, seizures, and even rarely mental retardation.<sup>[1,3]</sup> Unlike to adult, CCSDH in children may present with seizures and mental retardation; however, many asymptomatic cases are also picked up incidentally.<sup>[5]</sup> The clinical presentation of patients with “armored brain” is characterized by a slow progression of neurological signs and symptoms. While the majority of patients remain asymptomatic, symptoms can include gait disturbance, chronic headache, deteriorating vision, epileptic seizure, dysphasia, behavioral problems, and paresis.

CT scan head or magnetic resonance imaging brains are helpful in confirmation of diagnosis. More common differentials include calcification in meningioma and epidural hematoma calcification.

Management of calcified CSH is controversial; management option includes observation, cerebral decongestant, or surgical intervention. The conservative treatment modalities are also advocated for those patients, who are either elderly or asymptomatic.<sup>[2]</sup> However, asymptotic cases discovered incidentally may be followed up and managed conservatively as only few cases need surgical management.<sup>[19]</sup>

Surgical interventions are recommended for patients with progressive neurological deficits or raised intracranial tension.<sup>[2,3]</sup> The surgical treatment options for armored brain cases include shunt revision, burr-hole craniostomy, or craniotomy, and drilling of calcified subdural membrane should be made judiciously. The surgical procedure of craniotomies and drilling of calcified membranes carry risk of injury to the underlying brain.<sup>[14]</sup> In cases where the etiology of armored brain is secondary to shunt overdrainage, the management plan may differ.

Salunke *et al.* offer alternative method of revision surgery of the VP shunt citing existence of fine-tune balance created between the overdraining shunt and the subdural collections, which is disturbed with shunt block and causes masking of obstructive hydrocephalus, as the brain cannot re-expand due to the presence of the already calcified membranes.<sup>[15]</sup>

Our cases underwent burr-hole evacuation with good result as burr-hole drainage can also offer an equivalent relief similar to craniotomy, with a lesser morbidity and mortality and relatively very short hospital stay. However, craniotomy is advocated in cases with recurrent hematoma reaccumulates after repeated burr-hole evacuation of CCSDH or residual hematoma membranes, which prevent re-expansion of the brain and persisting failure to obliteration of the cavity.<sup>[4]</sup>

Salunke *et al.* observed the burr-hole tapping of subdural collections may provide transient improvement, which may last only for few days. Although drilling of the calcified membranes may be carried and permitting re-expansion of the brain.<sup>[15]</sup> However, shunt revision is relatively much simpler surgical procedure associated with lesser morbidity and emphasized fresh VP shunt, or shunt revision should be standard method of care for the armored brain syndrome cases, especially who were asymptomatic for years and suddenly getting symptomatic. The more extensive procedure of craniotomy and drilling the calcified membranes should be considered only in those patients who fail to respond to shunt surgery.<sup>[15]</sup>

## Conclusion

Every case of hydrocephalus, managed with VP shunt surgery in the past, if presents during follow-up period with features of fresh neurological deficits, the possibility of developing calcified chronic subdural hematoma also needs to be considered, although incidence is much rare; however, a high degree of clinical suspicion is required for diagnosis of CCSDH. An early diagnosis and appropriate management is essential. Although every case does not warrant management intervention, who is diagnosed incidental on neuroimaging. Ideally, the therapeutic management options should be tailored made depending on focal neurological deficit, march of progression of neurological deficits, volume of chronic subdural hematoma, associated degree mass effects, and response to conservative therapy.

## Financial support and sponsorship

Nil.

## Conflicts of interest

There are no conflicts of interest.

## References

1. Goyal PK, Singh D, Singh H, Dubey J, Tandon M. Armoured brain of unknown etiology. *Asian J Neurosurg* 2013;8:165.
2. Taha MM. Armored brain in patients with hydrocephalus

- after shunt surgery: Review of the literatures. *Turk Neurosurg* 2012;22:407-10.
3. Amr R, Maraqa L, Choudry Q. 'Armoured brain'. A case report of a calcified chronic subdural haematoma. *Pediatr Neurosurg* 2008;44:88-9.
  4. Kaspera W, Bierzynska-Macyszyn G, Majchrzak H. Chronic calcified subdural empyema occurring 46 years after surgery. *Neuropathology* 2005;25:99-102.
  5. Ide M, Jimbo M, Yamamoto M, Umebara Y, Hagiwara S. Asymptomatic calcified chronic subdural hematoma – Report of three cases. *Neurol Med Chir (Tokyo)* 1993;33:559-63.
  6. Sharma RR, Mahapatra A, Pawar SJ, Sousa J, Athale SD. Symptomatic calcified subdural hematomas. *Pediatr Neurosurg* 1999;31:150-4.
  7. Garg K, Singh PK, Singla R, Chandra PS, Singh M, Satyarthee GD, *et al.* Armored brain-massive bilateral calcified chronic subdural hematoma in a patient with ventriculoperitoneal shunt. *Neurol India* 2013;61:548-50.
  8. Imaizumi S, Onuma T, Kameyama M, Naganuma H. Organized chronic subdural hematoma requiring craniotomy – Five case reports. *Neurol Med Chir (Tokyo)* 2001;41:19-24.
  9. Markwalder TM. The course of chronic subdural hematomas after burr-hole craniostomy with and without closed-system drainage. *Neurosurg Clin N Am* 2000;11:541-6.
  10. Sarkar C, Lakhtakia R, Gill SS, Sharma MC, Mahapatra AK, Mehta VS. Chronic subdural haematoma and the enigmatic eosinophil. *Acta Neurochir (Wien)* 2002;144:983-8.
  11. Arán-Echabe E, Frieiro-Dantas C, Prieto-González Á. Chronic calcified subdural haematoma: Armoured brain. *Rev Neurol* 2014;58:420-1.
  12. Borkar SA, Satyarthee GD, Mahapatra AK. Armoured brain syndrome: Chronic calcified subdural haematoma. *Pan Arab J Neurosurg* 2013;17:1-4.
  13. Niwa J, Nakamura T, Fujishige M, Hashi K. Removal of a large asymptomatic calcified chronic subdural hematoma. *Surg Neurol* 1988;30:135-9.
  14. Oda S, Shimoda M, Hoshikawa K, Shiramizu H, Matsumae M. Organized chronic subdural haematoma with a thick calcified inner membrane successfully treated by surgery: A case report. *Tokai J Exp Clin Med* 2010;35:85-8.
  15. Salunke P, Aggarwal A, Madhivanan K, Futane S. Armoured brain due to chronic subdural collections masking underlying hydrocephalus. *Br J Neurosurg* 2013;27:524-5.
  16. Galldiks N, Dohmen C, Neveling M, Fink GR, Haupt WF. A giant bilateral calcified chronic subdural hematoma. *Neurocrit Care* 2010;12:272-3.
  17. Dammers R, ter Laak-Poort MP, Maas AI. Neurological picture. Armoured brain: Case report of a symptomatic calcified chronic subdural haematoma. *J Neurol Neurosurg Psychiatry* 2007;78:542-3.
  18. Al Wohaibi M, Russell N, Al Ferayan A. A baby with an armoured brain. *CMAJ* 2003;169:46-7.
  19. Satyarthee GD, Pankaj D, Sharma BS. "Rabbit Ear" scalp deformity caused by massive subdural effusion in infant following bilateral burr-hole drainage. *J Pediatr Neurosci* 2013;8:235-8.