

 **Case Report** 

Prevention from Atheroembolization during Thoracic Endovascular Aortic Repair in Patients with Severe Atherosclerosis in the Aorta

Takashi Yamauchi, MD, PhD, Suguru Kubota, MD, PhD, and Kosei Hasegawa, MD

Postoperative ischemic complications, especially cerebral infarction due to atheroembolization following thoracic endovascular aortic repair, can be catastrophic. Herein, we present a maneuver of prevention of cerebral infarction using temporary cerebral arterial perfusion from the femoral artery, with the extracorporeal circuit including roller pump and filter in case of severe atherosclerotic change in thoracic aorta.

Keywords: thoracic endovascular aortic repair (TEVAR), stroke, extracorporeal circulation

Introduction

During thoracic endovascular aortic repair (TEVAR), severe atherosclerosis, the so-called “shaggy aorta,” is problematic for cardiovascular surgeons due to its ischemic complications. Among these ischemic complications, cerebral infarction (CI) is one of the most disastrous complications. The reported occurrence of stroke following TEVAR involving the cervical branch of the aortic arch ranges from 0% to 28.6%.^{1,2)} In addition to CI, cholesterol crystal embolism to the lower limbs has a poor prognosis and might often be fatal.³⁾ A technique of blocking total antegrade cerebral perfusion during the wire operation and the deployment of a stent graft (SG) may prevent such


complications. In thoracic aortic surgery, the reconstruction of arch vessels under hypothermic circulatory arrest or selective antegrade perfusion is widely used to avoid CI; however, in TEVAR, hypothermic circulatory arrest is difficult to perform, and selective perfusion is less common. This article aims to describe a maneuver of preventing CI in this pathology.

Case Report

A 75-year-old woman with a history of old myocardial infarction, mitral valve replacement, and coronary artery bypass grafting was referred to our hospital for surgical treatment for a thoracic aortic aneurysm. Computed tomography (CT) image revealed an enlarged proximal descending aorta (maximum diameter: 62 mm) with severe atherosclerotic change at the aortic arch (**Fig. 1a**). Both open surgical repair and TEVAR seemed to pose a sufficiently high operative risk. Due to the patient's history of cardiac surgery, including coronary artery bypass grafting, and reduced cardiac function (ejection fraction: 25%), we considered TEVAR to be more appropriate, and 2-debranching TEVAR was scheduled. In the present case, the proximal landing zone was very shaggy; therefore, we determined that a longer landing zone was necessary. In order to prevent CI, we blocked the total antegrade blood flow from the heart during SG deployment and wire operation, followed by arterial cerebral perfusion from the femoral artery (FA) to the prosthetic graft for the debranching graft. This maneuver can be seen in **Fig. 2**. We exposed and anastomosed the bilateral axillary artery (AxA) and the left common carotid artery (LCCA) with an 8-mm prosthetic Dacron graft (FUSION Vascular Graft, Maquet Cardiovascular, Wayne, NJ, USA) for debranching after systemic heparinization (100 U/kg). Following completion of debranching, we ligated the LCCA at the proximal site of anastomosis and anastomosed the Dacron graft to the graft for debranching at the site near the right AxA for total antegrade cerebral perfusion from the circuit of extracorporeal circulation (ECC). We performed arterial drainage (16 Fr) from the site opposite to the FA used for

Department of Cardiovascular Surgery, KKR Sapporo Medical Center, Sapporo, Hokkaido, Japan

Received: August 6, 2018; Accepted: December 27, 2018
Corresponding author: Takashi Yamauchi, MD, PhD. Department of Cardiovascular Surgery, KKR Sapporo Medical Center, 6-3-40 Ichijo Hiragishi, Toyohira, Sapporo, Hokkaido 062-0931, Japan
Tel: +81-11-822-1811, Fax: +81-11-841-4572
E-mail: yamataka@surg1.med.osaka-u.ac.jp

 ©2019 The Editorial Committee of Annals of Vascular Diseases. This article is distributed under the terms of the Creative Commons Attribution License, which permits use, distribution, and reproduction in any medium, provided the credit of the original work, a link to the license, and indication of any change are properly given, and the original work is not used for commercial purposes. Remixed or transformed contributions must be distributed under the same license as the original.

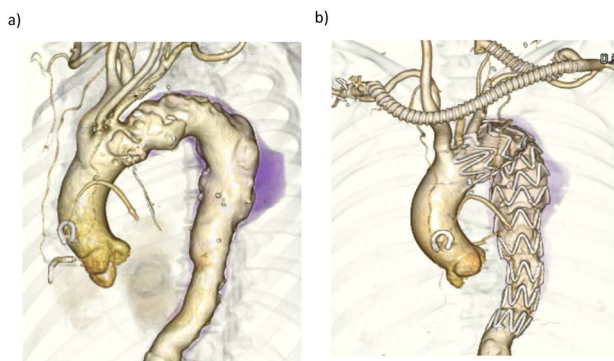


Fig. 1 (a) Preoperative three-dimensional computed tomography images showed a proximal descending aortic aneurysm with severe atherosclerotic change in the aortic arch and the descending aorta. (b) Postoperative computed tomography images showed no endoleak.

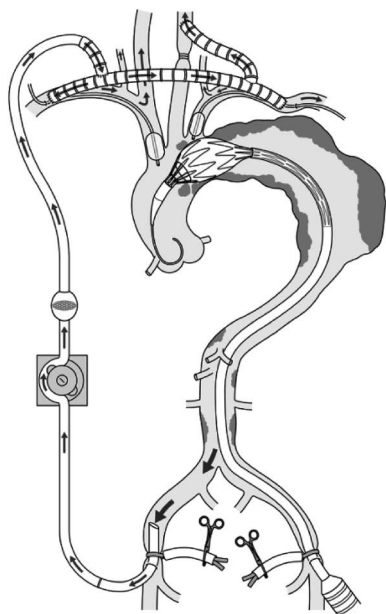


Fig. 2 Schema of our maneuver for preventing stroke and atheroembolization in the lower limbs using extracorporeal circulation with a filter during thoracic endovascular aortic repair.

the SG delivery. ECC circuits, consisting of a roller pump and filter without an oxygen membrane, were connected with the Dacron graft for cerebral perfusion and the arterial drainage cannula from the FA. We expected the filter to remove the debris from the upper blood stream during TEVAR. The occlusion balloons intended for inflation in the brachiocephalic artery (BCA) and the left subclavian artery (LSCA) were inserted via the right and left AxA, respectively. For preventing a thromboembolic event during the graft anastomosis with the LCCA and the balloon inflation in the BCA and LSCA, we performed carotid echography and enhanced CT, and confirmed that there

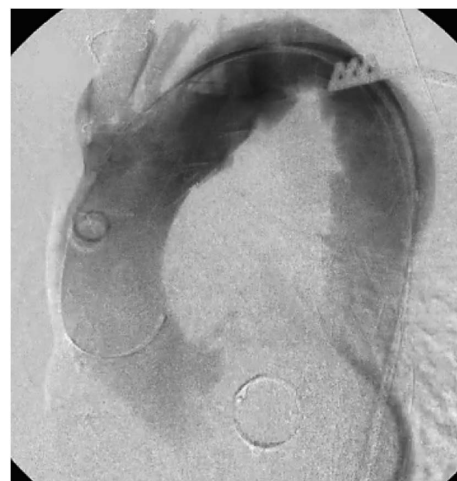

Fig. 3 Digital subtraction angiography. A stent graft was deployed with balloon occlusion of the brachiocephalic artery and the left subclavian artery. The left common carotid artery was ligated.

was no atherosclerotic change in these vessels. We initiated ECC at the flow rate of 500–600 ml/min and the balloon occlusion of the BCA and LCCA under the monitoring of cerebral near-infrared spectroscopy. After confirming that the saturation of the brain was preserved, we proceeded and placed the soft guidewire (Radifocus® Guidewire MR-FGA35303, Terumo Corporation, Tokyo, Japan) in the ascending aorta and changed by the stiff guidewire (Egoist® Interventional Guide Wire Double J Curve 300cm, Medico's Hirata Inc., Osaka, Japan) using a pigtail catheter from the FA. Subsequently, we placed a SG (RELAY PLUS 38-34-250mm, Bolton Medical, Sunrise, FL, USA) in the planned position and deployed it, followed by embolization to the LSCA (AMPLATZER Vascular Plug 12 mm, AGA medical corporation, North Plymouth, MN, USA) (Fig. 3). We predicted that each procedure (wire and catheter passage and removal, SG deployment) might produce floating debris from the atherosclerotic aortic wall, which might detach from the aortic wall shortly afterwards. Therefore, we deflated the balloon several minutes after the removal of the wire, catheter, and device; we then discontinued ECC.

Following the removal of the delivery system of the SG, we deflated the inflated balloon at the origin of the BCA and LSCA to restore antegrade cerebral blood flow from the heart. Subsequently, we discontinued ECC and the ligation of the prosthetic graft for cerebral perfusion. In the present case, the total ECC time was 59 min.

After awakening from anesthesia, the patient showed no neurological deficit. She was claustrophobic; therefore, it was difficult to perform magnetic resonance imaging. Hence, we performed both pre- and postoperative head CT. There was no evidence of new CI. Although the SG

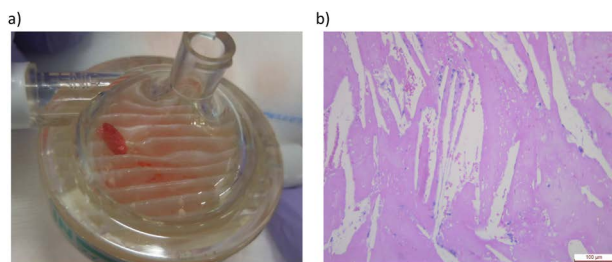


Fig. 4 (a) Postoperative macroscopic findings of the filter showed various large and small emboli trapped in the filter, likely from the atherosclerotic aortic wall during thoracic endovascular aortic repair via the femoral arterial cannula. (b) Hematoxylin and eosin staining showed cholesterol crystal embolism.

did not cover the LCCA as preoperatively planned, we observed no endoleak (Fig. 1b). Debris was captured by the filter (Fig. 4a), and its histological study confirmed cholesterol crystal embolism (Fig. 4b).

Discussion

Several reports have documented maneuver of preventing CI in patients undergoing TEVAR, including using a filter cerebral embolic protection device⁴⁾ or employing ECC.⁵⁾ With regard to the protection device, Grover et al. noted its feasibility but also showed that it could not prevent asymptomatic CI, which was diagnosed using diffusion-weighted magnetic resonance.⁴⁾ The maneuver described in the present report involves the total blockage of antegrade cerebral blood flow from the heart through the application of temporal cerebral perfusion using ECC without an oxygen membrane and using the bypass graft for debranching. This maneuver is applicable under the following circumstances. Firstly, the patient should have a thoracic aortic arch aneurysm with severe atherosclerotic change in the aortic arch and be a candidate for TEVAR instead of open surgery due to comorbidity. Secondly, the length of the proximal landing zone for TEVAR should be zone 0 or 1, which requires 2-debranching, because the temporary blockage of total antegrade cerebral blood flow from the heart is possible through ligation of the LCCA and the balloon occlusion of the LSCA and BCA. Thirdly, the atrial wall of the site of the balloon occlusion in the LSCA and BCA should have less atherosclerotic change. Ryomoto et al. have reported that endovascular aortic arch repair with mini-cardiopulmonary bypass can prevent stroke. Their concept regarding the prevention of CI is similar to that of our maneuver.⁵⁾ The differences between their excellent report and our report are as follows: Firstly, they employed venous drainage from the femoral vein and extracorporeal membrane oxygenation (ECMO), while we drained from the FA without employing ECMO. Sec-

ondly, they did not employ balloon occlusion of the BCA. The merits of our maneuver are as follows: Firstly, there is almost no time limit for the procedure from soft wire insertion to coiling because cerebral perfusion is guaranteed by ECC without ECMO. Secondly, antegrade cerebral blood flow can be completely and totally blocked, which is strongly expected to prevent stroke. Thirdly, the embolic debris occurring during the procedure at one lower limb may be captured by the filter through the femoral arterial drainage cannula. The opposite side of the lower limb seems less likely to experience a thromboembolic event due to the presence of the SG device in the common and external iliac artery. The drawback of our maneuver is that ECC, which is not usually required during TEVAR, must be established. The application of ECC for TEVAR is not common and seems bothersome; therefore, we do not advocate for the routine use of this maneuver. Surgeons should be aware of the complications of ECC, such as systemic inflammation and renal impairment. Therefore, the maneuver described in the present report should be limited to patients whose systemic atherosclerosis includes the ascending aorta and the aortic arch.

Conclusion

We reported a maneuver for preventing CI using temporary cerebral arterial perfusion with ECC in a case with severe atherosclerotic change in the thoracic aorta. Our reported maneuver might be a therapeutic option for preventing atheroembolization during TEVAR.

Acknowledgments

We greatly appreciate our excellent perfusionist, Naohiro Ogura, who perfectly controlled ECC during the operation in the present study.

Disclosure Statement

All authors have no conflict of interest.

Author Contributions

Writing: TY
 Critical review and revision: all authors
 Final approval of the article: all authors
 Accountability for all aspects of the work: all authors

References

- 1) Shirakawa Y, Kuratani T, Shimamura K, et al. The efficacy and short-term results of hybrid thoracic endovascular repair into the ascending aorta for aortic arch pathologies. *Eur*

- J Cardiothorac Surg 2014; 45: 298-304; discussion, 304.
- 2) Hiraoka A, Chikazawa G, Tamura K, et al. Clinical outcomes of different approaches to aortic arch disease. J Vasc Surg 2015; 61: 88-95.
 - 3) Sekine Y, Furutake T, Kusahara T, et al. Lethal cholesterol crystal embolization syndrome after operation for abdominal aortic aneurysm. Kyobu Geka 2011; 64: 195-9. (in Japanese)
 - 4) Grover G, Perera AH, Hamady M, et al. Cerebral embolic protection in thoracic endovascular aortic repair. J Vasc Surg 2018; May 24. [Epub ahead of print]
 - 5) Ryomoto M, Tanaka H, Kajiyama T, et al. Endovascular aortic arch repair with mini-cardiopulmonary bypass to prevent stroke. Ann Vasc Surg 2016; 36: 320-4.