



Original Article

## Mini-open thoracoscopic-assisted spinal thoracotomy for traumatic injuries: A technical note

Vikas Tandon, Abhinandan Reddy Mallepally, Ashok Reddy Peddaballe, Nandan Marathe, Harvinder Singh Chhabra

Spine Services, Indian Spinal Injuries Centre, New Delhi, India.

E-mail: Vikas Tandon - vikas.spinesurgeon@gmail.com; \*Abhinandan Reddy Mallepally - mabhi28@gmail.com; Ashok Reddy Peddaballe - drashokreddy@gmail.com; Nandan Marathe - nandanmarathe88@gmail.com; Harvinder Singh Chhabra - issicon@isiconline.org



**\*Corresponding author:**

Abhinandan Reddy Mallepally,  
Spine Services, Indian Spinal  
Injuries Centre, New Delhi,  
India.

mabhi28@gmail.com

Received : 14 July 2020

Accepted : 13 August 2020

Published : 29 August 2020

**DOI**

10.25259/SNI\_435\_2020

**Quick Response Code:**



### ABSTRACT

**Background:** Mini-open thoracoscopic-assisted thoracotomy (MOTA) has been introduced to mitigate disadvantages of conventional open anterior or conventional posterior only thoracoscopic procedures. Here, we evaluated the results of utilizing the MOTA technique to perform anterior decompression/fusion for 22 traumatic thoracic fractures.

**Methods:** There were 22 patients with unstable thoracic burst fractures (TBF) who underwent surgery utilizing the MOTA thoracotomy technique. Multiple variables were studied including; the neurological status of the patient preoperatively/postoperatively, the level and type of fracture, associated injuries, operative time, estimated blood loss, chest tube drainage (intercostal drainage), length of hospital stay (LOS), and complication rate.

**Results:** In 22 patients (averaging 35.5 years of age), T9 and T12 vertebral fractures were most frequently encountered. There were 20 patients who had single level and 2 patients who had two-level fractures warranting corpectomies. Average operating time and blood loss for single-level corpectomy were  $91.5 \pm 14.5$  min and 311 ml and  $150 \pm 18.6$  min and 550 ml for two levels, respectively. Mean hospital stay was 5 days. About 95.45% of cases showed fusion at latest follow-up. Average preoperative kyphotic angle corrected from  $34.2 \pm 3.5^\circ$  to  $20.5 \pm 1.0^\circ$  postoperatively with an average correction of 41.1% and correction loss of 2.4%.

**Conclusion:** We concluded that utilization of the MOTA technique was safe and effective for providing decompression/fusion of traumatic TBF.

**Keywords:** Burst fracture, Mini-open, Thoracic, Thoracoscopic, Thoracotomy

### INTRODUCTION

Management of acute traumatic fractures of thoracic and thoracolumbar spine has varied widely with time and individual surgeon preferences. Previous operations have included posterior only surgery versus anterior only surgery versus combined anterior/posterior surgical stabilization.<sup>[10]</sup> However, open anterior approaches and posterior only approaches for corpectomies are morbid procedures with typically high complication rates.

Mini-open thoracoscopic-assisted thoracotomy (MOTA) spine surgery has been introduced to mitigate the complications of anterior only, posterior only, or 360 procedures. It also has advantages of being minimally invasive while providing a direct vision of the pathological site in three dimensions rather than two-dimensional images of thoracoscopy. There is, however, a paucity of literature

This is an open-access article distributed under the terms of the Creative Commons Attribution-Non Commercial-Share Alike 4.0 License, which allows others to remix, tweak, and build upon the work non-commercially, as long as the author is credited and the new creations are licensed under the identical terms.

©2020 Published by Scientific Scholar on behalf of Surgical Neurology International

regarding the safety and efficacy of MOTA thoracotomy for treating unstable thoracic burst fracture (TBF). Here, we evaluated the results of utilizing the MOTA technique in anterior decompression and fusion of 22 traumatic TBFs.

## MATERIALS AND METHODS

This retrospective study was conducted at a tertiary care spine center after approval from the Institutional Review Board. A total of 22 patients with unstable TBF underwent the MOTA thoracotomy technique. Patients with incomplete neurological involvement and with previous pulmonary pathologies were excluded from the study [Table 1]. Multiple clinical and radiographic variables were studied [Table 2]. Patients were followed yearly for instrument-related complications for 5 years. Only patients with AIS A deficits were included in the study.

### Surgical technique

General anesthesia utilized a double-lumen tube for intubation to maintain single lung ventilation when required. All patients included in the study first underwent posterior stabilization in the prone position followed by the right lateral decubitus (i.e., left chest upwards) position [Figure 1].

### Mini-thoracotomy portal

On a radiolucent table, the mini-thoracotomy surface was marked on the skin by noting the level of the fractured

vertebrae/disc and/or adjacent vertebrae. For a single-level fracture/corpectomy, the incision line extended from the middle of the posterior wall of the proximal vertebrae to middle of the anterior wall of distal vertebrae [Figure 1]. For a two-level fracture/corpectomy, the incision line extended from the posterior inferior edge of proximal vertebrae above the fracture to anterosuperior edge of distal vertebrae below the fracture. The incision extended to the rib, with the intercostals subperiosteally dissected from the upper border of the rib. Next, the parietal pleura was incised, followed by placement of the rib spreader. At this point, anesthetist would deflate the lung on the operated side. Other portals (viewing portal and retraction portal) were established under visually assisted thoracoscopy guidance. A thoracoscope was then inserted through mini-thoracotomy into the chest. The viewing portal was placed about two intercostal spaces proximal to involved level and at the anterior edge of the body, while the retraction portal was placed one intercostal space proximal to the involved level and 9 cm anteriorly [Figure 2].

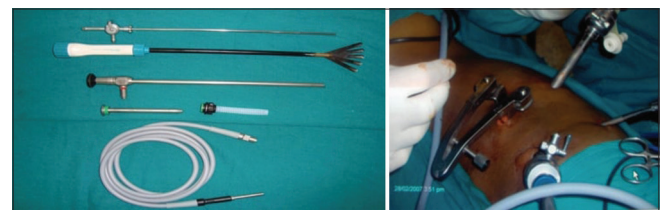
The thoracoscope was then removed from mini-thoracotomy incision and inserted through viewing portal sleeve, to the desired vertebral level. Regular spine instruments (short handle) were utilized to perform the single- or two-level corpectomy of the involved fracture vertebra, along with cord decompression [Figure 3]. Appropriate sized graft was harvested from the ipsilateral iliac crest and inserted anteriorly ensuring a snug fit [Figures 4 and 5]. Parietal pleura was resutured, the lung retractor was removed, and anesthetists reinflated the lung. An intercostal drainage (ICD) tube was left in place.

Inclusion criteria	Exclusion criteria
Patients with thoracic burst fractures	Patients with incomplete neurology
Patients with ASIA-A neurology	Patients with previous pleural/lung pathology
Follow-up of minimum 5 years	Patients who cannot tolerate single lung ventilation
No previous dorsal spine pathology	Patients with severe respiratory dysfunction

Clinical parameters assessed	Radiological parameters assessed
Neurology	Preoperative kyphotic angle
Level of fracture	Postoperative kyphotic angle
Type of fracture	% of kyphosis correction
Associated injuries	Loss of kyphotic correction
Intraoperative time	Radiologic fusion
Estimated blood loss	Status of implants on follow-up
Chest tube drainage	
Length of hospital stay	
Complications	



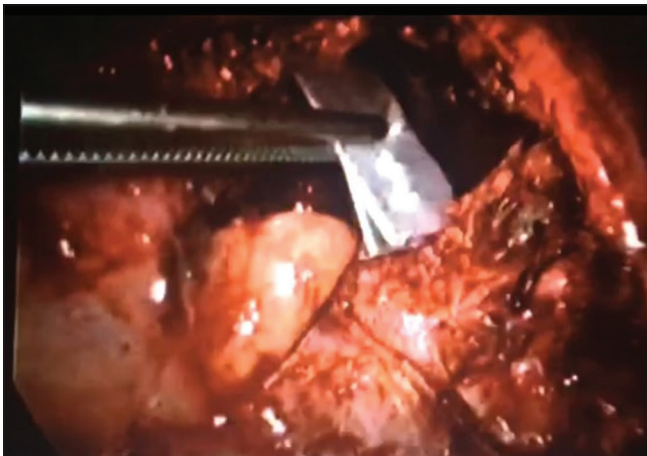**Figure 1:** Right lateral decubitus of patient after posterior surgery with left-sided chest upwards and surface marking for single-level corpectomy, S: Superior, I: Inferior, A: Anterior, P: Posterior.



**Figure 2:** Special instruments required for mini-open thoracoscopic-assisted thoracotomy. Self-retaining retractor and thoracoscope.



**Figure 3:** Image showing ligation of segmental arteries.



**Figure 4:** Measurement of the size of the graft postcorpectomy.



**Figure 5:** Iliac crest strut graft insertion into the corpectomy site.

#### Postoperative care

Patients were mobilized on the 1<sup>st</sup> postoperative day (e.g., sitting with or without support). The ICD drain was removed

when 24 h collection in both drains together was <50 ml. Sitting radiographs were taken on the 3<sup>rd</sup> postoperative day and at every follow-up examination [Figure 6]. Fusion was independently evaluated on X-rays by two spine surgeons, each with more than 5 years of experience in the field.

#### RESULTS

Twenty-two patients were included in study. They averaged 35.5 years of age and were followed up for 8 years 3 months on an average [Table 3]. The patients were predominantly males with T9 and T12 vertebrae fractures (M:F = 6:1). There were 20 single- and 2 double-level corpectomies performed. The average operating time for the MOTA procedure for a single-level corpectomy was  $91.5 \pm 14.5$  min and  $150 \pm 18.6$  min for two levels. The average blood loss was 311 and 550 ml, respectively, in the two groups. ICD was removed typically on the 3<sup>rd</sup> postoperative day, and the average LOS was 5 days.

About 95.45% of cases showed fusion at the latest follow-up. One patient showed radiological evidence of pseudoarthrosis. The average preoperative kyphotic angle was corrected from  $34.2 \pm 3.5^\circ$  to  $20.5 \pm 1.0^\circ$  postoperatively with an average correction of 41.1%. Radiographs at final follow-up showed an average loss of kyphotic correction of 2.4% and there was no evidence of implant loosening or migration.

The most common complication was intercostal neuralgia seen in 12 patients; 10 required membrane stabilizing agents (pregabalin) and two patients required intercostal nerve block. There was one case with traumatic cerebrospinal fluid leakage; this was successfully managed with a muscle graft and postoperative lumbar drainage. The patient with pseudoarthrosis was clinically asymptomatic. On close follow-up, there was no evidence of implant failure or increase in kyphosis. Hence, no active intervention was done.

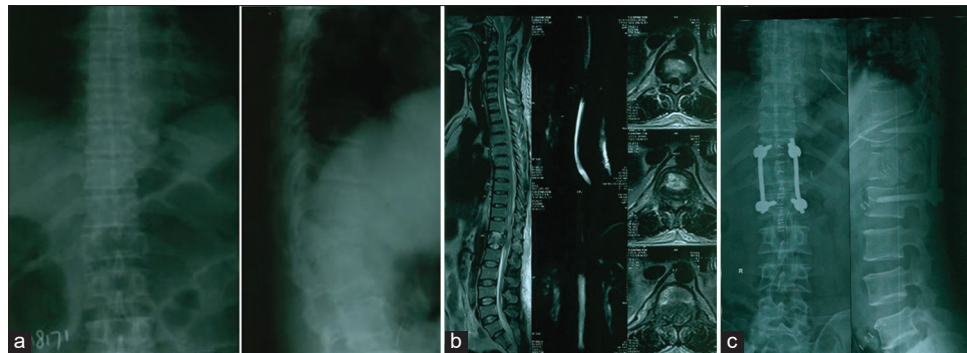
#### DISCUSSION

The mini-open thoracoscopic surgery (MOTA) was introduced for anterior thoracic and thoracolumbar spinal cord decompression with anterior column reconstruction. It provides direct three-dimensional visualizations of focal neurovascular structures, while also providing easy access to manage complications.<sup>[2]</sup> Its major advantage is direct access to perform a vertebrectomy, decompression, and bone graft or cage insertion.

This technique has been used successfully in various indications such as Pott's spine, metastatic spine tumors, and thoracic disc prolapse. Lu *et al.*<sup>[5]</sup> used MOTA in their 50 patients with thoracic Pott's disease. Vijay *et al.*<sup>[7]</sup> used a similar technique in 12 patients with metastatic thoracolumbar spine pathology. Madi<sup>[6]</sup> in their prospective study of 20 patients of thoracolumbar fractures, underwent

**Table 3:** Demographics of study group and intraoperative data and latest follow-up.

Case No.	Age	Sex	Type of fracture	TLICS	Posterior stabilization	Corpectomy levels	Duration of mini-open thoracoscopic-assisted thoracotomy (min)	Blood loss (ml)	Follow-up
1	25	Male	T12 burst	6	T11-L1	One	120	500.00	9 years
2	25	Male	T12 burst fracture	8	T11-L1	One	120	700.00	9 years
3	29	Male	T6 compression	6	T5-T7	One	120	150.00	9 years
4	40	Male	T8 burst	6	T7-T9	One	90	230.00	9 years
5	35	Female	T12 burst	6	T11-L1	One	120	360.00	9 years
6	37	Male	T8 burst	6	T7-T9	One	120	220.00	9 years
7	42	Male	T8 burst	6	T7-T9	One	120	150.00	9 years
8	29	Male	T8 compression	5	T7-T9	One	120	340.00	8 years 9 months
9	29	Male	T10 burst	6	T9-T11	One	90	220.00	8 years 9 months
10	44	Male	T12 burst fracture with translation	9	T11-L1	One	60	300.00	8 years 9 months
11	41	Female	T8 compression	5	T7-T9	One	90	250.00	8 years 9 months
12	50	Female	T9 burst	6	T8-T10	One	60	270.00	8 years 6 months
13	47	Male	T12 bony chance	9	T11-L1	One	60	330.00	8 years 3 months
14	33	Male	T8 burst	6	T7-T9	One	60	230.00	8 years 9 months
15	38	Male	T12 burst	6	T11-L1	One	60	500.00	8 years
16	24	Male	T12 burst	6	T11-L1	One	90	300.00	8 years
17	32	Female	T10 burst	6	T9-T11	One	90	250.00	8 years
18	51	Male	T9,T10 flexion compression	6	T8-T11	Two	180	450.00	8 years
19	30	Male	T12 burst	6	T11-L1	One	90	370.00	8 years
20	33	Female	T8 burst	6	T7-T9	One	90	250.00	7 years
21	26	Male	T7, T8 burst fracture with translation	7	T6-T9	Two	120	650.00	7 years 7 months
22	41	Male	T7 burst	6	T7-T9	One	60	300.00	8 years



**Figure 6:** (a) Preoperative anteroposterior and lateral radiograph showing burst fracture of T12 vertebra. (b) Sagittal and axial magnetic resonance imaging showing fracture of T12 vertebra with surrounding edema. (c) Postoperative anteroposterior and lateral radiographs showing T11-L1 posterior pedicle screw instrumentation with anterior iliac crest strut graft in position.

anterior surgery by a similar approach. Kocis<sup>[3]</sup> in their retrospective study of 127 patients with thoracolumbar fractures also used a similar procedure as did Lee *et al.*<sup>[4]</sup> [Table 4].

The present study shows the results of MOTA technique to perform corpectomy for unstable TBF. The average operating time was 120–180 min, significantly less than the

open thoracotomy approach (average: 210–617 min). The average estimated blood loss (EBL) was 300–500 mL which is comparable with previously published MOTA approach literature; this is also significantly less than the average 1362 ml<sup>[9]</sup> EBL for open thoracotomy. Patients in this study were discharged an average of 5 days postoperatively, while other minimal invasive approaches cited a mean duration

**Table 4:** Review of literature.

Authors	Year	No. of subjects	Pathology	Conclusion
Khoo <i>et al.</i>	2002	371	Thoracic and thoracolumbar fractures	VATS is safe, less morbid, and cosmetically better Technically challenging and has steep learning curve
Lu <i>et al.</i>	2012	50	Pott's spine	MOTA is safe and effective
Vijay <i>et al.</i>	2016	12	Metastatic spinal disease of thoracolumbar spine	Less morbid compared to open approach
Ronald <i>et al.</i>	2007	21/9	Thoracic disc prolapse	Procedure is simpler with no outcome differences
Madi	2005	20	Thoracolumbar fractures	Has minimal approach related complications (three cases of atelectasis), significant correction of focal kyphosis of 13.7 degrees, maintenance of the correction at 1 year follow-up, and 100% fusion of the anterior column
Kocis	2009	127	Thoracolumbar fractures	Less operative time, less blood loss, improvement in neurology 10/19
Lee <i>et al.</i>	2016	111-VATS 76- MOTA	Multiple pathologies of thoracic and thoracolumbar spine	VATS group has longer operating times, more approach related complications, and high conversion rates to open surgery when compared to MOTA
William <i>et al.</i>	2010	52	Thoracic and lumbar fractures	Lesser operative time, lesser blood loss, hospital stay $\leq$ 4 days

of 5.3 days.<sup>[8]</sup> Alternatively, the LOS for open procedures ranged from 10 to 35 days.<sup>[8]</sup> We had 1 major (4.5%) complication (dural tear) and 12 patients (54.5%) with minor complications of intercostal neuralgia. Complications for open thoracolumbar corpectomy ranged from 9 to 56%.<sup>[1]</sup>

About 95.45% of cases in the current series showed fusion at their latest follow-up, with overall good stabilization of kyphosis. One patient with pseudoarthrosis was managed conservatively as he was clinically asymptomatic with no evidence of progression of kyphosis or implant failure.

Major limitations of this study include the very small sample size, retrospective nature of analysis, data from a single center, and lack of control group. Our study is just a preliminary report on the safety and efficacy of MOTA approach for the management of TBF. A multi-centric analysis with a larger sample size is needed to further validate our findings. However, we believe that the MOTA approach may serve as a useful middle ground between open and endoscopic procedures mitigating the disadvantages of each.

## CONCLUSION

The MOTA approach to unstable thoracic single-/double-level fractures is yet to be confirmed, as this study is only a preliminary report as to its safety/efficacy.

## Declaration of patient consent

Institutional Review Board permission obtained for the study.

## Financial support and sponsorship

Publication of this article was made possible by the James I. and Carolyn R. Ausman Educational Foundation.

## Conflicts of interest

There are no conflicts of interest.

## REFERENCES

- Karmakar MK, Ho AM. Postthoracotomy pain syndrome. *Thorac Surg Clin* 2004;14:345-52.
- Khoo LT, Beisse R, Potulski M. Thoracoscopic-assisted treatment of thoracic and lumbar fractures: A series of 371 consecutive cases. *Neurosurgery* 2002;51 Suppl 5:S104-17.
- Kocis J, Wendsche P, Muzik V, Bilik A, Vesely R, Cernohousova I. Minimally invasive thoracoscopic transdiaphragmatic approach to thoracolumbar junction fractures. *Acta Chir Orthop Traumatol Cech* 2009;76:232-8.
- Lee CY, Wu MH, Li YY, Cheng CC, Lee CY, Huang TJ. Video-assisted thoracoscopic surgery and minimal access spinal surgery compared in anterior thoracic or thoracolumbar junctional spinal reconstruction: A case-control study and review of the literature. *Biomed Res Int* 2016;2016:6808507.
- Lu G, Wang B, Li J, Liu W, Cheng I. Anterior debridement and reconstruction via thoracoscopy-assisted mini-open approach for the treatment of thoracic spinal tuberculosis: Minimum 5-year follow-up. *Eur Spine J* 2012;21:463-9.
- Madi K, Dehoux E, Aunoble S, Le Huec JC. Video-assisted mini-thoracotomy for surgical treatment of thoracolumbar junction fractures. *Rev Chir Orthop Reparatrice Appar Mot* 2005;91:702-8.
- Ravindra VM, Brock A, Awad AW, Kalra R, Schmidt HM. The role of the mini-open thoracoscopic-assisted approach in the management of metastatic spine disease at the thoracolumbar junction. *Neurosurg Focus* 2016;41:E16.
- Smith WD, Dakwar E, Le TV, Christian G, Serrano S, Uribe JS. Minimally invasive surgery for traumatic spinal pathologies: A mini-open, lateral approach in the thoracic and lumbar spine. *Spine (Phila Pa 1976)* 2010;35 Suppl 26:S338-46.
- Vaccaro AR, Lehman RA Jr, Hurlbert RJ, Anderson PA,

Harris M, Hedlund R, *et al.* A new classification of thoracolumbar injuries: The importance of injury morphology, the integrity of the posterior ligamentous complex, and neurologic status. *Spine (Phila Pa 1976)* 2005;30:2325-33.

10. Verlaan JJ, Diekerhof CH, Buskens E, van der Tweel I, Verbout AJ, Dhert WJ, *et al.* Surgical treatment of traumatic

fractures of the thoracic and lumbar spine: A systematic review of the literature on techniques, complications, and outcome. *Spine* 2004;29:803-14.

**How to cite this article:** Tandon V, Mallepally AR, Peddaballe AR, Marathe N, Chhabra HS. Mini-open thoracoscopic-assisted spinal thoracotomy for traumatic injuries: A technical note. *Surg Neurol Int* 2020;11:265.