

Evaluation of various preservation media for storage of donor corneas

Namrata Sharma, Farin Shaikh, Ritu Nagpal, Manumuraleekrishna, Prafulla K Maharana, Tushar Agarwal, Rajesh Sinha, Gita Satpathy¹, Thirumurthy Velpandian², Jeewan S Titiyal

Purpose: To compare the physical and microbiological characteristics of McCarey-Kaufman (MK), Cornisol, and Optisol-GS media and evaluate the outcomes of keratoplasty performed using corneas stored in these three media. **Methods:** The study involved 60 donor corneas which were distributed in 3 groups: MK, Cornisol, and Optisol-GS. Corneas in these groups were further analyzed based on the type of keratoplasty performed (full thickness versus endothelial keratoplasty). At baseline, the endothelial cell density and death to preservation time of donor corneas were recorded. Following keratoplasty, patients were evaluated on day 1, at 1 month, 3 months, and 6 months follow-up. Outcomes were assessed in terms of corrected distance visual acuity (CDVA), endothelial cell density, percentage endothelial cell loss, and corneal thickness. The storage media were also assessed for their physical quality and their microbiological characteristics. **Results:** Physical characteristics of all three media were found to be within normal limits. Mean CDVA was comparable among the 3 groups at 6-month follow-up. The absolute endothelial cell count values were significantly lower for corneas stored in MK medium (1873.7 ± 261.1 cells/mm²) compared to the Cornisol (2085.0 ± 230.3 cells/mm²) and Optisol-GS media [$(2180.3 \pm 217.2$ cells/mm²) ($P = <0.001$)]. Corneas stored in Optisol-GS medium were significantly thinner at 1-month follow-up with no significant difference at 6 months ($P = 0.66$). **Conclusion:** Optisol-GS and Cornisol media were found to preserve endothelial cell density better and stabilize corneal thickness earlier as compared to the MK medium. However, the functional outcomes were comparable among the three groups.

Key words: Corneal preservation, Cornisol medium, donor corneal storage, MK medium, Optisol-GS medium

The main objective of corneal preservation is to prolong the duration of donor tissue storage, besides maintaining the viability of endothelial cells. Use of preservation media has helped long way in ensuring the optimal utilization of precious donor tissues, especially in developing countries where the availability of donor tissues is a major limiting factor. Based on the duration up to which the corneal tissues can be viably stored in them, the media can be classified as "short-term," "intermediate-term," or "long-term" storage media. Short-term storage media include moist chambers and McCarey-Kaufman (MK) medium which allow for 24 h and 72 h of storage duration, respectively. Intermediate-term storage media include Optisol-GS, Cornisol, Eusol-C, and Life 4°C, which allow for 10–14 days of corneal tissue storage. Long-term storage media comprise of organ culture medium with 1-month storage period, glycerine with 1 year, and the cryopreservation technique with indefinite duration of corneal storage.

The MK medium contains tissue culture medium 199, gentamicin, 5% dextran as an osmotic agent, HEPES

(4-(2-hydroxyethyl)-1-piperazineethanesulfonic acid) as a buffer, and phenol red as a pH indicator. This is a cost-effective medium which is widely used for storing and transporting donor corneas in various developing countries. The Cornisol medium (AuroLab, Madurai, India) is composed of tissue culture medium 199, Earle's balanced salt solution, minimum essential medium, 2.5% chondroitin sulfate, recombinant human insulin as a metabolism enhancer, dextran, L-glutamine, adenosine triphosphate precursors, various vitamins and antibiotics including gentamicin and streptomycin. It is commonly used in India for transportation and storage of donor corneal tissues. The Optisol-GS (Bausch and Lomb, Rochester, NY) medium which was introduced in 1990s is composed of tissue culture medium-199, Earle's balanced salt solution, minimum essential medium, HEPES buffer, 2.5% chondroitin sulfate, 1% dextran, various ATP precursors, iron, cholesterol, L-hydroxyproline, and numerous vitamins along with gentamicin and streptomycin.^[1]

In a study by Rijneveld *et al.*,^[2] 9 pairs of corneas stored in MK medium (mean storage duration: 21 h) were compared with corneas stored in organ culture medium (mean storage duration: 192 h). The visual outcomes, endothelial cell density, and cell loss were comparable at 14 years follow-up. However,

Cataract, Cornea and Refractive Surgery Services, Dr. Rajendra Prasad Centre for Ophthalmic Sciences, All India Institute of Medical Sciences, New Delhi, ¹Ocular Microbiology, Dr. Rajendra Prasad Centre for Ophthalmic Sciences, All India Institute of Medical Sciences, ²Ocular Pharmacology and Pharmacy, Dr. Rajendra Prasad Centre for Ophthalmic Sciences, All India Institute of Medical Sciences, New Delhi, India

Correspondence to: Prof. Namrata Sharma, Cataract, Cornea and Refractive Surgery Services, Dr. Rajendra Prasad Centre for Ophthalmic Sciences, All India Institute of Medical Sciences, New Delhi, India. E-mail: namrata.sharma@gmail.com

Received: 05-Feb-2021

Revision: 25-Feb-2021

Accepted: 08-Apr-2021

Published: 25-Aug-2021

Access this article online

Website:

www.ijo.in

DOI:

10.4103/ijo.IJO_258_21

Quick Response Code:



This is an open access journal, and articles are distributed under the terms of the Creative Commons Attribution-NonCommercial-ShareAlike 4.0 License, which allows others to remix, tweak, and build upon the work non-commercially, as long as appropriate credit is given and the new creations are licensed under the identical terms.

For reprints contact: WKHLRPMedknow_reprints@wolterskluwer.com

Cite this article as: Sharma N, Shaikh F, Nagpal R, Manumuraleekrishna, Maharana PK, Agarwal T, *et al.* Evaluation of various preservation media for storage of donor corneas. Indian J Ophthalmol 2021;69:2452-6.

grafts stored in organ culture medium were thinner compared to the MK medium stored grafts. Price *et al.*^[3] in another study compared endothelial cell loss and graft success rates among 27 paired donor corneas which were stored in either Optisol GS or Life 4°C solutions. The endothelial cell loss was comparable among the two groups at 6-month follow-up. In an in-vitro randomized study by Basak and Prajna,^[4] 31 paired donor corneas were compared, which were stored in either Cornisol or Optisol-GS medium. The study showed that comparable endothelial cell loss between the two groups after a storage period of 14 days.

Our study compared the physical and microbiological characteristics of three preservation media—MK, Cornisol and Optisol-GS and evaluated the impact of these preservation media on the outcomes of keratoplasty.

Methods

This was a prospective comparative study conducted at a tertiary eye care institute. Ethics approval was obtained from ethics committee of the institute. The study adhered to the tenets of declaration of Helsinki. Ethics committee approval was obtained from the ethics of AIIMS on 23.06.15. Ref. No.: IESC/T-132/03.2015.

The study involved 60 optical grade donor corneal tissues which were preserved in MK medium, Cornisol, and Optisol-GS storage media. Corneas stored in all the three groups were further classified into 2 groups, based on the type of keratoplasty for which they were used. 10 eyes in each of the three groups were used for penetrating keratoplasty (PK group) and another 10 were used for Descemet's stripping automated endothelial keratoplasty (DSAEK group). The division strategy is illustrated in Fig. 1.

Indications for keratoplasty included Fuchs endothelial corneal dystrophy and pseudophakic bullous keratopathy for DSAEK and healed keratitis for penetrating keratoplasty. Exclusion criteria were age less than 18 years, ocular findings suggestive of a prior episode of anterior or posterior segment inflammation, presence of preexisting glaucoma, ocular surface disease, presence of a prior graft, posterior segment pathology, and patients not willing to participate and follow up.

All three storage media were analyzed for their physical quality and microbiological characteristics. Physical quality parameters included viscosity, osmolarity, pH, and optical density. Microbiological examination was performed to look for any bacterial or fungal contamination. All donor tissues were analyzed preoperatively on slit lamp using a

viewing chamber to assess the status of corneal epithelium, stroma, Descemet's membrane, and endothelium. Endothelial cell count was evaluated using a specular microscope (Konan KSS-EB10, Irvine, CA).

Preoperative evaluation of patients included assessment of corrected distance visual acuity (CDVA), degree of corneal stromal scarring, anterior chamber anatomy, iris details, intraocular lens position and stability, and posterior segment details. Parameters which were evaluated intraoperatively included size of donor and recipient tissue trephination, surgical time, and any additional procedures if combined with keratoplasty. The excised donor rim was sent for microbiological examination to rule out any microbial contamination. Patients were followed up on day 1, at 1 week, 1 month, 3 months, and 6 months. Parameters which were evaluated postoperatively in eyes that underwent full thickness keratoplasty included rate of corneal epithelization, graft clarity, status of sutures, presence of anterior chamber reaction, intraocular pressure, endothelial cell count, central corneal thickness, and posterior segment details. In cases of DSAEK, graft position and thickness, anterior chamber details, IOL status, intraocular pressure, endothelial cell count, and posterior segment details were noted.

Postoperative CDVA was recorded using Snellen's chart. Central corneal thickness (CCT) was assessed using anterior segment optical coherence tomography (Visante, Carl Zeiss Meditec Inc, Dublin, Calif) and endothelial cell count measurement was done using Topcon SP-1P specular microscope (Topcon Europe Medical B.V, Netherlands).

Statistical analysis was performed using Microsoft Excel (Microsoft Office Professional Plus 2013; WA) and Stata statistical software (version 13; StataCorp, TX). Quantitative data was expressed as mean \pm standard deviation. Categorical data was expressed as frequency. Median (inter quartile range) was used to express skewed data. Bonferroni test and one way Anova tests were used for comparison of three groups and *P* value of < 0.05 was considered statistically significant.

Results

Baseline characteristics

The donor parameters which were compared among the 3 groups included age and sex of the donor, death to preservation time, and endothelial cell count. All these parameters were found comparable among the 3 groups as depicted in Table 1.

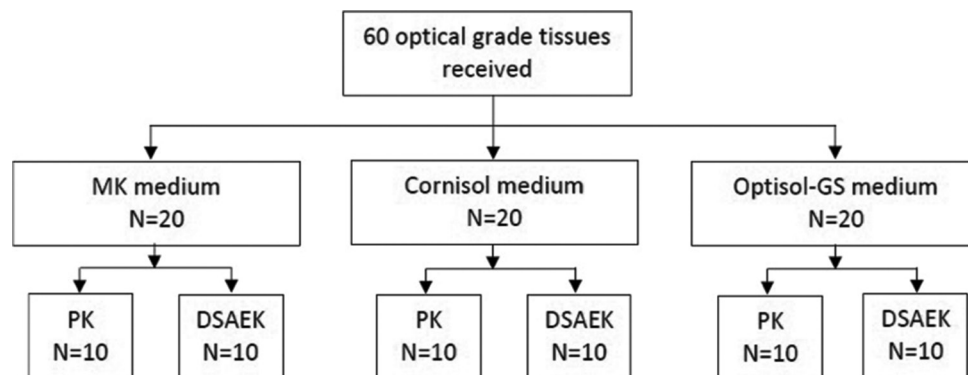


Figure 1: Flow chart representing the pattern of division of donor corneal tissues based on the type of preservation medium and keratoplasty performed

Postoperative parameters

Visual acuity

The overall mean CDVA was comparable among the 3 groups at 6-month postoperative follow-up. Among the subgroups (PK and DSAEK), the 3 storage media groups were comparable in terms of mean CDVA at last follow up.

Endothelial cell density

At 6th postoperative month, corneas stored in MK medium had the least mean endothelial cell count (1873.7 ± 261.1 cells/mm²), whereas corneas stored in Optisol-GS medium had the highest absolute endothelial cell counts (2180.3 ± 217.2 cells/mm²). The cell count values in MK medium were significantly lower compared to both Cornisol as well as Optisol-GS medium ($P = 0.008$ and 0.001 respectively). No statistically significant difference was noted among the Cornisol and Optisol-GS groups with respect to endothelial cell count at 6-month follow-up ($P = 0.32$).

Fig. 2 demonstrates the trend of change in endothelial cell density from preoperative to 6-month postoperative period in three groups. Analysis of endothelial cell loss on serial postoperative follow-up visits showed that corneal tissues preserved in MK media showed maximum endothelial cell loss ($19.9 \pm 5.6\%$) compared to corneal tissues preserved in Cornisol ($14.0 \pm 5.1\%$) and Optisol-GS ($12.2 \pm 3.7\%$) media ($P < 0.001$) [Fig. 3]. Although the difference between MK medium versus Cornisol and Optisol-GS medium group was statistically significant, no significant difference was noted between Cornisol and Optisol-GS medium in all follow-up visits.

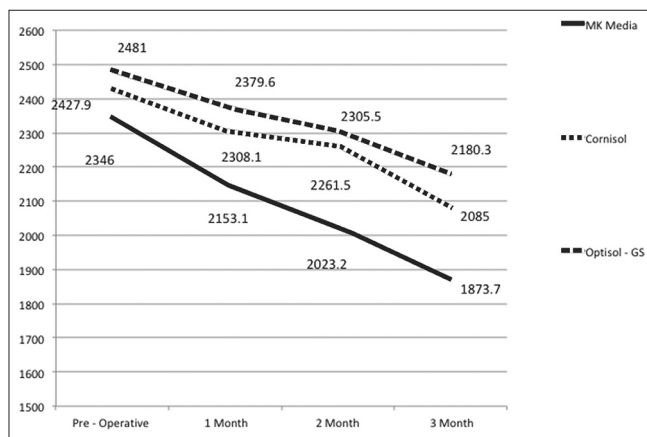


Figure 2: Line diagram demonstrating change in endothelial cell density among the 3 groups (MK, Cornisol, and Optisol-GS) from preoperative to 3-month postoperative period

Subgroup analysis of eyes which underwent Descemet’s Stripping Automated Endothelial Keratoplasty (DSAEK group)

Comparing endothelial cell counts in eyes which underwent DSAEK, corneas preserved in MK medium had significantly lesser endothelial cell counts (1793.75 ± 161.65 cells/mm²) compared to Cornisol (1975.1 ± 187.20 cells/mm²) and Optisol-GS (2086.1 ± 156.08 cells/mm²) media groups ($P < 0.05$). The difference between Cornisol and Optisol-GS media groups was not significant statistically ($P = 0.45$). Fig. 4 shows the trend of endothelial cell count from preoperative to 3-month postoperative follow-up, in eyes which underwent DSAEK.

Subgroup analysis of eyes which underwent Penetrating Keratoplasty (PK group)

Comparing endothelial cell counts in eyes which underwent PK, corneas preserved in MK medium had lesser endothelial cell counts (1993.7 ± 341.6 cells/mm²) compared to Cornisol (2194.9 ± 223.8 cells/mm²) and Optisol-GS (2274.6 ± 235.7 cells/mm²) media groups at 6-month follow-up. Percentage endothelial cell loss in three groups of media suggested that endothelial cell loss was significantly higher for corneas stored in McCarey Kaufman medium ($13.4 \pm 1.5\%$) as opposed to corneas stored in Cornisol ($9.4 \pm 1.1\%$) and Optisol-GS ($10.0 \pm 2.3\%$) medium. Fig. 5 shows the trend in endothelial cell count from preoperative to 3-month postoperative follow-up in eyes that underwent PK.

CCT measurements showed that corneas stored in Optisol-GS medium were thinner ($547 \pm 56.6 \mu\text{m}$) at 1 week

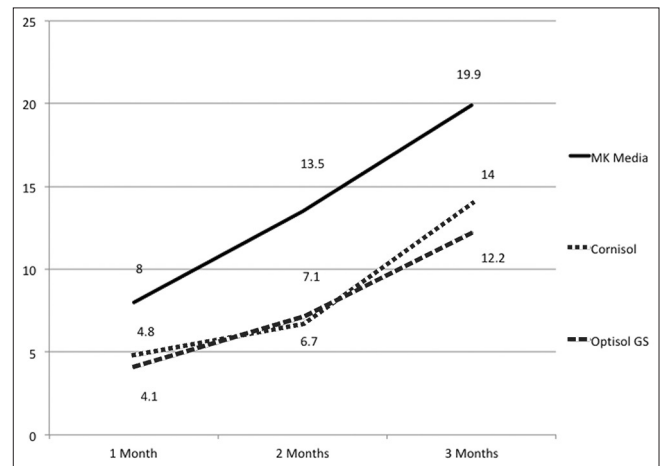


Figure 3: Line diagram representing percentage endothelial cell loss among the 3 groups (MK, Cornisol, and Optisol-GS) upto 3-month postoperative period

Table 1: Comparison of various baseline donor parameters among the 3 groups: MK, Cornisol, and Optisol-GS

	MK group n=20	Cornisol group n=20	Optisol-GS group n=20	P
Age (years)				
Mean±S.D	30.8±17.0	39.0±12.9	30.2±12.7	0.08
Gender distribution				
Number of females/Number of males	11/09	8/12	11/09	0.549
Death to preservation time (hours)				
Mean±S.D	4.5±1.7	4.9±1.3	4.5±1.9	0.52
Endothelial cell count (cells/mm ²)				
Mean±S.D	2304.7±405.1	2425.1±253.0	2525.7±228.7	0.31

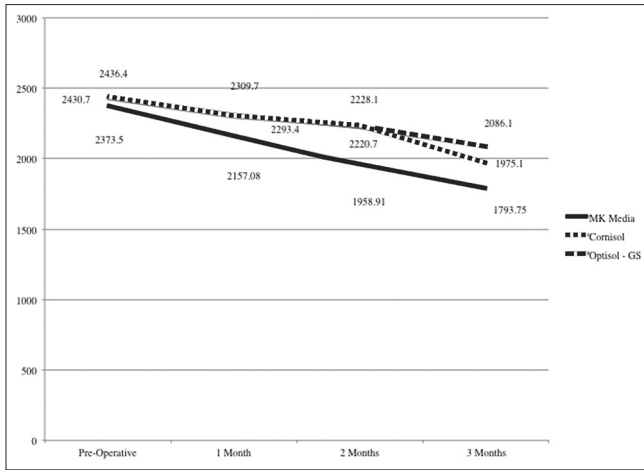


Figure 4: Line diagram representing endothelial cell count trend in eyes belonging to the Descemet's stripping automated endothelial keratoplasty subgroup

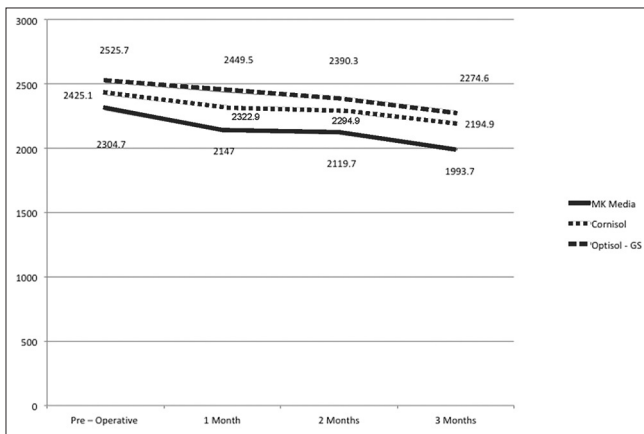


Figure 5: Line diagram representing endothelial cell count trend in eyes belonging to the Penetrating keratoplasty subgroup

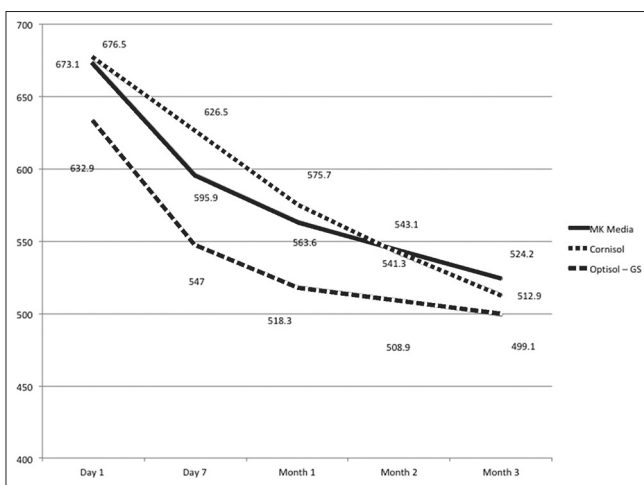


Figure 6: Line diagram representing change in postoperative central corneal thickness in eyes belonging to the Penetrating keratoplasty subgroup

postoperative visit compared to MK ($595.9 \pm 40.9 \mu\text{m}$) and Cornisol ($626.5 \pm 159.8 \mu\text{m}$) groups. However, at 6-month

Table 2: Physical and microbiological quality characteristics of donor corneal storage media

Quality characteristics (mean±S.D)	MK medium	Cornisol medium	Optisol-GS medium
pH	7.11±0.07	7.27±0.06	7.30±0.01
Osmolarity (mOsm/L)	334±10	345±6	378±8
Viscosity (cps)	2.02±0.1	4.01±0.2	8.54±0.4
Optical Density (/cm)	0.873±0.05	0.193±0.01	0.463±0.03
Bacterial Culture	Sterile	Sterile	Sterile
Fungal Culture	Sterile	Sterile	Sterile

follow-up, the values were comparable. Fig. 6 shows the trend of central corneal thickness values, from preoperative to 3-month postoperative follow-up, in eyes that underwent PK.

For Optisol-GS stored corneas, trend analysis of % change in CCT suggested that maximum reduction in CCT was obtained at postoperative 1 week with a gradual decline over the next 6 months.

Complications

Two patients had elevation in intraocular pressure, one in each of MK and Cornisol group, that was controlled medically. One patient in Optisol-GS group had an episode of graft rejection that was reversed using intravenous pulse steroid therapy.

Physical and microbiological quality characteristics of donor corneal storage media

The three-storage media were assessed for their physical characteristics in terms of pH at 4°C, osmolarity, viscosity, and optical density. All these parameters were found to be within normal limits [Table 2]. None of the storage medium showed any evidence of bacterial or fungal contamination.

Discussion

The key difference among MK medium, Cornisol, and Optisol-GS media is the presence of chondroitin sulfate in the latter two. Chondroitin sulfate acts as an antioxidant and a free radicle scavenger, shielding the cell membranes from apoptotic changes. It also abets in chelation complex formation by functioning as a cation exchange resin.^[5-7]

Apart from the forming constituents, the physical characteristics of a storage medium such as its osmolarity, optical density, viscosity, and its pH have a bearing on endothelial cell survival. In order to estimate the exact contribution of forming components of a particular media on graft characteristics, it is essential that the physical parameters be kept within normal limits. Physical quality assessment showed that the three media were comparable and suitable for the preservation of donor corneas.^[8]

In a study by Lindstrom *et al.*^[1], donor corneal tissues stored in Optisol-GS medium were used for full thickness keratoplasty. Postoperatively, the graft thickness was found to be $690 \pm 100 \mu\text{m}$ on day 1 declining to $540 \pm 60 \mu\text{m}$ at 6-month follow-up visit. A similar observation was seen in our study also. The thickness of tissues stored in Optisol-GS media was found to be $632.9 \pm 91.4 \mu\text{m}$ on postoperative day 1, which reduced to $499.1 \pm 62.7 \mu\text{m}$ at 6-month follow-up. Maximum reduction in central corneal was obtained at 1 week follow-up, with a gradual decline over the next 6 months as compared to MK and Cornisol media. Thus, Optisol-GS stored corneas

showed least detergence time compared to Cornisol and MK medium stored corneas which showed gradual reduction in CCT over a follow-up period of 6 months.

Subgroup analysis of PKP and DSAEK patients with respect to donor corneal storage medium was also done in our study. Central corneal thickness of patients who underwent penetrating keratoplasty (PKP) suggested no significant difference in three groups of media at any point of follow up. Average central corneal thickness in three groups of PKP patients was noted to be between 499 and 524 μm at postoperative 6 months. Patients who underwent DSAEK also had the thinnest cornea at postoperative day 7 in the Optisol-GS as compared to MK and Cornisol media. No significant difference was seen in central corneal thickness of DSAEK patients in the three groups at postoperative 6-month follow-up.

We compared absolute endothelial cell count using centre method in all three study groups and found that endothelial cell counts of donor cornea in all the three groups were comparable preoperatively. At 6th postoperative month, corneas stored in McCarey Kaufman (MK Medium) had the least mean endothelial cell count, whereas corneas stored in Optisol-GS maintained the highest mean endothelial cell count. No statistically significant difference was noted in endothelial cell density at 6th postoperative month in Cornisol and Optisol-GS media. When comparison was done for 30 corneas that underwent PKP, there was no significant difference with respect to storage media used at all postoperative follow-ups. In the subgroup which underwent DSAEK, analysis of absolute endothelial cell count at 6th postoperative month suggested that corneas from MK medium had the least absolute endothelial cell count as compared to corneas stored in the Cornisol and Optisol-GS.

Analysis of endothelial cell loss performed on serial follow-ups showed that corneas stored in MK Medium had maximum percentage cell loss ($19.9 \pm 5.6\%$) as opposed to Cornisol ($14.0 \pm 5.1\%$) and Optisol-GS ($14.0 \pm 5.1\%$) media groups at 3 months. This difference was statistically significant at all follow-up points ($P < 0.001$). No significant difference was noted between Cornisol and Optisol-GS media groups at any point in time. When subgroups of PKP and DSAEK were analyzed with respect to donor corneal storage medium, percentage endothelial cell loss was significantly found to be higher for corneas stored in MK medium ($13.4 \pm 1.5\%$) as opposed to corneas stored in Cornisol ($9.4 \pm 1.1\%$) and Optisol-GS medium [$(10.0 \pm 2.3\%)$ ($P < 0.05$)]. These results were comparable to the results reported by Bourne *et al.*^[9]

Although the endothelial cell density was poor in MK group, best-corrected visual acuity at postoperative 6 months did not differ significantly with respect to the other two media used for storage of donor corneas ($P = 0.10$). Significant gain in visual acuity was noted at 6 months within all the three groups with respect to preoperative visual acuity ($P < 0.05$). In addition, there were no cases of primary graft failure in any of the study groups. Also, at the final 6-month follow-up, all corneas were optically clear with graft clarity of 4 plus. The endothelial cell density (ECD) in MK media group was 1873.7 ± 261.1 cells/ mm^2 at 6-month follow-up. In the Specular Microscopy Ancillary Study (SMAS) of the multicenter Cornea Donor Study (CDS) examining endothelial cell loss following PK, 24% of the subjects with a clear graft after 10 years had an ECD below 500 cells/ mm^2 . This had also been previously shown in other studies that there is a critical ECD below which irreversible corneal edema occurs, explaining the sudden decompensation of some grafted corneas years after successful transplantation.^[10,11] Thus, even

though MK medium results in higher ECD loss compared to other medium, the ECD is found to be adequate enough to maintain graft clarity in our study. This is further supported by the comparable CCT at final follow-up.

There are several limitations to this study. The sample size in individual subgroups is relatively small. Besides, being a study with three groups of media we could not use paired donor cornea in our study. Although the overall trend of central corneal thickness and endothelial cell density suggested better long-term graft survival, 6-month follow-up period is relatively short to analyze the long-term effects of preservation media on the outcomes of corneal graft.

Conclusion

To conclude, MK, Cornisol, and Optisol-GS are effective methods of donor cornea preservation. Optisol-GS and Cornisol are better than MK medium in terms of postoperative endothelial cell density and CCT stabilization. However, all media are equal in terms of functional outcomes. Strength of our study lies in the fact that it is a first prospective randomized controlled study comparing three different corneal storage media with respect to their physical and microbiological quality characteristics as well as their postoperative effects on two different types of keratoplasty procedures.

Financial support and sponsorship

Nil.

Conflicts of interest

There are no conflicts of interest.

References

1. Lindstrom RL, Kaufman HE, Skelnik DL, Laing RA, Lass JH, Musch DC, *et al.* Optisol corneal storage medium. *Am J Ophthalmol* 1992;114:345-56.
2. Rijnveld WJ, Remeijer L, van Rij G, Beekhuis H, Pels E. Prospective clinical evaluation of McCarey-Kaufman and organ culture cornea preservation media: 14-year follow-up. *Cornea* 2008;27:996-1000.
3. Price MO, Knight OJ, Benetz BA, Debanne SM, Verdier DD, Rosenwasser GO, *et al.* Randomized, prospective, single-masked clinical trial of endothelial keratoplasty performance with 2 donor cornea 4°C storage solutions and associated chambers. *Cornea* 2015;34:253-6.
4. Basak S, Prajna NV. A prospective, in vitro, randomized study to compare two media for donor corneal storage. *Cornea* 2016;35:1151-5.
5. Stein RM, Bourne WM, Campbell RJ. Chondroitin sulfate for corneal preservation at 4 degrees C. Evaluation by electron microscopy. *Arch Ophthalmol Chic Ill* 1960 1986;104:1358-61.
6. Mizukawa T, Manabe R. Recent advances in keratoplasty with special reference to the advantage of liquid preservation. *Folia Ophthalmol Jpn* 1968;19:1310-8.
7. Teresa LM, Geroski GH. Viability of human corneal endothelium following Optisol GS storage. *Arch Ophthalmol* 1995;113:805-9.
8. Effect of pH change on Corneas during storage at 4°C. EBAA Abstract, university of Southern California, Doheny Eye Institute, Los Angeles, CA, U.S.A.
9. Bourne WM, Nelson LR, Maguire LJ, Baratz KH, Hodge DO. Comparison of chen medium and Optisol-GS for human corneal preservation at 4 degrees C: Results of transplantation. *Cornea* 2001;20:683-6.
10. Bell KD, Campbell RJ, Bourne WM. Pathology of late endothelial failure: Late endothelial failure of penetrating keratoplasty: Study with light and electron microscopy. *Cornea* 2000;19:40-6.
11. Writing Committee for the Cornea Donor Study Research Group; Lass JH, Benetz BA, Gal RL, Kollman C, Raghinaru D, Dontchev M, *et al.* Donor age and factors related to endothelial cell loss 10 years after penetrating keratoplasty: Specular Microscopy Ancillary Study. *Ophthalmology* 2013;120:2428-35.