

# Knee Arthroscopy: A Diagnostic and Therapeutic Tool for Management of Ochronotic Arthropathy



William B. Stetson, M.D., Stephanie A. Morgan, M.P.A.P., P.A.-C., Nicole J. Hung, B.A., and Samuel Polinsky, B.A.

**Abstract:** The surgical treatment of ochronotic arthropathy remains unclear. Although there is no absolute cure for ochronotic arthropathy, current management typically begins with conservative treatment. Total joint replacement may eventually be necessary for joints that become severely degenerative. Ochronotic arthropathy is present in patients with alkaptonuric ochronosis, which is characterized by dark pigmentation of connective tissue and black discoloration of urine owing to a deficiency of homogentisic acid oxidase. As a result, soft tissues become brittle and subsequently more susceptible to mechanical stress, resulting in articular cartilage degeneration. The diagnosis of ochronotic arthropathy of the knee often occurs intraoperatively after discovery of darkened synovium and black deposits during arthroscopy. The purpose of this article is to describe arthroscopic debridement as an effective treatment option and diagnostic tool for ochronotic arthropathy of the knee after failure of conservative measures.

Ochronotic arthropathy is present in patients with alkaptonuria, a rare inheritable autosomal recessive metabolic disorder characterized by dark pigmentation of connective tissue owing to a deficiency of homogentisic acid (HGA) oxidase. Lack of HGA oxidase causes inadequate metabolism of tyrosine and phenylalanine, which results in the accumulation of HGA metabolites.

HGA metabolites polymerize and bind to collagen-rich surfaces, causing brown-black discoloration of connective tissue. This leads to degenerative ochronotic arthropathy, most commonly in large joints such as the knee and hip.<sup>1</sup> With excessive HGA metabolite deposition, the soft-tissue surface becomes brittle and subsequently more susceptible to mechanical stress, resulting in articular cartilage degeneration.<sup>2</sup>

Symptoms of ochronotic arthropathy typically present in the fourth decade of life. Male patients are typically more affected than female patients.<sup>3</sup> Ochronotic arthropathy will not develop in all patients with alkaptonuria.<sup>4</sup> The main morbidity in patients with ochronosis is arthropathy that resembles osteoarthritis. The knee is the most commonly affected joint, comprising an estimated 64% of cases of ochronotic arthropathy.<sup>4,5</sup> Other systemic pathologies include dark pigmentation of the ears, nose, lungs, kidneys, and heart endocardium and valves owing to HGA metabolite accumulation<sup>6</sup> (Fig 1).

## Preoperative Diagnosis and Imaging

Given the extremely rare prevalence and late onset of symptoms of ochronotic arthropathy, preoperative diagnosis can be difficult. The differential diagnosis of ochronotic arthropathy includes hemophilic arthropathy, arthropathy associated with hemochromatosis, and pigmented villonodular synovitis.<sup>5</sup> Furthermore, arthroscopy itself is often used as a diagnostic tool for ochronotic arthropathy. In many cases the diagnosis occurs through intraoperative discovery of a bluish-black substance surrounding the articular cartilage along with darkened synovium followed by pathology report findings.

Still, there are several clinical and radiologic presentations that are suggestive of ochronotic arthropathy of the knee. The most common radiologic presentation of ochronotic arthropathy of the knee is degeneration of the articular cartilage that resembles osteoarthritis.

From Stetson Powell Orthopedics and Sports Medicine (W.B.S., S.A.M., N.J.H., S.P.), Burbank; and Department of Orthopaedic Surgery, Keck School of Medicine, University of Southern California (W.B.S.), Los Angeles, California, U.S.A.

The authors report that they have no conflicts of interest in the authorship and publication of this article. Full ICMJE author disclosure forms are available for this article online, as [supplementary material](#).

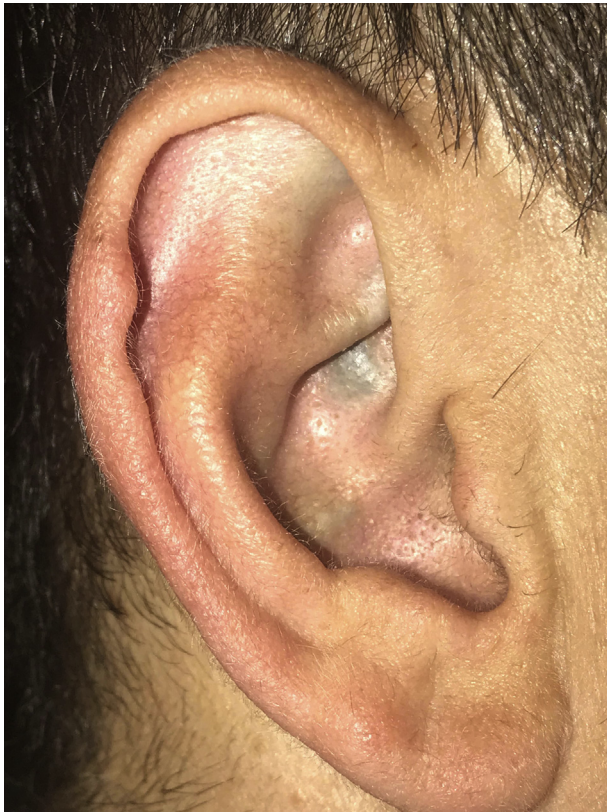Received April 25, 2018; accepted July 10, 2018.

Address correspondence to William B. Stetson, M.D., Stetson Powell Orthopedics and Sports Medicine, 191 S Buena Vista St, Ste 470, Burbank, CA 91505, U.S.A. E-mail: [wbstesonmd@gmail.com](mailto:wbstesonmd@gmail.com)

© 2018 by the Arthroscopy Association of North America. Published by Elsevier. This is an open access article under the CC BY-NC-ND license (<http://creativecommons.org/licenses/by-nc-nd/4.0/>).

2212-6287/18501

<https://doi.org/10.1016/j.eats.2018.07.004>



**Fig 1.** Deposit of dark pigmented tissue in external right ear. Pigmented cartilaginous tissue is a common physical examination finding in patients with a diagnosis of ochronosis.

Doganavsargil et al.<sup>7</sup> found that mild to severe degenerative changes including joint space narrowing, subchondral sclerosis, and peripheral osteophytes were observed on radiographs of patients with ochronotic arthropathy of the knee.

The clinical presentation of ochronotic arthropathy of the knee can include pain and limited range of motion.<sup>7</sup> Synovial effusion owing to inflammation of the articular cartilage may also be present and has been found in approximately 50% of patients with ochronotic arthropathy.<sup>8</sup> However, given the non-disease-specific nature of these radiologic and clinical findings, the diagnosis of ochronotic arthropathy is ultimately confirmed by pathology report findings. [Table 1](#) lists the pearls and pitfalls of diagnosing ochronotic arthropathy.

**Table 1.** Pearls and Pitfalls

---

Clinically, patients may present with pain, stiffness, and/or decreased mobility.

Radiographic signs may include mild to severe degenerative changes. Because the clinical presentation and radiographic findings are nonspecific, knee arthroscopy, followed by pathology report findings, is often the most accurate diagnostic tool.

The surgeon should be aware of comorbidities associated with alkaptonuria that could be suggestive of the diagnosis of ochronotic arthropathy (darkened urine or dark pigmentation of ear or other connective tissue).

---

## Surgical Options

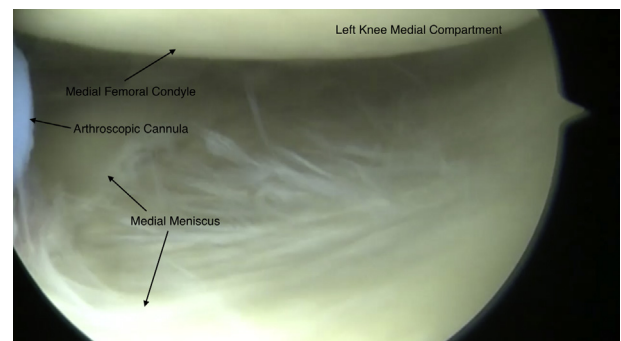
When conservative measures including rest, physical therapy, and nonsteroidal anti-inflammatory medication fail, surgical intervention is the next treatment. Given the rare nature of ochronotic arthropathy, surgical treatment options remain limited, and further research is necessary. The existing literature reports that arthroplasty is often necessary because of complete degradation of the articular cartilage with progressive ochronotic arthropathy. Ulucay et al.<sup>9</sup> described total joint replacement as an effective therapy for joints with degraded articular cartilage. However, for symptomatic patients who do not yet have severe progression of ochronotic arthropathy, arthroplasty may not be the best treatment option. In addition, given the hesitation of some patients to proceed with total joint replacement because of numerous factors such as age and activity level, alternative surgical options are necessary.

Knee arthroscopy is an excellent alternative option to arthroplasty for both management and diagnosis of ochronotic arthropathy. Arthroscopic debridement can provide patients with therapeutic pain relief and improvement in range of motion while potentially slowing the progression of cartilage degradation; in some cases, knee arthroscopy is also a useful adjunctive diagnostic tool.<sup>10</sup> The procedure described in [Video 1](#) shows a 38-year-old male patient who presented with a 4-year history of left knee pain and moderate effusion. Intraoperatively, there was significant synovitis and dark pigmentation of the articular cartilage and the menisci. Multiple tissue biopsy specimens were submitted for surgical pathologic analysis, which showed a diagnosis of ochronotic arthropathy.

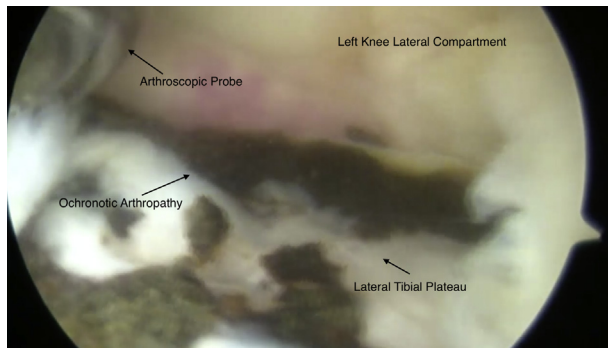
## Surgical Technique

### Preoperative Planning

Careful preoperative planning is an essential component of successful surgery. Advanced arthroscopic skills are necessary for surgical procedures that may be more



**Fig 2.** Diagnostic arthroscopy of medial compartment of left knee. The medial compartment is spared of any ochronotic arthropathy.

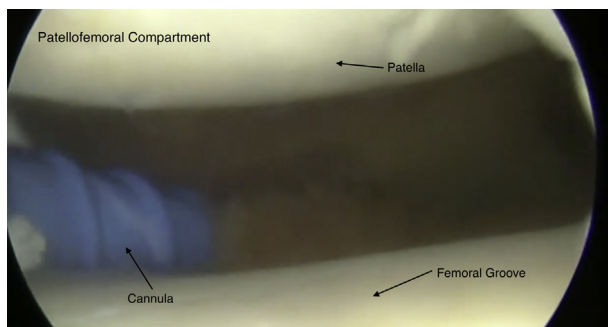


**Fig 3.** Diagnostic arthroscopy of lateral compartment of left knee. Severe degeneration of the left knee articular cartilage is noted.

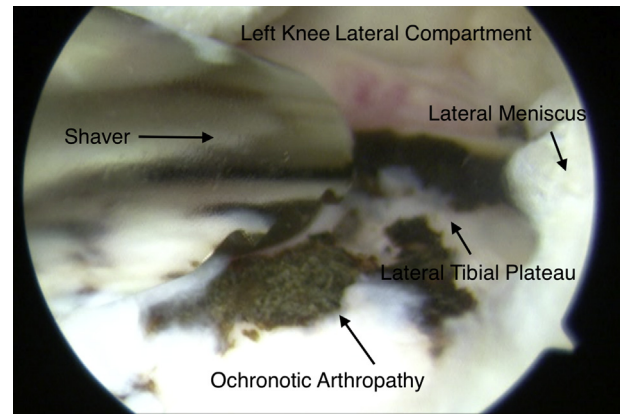
complicated than anticipated. Surgeons must be comfortable using various types of equipment and tools in addition to making complex medical decisions. A well-versed and qualified team of assistants, nurses, and an anesthesiologist is crucial for a smooth procedure. A communication game plan, including a checklist of all necessary equipment, needs to be established before bringing the patient into the operating room.

### Positioning

The patient is placed in a supine position on the operating room table followed by induction of general anesthesia with endotracheal intubation or a laryngeal mask airway. Epidural or spinal anesthesia can also be used, but there are more inherent risks, so we recommend general anesthesia. A pneumatic compression device is applied to the nonsurgical lower extremity to reduce the risk of postoperative deep venous thrombosis. With the patient under general anesthesia, the surgeon performs an examination of the knee, noting range of motion and gross instability of the knee. The knee is then injected with 20 mL of 0.25% bupivacaine hydrochloride with epinephrine and 20 mL of 0.25% bupivacaine hydrochloride without epinephrine. The operative extremity is prepared and draped in the usual sterile manner. A supportive bump composed of



**Fig 4.** Diagnostic arthroscopy of patellofemoral compartment of left knee. The patellofemoral compartment is spared of any ochronotic arthropathy.

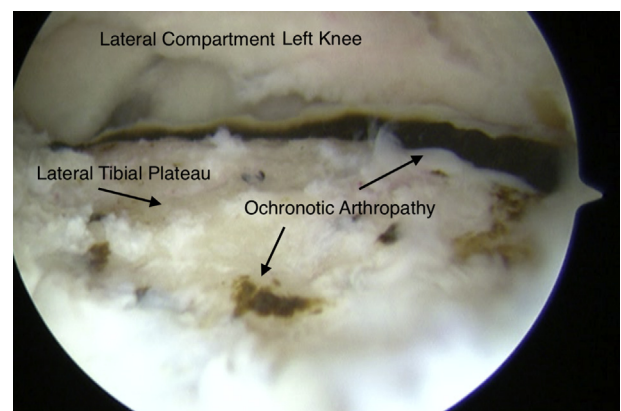


**Fig 5.** Arthroscopic view of lateral compartment of left knee, showing evidence of dark pigmentation deep in lateral meniscus and synovium, consistent with ochronotic arthropathy.

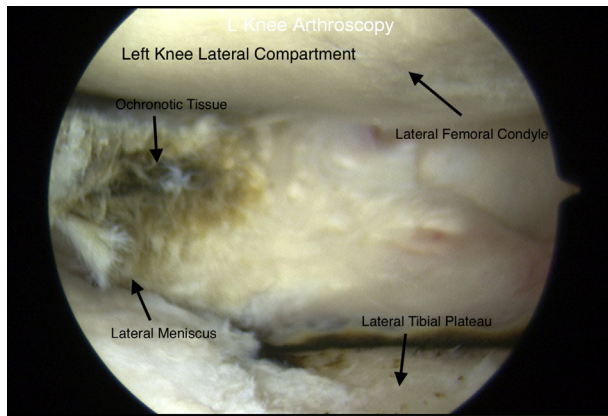
surgical towels is used, and the knee is bent to 90°. We no longer use a tourniquet for routine knee arthroscopy and do not place one around the thigh during the leg preparation. The patient's systolic blood pressure should remain between 90 and 100 mm Hg, which keeps bleeding to a minimum and allows for adequate intraoperative visualization. An arthroscopic pump is used with a pump pressure of 40 mm Hg using lactated ringer's solution with epinephrine.

### Diagnostic Arthroscopy With Incidental Debridement of Ochronotic Arthropathy

With the patient under general anesthesia, standard anterolateral and anteromedial portals are established and an arthroscopic cannula is introduced. If an abnormal amount of fluid is present, then a sample should be obtained and submitted to the laboratory for cell count, culture, and sensitivity assessment and examination for crystals. Only 2 arthroscopic portals are necessary because we have seen that a third arthroscopic superior-medial portal violates the vastus



**Fig 6.** Arthroscopic view of lateral aspect of left knee. Severe degeneration of the left knee articular cartilage is noted. The dark pigmentation appears to penetrate deep into the bone.



**Fig 7.** Arthroscopic view of lateral aspect of left (L) knee. A left knee partial lateral meniscectomy has been performed to debride the dark ochronotic tissue.

medialis obliquus muscle and inhibits postoperative rehabilitation.<sup>11</sup>

The arthroscope is placed through the anterolateral portal and an arthroscopic disposable cannula (3.5 × 8 mm; Smith & Nephew Dyonics) in the anteromedial portal with a side port with suction attached and controlled with an on-off valve. Diagnostic arthroscopy of all 3 compartments of the knee is then performed (Figs 2-4).

If black tissue is found in the articular cartilage, it should be debrided to a stable rim and a chondroplasty can be performed with a full-radius shaver (3.5 mm; Smith & Nephew Dyonics) (Fig 5). Some tissue may be hardened and may penetrate deep into the rim of the articular cartilage and bone (Fig 6). The shavings obtained should be submitted to the surgical pathology department for surgical examination. If black tissue enters the meniscus, this should be removed arthroscopically with a partial meniscectomy and submitted for pathologic examination (Fig 7).

A 3-compartment synovectomy should be performed with a full-radius shaver, and the synovial biopsy specimens of the synovium may also be taken and submitted to the laboratory for examination. After this, the knee should be thoroughly irrigated with lactated Ringer solution. A list of key points to perform the procedure is found in Table 2.

#### **Table 2.** Key Points of Surgical Technique

If a large amount of fluid is obtained with the introduction of the arthroscopic cannula, this should be submitted to the laboratory for cell count, culture, and sensitivity assessment and examination for crystals.
Any black tissue found in the articular cartilage should be extensively debrided to a stable rim.
Any black tissue found in the meniscus should be removed with a partial meniscectomy.
Shavings from the articular cartilage and the meniscus should be submitted to the surgical pathology department for further examination to evaluate for ochronotic arthropathy.

#### **Table 3.** Advantages and Risks of Debridement of Ochronotic Arthropathy

##### Advantages

- The need for total knee arthroplasty can be avoided or delayed.
- Arthroscopic debridement allows for a rapid recovery time.
- Future treatment options including hyaluronic acid injections or PRP injections.

##### Risks

- Arthroscopic surgery is not curative.
- An experienced surgeon is needed to perform the procedure safely and efficiently.

PRP, platelet-rich plasma.

#### **Postoperative Diagnosis of Alkaptonuric Ochronosis**

The surgical pathology report findings should be used to confirm the diagnosis of alkaptonuric ochronosis. Black pigmentation of fibrotendinous and cartilaginous tissue is strongly consistent with alkaptonuric ochronosis. The patient should be monitored postoperatively and use crutches as needed for comfort for the first few days. Active knee flexion and straight leg raising are started immediately. An aggressive physical therapy program is initiated within the first week postoperatively, with an emphasis on regaining range of motion followed by strength.

#### **Discussion**

Ochronotic arthropathy is a rare pathology observed in patients with alkaptonuria, an autosomal recessive metabolic disease with a prevalence of 1 in 1,000,000.<sup>12</sup> There is currently no cure for ochronotic arthropathy or alkaptonuria, and surgical options remain limited.

Because of the extremely rare prevalence of ochronotic arthropathy, there is no consensus on surgical treatment. Aydođdu et al.<sup>13</sup> described treating ochronotic arthropathy of the knee with cementless total knee arthroplasty with a satisfactory 4-year follow-up that showed no evidence of loosening of the implants. They described no bone formation complication despite the deleterious effects of ochronotic arthropathy on cartilage preservation.

Although total knee arthroplasty is reported to be a necessary intervention for severe progression of ochronotic arthropathy, we recommend arthroscopic debridement as an effective procedure for both management and diagnosis of the disease. Few cases of intraoperative discovery of ochronotic arthropathy during knee arthroscopy have been reported in the literature.<sup>12</sup> In a patient with a known diagnosis of ochronotic arthropathy, conservative treatment including physical therapy, analgesia, and rest is first advised. If these measures fail, arthroscopic debridement is recommended as both a diagnostic and therapeutic tool that can quickly alleviate symptoms including pain, limited range of motion, and swelling. A list of advantages and disadvantages of performing this

procedure can be found in Table 3. Perhaps most important, knee arthroscopy can delay the need for arthroplasty owing to cartilage degradation.<sup>10</sup> In addition, hyaluronic acid injections have shown promising therapeutic results after arthroscopic treatment of ochronotic arthropathy.<sup>14</sup>

Finally, radiography, magnetic resonance imaging, and bone scintigraphy can be considered in managing the clinical course of ochronotic arthropathy. Assessing the progression of joint space narrowing and reactive sclerosis of the articular surfaces can help better manage symptoms. Consultation with a rheumatologist should be considered to follow these arthropathies. Given the multiple systemic pathologies that are concurrent with ochronotic arthropathy, a full cardiac evaluation is also recommended. Furthermore, a geneticist may play a valuable role if one is considering a familial component to alkaptonuric ochronosis.

### References

1. Kara A, Celik H, Sezer H, Kilinc E, Uzun M. Ochronosis diagnosed after knee arthroscopy. *Int J Surg* 2014;5:497-499.
2. Raaijmakers M, Steenbrugge F, Dierickx C. Ochronosis, arthroscopy of a black knee: A case report and review of the literature. *Knee Surg Sports Trauma* 2007;16:182-184.
3. Cobey MC. Ochronosis: A case report. *Clin Orthop Relat Res* 1972;87:233-234.
4. Gil JA, Wawrzynski J, Waryasz GR. Orthopedic manifestations of ochronosis: Pathophysiology, presentation, diagnosis, and management. *Am J Med* 2016;129:536.e1-536.e6.
5. Chen A, Rose D, Desai P. Arthroscopic diagnosis and management of ochronotic arthropathy of the knee. *Arthroscopy* 2001;17:869-873.
6. Collins E, Hand R. Alkaptonuric ochronosis: A case report. *AANA J* 2005;73:41-46.
7. Doganavsargil B, Pehlivanoglu B, Bicer EK, et al. Black joint and synovia: Histopathological evaluation of degenerative joint disease due to ochronosis. *Pathol Res Pract* 2015;211:470-477.
8. Sahin G, Milcan A, Bagis S, et al. A case of ochronosis: Upper extremity involvement. *Rheumatol Int* 2001;21:78-80.
9. Ulucay C, Ozler T, Inan M, et al. Arthroplasty in ochronosis "tips and pearls in surgery": Case series. *J Arthritis* 2013;3:116.
10. Thacker M, Garude S, Puri A. Ochronotic arthropathy: Arthroscopic findings in the shoulder and the knee. *Arthroscopy* 2003;19:e99-e102.
11. Stetson WB, Templin K. Two-versus three-portal technique for routine knee arthroscopy. *Am J Sports Med* 2002;30:108-111.
12. Keller JM, Macaulay W, Nercessian OA, Jaffe IA. New developments in ochronosis: Review of the literature. *Rheumatol Int* 2005;25:81-85.
13. Aydoğdu S, Cullu E, Ozsoy MH, Sur H. Cementless total knee arthroplasty in ochronotic arthropathy: A case report with a 4-year follow-up. *J Arthroplasty* 2000;15:539-543.
14. Toussirof E, Aquaron R. Short-term efficacy of hyaluronic acid joint injections in a case of ochronotic arthropathy. *J Clin Rheumatol* 2013;19:152-153.