

# Quantitative assessment of the vascularity of the skeletally immature patella: a cadaveric study using MRI

Naomi E. Gadinsky<sup>1</sup>  
Kenneth M. Lin<sup>1</sup>  
Craig E. Klinger<sup>1</sup>  
Jonathan P. Dyke<sup>2</sup>  
Laura J. Kleeblad<sup>3</sup>  
Kevin G. Shea<sup>4</sup>  
David L Helfet<sup>1</sup>  
Scott A. Rodeo<sup>1</sup>  
Daniel W. Green<sup>1</sup>  
Lionel E. Lazaro<sup>5</sup>

## Abstract

**Purpose:** While predominant blood supply to the adult patella enters inferomedially, little is known about skeletally immature patellar perfusion. Improved knowledge of immature patella vascularity can further understanding of osteochondritis dissecans, dorsal defects of the patella and bipartite patella, and help ensure safe surgical approaches. We hypothesized that the immature patella would exhibit more uniform blood flow. The study purpose was to quantify immature patella regional perfusion in comparison with adults.

**Methods:** Ten cadaveric knees were utilized (five immature, five mature). The superficial femoral artery was cannulated proximally. Signal enhancement increases were compared from pre- to post-contrast MRI to assess relative arterial contributions to patella regions (quadrants, anterior/posterior, superior/inferior, medial/lateral, and outer/inner).

**Results:** Quantitative-MRI analysis revealed similar distribution of enhancement between the immature and mature

patella. The inferior pole exhibited significantly higher arterial contribution *versus* superior pole in both immature and mature groups ( $p = 0.009$ ; both groups), while the inferomedial quadrant had the highest arterial contribution of all quadrants in both groups. The superolateral quadrant demonstrated the lowest arterial contribution in the immature group and second lowest in the adult group. The patella outer periphery had significantly greater arterial contribution than the inner central region in both immature ( $p = 0.009$ ) and mature ( $p = 0.009$ ) groups.

**Conclusion:** Distribution of arterial contributions between the immature and mature patella was similar. Our results highlight the importance of inferior and inferomedial blood supply in both immature and mature patellas. These findings have implications for paediatric and adult patients; surgical damage to inferior patellar vessels should be avoided to prevent associated complications.

Cite this article: Gadinsky N E, Lin K M, Klinger C E, Dyke J P, Kleeblad L J, Shea K G, Helfet D L, Rodeo S A, Green D W, Lazaro L E. Quantitative assessment of the vascularity of the skeletally immature patella: a cadaveric study using MRI. *J Child Orthop* 2021;15:157-165. DOI: 10.1302/1863-2548.15.200261

**Keywords:** patella vascularity; quantitative-MRI; skeletally immature; skeletally mature

## Introduction

The blood supply to the mature patella has been extensively studied. A vascular ring fed by the five genicular arteries and the anterior tibial recurrent artery encircles the patella, giving off two main vessel systems that supply the patella: 1) the mid-patellar (dorsal) system; and 2) the radial system.<sup>1,2</sup> The majority of the patella's arterial supply enters inferomedially, in close proximity to the infrapatellar fat pad.<sup>2,3</sup> This vascular pattern has implications for surgical procedures about the knee joint, such as total knee arthroplasty and anterior cruciate ligament (ACL) reconstruction using bone-patellar tendon-bone (BTB) autograft, as iatrogenic damage to the inferior blood supply must be avoided to prevent potential patellofemoral complications postoperatively.<sup>1,4,5</sup>

<sup>1</sup> Hospital for Special Surgery/New York Presbyterian Hospital/Weill Cornell Medicine, New York, NY, USA

<sup>2</sup> Citigroup Biomedical Imaging Center and Weill Cornell Medicine, New York, NY, USA

<sup>3</sup> Northwest Clinics, Alkmaar, the Netherlands

<sup>4</sup> Stanford University Medical Center, Stanford, CA, USA

<sup>5</sup> Miami Orthopedic and Sports Medicine Institute, Baptist Health South Florida, Miami, FL, USA

Despite our knowledge of the adult patella, there is a paucity of literature on the vascularity of the immature patella. The patella becomes completely cartilaginous early in gestation, while progressive circumferential ossification begins at around three years of age and can last until the teenage years.<sup>6-8</sup> Throughout maturation, the ossification centres are areas of high metabolic activity, requiring a robust blood supply via a network of cartilage vascular canals for proper nutrition and development.<sup>9</sup> As ossification progresses, the vascularity of the remaining unossified cartilage declines<sup>9</sup> potentially creating opportunities for perfusion defects to arise.

Studying perfusion patterns of the immature patella may help improve the understanding of certain pathological conditions likely associated with early vascular compromise, including osteochondritis dissecans (OCD) of the patella, dorsal defects of the patella (DDP) and bipartite patella (BP). Furthermore, an increasing number of children and adolescents are undergoing operative interventions involving the knee joint once thought of as adult procedures, such as ACL reconstruction, cartilage or osteochondral procedures and medial patellofemoral ligament reconstruction. Improved understanding of the vascularity of the developing patella will help guide surgical technique and indications in paediatric patients.

The purpose of our study was to quantify vascularity of the immature patella, and to compare regional perfusion patterns with those of the adult patella. We hypothesized that the paediatric patella would exhibit more uniform distribution of arterial contributions compared with the adult patella, given the greater proportional metabolic demand to support the growing and ossifying patella. We utilize a quantitative-MRI (qMRI) protocol that has previously been validated and used to quantify arterial contribution to the adult patella as well as other bony and soft tissue structure of the lower extremity.<sup>3,10-12</sup> To the best of our knowledge, this is the first study to quantify regional arterial contribution in the immature patella.

## Materials and methods

### *Cadaveric specimens*

An institutional review board exemption was provided for this cadaveric tissue study. Ten cadaveric specimens were obtained, including five fresh frozen skeletally immature human cadaver knees (ages between 0 and six months, mean age 3.0 months) and five fresh frozen skeletally mature human cadaver knees (ages between 34 and 60 years, mean age 50.2 years); skeletally immature cadaveric knee specimens were obtained from Allosource (Centennial, Colorado) and mature specimens from Anatomy

Gifts Registry (Hanover, Maryland). In the paediatric group, there were four male and one female knee. In the adult group, there were three male and two female knees. Exclusion criteria included history of peripheral vascular disease, prior lower extremity surgery or lower extremity trauma. Cause of death of the paediatric specimens was not known, however, none had a known history of chromosomal anomalies.

### *Specimen dissection and preparation*

Specimen dissection and preparation was performed in our institution's Bioskills Education Laboratory, which is an American College of Surgeons accredited dissection laboratory. Prior to imaging, the superficial femoral artery was cannulated proximal to the knee joint, along the femoral stump and with minimal dissection performed and cannulas sutured in place. Vessel cannulas (model DLP 30000, Medtronic, Minneapolis, Minnesota) were used for cannulation. Infusion of normal saline was performed via syringe and all major extravasating vessels distal to the knee joint were tied off with silk ties.

### *MRI acquisition methods*

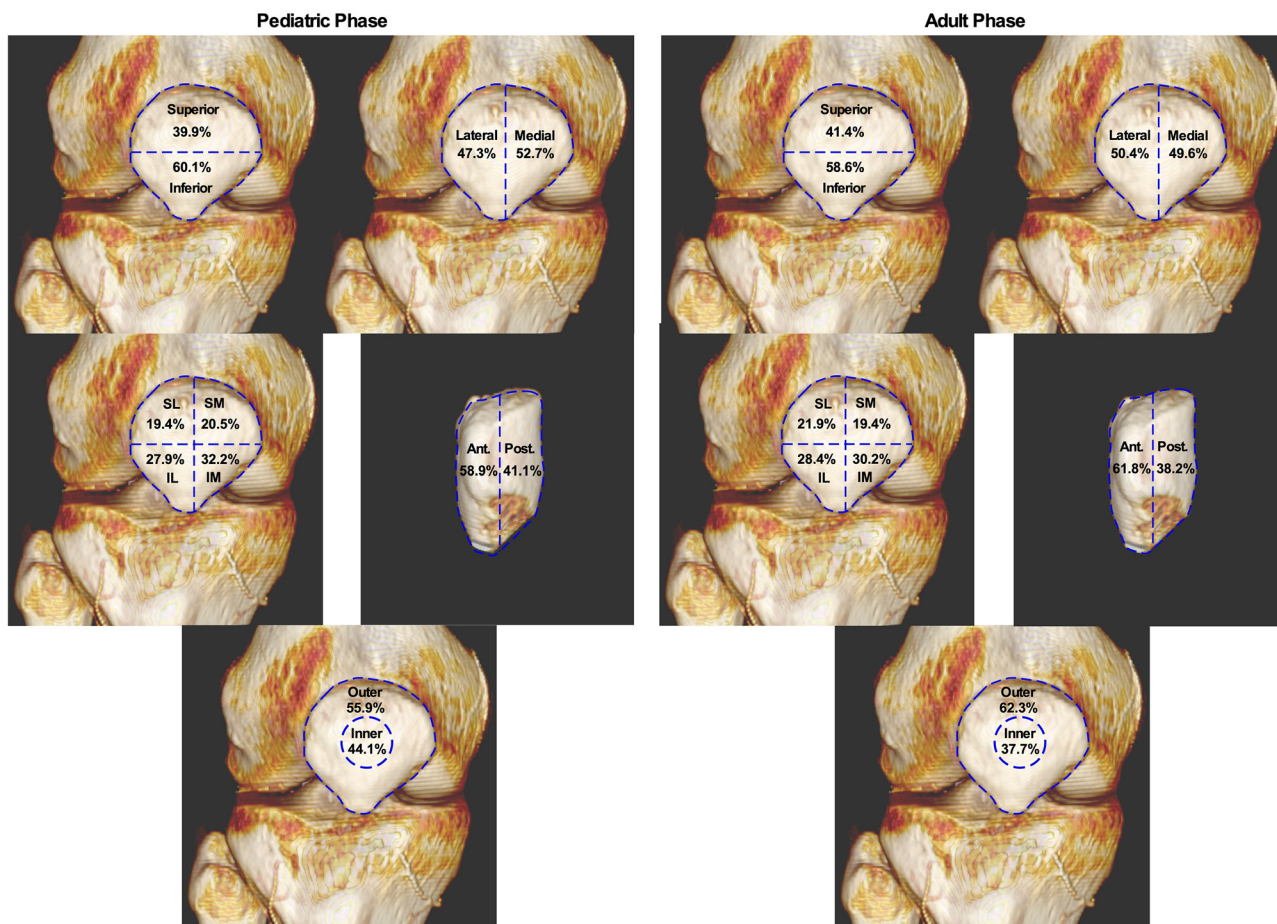
Imaging was completed using a 3.0 Tesla Excite HD GE MRI scanner (General Electric Healthcare, Milwaukee, Wisconsin). An eight-channel knee coil was used for the adult knees, while an eight-channel wrist coil was used for the paediatric knees due to the smaller specimen size. Images were obtained using a previously reported protocol used for similar research quantifying arterial contributions.<sup>3,13</sup> Gadolinium-diethylenetriamine pentaacetic acid (Gd-DTPA) was diluted with normal saline at a ratio of 3:1 to serve as a MRI contrast agent. The contrast solution volume for the adult specimen (61 ml total infusion volume) was based on a previous qMRI study which evaluated adult patella arterial perfusion.<sup>3</sup> The contrast solution volume utilized for the neonatal specimen (5 ml total infusion volume) was selected by measuring and adjusting for the size difference between adult and neonatal specimens. High-resolution fat-suppressed 3D T<sub>1</sub>-weighted gradient echo sequences were obtained both prior to and following contrast solution injection. Fat-suppressed MRI images were used for qMRI assessment purposes in order to remove signal generated by fatty bone marrow which may obscure Gd-DTPA image detail. MRI images were acquired both pre- and post-contrast solution infusion at 2-mm slice thickness. Post-contrast MRI imaging was performed at a single time point i.e. ten minutes following contrast infusion. Images were reconstructed to achieve a resolution of 0.4 mm × 0.4 mm × 1.0 mm. Image acquisition parameters consisted of repetition and echo times of 18.6 ms and 5.3 ms, respectively, using a 35° flip angle.

*qMRI analysis*

For quantitative analysis, regions of interest (ROI) corresponding to the four quadrants of the patella as well as the outer and inner portions were identified and manually defined on pre-contrast coronal MRI images. The four quadrants included superomedial (SM), superolateral (SL), inferomedial (IM) and inferolateral (IL); and additional regions analyzed included anterior and posterior regions, superior and inferior, medial and lateral, and inner and outer regions (Fig. 1). These ROIs were used to evaluate the increase in signal intensity from the defined ROI on pre-contrast images to the same ROI area on post-contrast images using software developed by a study investigator (JPD) based on Interactive Data Language (IDL) 6.4 (Harris Geospatial; Boulder, Colorado). The analysis software permits custom ROIs to be defined by the user over multiple MRI study slices, with each corresponding to differing anatomical sites (for example a quadrant of the patella). After ROIs are defined for all associated regions within the MRI slice range, the analysis software automatically creates a data file. For each ROI,

the data file includes the MRI slice number, ROI slice signal intensity, and total area (in voxels). The software also saves ROI definition files to enable the same ROI definitions to be applied to both pre- and post-contrast MRI images, allowing precise comparison of the same osseous regions. This technique has been previously validated in qMRI research which assessed arterial contributions along multiple anatomical sites using the same qMRI assessment protocol.<sup>3,4,10-13</sup> This qMRI analysis software has been previously described in the assessment of vascularity to various structure of the lower extremity.<sup>3,10-12</sup> Signal enhancement was quantified to produce a weighted average, and raw signal intensity (defined as the mean signal intensity of each region defined in each ROI on each MRI slice) per voxel was corrected through normalization to non-enhancing muscle tissue proximal to the cannulation point as a baseline measurement to account for theoretical potential changes in MRI gain which could affect signal intensity measurements.

Increase in signal enhancement following contrast injection through the arterial system supplying the



**Fig. 1** Paediatric and adult mean percentage increase in perfusion for each quadrant and region (percentages rounded to the one decimal place) (SL, superolateral; SM, superomedial; IL, inferolateral; IM, inferomedial; Ant., anterior; Post., posterior).



patella was considered to represent arterial contribution in both paediatric and adult specimens. Normalized data from each of the four quadrants was combined with the addition of ROI regions to allow for comparisons between specific regions of the patella, including superior *versus* inferior regions and medial *versus* lateral regions (Fig. 1). Anterior *versus* posterior regions of the patella were also compared using normalized data from the anterior and posterior MRI slices, as well as for inner and outer aspects, respectively, for each study patella (Fig. 1).

#### Statistical analysis

Non-parametric tests were performed using medians and interquartile ranges, as there were only five specimens per group. Quadrant and regional analyses were performed in both the paediatric and adult groups. For the quadrant analysis, the Kruskal-Wallis test was used to evaluate significant differences in perfusion between the four quadrants of the patella, including the SL, SM, IL and IM quadrants (Fig. 1). For the regional analysis, the Mann-Whitney U test was used to test for significant differences in perfusion between the following regions of the patella: 1) anterior *versus* posterior; 2) superior *versus* inferior; 3) medial *versus* lateral; and 4) outer *versus* inner (Fig. 1). Finally, to assess differences in perfusion patterns between the paediatric *versus* adult groups in both the quadrant and regional analyses, the Mann-Whitney U test was utilized. A p-value < 0.05 was considered statistically significant.

## Results

#### Paediatric group

Quadrant analysis revealed significant differences in perfusion patterns among the four quadrants of the patella ( $p = 0.002$ ), as represented by change in normalized signal enhancement following contrast administration. The median and interquartile range for each quadrant are presented in Table 1, as well as the statistical analysis using the Kruskal-Wallis test which showed significant differences in pairwise comparisons among the quadrants. The mean percentage increase in signal enhancement for each quadrant is depicted in Fig. 1.

Regional comparisons of median signal enhancement following contrast administration revealed the following: no significant difference anterior *versus* posterior ( $p = 0.076$ ); significantly greater signal enhancement inferiorly compared with superior ( $p = 0.009$ ); no significant difference medial *versus* lateral ( $p = 0.421$ ); and significantly greater enhancement to the periphery compared with the central region of the patella ( $p = 0.009$ ). Raw data and

descriptive statistics including medians and interquartile ranges are summarized in Table 2. The mean percentage increase in signal enhancement for each region is depicted in Figure 1.

#### Adult group

Quadrant analysis revealed significant differences in normalized signal enhancement following contrast administration among the four quadrants of the patella ( $p = 0.030$ ). The raw data, median and interquartile range for each quadrant, and *post hoc* analysis using Kruskal-Wallis test, can be found in Table 1 and mean percentage increase in signal enhancement for each quadrant is depicted in Figure 1.

Regional analysis showed the following: significantly greater increase in signal enhancement in the anterior half of the patella compared with posterior ( $p = 0.009$ ); significantly greater enhancement in the inferior pole compared with superior ( $p = 0.009$ ); no significant difference in the medial *versus* lateral halves of the patella ( $p = 0.917$ ); and significantly greater signal enhancement to the periphery of the patella compared with the central region ( $p = 0.009$ ). Results including raw data, medians and interquartile ranges and *post hoc* analysis are summarized in Table 2. The mean percentage increase in signal enhancement for each region is depicted in Figure 1.

#### Paediatric versus adult group

There were no significant differences in perfusion between paediatric *versus* adult group in any of the four quadrants of the patella. Regions of the patella (anterior/posterior, superior/inferior, medial/lateral, outer/inner) were also compared between the paediatric *versus* adult group and no significant differences were found.

## Discussion

This qMRI analysis demonstrated analogous perfusion patterns of the paediatric and adult specimens. In both groups, the inferior pole of the patella received statistically significant greater perfusion than the superior pole, with the IM quadrant receiving the greatest perfusion of all four quadrants. The outer rim of the patella received statistically significant greater perfusion than the central inner region of the patella in both groups, and in the paediatric specimens, the SL quadrant received the least relative perfusion (second least in the adult specimens). These findings are supported by prior cadaveric studies involving predominantly adult specimens.<sup>2-5</sup> Scapinelli<sup>2</sup> first described the main arterial systems to the patella, including the mid-patellar (dorsal) system

**Table 1** Paediatric and adult percentage increase in enhancement for the patellar quadrants

Age, mths	Sex	Superolateral (SL)	Superomedial (SM)	Inferolateral (IL)	Inferomedial (IM)	p-value <sup>†</sup>
<b>Paediatric group</b>						
0	F	26.2	19.3	25.7	28.8	
2	M	12.8	22.5	26.8	37.9	
2	M	21.4	20.0	28.5	30.1	
5	M	19.6	20.8	25.1	34.5	
6	M	17.0	19.8	33.4	29.8	
	<b>Median</b>	<b>19.6</b>	<b>20.0</b>	<b>26.8</b>	<b>30.1</b>	<b>0.002<sup>†</sup></b>
	<b>Range<sup>*</sup></b>	<b>14.9 to 23.8</b>	<b>19.6 to 21.6</b>	<b>25.4 to 31.0</b>	<b>29.3 to 36.2</b>	
	<b>Mean</b>	<b>19.4</b>	<b>20.5</b>	<b>27.9</b>	<b>32.2</b>	
	<b>SD</b>	<b>5.0</b>	<b>1.2</b>	<b>3.3</b>	<b>3.8</b>	
<b>Adult group</b>						
34	M	30.2	16.7	30.3	22.9	
48	F	27.8	15.0	26.3	31.0	
53	M	24.9	24.7	20.6	29.8	
56	F	15.2	18.9	32.7	33.2	
60	M	11.6	22.0	32.4	34.1	
	<b>Median</b>	<b>24.9</b>	<b>18.9</b>	<b>30.3</b>	<b>31.0</b>	<b>0.030<sup>∇</sup></b>
	<b>Range<sup>*</sup></b>	<b>13.4 to 29.0</b>	<b>15.8 to 23.4</b>	<b>23.4 to 32.6</b>	<b>26.3 to 33.7</b>	
	<b>Mean</b>	<b>21.9</b>	<b>19.4</b>	<b>28.4</b>	<b>30.2</b>	
	<b>SD</b>	<b>8.1</b>	<b>4.0</b>	<b>5.1</b>	<b>4.4</b>	

\*Ranges are reported as interquartile ranges (25th to 75th percentile).

<sup>†</sup>Kruskal-Wallis test, *post hoc* analysis showed significant differences between SL versus IL ( $p = 0.028$ ), SL versus IM ( $p = 0.009$ ), SM versus IL ( $p = 0.009$ ), SM versus IM ( $p = 0.009$ )

<sup>∇</sup>Kruskal-Wallis test, *post hoc* analysis showed significant differences between SM versus IL ( $p = 0.028$ ), SM versus IM ( $p = 0.016$ )

entering anteriorly and the infrapatellar vessels entering inferiorly. He noted this vascular anatomy gave the inferior patella dual blood supply, therefore, explaining the clinically lower rate of osteonecrosis seen in the inferior pole compared with the superior pole of the patella.<sup>2</sup> A subsequent study in adults using qMRI found that all specimens had a dominant inferior blood supply, with 80% of specimens showing a dominant vessel entering inferomedially.<sup>3</sup>

In contrast with our initial hypothesis that the paediatric group would display a more uniform vascular distribution, our results imply that paediatric patients have similar perfusion patterns as adults. This suggests the patellar vascular structure is determined very early in development, with a distribution similar to that seen in adults even before ossification takes place, when cartilage canals are present. It is possible this vascularity gradient is related to ossification patterns of the patella. In a MRI study of skeletally immature subjects two to 19 years of age, the inferior portion was observed to ossify first and the superior tip last.<sup>8</sup> The similar perfusion patterns between immature and mature specimens suggest analogous vessel architecture. In a qualitative microangiographic study comparing

the gross knee joint vasculature in paediatric (aged seven days to 12 years) and adult (aged 50 to 93 years) cadaveric specimens, vessel arrangements were similar in both groups.<sup>14</sup>

Knowledge of the perfusion pattern and particularly dominant blood supply to the patella has implications for surgical planning, as it is important that the inferior and IM vessels entering the patella are left intact in young patients undergoing knee surgery. The incidence of operative treatment for ligamentous knee injuries in children and adolescents is increasing,<sup>15,16</sup> namely ACL reconstruction with BTB autograft.<sup>17</sup> In an adult cadaveric study, a 56% decrease in patellar perfusion was observed as a result of damage to the predominant IM blood supply during BTB harvest.<sup>4</sup> Iatrogenic damage to these vessels may lead to patellofemoral complications and anterior knee pain in adults,<sup>1</sup> which could occur in paediatric patients considering their similar arterial distribution. Additionally, there are higher rates of patellar osteoarthritis following BTB autograft, compared with hamstring autograft;<sup>18</sup> this could be related to disruption of patellar blood supply, although further study is required. Further research is needed to address clinical implications of iat-

**Table 2** Paediatric and adult percentage increase in enhancement for the patellar regions

Age, months	Sex	Anterior	Posterior	p-value†	Superior	Inferior	p-value†	Medial	Lateral	p-value†	Outer	Inner	p-value†
<b>Paediatric group</b>													
0	F	47.8	52.2		45.5	54.5		48.1	51.9		56.1	43.9	
2	M	47.3	52.7		35.3	64.7		60.3	39.7		60.9	39.1	
2	M	76.7	23.3		41.4	58.6		50.1	49.9		50.5	49.5	
5	M	59.6	40.4		40.4	59.6		55.3	44.7		54.7	45.3	
6	M	63.2	36.8		36.8	63.2		49.6	50.4		57.5	42.5	
	<b>Median</b>	<b>59.7</b>	<b>40.4</b>	<b>0.076</b>	<b>40.4</b>	<b>59.6</b>	<b>0.009</b>	<b>50.1</b>	<b>49.9</b>	<b>0.421</b>	<b>56.1</b>	<b>43.9</b>	<b>0.009</b>
	<b>Range</b>	<b>47.5 to 69.9</b>	<b>30.1 to 52.5</b>		<b>36.1 to 43.4</b>	<b>56.6 to 63.9</b>		<b>48.9 to 57.8</b>	<b>42.2 to 51.1</b>		<b>52.6 to 59.2</b>	<b>40.8 to 47.4</b>	
	<b>Mean</b>	<b>58.9</b>	<b>41.1</b>		<b>39.9</b>	<b>60.1</b>		<b>52.7</b>	<b>47.3</b>		<b>55.9</b>	<b>44.1</b>	
	<b>SD</b>	<b>12.2</b>	<b>12.2</b>		<b>4.0</b>	<b>4.0</b>		<b>5.1</b>	<b>5.1</b>		<b>3.8</b>	<b>3.8</b>	
<b>Adult group</b>													
34	M	58.0	42.0		46.9	53.1		39.5	60.5		52.1	47.9	
48	F	58.5	41.5		42.8	57.2		45.9	54.1		69.2	30.8	
53	M	64.7	35.3		49.6	50.4		54.5	45.5		59.2	40.8	
56	F	65.4	34.6		34.0	66.0		52.1	47.9		66.2	33.8	
60	M	62.2	37.8		33.5	66.5		56.1	43.9		65.0	35.0	
	<b>Median</b>	<b>62.2</b>	<b>37.8</b>	<b>0.009</b>	<b>42.8</b>	<b>57.2</b>	<b>0.009</b>	<b>52.1</b>	<b>47.9</b>	<b>0.917</b>	<b>65.1</b>	<b>35.0</b>	<b>0.009</b>
	<b>Range</b>	<b>58.3 to 65.1</b>	<b>34.9 to 41.8</b>		<b>33.8 to 48.2</b>	<b>51.8 to 66.2</b>		<b>42.7 to 55.3</b>	<b>44.7 to 57.3</b>		<b>55.7 to 67.7</b>	<b>32.3 to 44.4</b>	
	<b>Mean</b>	<b>61.8</b>	<b>38.2</b>		<b>41.4</b>	<b>58.6</b>		<b>49.6</b>	<b>50.4</b>		<b>62.3</b>	<b>37.7</b>	
	<b>SD</b>	<b>3.4</b>	<b>3.4</b>		<b>7.3</b>	<b>7.3</b>		<b>6.8</b>	<b>6.8</b>		<b>6.8</b>	<b>6.8</b>	

\*Ranges are reported as interquartile ranges (25<sup>th</sup> to 75<sup>th</sup> percentile).

†Mann-Whitney U test was used to compare the regions.

rogenic damage to the patellar arterial supply in skeletally immature patients.

In addition to surgical planning, our data also may help improve understanding of patellar OCD lesions. Several potential aetiologies for OCD lesions have been proposed, including genetic, inflammatory, vascular and repetitive microtrauma.<sup>19</sup> According to the vascular hypothesis, it is thought that patellar OCD lesions are caused by failure of the vascular cartilage canals during development, leading to focal osteonecrosis and subsequent subchondral bone defects.<sup>20,21</sup> Although patellar OCD is far less common than lesions of other areas, these lesions cause significant pain and discomfort, with one-third of patellar lesions eventually requiring surgery.<sup>22</sup> In a series of eight patellar OCD lesions in adolescents, seven lesions were located centrally and one was in the SL region of the patella.<sup>23</sup> The location of these lesions correlate with the areas of lower relative perfusion in the central and SL portions of the immature patella observed in this study, supporting vascular failure during development as a potential aetiology of patellar OCD.

The results of this study also support a possible vascular aetiology of DDP and BP. DDP is an uncommon lytic lesion generally found in the SL region of the patella during adolescence through the second decade of life,<sup>24</sup> and may cause symptoms such as chronic intermittent pain.<sup>25,26</sup> Prior studies have shown that DDP lesions demonstrate areas of focal avascular necrosis.<sup>24</sup> Similarly, BP occurs predominantly in the SL zone of the patella, and although precise aetiology remains unknown, vascular compromise is a possible contributor. A histological analysis of adolescent BP specimens found that the interposed tissue was largely fibrous, almost completely lacked blood vessels and showed diffuse degenerative and necrotic changes.<sup>27</sup> Although treatment options for symptomatic BP vary widely, reflecting general lack of consensus,<sup>28</sup> the finding of lowest perfusion in the SL quadrant in this study supports the recommended treatment of excision of a painful BP, rather than fixation.<sup>29</sup> Even in patients without BP, Scapinelli<sup>2</sup> noted fractures of the SL portion of the patella rarely unite, which was attributed to poor intraosseous and peripheral blood supply in that region. While further study is warranted to better characterize role of vascularity in the pathogenesis of these conditions, it is possible that DDP, BP and patella OCD may be different manifestations of a similar disease process, namely vascular phenomena during development.

Limitations of our study include the small number of cadaveric samples used (five per group). Therefore, this data has to be interpreted with caution as this study has been limited due to the procurement of young specimens. It is extremely difficult to obtain

infantile or paediatric human cadaveric specimens for research purposes, making a larger sample size difficult to achieve. Furthermore, this study was a pilot study within this field, therefore, not suitable for (*post hoc*) power analysis. We were also unable to obtain MRI data on perfusion in live human individuals, as there are risks associated with contrast administration in children, the most well-described being nephrotoxicity.<sup>30-32</sup> Another study limitation was that we did not map out the individual vascular pattern in each specimen, but rather analyzed overall perfusion within the designated ROI groups. Further research using higher resolution MRI or micro-computed tomography could help define the precise vascular pattern supplying the immature patella, making comparisons with adult patellar vascularity even stronger. Nevertheless, this study remains unique in the literature, as we performed a detailed perfusion analysis of individual quadrants and regions of the immature patella. Another potential limitation is that our adult cohort received a larger volume of contrast than the paediatric cohort. It is unknown whether the volume of contrast may have had a significant effect on signal intensity measurements. To overcome this, all quantitative analysis was performed with normalization to a non-enhancing region of muscle within each specimen as a baseline, resulting in normalized data that could be compared across different specimens regardless of specimen size or contrast volume. However, further research using contrast volumes further standardized to individual specimen size would be beneficial.

### Conclusion

Similar perfusion patterns between adult and paediatric patellas were observed using qMRI, with highest perfusion observed in the IM quadrant as well as higher perfusion in the periphery compared with central regions of the patella. The dominant IM blood supply to the patella must be preserved during paediatric knee surgery, where these vessels may be at risk of iatrogenic damage. Improved knowledge of the arterial supply to the immature patella will advance our understanding of various pathologies of the knee and better guide surgical indications and techniques in adult and paediatric patients.

Received 18 December 2020, accepted after revision 10 March 2021

### COMPLIANCE WITH ETHICAL STANDARDS

#### FUNDING STATEMENT

No benefits in any form have been received or will be received from a commercial party related directly or indirectly to the subject of this article.

### OA LICENCE TEXT

This article is distributed under the terms of the Creative Commons Attribution-Non Commercial 4.0 International (CC BY-NC 4.0) licence (<https://creativecommons.org/licenses/by-nc/4.0/>) which permits non-commercial use, reproduction and distribution of the work without further permission provided the original work is attributed.

### ETHICAL STATEMENT

**Ethical approval:** An Institutional Review Board exemption was provided for this cadaveric tissue study. This article does not contain any studies with human participants or animals performed by any of the authors.

**Informed consent:** Not required.

### ICMJE CONFLICT OF INTEREST STATEMENT

One author reports personal fees from Advance Medical/Teladoc, personal fees from Ortho RTI, Inc., outside the submitted work. All other authors declare that they have no conflict of interest.

### FUNDING

This research was funded by the Hospital for Paediatric Service Research Award, specifically the contrast-enhanced MRI imaging.

### AUTHOR CONTRIBUTIONS

NEG, KML, CEK, and LEL were involved in study design, data and MRI acquisition, MRI-ROI analysis, statistical analysis, preparation of the initial manuscript draft, and manuscript revisions.

JPD, LJK were involved in study design, data and MRI acquisition, statistical analysis, preparation of the initial manuscript draft, and manuscript revisions.

KGS, DLH, SAR, DWG were involved in study design, preparation of the initial manuscript draft, and manuscript revisions.

### REFERENCES

- Gadinsky NE, Lorich DG, Lazaro LE.** Patellar vascularity and surgical intervention about the knee: is postoperative anterior knee pain secondary to a patellar vascular insult? *Ann Sport Med Res* 2017;4:1125.
- Scapinelli R.** Blood supply of the human patella. Its relation to ischaemic necrosis after fracture. *J Bone Joint Surg [Br]* 1967;49-B:563-570.
- Lazaro LE, Wellman DS, Klinger CE, et al.** Quantitative and qualitative assessment of bone perfusion and arterial contributions in a patellar fracture model using gadolinium-enhanced magnetic resonance imaging: a cadaveric study. *J Bone Joint Surg [Am]* 2013;95:e1401-e1407.
- Jones KJ, Lazaro LE, Taylor SA, et al.** Quantitative assessment of patellar vascularity following bone-patellar tendon-bone autograft harvest for ACL reconstruction. *Knee Surg Sports Traumatol Arthrosc* 2016;24:2818-2024.
- Lazaro LE, Cross MB, Lorich DG.** Vascular anatomy of the patella: implications for total knee arthroplasty surgical approaches. *Knee* 2014;21:655-660.
- Maloney E, Stanescu AL, Ngo AV, Parisi MT, Iyer RS.** The pediatric patella: normal development, anatomical variants and malformations, stability, imaging, and injury patterns. *Semin Musculoskelet Radiol* 2018;22:81-94.
- Ogden JA.** Radiology of postnatal skeletal development. X. Patella and tibial tuberosity. *Skeletal Radiol* 1984;11:246-257.
- Pennock AT, Bomar JD, Manning JD.** The creation and validation of a knee bone age atlas utilizing MRI. *J Bone Joint Surg [Am]* 2018;100:e20.
- Yousefzadeh DK, Doerger K, Sullivan C.** The blood supply of early, late, and nonossifying cartilage: preliminary gray-scale and Doppler assessment and their implications. *Pediatr Radiol* 2008;38:146-158.
- Boraiah S, Dyke JP, Hettrich C, et al.** Assessment of vascularity of the femoral head using gadolinium (Gd-DTPA)-enhanced magnetic resonance imaging: a cadaver study. *J Bone Joint Surg [Br]* 2009;91-B:131-137.
- Lazaro LE, Nawabi DH, Klinger CE, et al.** Quantitative assessment of femoral head perfusion following arthroscopic femoral osteochondroplasty: a cadaveric study. *J Bone Joint Surg [Am]* 2017;99:2094-2102.
- Lin KM, Gadinsky NE, Klinger CE, et al.** Increased vascularity in the neonatal versus adult meniscus: evaluation with magnetic resonance imaging. *Cartilage* 2020 May 2020. (Epub ahead of print)
- Dewar DC, Lazaro LE, Klinger CE, et al.** The relative contribution of the medial and lateral femoral circumflex arteries to the vascularity of the head and neck of the femur: a quantitative MRI-based assessment. *Bone Joint J* 2016;98-B:1582-1588.
- Shim SS, Leung G.** Blood supply of the knee joint. A microangiographic study in children and adults. *Clin Orthop Relat Res* 1986;208:119-125.
- Popkin CA, Wright ML, Pennock AT, et al.** Trends in management and complications of anterior cruciate ligament injuries in pediatric patients: a survey of the PRISM society. *J Pediatr Orthop* 2018;38:e61-e65.
- Soneru A, Sarwark JF.** Survivorship of allograft ACL reconstruction in adolescent patients. *J Orthop* 2018;16:11-13.
- Funahashi KM, Moksnes H, Maletis GB, et al.** Anterior cruciate ligament injuries in adolescents with open physis: effect of recurrent injury and surgical delay on meniscal and cartilage injuries. *Am J Sports Med* 2014;42:1068-1073.
- Pinczewski LA, Lyman J, Salmon LJ, et al.** A 10-year comparison of anterior cruciate ligament reconstructions with hamstring tendon and patellar tendon autograft: a controlled, prospective trial. *Am J Sports Med* 2007;35:564-574.
- Crawford DC, Safran MR.** Osteochondritis dissecans of the knee. *J Am Acad Orthop Surg* 2006;14:90-100.
- Olstad K, Shea KG, Cannamela PC, et al.** Juvenile osteochondritis dissecans of the knee is a result of failure of the blood supply to growth cartilage and osteochondrosis. *Osteoarthritis Cartilage* 2018;26:1691-1698.
- Ytrehus B, Carlson CS, Ekman S.** Etiology and pathogenesis of osteochondrosis. *Vet Pathol* 2007;44:429-448.
- Weiss JM, Nikizad H, Shea KG, et al.** The incidence of surgery in osteochondritis dissecans in children and adolescents. *Orthop J Sports Med* 2016;4:2325967116635515.
- Chadli L, Cottalorda J, Delpont M, et al.** Autologous osteochondral mosaicplasty in osteochondritis dissecans of the patella in adolescents. *Int Orthop* 2017;41:197-202.
- van Holsbeeck M, Vandamme B, Marchal G, et al.** Dorsal defect of the patella: concept of its origin and relationship with bipartite and multipartite patella. *Skeletal Radiol* 1987;16:304-311.
- Gerrie BJ, McCulloch PC, Labis JS, Lintner DM, Harris JD.** Dorsal defect of the patella in a teenage male football player: a case report and differential diagnosis of lytic patellar lesion. *Orthop J Sports Med* 2016;4:2325967116665580.



26. **Narváez J, Narváez JA, Clavaguera MT, et al.** Dorsal defect of the patella: an uncommon cause of knee pain. *Arthritis Rheum* 1996;39:1244-1245.
27. **Oohashi Y, Noriki S, Koshino T, Fukuda M.** Histopathological abnormalities in painful bipartite patellae in adolescents. *Knee* 2006;13:189-193.
28. **McMahon SE, LeRoux JA, Smith TO, Hing CB.** The management of the painful bipartite patella: a systematic review. *Knee Surg Sports Traumatol Arthrosc* 2016;24:2798-805.
29. **Atesok K, Doral MN, Lowe J, Finsterbush A.** Symptomatic bipartite patella: treatment alternatives. *J Am Acad Orthop Surg* 2008;16:455-461.
30. **Elbeshlawi I, AbdelBaki MS.** Safety of gadolinium administration in children. *Pediatr Neurol* 2018;86:27-32.
31. **Penfield JG.** Nephrogenic systemic fibrosis and the use of gadolinium-based contrast agents. *Pediatr Nephrol* 2008;23:2121-2129.
32. **Rozenfeld MN, Podberesky DJ.** Gadolinium-based contrast agents in children. *Pediatr Radiol* 2018;48:1188-1196.