



Since January 2020 Elsevier has created a COVID-19 resource centre with free information in English and Mandarin on the novel coronavirus COVID-19. The COVID-19 resource centre is hosted on Elsevier Connect, the company's public news and information website.

Elsevier hereby grants permission to make all its COVID-19-related research that is available on the COVID-19 resource centre - including this research content - immediately available in PubMed Central and other publicly funded repositories, such as the WHO COVID database with rights for unrestricted research re-use and analyses in any form or by any means with acknowledgement of the original source. These permissions are granted for free by Elsevier for as long as the COVID-19 resource centre remains active.



Inner retinal layer ischemia and vision loss after COVID-19 infection: A case report

Hatice Kubra Sonmez^{a,*}, Osman Ahmet Polat^b, Guzel Erkan^b

^a Department of Ophthalmology, Kayseri State Hospital, Kayseri, Turkey

^b Department of Ophthalmology, Erciyes University, Kayseri, Turkey

ARTICLE INFO

Keywords:

Paracentral acute middle maculopathy
Retinal ischemia
OCTA

ABSTRACT

Introduction: COVID-19 infection may also occur with ocular manifestations. Paracentral acute middle maculopathy (PAMM) is a condition that causes ischemia in the inner retinal layers characterized by disruptions in capillary plexus flow. Also, ischemia in inner retinal layers secondary to COVID-19 infection has not yet been reported.

Case report: The case, presented with the complaint of gradually decreasing visual acuity in the right eye after COVID-19 infection. PAMM was suspected, however, ischemia was detected in all inner retinal layers with Optical coherence tomography angiography.

Discussion: We showed that it should be kept in mind that atypical retinal involvement of COVID-19 infection could present, with this case.

1. Introduction

While the blood supply of the outer retina layers is provided by the choriocapillaris, the blood supply of the inner layers is provided by the capillary plexus. The central macula has 3 main tri-laminar capillary plexuses. The superficial capillary plexus (SCP) supplies the area from the ganglion cell layer to the inner nuclear layer (INL), the intermediate capillary plexus (ICP) supplies the interior of the INL and the deep capillary plexus (DCP) supplies the part from the outer border of the INL to the outer plexiform layer [1]. Response of the ICP to hypoxia is much greater than the other two plexuses [2]. Paracentral acute middle maculopathy (PAMM) is a nomenclature based on optical coherence tomography (OCT) image characteristics. INL infarction caused by ICP and DCP hypoperfusion is seen as a hyperreflective band in this line. In the etiology of PAMM, reasons such as retinal artery and vein occlusions, hypercoagulability conditions, cataract and vitrectomy surgery and trauma have been implicated [1]. COVID-19 infection causes vascular occlusion by causing endothelial damage or increasing systemic thrombotic factors [3]. Retinal artery occlusion, PAMM and acute macular neuro-retinopathy cases associated with COVID-19 have also been reported in the literature [4–7].

In this case, we aimed to add a new perspective to the ophthalmological involvement of COVID-19 with an atypical PAMM case

presenting with involvement of inner retinal layers associated with COVID-19.

2. Case report

A 41-year-old woman presented with the complaint of gradually decreasing visual acuity in the right eye for three weeks. She had no previous trauma or surgical history. A COVID-19 PCR nasopharyngeal swab test was positive 1 month ago. She described a paracentral scotoma that occurred when the vision decreased. However, she declared that the scotoma improved over time. In the ophthalmological examination, corrected visual acuity was 0.5 in the right eye with the Snellen decimal chart and no pathological appearance with slit lamp examination. In the indirect ophthalmoscopic examination, there was a parafoveal hyperpigmented round lesion in the right eye. Increased vascular tortuosity was observed in indirect ophthalmoscopic retinal examination, wide-field retinal imaging and fundus fluorescein angiography (FFA). Retinal vascular structures were symmetrical. OCT (Hiedelberg Spectralis OCT, Germany) images showed a hyperreflective lesion over the outer plexiform layer, including all parafoveal inner retinal layers next to the foveal pit [Fig. 1a]. No vascular occlusion finding was detected in FFA (Optos200Tx, Marlborough, MA, USA) [Fig. 1b]. There was no absolute scotoma, but decreased sensitivity was present in the visual field

* Corresponding author at: Kayseri State Hospital, Department of Ophthalmology, Kayseri, 38010, Turkey.

E-mail address: drkubrasavasci@gmail.com (H.K. Sonmez).

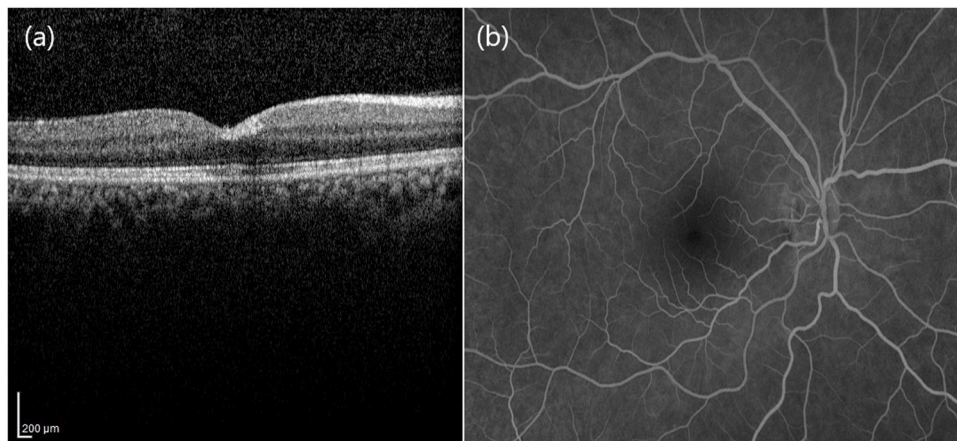


Fig. 1. OCT and fundus fluorescein angiography images of the right eye of the case. (a) OCT image shows a hyperreflective lesion over the outer plexiform layer, including the foveal pit and extending adjacent area. (b) No vascular occlusion on fundus fluorescein angiography.

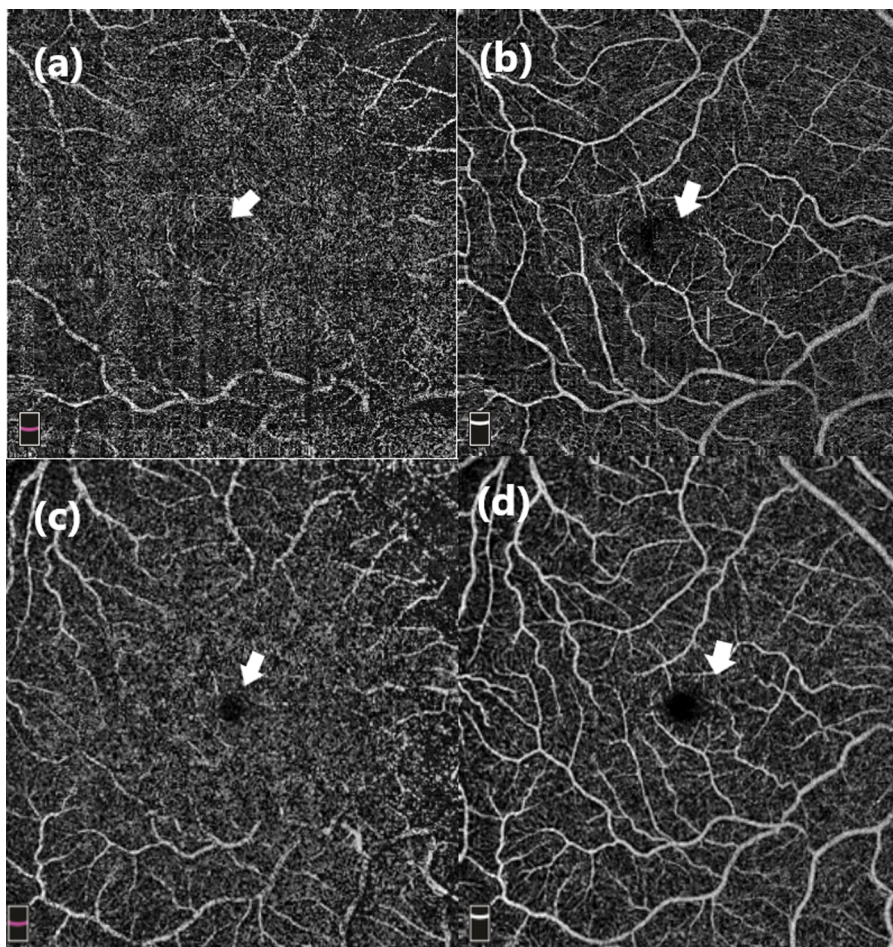


Fig. 2. Superficial and deep capillary plexus imaging of the right eye with OCT-A. (a) Even the avascular zone in the deep capillary plexus cannot be detected due to the shadowing effect of the lesion that was initially observed in the superficial plexus. (b) On the superficial capillary plexus face images, a hyperreflective reflection and FAZ irregularity, which could be an artifact because of the lesion. (c) In the images repeated 1 month later, it is observed that the shadowing effect previously seen in the deep capillary plexus has disappeared and the borders can be defined more clearly. (d) In the images repeated 1 month later, it was observed that the hyperreflective image in the superficial capillary plexus extending into the avascular zone disappeared.

test consistent with the hyperreflective area (Octopus-900, HAAG-STREIT eyesuite static perimetry, V2.2.0). Two multifocal electroretinogram (mfERG) (MetrovisionMon2018F) tests were performed with the patient. At the first visit, there was no amplitude reduction compared to the normal population. However, after 5 weeks when the mfERG was repeated, “a waves” in the paracentral area were decreased compared to the first test but the statistical comparison to the healthy database did not reach the level of $p < 0.05$. To evaluate retinal capillary vascular density, OCT-A (6 × 6 mm) retinal angiography imaging was performed

(RTVueXR AvantiOptovue Inc, Fremont CA, version 2017.1.0.151). When both eyes were compared in OCT-A en-face images covering the SCP, ICP and DCP, disruption was observed in the capillary network, suggesting decreased flow [Fig. 2]. The lesion was at the border of the foveal avascular zone and was seen as a mild hyperreflective reflection in OCT-A images. Arterial hypertension was not detected. The hematology department was consulted in terms of thrombophilia, and Protein C, Protein S, homocysteine and prothrombin time were normal in the examination. In genetic tests for methyltetrahydrofolate reductase

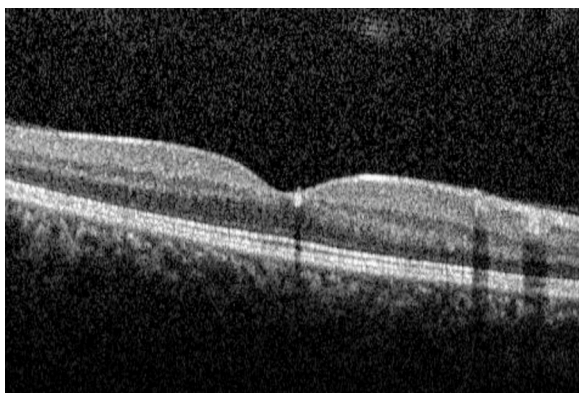


Fig. 3. In OCT imaging 1 month later, it was observed that the lesion had nearly complete resolution and there was no atrophic appearance in the inner layers.

(MTHFR) gene polymorphism, MTHFR C677T was heterozygous and MTHFR A1298C was heterozygous. D-dimer test was performed by the hematology department and the result was 710 $\mu\text{g/L}$, which was elevated. They recommended acetylsalicylic acid (aspirin) daily 1×100 mg lifelong and also recommended low-molecular-weight heparin 1×60 mg daily for 6 months. Visual acuity in the right eye was increased to 0.9 on the Snellen decimal chart in the ophthalmologic examination performed at the first-month follow-up. In OCT imaging, it was observed that the previous lesion had nearly complete resolution and there was no atrophic appearance in the inner layers [Fig. 3]. A slight thickening was observed in the old lesion area only in the outer plexiform layer. When the OCT-A was repeated, it was found that the capillary circulation was significantly improved by comparing it with the previous test.

3. Discussion

PAMM is a disease characterized by obstruction of the ICP and DCP due to deterioration in the microcirculation [1]. We know that patients with COVID-19 infection are susceptible to thrombosis, and in ophthalmology, there have been cases reported that thrombosis is mostly in the retinal arteries and veins [3]. However, in the literature we did not find any atypical PAMM cases involving all capillary plexuses as in our case. In the literature, there are postviral PAMM cases that develop after flu-like symptoms, but the difference from our case was that they appeared to hold the ICP and DCP with diffuse bilateral involvement, which occurred with a Purtscher-like hypopigmented cotton wool spot appearance [8,9]. In our case, we detected a hyperpigmented PAMM appearance involving both SCP, ICP and DCP, causing involvement in unilateral, perifoveal and parafoveal areas, and electrophysiological changes in these areas. Absolute scotoma in visual testing was not detected in the visual field testing, but this might have resulted from the delayed application and the resolving of symptoms for the patient. Although the mild increase in tortuous vascular structures primarily suggests chronic hypertension, the patient's systemic blood pressure values were at normal levels and there was an absence of other signs of hypertensive retinopathy. Therefore, the idea that the structures might have developed secondary to chronic hypertension was dismissed. The MTHFR C677T heterozygous mutation was detected in our case. It is known that hyperhomocysteinemia occurs as a result of disruption of MTHFR enzyme activity by heterozygous mutation. Hyperhomocysteinemia was reported to be associated with diabetic

retinopathy, age-related macular degeneration, glaucoma, retinal degeneration, retinal vein branch occlusion and central retinal artery and vein occlusion [10]. However, in our case, although the MTHFR heterozygous mutation was present, homocysteine levels were within the normal range, and therefore primary thrombophilia was not considered. Although there is evidence in the literature that hyperhomocysteinemia increases the risk of retinal vein occlusion, no relationship has been found between the MTHFR C677T polymorphism and retinal vein occlusion [11,12]. However, this is still a controversial topic. Although a typical PAMM appearance causes infarction in the ICP and DCP area, the location of the lesion and its failure to progress to the outer layers of the retina have distanced us from a diagnosis of type 2 acute macular neuroretinopathy [13].

In summary, in this report, a case of atypical PAMM with SCP, ICP and DCP involvement was considered that furthermore resolved spontaneously. Although not accompanied by hyperhomocysteinemia, the MTHFR C677T mutation and higher D-dimer levels led us to antithrombotic treatment. This case showed that it should be kept in mind that retinal involvement of COVID-19 infection could present in different ways.

Declaration of Competing Interest

None.

Funding

None.

References

- [1] J. Scharf, K.B. Freund, S. Sadda, et al., Paracentral acute middle maculopathy and the organization of the retinal capillary plexuses, *Prog. Retin. Eye Res.* (2020), 100884.
- [2] C. Caprara, M. Thiersch, C. Lange, et al., HIF1A is essential for the development of the intermediate plexus of the retinal vasculature, *Invest. Ophthalmol. Vis. Sci.* 52 (5) (2011) 2109–2117.
- [3] A. Invernizzi, A. Torre, S. Parrulli, et al., Retinal findings in patients with COVID-19: results from the SERPICO-19 study, *EClinicalMedicine* 27 (2020), 100550.
- [4] N. Turedi, B. Onal Gunay, Paracentral acute middle maculopathy in the setting of central retinal artery occlusion following COVID-19 diagnosis, *Eur. J. Ophthalmol.* (2021 Feb), 1120672121995347.
- [5] P. Gascon, A. Briantais, E. Bertrand, et al., Covid-19-associated retinopathy: a case report, *Ocul. Immunol. Inflamm.* 28 (8) (2020) 1293–1297.
- [6] J. Virgo, M. Mohamed, Paracentral acute middle maculopathy and acute macular neuroretinopathy following SARS-CoV-2 infection, *Eye (Lond)* 34 (12) (2020) 2352–2353.
- [7] M.N. Aidar, T.M. Gomes, M.Z.H. de Almeida, et al., Low visual acuity due to acute macular neuroretinopathy associated with COVID-19: a case report, *Am. J. Case Rep.* 30 (22) (2021), e931169.
- [8] A. Shahlaee, J. Sridhar, E. Rahimy, et al., Paracentral acute middle maculopathy associated with postviral purtscher-like retinopathy, *Retin. Cases Brief Rep.* 13 (1) (2019) 50–53.
- [9] Mohammad Reza Hassanpoor Niyousha, et al., Simultaneous paracentral acute middle maculopathy and purtscher-like retinopathy after acute febrile illness, *Can. J. Ophthalmol.* 53 (2018) e184–e186.
- [10] S. Markand, A. Saul, P. Roon, et al., Retinal ganglion cell loss and mild vasculopathy in methylene tetrahydrofolate reductase (Mthfr)-deficient mice: a model of mild hyperhomocysteinemia, *Invest. Ophthalmol. Vis. Sci.* 56 (4) (2015) 2684–2695.
- [11] D. Li, M. Zhou, X. Peng, et al., Homocysteine, methylenetetrahydrofolate reductase C677T polymorphism, and risk of retinal vein occlusion: an updated meta-analysis, *BMC Ophthalmol.* 27 (14) (2014) 147.
- [12] M. Marques, F. Alves, M. Leitão, et al., Methylenetetrahydrofolate reductase polymorphisms as risk factors for retinal venous occlusive disease: a literature review, *Eur. J. Ophthalmol.* (2021 Mar), 11206721211000647.
- [13] K.V. Bhavsar, S. Lin, E. Rahimy, et al., Acute macular neuroretinopathy: a comprehensive review of the literature, *Surv. Ophthalmol.* 61 (5) (2016) 538–565.