



CASE REPORT

Root canal treatment of a three-rooted maxillary second premolar



Chia-Shuo Yeh^a, Wen-Bing Wong^a, Wayne Yu-Wei Kan^a,
Ming-Gen Tu^{a,b*}

^a Department of Dentistry, China Medical University Hospital, Taichung, Taiwan

^b School of Dentistry, College of Medicine, China Medical University, Taichung, Taiwan

Received 1 January 2011; Final revision received 1 February 2011

Available online 19 April 2013

KEYWORDS

endodontics;
maxillary second
premolar;
root canal
morphology;
three-rooted
maxillary premolar

Abstract Successful root canal treatment relies on correct access cavity preparation, sufficient cleaning, adequate shaping, and complete obturation. Prior to these, location of all existing canals in the tooth plays an important part in the initial treatment procedures. While most teeth have a normal morphology, we should recognize that variations do exist. Normal maxillary second premolars have one or two root canals. Maxillary second premolars are less likely to have three canals. To date, only a few cases of maxillary second premolars with three roots (and three canals) have been reported in the literature. This case presentation reports a 20-year-old female who had three root canals in a maxillary second premolar, which underwent endodontic treatment at a teaching hospital in Taiwan.

© 2017 Association for Dental Sciences of the Republic of China. Publishing services by Elsevier B.V. This is an open access article under the CC BY-NC-ND license (<http://creativecommons.org/licenses/by-nc-nd/4.0/>).

Introduction

A thorough understanding of the root canal morphology and correct evaluation of preoperative radiographs are

essential parts of endodontic therapy. As many cases of endodontic failure are due to missed canals,¹ clinicians should be aware of all types of variations that may exist in the root canal system of each tooth.

Morphological variations in the root canal system of maxillary premolars, mostly *in vitro*, have been reported in a number of studies.^{2–4} The incidence of maxillary first premolars having three roots ranges from 0% to 6%,³ generally with one canal in each root. Maxillary second premolars are less likely to have three canals. To date, only a few cases of

* Corresponding author. Department of Dentistry, China Medical University Hospital, 2 Yu-De Road, North District, Taichung 404, Taiwan.

E-mail address: mgtu@mail.cmu.edu.tw (M.-G. Tu).

maxillary second premolars with three roots (and three canals) have been reported in the literature.^{1,2,5-9}

The purpose of this report was to discuss a case with three root canals in the right maxillary second premolar, which received endodontic treatment at a teaching hospital in Taichung, Taiwan.

Case report

A 20-year-old female patient was referred by her general dentist to the Department of Endodontics, China Medical University Hospital, Taichung, Taiwan, for endodontic treatment of her right maxillary second premolar. The patient's chief complaint was mild lingering pain after drinking cold water. There was no specific finding during the extra-oral examination. At the initial examination, a radiolucent area was noted underneath the distal aspect of an existing Class II amalgam restoration in a periapical radiograph of that tooth, which was suspected to be a recurrent carious lesion. No periradicular lesions or widening of the periodontal ligament spaces were found to be associated with the tooth (Fig. 1). Besides reproducing the lingering pain using a vitality thermal test, no other abnormalities of palpation, percussion, probing depth, or mobility were seen. Clinically, carious pulp exposure was detected following removal of the amalgam restoration and underlying soft dentine. Our diagnosis was symptomatic irreversible pulpitis with normal periapical tissue. This tooth was to be restored by a crown after complete root canal treatment.

The tooth was isolated with a rubber dam after receiving infiltration with local anesthesia (2% lidocaine with 1:10⁵ epinephrine). The access cavity was prepared with a number 4 round carbide bur, and an ovoid outline of the pulp chamber was established. Two canal orifices were detected with a DG16 explorer. A number 5 reamer (Profile Series 29 hand instrument, equal to ISO 27.9, Dentsply Tulsa Dental, PA, USA) was used to remove the pulp tissue and a number 1 K-file (Profile Series 29 hand instrument, equal to ISO 10) was introduced into the palatal and buccal canals to set the patency and initial working lengths with the aid of an apex locator (Root ZX, J. Morita USA, Irvine,

CA, USA). Canal enlargement and debridement were completed with the reamers and files, accompanied by Gates-Glidden drills (Blackwell Supplies Ltd, Basildon, Essex, UK) and Profile GT file (0.06 taper, number 20). Sodium hypochlorite (2.5%) and 17% ethylenediaminetetraacetic acid were used for canal irrigation and debris removal. As a precurved number 4 file (Profile Series 29 hand instrument, equal to ISO 21.6) was bound during final patency checking in the buccal canal, a third canal was discovered and determined to be a distobuccal canal. A final working-length periapical radiograph showed all three canals located by files (Fig. 2).

All three root canals of this maxillary second premolar were obturated by warm gutta-percha vertical compaction with Gutta Percha and Pulp Canal Sealer (EWT, SybronEndo, Orange, CA, USA), followed by temporary restoration of the coronal portion of the pulp chamber with Caviton (GC United Kingdom, Newport Pagnell, Buckinghamshire, UK). A postoperative periapical radiograph showed complete filling of the three main canals and the lateral canal (Fig. 3).

Following the completion of endodontic treatment of the right maxillary second premolar, the patient, who felt no obvious symptoms or signs, was referred back to her general dentist for later prosthetic treatment. According to her general dentist, the tooth was free of palpation pain, percussion pain, and biting pain after the prosthetic procedure.

Discussion

Complete canal debridement and obturation are essential to the success of endodontic treatment. Missing a canal may lead to treatment failure. Clinicians must therefore recognize the anatomical morphology of a normal root canal system, as well as any variations that may exist.

According to Krasner and Rankow,¹⁰ more than 95% of teeth conformed to their nine guidelines, or "laws", of pulp chamber anatomy, while other teeth may have some kind of anatomical variations, e.g., C-shaped canals of lower mandibular molars.

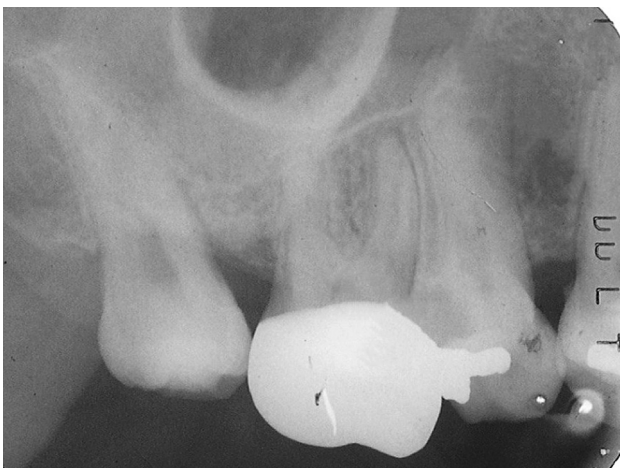


Figure 1 Initial film.

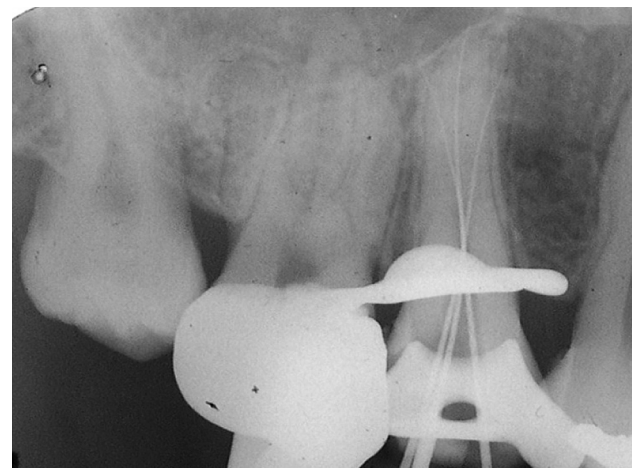


Figure 2 A three-root canal was found.

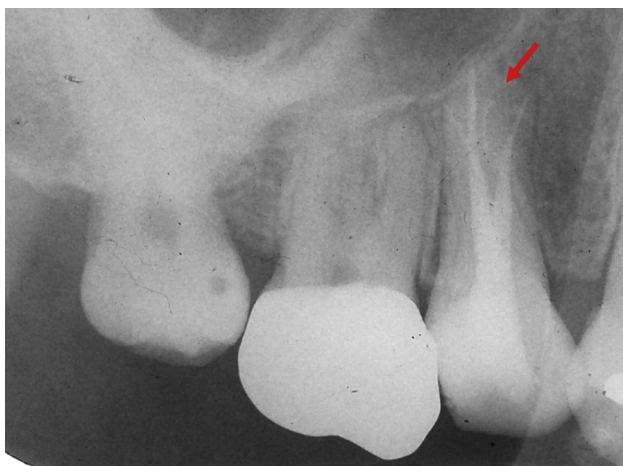


Figure 3 Postoperative periapical radiograph showing complete filling of the three main canals and lateral canal (arrow) by the warm gutta-percha vertical compaction technique.

Maxillary second premolars generally have one or two canals, while some may have a third canal that is regarded as a variation. Three-rooted maxillary premolars are also nicknamed “ridiculous premolars” or “small molars” that have two buccal roots (mesiobuccal and distobuccal) and one palatal root, similar to maxillary molars.⁸

While the occurrence of three roots in a maxillary second premolar is rare, an increased number of clinical cases have been reported during the past decade.^{1,2,5–9} This is due to increased demands for tooth preservation, advances in dental technology such as microscopes and digital radiography, and broadened knowledge of endodontics. Third canals in maxillary second premolars are rarely reported; only being mentioned in a number of *in vitro* studies, or clinically on postobturation radiographs and during apicoectomy procedures with direct vision.

According to Bellizzi,¹¹ the root morphology of maxillary second premolars can be divided into three groups: (1) three fused roots or fused buccal roots and a partially fused or separated palatal root; (2) buccal roots fused at the middle or apical third, and with a separated or partially fused palatal root; and (3) all three roots separated at the cervical third. In this case, the root canal system was Group 2.

Moreover, periapical radiographs with angle variations may facilitate root canal detection in Group 1 cases, while those without angle variation favor the other two groups.

As conventional radiographs are two-dimensional images, the use of a horizontal angle variation technique may allow the clinician to determine the three-dimensional root canal anatomy. In straight-on radiographs of maxillary premolars, Sieraski et al¹² suggested that when the mesiodistal width of the mid-root image is equal to or greater than the mesiodistal width of the crown, the tooth most likely has three roots (Fig. 1).

There were no differences in success rates between cold lateral compaction and warm gutta-percha vertical

compaction techniques.¹³ Cold lateral compaction is the most commonly practiced filling technique. Warm gutta-percha vertical condensation was promoted by Herbert Schilder. Three-dimensional obturation seals every portal of the root canal system tightly with filling material, including the lateral canals and apical ramification (Fig. 3).

In reviewing the literature,^{1,2,5–9} the incidence of maxillary second premolars with three root canals seems to be distributed among particular regions of the world: with most being in South America (five cases reported in Brazil), followed by the Middle East (three in Saudi Arabia and two in Turkey), and southern China (one in Hong Kong and one, the first case, in Taiwan). It would be interesting to consider whether there were any possible contributing factors to this, such as inheritance patterns or ethnic origins.

A correct diagnosis and careful clinical and radiographic interpretation are the first requirements for success in endodontic therapy. In addition to having a sound knowledge of the normal root canal anatomy, the clinician should bear in mind that possible variations can exist in each tooth and should use additional caution.

References

1. Ferreira CM, de Moraes IG, Bernardineli N. Three-rooted maxillary second premolar. *J Endod* 2000;26:105–6.
2. Low D. Unusual maxillary second premolar morphology: a case report. *Quintess Int* 2001;32:626–8.
3. Kartal N, Ozcelik B, Climilli H. Root canal morphology of maxillary premolars. *J Endod* 1998;24:417–9.
4. Pecora JD, Sousa Neto MD, Saquy PC, Woelfel JB. In vitro study of root canal anatomy of maxillary second premolars. *Braz Dent J* 1992;3:81–5.
5. Kustarci A, Kürsat ER, Akpınar KE. Root canal treatment of maxillary second premolar with three roots and three canals: clinical cases. *Braz J Oral Sci* 2007;6:1411–4.
6. Pattanshetti N, Kandari AM, Gaidhane MP. Maxillary second premolar with three canals. Report of three cases. *Saudi Dent J* 2007;19:176–9.
7. Soares JA, Leonardo RT. Root canal treatment of three-rooted maxillary first and second premolars – a case report. *Int Endod J* 2003;36:705–10.
8. Barros DB, Tanomaru JMG, Tanomaru-Filho M. Root canal treatment of three-rooted maxillary second premolars: report of four cases. *Aust Endod J* 2009;35:73–7.
9. de Almeida-Gomes F, de Sousa BC, de Souza FD, dos Santos RA, Maniglia-Ferreira C. Unusual anatomy of maxillary second premolars. *Eur J Dent* 2009;3:145–9.
10. Krasner P, Rankow HJ. Anatomy of the pulp-chamber floor. *J Endod* 2004;30:5–17.
11. Bellizzi R, Hartwell G. Radiographic evaluation of root canal anatomy of in vivo endodontically treated maxillary premolars. *J Endod* 1985;11:37–9.
12. Sieraski SM, Taylor GN, Kohn RA. Identification and endodontic management of three-canal maxillary premolars. *J Endod* 1989;15:29–32.
13. Whitworth J. Methods of filling root canals: principles and practices. *Endo Topics* 2005;12:2–24.