



Roberts syndrome with tetraphocomelia: A case report and literature review

SAGE Open Medical Case Reports
Volume 10: 1–5
© The Author(s) 2022
Article reuse guidelines:
sagepub.com/journals-permissions
DOI: 10.1177/2050313X221094077
journals.sagepub.com/home/sco



Boniface Chukwuneme Okpala^{1,2,3} , **Sylvia Tochukwu Echendu³**,
Joseph Ifeanyichukwu Ikechebelu^{1,2,3}, **George Uchenna Eleje^{1,2}** ,
Ngozi Nneka Joe-Ikechebelu^{3,4}, **Louis Anayo Nwajiaku²**,
Cyril Emeka Nwachukwu^{5,6}, **Emeka Philip Igbodike⁷**,
Mark Chinedu Nnoruka³, **Augusta Nkiruka Okpala⁸**,
Chukwuemeka Jude Ofojebe^{1,2} and **Osita Samuel Umeononihu^{1,2}**

Abstract

Roberts syndrome is a rare genetic disorder characterized by symmetrical reductive limb malformation and craniofacial abnormalities. It is caused by mutation in the “Establishment of cohesion I homolog 2” genes, resulting in the loss of acetyltransferase activities and manifesting as premature centromere separation in metaphase chromosomes. The affected individual grows slowly during pregnancy and after birth with associated mild to severe intellectual impairment. We present a 35-year-old multiparous Nigerian lady who had emergency cesarean section at 35 weeks of gestation following abruptio placentae with a live fetus. The baby had poor Apgar score at birth and died shortly afterward. Tetraphocomelia was detected on prenatal ultrasound done at about 24 weeks of gestation with other features sonographically normal. However, clinical diagnosis of severe variant of Roberts syndrome with tetraphocomelia, growth restriction, and craniofacial abnormalities were noted at birth. This case exhibits a very rare variant of Roberts syndrome with tetraphocomelia, intrauterine growth restriction, and craniofacial abnormalities. It also highlights the crucial role of detailed clinical examination and the inherent challenges in making cytogenetic diagnosis in low-income countries.

Keywords

Roberts syndrome, skeletal malformation, pseudothalidomide syndrome, *ESCO2* gene

Date received: 16 August 2021; accepted: 25 March 2022

Introduction

Roberts syndrome is a rare genetic disorder characterized by prenatal and postnatal growth retardation, limbs, and craniofacial defects.^{1,2} The limb defects are similar to those seen in thalidomide embryopathy; hence, the disorder is also known as pseudothalidomide syndrome. The other associated anomalies include cardiac and renal malformations.³ It is an autosomal recessive disorder and expression is diverse, varying greatly within families.

John Roberts in 1919 first described the disease in a case of a male neonate with bilateral cleft lip and tetraphocomelia. Later, Apeltz⁴ in 1964 described it as a syndrome. In 1969, Herman described it as pseudothalidomide syndrome or phocomelia syndrome because of the presence of shortened limbs.⁵ Only about 150 cases have been described in literature in the world over.^{4,6,7}

¹Department of Obstetrics and Gynaecology, Nnamdi Azikiwe University, Awka, Nigeria

²Department of Obstetrics and Gynaecology, Nnamdi Azikiwe University Teaching Hospital, Nnewi, Nigeria

³Life International Hospital, Awka, Nigeria

⁴Department of Community Medicine, Chukwuemeka Odumegwu Ojukwu University Teaching Hospital, Awka, Nigeria

⁵Department of Anaesthesia, Nnamdi Azikiwe University, Awka, Nigeria

⁶Department of Anaesthesia, Nnamdi Azikiwe University Teaching Hospital, Nnewi, Nigeria

⁷Department of Obstetrics and Gynecology, St Georges Hospital Memorial Centre, Lagos, Nigeria

⁸Department of Family Medicine, Nnamdi Azikiwe University Teaching Hospital, Nnewi, Nigeria

Corresponding Author:

Boniface Chukwuneme Okpala, Department of Obstetrics and Gynaecology, Nnamdi Azikiwe University, Awka, Nigeria.
Emails: bc.okpala@unizik.edu.ng; biastalee@gmail.com



Roberts syndrome occurs equally in both males and females, and is common among closely related parents (parental consanguinity). The etiologies are not known but have been related to parental consanguinity with cytogenetic premature centromere separation (PCS) present in most of the cases.⁷ This disorder follows mutation in the “Establishment of cohesion 1 homolog 2” (*ESCO2*) gene on the short arm of chromosome 8, which encodes a protein responsible for regulating sister chromatid cohesion.^{5,8–10} Aneuploidy with random chromosome loss and micronuclei and/or nuclear lobulation in the interphase cells are also characteristics of this syndrome.¹⁰

An experienced sonographer can suspect Roberts syndrome with prenatal ultrasound¹¹ where structural defects can be well defined, buttressing the importance of routine anomaly ultrasonography between 18 and 22 weeks of gestation, especially in low-income countries where postnatal genetic diagnosis is rare. Postnatal cytogenetic testing of the biopsied tissue confirms the diagnosis. However, in low-income countries, clinical diagnosis can be made where cytogenetic diagnosis is not feasible.

Prognosis depends on the severity of structural malformations and involvement of other organs.¹² Infants with a severe form of Roberts syndrome are often stillborn or die shortly after birth. Mildly affected individuals may live into adulthood.^{13,14} Roberts-SC phocomelia represents the milder form of Roberts syndrome and typically survive to adulthood.¹³ The majority of infants with Roberts syndrome die due to cardiac, renal anomalies, and neonatal infective complications.

The authors report a case of severe variant of Roberts syndrome with tetrachomelia, growth restriction, and craniofacial abnormalities and the challenges in making a definitive cytogenetic diagnosis in low- or middle-income setting.

Case presentation

A 35-year-old multiparous Nigerian lady had an emergency cesarean section at 35 weeks of gestation following a diagnosis of abruptio placentae with a live fetus. The baby did not cry immediately after delivery and had Apgar¹⁵ scores of 5 at both 1 and 5 min. The baby was supported with intranasal oxygen and was quickly transferred to neonatal intensive care unit (NICU) of the hospital. The baby died 10 min after admission to the NICU. Examination findings showed a small for age baby who weighed 1.1 kg without chest expansion. There was associated microbrachycephaly with an occipitofrontal circumference of 24 cm. The abdominal girth was 23 cm and length was 34 cm. The baby also had oligodactyly with thumb aplasia, micrognathia, malar hypoplasia, down-slanting palpebral fissures, ocular hypertelorism, broad nose, dysplastic low set ears, and absence of the four limbs (tetrachomelia). There were also omphalocele minor, absence of genitalia, imperforate anus, and hemangiomas on the forehead and back. The heart sounds

were present but remote and barely countable for few minutes. The renal and cardiac involvements were not ascertained as baby died shortly after birth. The parents did not consent for an autopsy or X-ray to be performed on the baby to ascertain other internal organ involvement.

She conceived spontaneously and started her antenatal visit to the hospital at 6 weeks of gestation, and she was regular with her visits. Her booking investigations were normal. There was no history of alcohol intake, smoking, or any other non-prescribed drugs. There was no exposure to irradiation. The mother was not a known diabetic, and there was no history of consanguinity. Her first three pregnancies were normal without any congenital malformation, while the pregnancy that preceded the case reported above was terminated at 20 weeks due to gross malformation incompatible with life (anencephaly).

Tetrachomelia without any other abnormality was detected on ultrasound done at about 24 weeks of gestation, though previous ultrasound scans done earlier missed this defect. Treatment options were discussed with the mother, but she decided to carry the pregnancy to term. She had premature rupture of membranes and abruptio placentae at 35 weeks of gestation with fetus alive, and this prompted the delivery of the baby via emergency cesarean section.

A diagnosis of Roberts syndrome was made clinically based on the presence of tetrachomelia, low birth weight, and presence of other craniofacial abnormalities. Autopsy and X-ray of the spine were not done as the parents declined consent. Also, cytogenetic testing service was not available in the hospital and very expensive to be undertaken.

Discussion

Roberts syndrome is a rare genetic disease with autosomal recessive inheritance pattern, leading to multiple congenital malformation. A child must inherit two copies of the defective gene from both parents since it is autosomal recessive before manifesting with Roberts syndrome. In a normal cell division, each chromosome is copied and then attached to its newly formed copy at the centromere.¹⁶ During the cell division in Roberts syndrome, the copies are not attached at the centromere. Consequently, the chromosomes are not properly aligned with resultant slowing or no division of cells. The new cells typically will have too many or too few chromosomes. The odd number of chromosomes causes defective cells to die leading to malformations associated with Roberts syndrome. It occurs equally in both males and females with varying severity.

Affected individuals present with bilateral symmetrical tetrachomelia with the upper limb more affected than lower limb.¹² There are also intrauterine growth restriction, hypomelia, oligodactyly, thumb aplasia, syndactyly, micrognathia, microbrachycephaly, malar hypoplasia, down-slanting palpebral fissures, ocular hypertelorism, big nose, and hemangiomas. All these features were present in our index

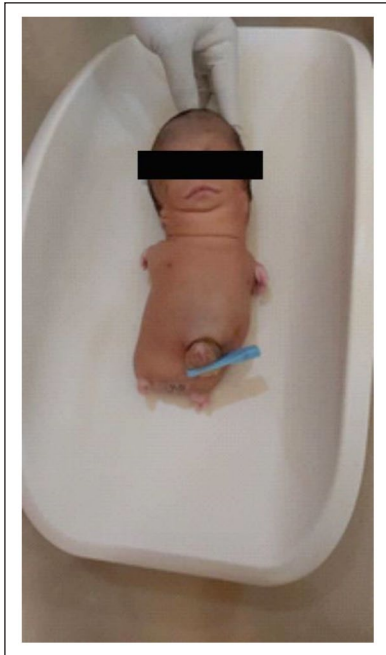

Figure 1. Ventral view of the patient with tetraphocomelia.

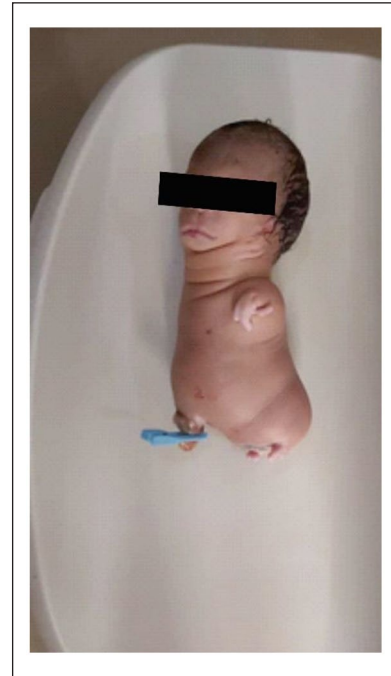

Figure 2. Lateral view of the patient.

patient (Figures 1–3). They also present with clinodactyly, elbow/knee flexion contractures, cleft lip and palate, premaxillary protrusion, exophthalmos, corneal clouding, hypoplastic nasal alae, beaked nose, encephalocele, and intellectual disability.^{17,18} The mortality rate is high among severely affected individuals, as the index case that died shortly after birth was severely affected. However, individuals that are mildly affected sometimes grow into adulthood.^{13,14} Other associations include abnormalities of the heart—atrial septal defect, ventricular septal defect, and patent ductus arteriosus. They also present with polycystic or horseshoe kidneys. They also present with genital abnormalities such as enlarged penis, cryptorchidism, and enlarged clitoris. In the index case presented, the external genitalia were not formed. Sparse scalp hair and cranial nerve palsies are also features seen in Roberts syndrome.¹²

The diagnosis of Roberts syndrome can be made clinically in individuals with characteristic intrauterine growth restriction, limb malformation, and craniofacial abnormalities. However, the gold standard for diagnosis is cytogenetic testing.¹⁹ The diagnosis ESCO2 spectrum disorder is established in a proband with suggestive clinical findings by identification of either biallelic pathogenic variants in ESCO2 by molecular genetic testing or PCS by cytogenetic testing.²⁰ Cytogenetic preparations are stained by Giemsa or C-banding techniques, which show PCS and their centromeres separate during metaphase rather than anaphase. The second chromosomal abnormality is heterochromatin repulsion and chromosome with heterochromatin repulsion experience separation of heterochromatin regions during metaphase.

Both abnormalities give the chromosome “a railroad track” appearance.^{6,8–10} Other findings which may be found on the chromosome in Roberts syndrome include aneuploidy, micronucleation, and multilobulated nuclei.³

The differential diagnosis of Roberts syndrome include mosaic variegated aneuploidy syndrome (OMIM PS257300), Fanconi anemia, Holt–Oram syndrome, Cornelia de Lange syndrome, Baller–Gerold syndrome, Tetra-Amelia Syndrome 1, thrombocytopenia-absent radius (TAR) syndrome, Zimmer phocomelia, splenogonadal fusion with limb defects and micrognathia, DK phocomelia syndrome (Von Voss Cherstvoy syndrome), and thalidomide embryopathy.^{8–10} The other differential diagnosis includes Bartsocas–Papas syndrome and acrofacial dysostosis, particularly Nager type. Some features, such as popliteal and other pterygia and absent penis and pinnae, are suggestive of Bartsocas–Papas syndrome, but the encephalocele, absent limb bones, the absence of syndactyly, and the well-formed digits (a second plate in the original description shows well-formed nails on both hands and feet) are not features that would be expected in this syndrome. Severe Nager acrofacial dysostosis can present with similar features, but encephalocele and pterygia would not be expected. The most probable diagnosis is that of Roberts syndrome, though there are some unusual features, such as the prominent pterygia and absent external genitalia. Roberts and SC phocomelia syndrome are generally regarded as the same nosological entity though the absence of cleft palate in the SC syndrome may be a difference. Roberts syndrome has been interpreted as a human mitotic mutation syndrome that leads to a wide spectrum of

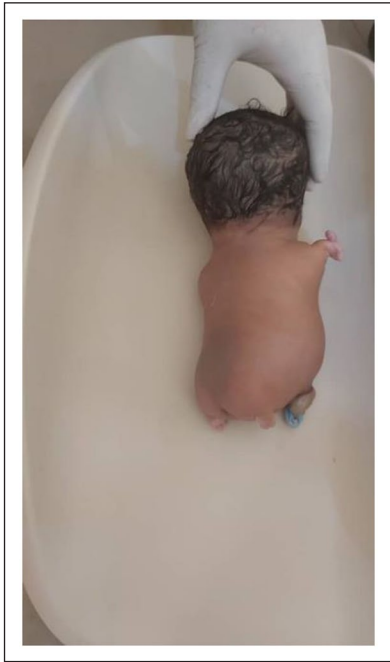


Figure 3. Dorsal view of the patient.

secondary developmental defects.^{6–10} The phenotype is highly variable.

Prenatal testing and preimplantation genetic testing are important in the management of Roberts syndrome. This has become imperative because the parents of an affected child are obligate heterozygotes (i.e. presumed to be carriers of one ESCO2 pathogenic variant based on family history). Molecular genetic testing is recommended for the parents of a proband to confirm that each parent is heterozygous for an ESCO2 pathogenic variant and allow reliable recurrence risk assessment. Although a *de novo* pathogenic variant has not been reported in ESCO2 spectrum disorder to date, *de novo* variants are known to occur at a low but appreciable rate in autosomal recessive disorders. Heterozygotes (carriers) are asymptomatic and are not at risk of developing the disorder.

Roberts syndrome can be suspected prenatally by observation of characteristic Roberts syndrome anomalies at ultrasonography^{1,11} and confirmed by cytogenetic testing.¹ A high index of suspicion is, however, needed, as this condition is rare. In our index case, prenatal suspicion was missed despite ultrasound diagnosis of tetraphocomelia. This buttress further the needs for detailed anatomy scan by a well-trained sonographer and high index of suspicions. The diagnosis was made in our index case based on clinical features at birth, and cytogenetic testing was not done due to the high cost of the test and only few laboratories can perform cytogenetic tests in our low-income setting.

Treatment for survivors is a multidisciplinary approach involving the plastic surgeon, pediatrician, orthopedics, physiotherapist, speech therapist, cardiologist, nephrologist,

eye specialist, social workers, and genetic counselors. The aim of treatment in mild forms is to improve the quality of life of children affected with this syndrome. The possible corrections include correction of cleft lip and palate, surgical correction of limb abnormalities, and management of cognitive disabilities.^{12,17}

The prognosis depends on the severity of the degree of malformation and other organ involvement.¹² Our index patient had severe malformation and died shortly after birth. It is probably the first reported case of Roberts syndrome in Nigeria.

Conclusion

This case is a very rare condition of Roberts syndrome with tetraphocomelia, intrauterine growth restriction (IUGR), and craniofacial abnormalities. Currently, there is no national guideline on how to manage this disorder. Proper and prompt diagnosis can encourage accurate genetic counseling—educate mothers on recurrence risks in siblings and possible prenatal diagnosis. Every woman with previous history of a baby with Roberts syndrome or previous history of structural abnormalities in the fetus should undergo genetic counseling and possibly do preimplantation genetic diagnosis (PGD) when feasible in her subsequent pregnancies. Termination of pregnancy may be offered if a severe form of the syndrome is detected before the age of viability. Routine anomaly ultrasound should be offered to all women as a basic prenatal testing between 18 and 22 weeks of gestation and can be extended to 24 weeks. Early involvement of the multidisciplinary team is the key for a favorable outcome in mild cases.

Acknowledgements

We hereby acknowledge the theater nurse and the entire staff of neonatal intensive care unit of Life International Hospital, Awka, Anambra State, Nigeria, for their immense support.

Author contributions

All authors contributed to the report, discussion, and conclusion of this work.

Declaration of conflicting interests

The author(s) declared no potential conflicts of interest with respect to the research, authorship, and/or publication of this article.

Funding

The author(s) received no financial support for the research, authorship, and/or publication of this article.

Ethical approval

Our institution does not require ethical approval for reporting individual cases or case series.

Informed consent

A written informed consent was obtained from the parents of the patient for the anonymized information of the patient to be published in this article. A copy of the written consent is available for review by the Editor-in-Chief of the journal.

ORCID iDs

Boniface Chukwuneme Okpala  <https://orcid.org/0000-0003-1693-373X>

George Uchenna Eleje  <https://orcid.org/0000-0002-0390-2152>

References

1. Ayaz R, Göktaş E and Balasar M. A case of Roberts syndrome: its ultrasonographic characteristics and genetic diagnosis. *Perinatal J* 2020; 28(3): 212–216.
2. Borjas-Lucio CG, Briones-Bernal BL, Gutiérrez HT, et al. Roberts syndrome—an isolated case. *Medicina Universitaria* 2017; 19(75): 98–99.
3. Jab EW, Tuck-Muller CM, Cusano R, et al. Studies of mitotic and centromeric abnormalities in Roberts syndrome: implications for a defect in mitotic mechanisms. *Chromosome* 1991; 100: 251–252.
4. Murthy J, Dewan M and Hussain A. Roberts-SC syndrome, a rare syndrome and cleft palate repair. *Indian J Plast Surg* 2008; 41: 222–225.
5. Temtany SA, Ismail S and Helmy NA. Roberts syndrome: study of four new Egyptian cases with comparison of clinical and cytogenetic findings. *Genet Couns* 2006; 17: 11–13.
6. Vega H, Waisfisz Q, Gordillo M, et al. Roberts syndrome is caused by mutations in ESCO2, a human homolog of yeast ECO1 that is essential for the establishment of sister chromatid cohesion. *Nat Genet* 2005; 37: 468–470.
7. Olney RS, Hoyme HE, Roche F, et al. Limb/pelvis hypoplasia/aplasia with skull defect [Schinzel phocomelia]: distinctive features and prenatal detection. *Am J Med Genet* 2001; 103: 295–301.
8. Kaissib AI, Robert C, Klaushofer K, et al. Femoral-tibial-synostosis in a child with Roberts syndrome (pseudothalidomide): a case report. *Cases J* 2008; 1: 109.
9. Abbas R, Waqar S, Ahmad TM, et al. A child with Roberts syndrome. *J Coll Physicians Surg Pak* 2011; 7: 431–433.
10. Gordillo M, Vega H, Trainer AH, et al. The molecular mechanism underlying Roberts syndrome involves loss of ESCO2 acetyltransferase activity. *Hum Mol Genet* 2008; 17(14): 2172–2180.
11. Socolov RV, Andreescu NI, Haliciu AM, et al. Intrapartum diagnostic of Roberts syndrome—case presentation. *Rom J Morphol Embryol* 2015; 56(2): 585–588.
12. Gordillo M, Vega H and Jabs EW. Roberts syndrome. *GeneReviews*, 2009, <http://www.ncbi.nlm.nih.gov/books/NBK1153/>(accessed 17 June 2021).
13. Goh ES, Li C, Horsburgh S, et al. The Roberts syndrome/SC phocomelia spectrum—a case report of an adult with review of the literature. *Am J Med Genet A* 2010; 152A(2): 472–478.
14. Sezer A, Kayhan G, Zenker M, et al. Hypopigmented patches in Roberts/SC phocomelia syndrome occur via aneuploidy susceptibility. *Eur J Med Genet* 2019; 62(12): 103608.
15. American Academy of Pediatrics; Committee on Fetus Newborn; American College of Obstetricians Gynecologists; Committee on Obstetric Practice. The Apgar score. *Adv Neonatal Care* 2006; 6(4): 220–223.
16. Mfarej MG and Skibbens RV. An ever-changing landscape in Roberts syndrome biology: implications for macromolecular damage. *PLoS Genet* 2020; 16(12): e1009219.
17. Holden KR, Jab EW and Sponsellar PD. Roberts/pseudothalidomide syndrome and normal intelligence: approaches to diagnosis and management. *Dev Med Child Neurol* 2008; 34: 534–539.
18. Allingham D and Tomkins D. Heterogeneity in Roberts syndrome. *Am J Med Genet* 1995; 55: 188–194.
19. Malla TM, Pandith AA, Dar FA, et al. Cytogenetic diagnosis of Roberts SC phocomelia syndrome: first report from Kashmir. *Egypt J Med Human Genet* 2016; 17: 137–140.
20. Vega H, Gordillo M and Jabs EW. ESCO2 spectrum disorder. In: Adam MP, Ardinger HH, Pagon RA, et al (eds) *GeneReviews*®. Seattle, WA: University of Washington, Seattle, 2006, 1993–2022.