

Received: 2019.11.15

Accepted: 2020.01.29

Available online: 2020.04.01

Published: 2020.05.17

# Successful Transition from Plasma Exchange to Eculizumab in Acetylcholine Receptor Antibody- and Muscle-Specific Kinase (MuSK) Antibody-Negative Myasthenia Gravis: A Case Report

## Authors' Contribution:

Study Design A  
Data Collection B  
Statistical Analysis C  
Data Interpretation D  
Manuscript Preparation E  
Literature Search F  
Funds Collection G

BDE **Gregory T. Greenwood**BDE **Zachary Lynch**

Nephrology Section, Forsyth Medical Center, Winston-Salem, NC, U.S.A.

**Corresponding Author:** Gregory T. Greenwood, e-mail: [gtgreen@wakehealth.edu](mailto:gtgreen@wakehealth.edu)**Conflict of interest:** Dr. Gregory T. Greenwood has served as a paid consultant for Alexion Pharmaceuticals. Mr. Zachary Lynch has no conflicts of interest**Source of support:** Editorial support was provided by Dr. Nicky French of Anthemis Consulting Ltd., funded by Alexion Pharmaceuticals, Inc.

**Patient:** Female, 67-year-old  
**Final Diagnosis:** Generalized myasthenia gravis  
**Symptoms:** Muscle weakness • slurred speech • ptosis  
**Medication:** Eculizumab • pyridostigmine • azathioprine • mycophenolate mofetil • onabotulinum toxin A • IVIG  
**Clinical Procedure:** Plasma exchange  
**Specialty:** Neurology

**Objective:** Unusual or unexpected effect of treatment**Background:** The effectiveness of eculizumab (a terminal complement inhibitor) in acetylcholine receptor (AChR) antibody-negative generalized myasthenia gravis (gMG) is unknown.**Case Report:** A female patient was diagnosed with AChR-antibody and muscle-specific kinase (MuSK) antibody-negative gMG in March 2016. In January 2017, the patient was referred for plasma exchange (PLEX) because of continuing symptoms. She was also receiving azathioprine, mycophenolate mofetil, and pyridostigmine (all were continued during subsequent therapies). PLEX (5 sessions over 10 days) was initially effective, but over the following month the patient received PLEX weekly, then twice weekly, followed by 3-times weekly because of worsening symptoms. In April 2018, PLEX was reduced to twice weekly following initiation of eculizumab (weekly induction dose of 900 mg 1 day after first PLEX, plus 600 mg on the day of the second PLEX session, for 4 weeks). The patient was then stabilized on eculizumab 1200 mg every 2 weeks and the frequency of PLEX treatment was reduced, until PLEX was discontinued at Week 39 after eculizumab initiation. During eculizumab treatment, the patient's Myasthenia Gravis Activities of Daily Living (MG-ADL) score decreased from 9 to 1 or 2 at most assessments, with a transient increase to 4 or 5 between Weeks 19 and 27 following less frequent eculizumab treatment. There were no eculizumab-related adverse events.**Conclusions:** Following transition from 3-times weekly PLEX to eculizumab in a patient with treatment-refractory, AChR antibody- and MuSK antibody-negative gMG, there were clinically significant improvements in everyday activities affected by MG symptoms. Further investigation of eculizumab in antibody-negative MG is required.**MeSH Keywords:** Complement Inactivating Agents • Myasthenia Gravis • Plasma Exchange**Full-text PDF:** <https://www.amjcaserep.com/abstract/index/idArt/921431>

1700



—



1



17



## Background

Generalized myasthenia gravis (gMG) is an autoimmune condition affecting the neuromuscular junction [1]. Most patients with MG (~80%) harbor antibodies against the acetylcholine receptor (AChR), with ~4% testing positive for muscle-specific kinase (MuSK) antibodies and ~2% for low-density lipoprotein receptor-related protein 4 (LRP4) antibodies; ~5% of patients are considered seronegative [2]. Treatments for MG include acetylcholinesterase inhibitors, immunosuppressants, and immunotherapies (total plasma exchange [PLEX] and intravenous immunoglobulin [IVIg]) [1–3]. However, ~10–15% of patients do not achieve full disease control or cannot tolerate prolonged immunosuppression [2]. One option for treatment-refractory disease is eculizumab, a humanized murine monoclonal antibody that targets the innate immune system by blocking formation of the terminal complement complex [4]. Eculizumab was shown to be effective and well tolerated in patients with refractory AChR antibody-positive gMG in short-term, placebo-controlled studies [5,6] and during long-term maintenance [7]. However, its effectiveness in antibody-negative MG is unknown. Here, we report the case of a patient with refractory AChR antibody- and MuSK antibody-negative MG who was transitioned from PLEX and successfully managed with eculizumab.

## Case Report

The female patient (now 70 years old) was diagnosed with gMG by a neurologist in March 2016. The patient's serum was antibody-negative for both AChR (AChR-binding antibodies <0.30 nmol/L; AChR-blocking antibodies <15% inhibition; AChR-modulating antibodies 4% [using radioimmunoassay]) and MuSK (using radioimmunoprecipitation assay); antibodies against were not measured. The patient's MG was managed aggressively with therapies including pyridostigmine and azathioprine, and historically, with onabotulinum toxin A and IVIG, but these failed to control her symptoms. She had no psychiatric comorbidities, nor physical comorbidities other than those related to her gMG, and no history of tobacco smoking, or alcohol or substance abuse.

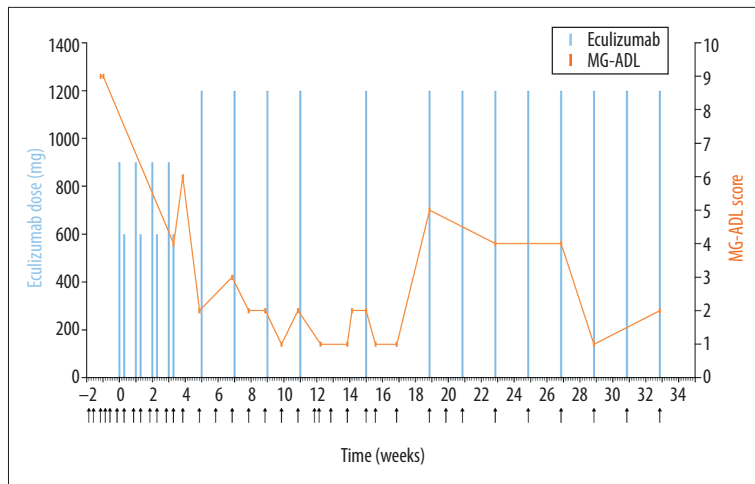
In January 2017, the patient was referred by her neurologist to the nephrology clinic for PLEX. At that time, she had symptoms of ptosis and slurred speech, and scored 4/5 (scale: 0, no contraction; 5, normal strength) for flexor and extensor strength in all 4 extremities. Her treatment comprised azathioprine 50 mg twice daily, mycophenolate mofetil 1 g twice daily, and pyridostigmine 120 mg 3-times daily (which continued at the same doses during all subsequent therapies). The patient received 5 PLEX sessions over 10 days; her condition initially improved and PLEX was well tolerated. However, within 11 days

her symptom severity regressed to pre-PLEX levels and weekly PLEX was instigated. Over the following month, PLEX frequency was increased to twice weekly and then 3-times weekly because of worsening symptoms.

In April 2018, the patient requested treatment with eculizumab because of lack of symptom improvement and the inconvenience of 3-times weekly PLEX. This was initially declined because of her AChR antibody-negative status, but the patient successfully petitioned her medical insurance company to cover off-label treatment. Two weeks after meningococcal vaccinations, the patient started on eculizumab and PLEX was reduced to twice weekly. The initial eculizumab dose was 1500 mg per week for 4 weeks, comprising a weekly induction dose of 900 mg 1 day after the first PLEX and a supplemental 600-mg dose on the day of the second PLEX. Over subsequent weeks, the patient was stabilized on eculizumab 1200 mg (single dose) every 2 weeks and PLEX frequency was reduced (Figure 1). The patient underwent her last PLEX in January 2019, 39 weeks after eculizumab initiation; the patient continued treatment with eculizumab 1200 mg every 2 weeks. Eculizumab was well tolerated, with no treatment-related adverse events.

At regular intervals during eculizumab treatment, the patient completed the Myasthenia Gravis Activities of Daily Living (MG-ADL) questionnaire [8], which assesses the impact of MG symptoms on 8 everyday activities on a scale of 0–24 (higher scores indicate greater negative impact). Before eculizumab, the patient's total MG-ADL score was 9, with item scores of 3 for talking, 2 each for swallowing, impairment of ability to arise from chair, and eyelid droop, and 0 [normal] for all other items). Within 8 weeks after initiation of eculizumab, the total score decreased to 1 or 2 and this was maintained until Week 17. Total scores increased to 4 or 5 at Weeks 19–27 before a decrease back to 1 or 2 at Week 29 (Figure 1). This transient increase may be related to the patient missing eculizumab treatment at Weeks 13 and 17 because of appointment scheduling errors. Item scores for talking and swallowing were lower than pre-treatment levels at all assessments. For eyelid droop, all scores were 1, except at one assessment 4 weeks after eculizumab initiation, when it was 2 (the same as pre-treatment). Items that scored 0 before eculizumab treatment remained at 0 during treatment, except for breathing (for which there were 2 incidences of a score of 1 [at Weeks 4 and 19]). There were also objective improvements in her muscle strength on physical examination during eculizumab treatment and the patient reported “feeling stronger” and “more energy” within 2 months of eculizumab initiation.

The patient's serum was retested (using enzyme-linked immunosorbent assays) in April 2019 and she was confirmed to be negative for both anti-AChR and anti-MuSK antibodies.



**Figure 1.** MG-ADL score and eculizumab dose in a patient with treatment-refractory, AChR antibody- and MuSK antibody-negative MG being transitioned from PLEX to eculizumab. Published data and guidance are lacking on eculizumab dosing in PLEX-treated patients; a 600 mg supplemental dose was administered 2 days after the 900 mg dose (on the same days each week) when PLEX was conducted twice weekly; no supplemental eculizumab doses were given after PLEX frequency was reduced to once per week or less. Arrows along the x-axis indicate days on which PLEX was performed (note that it was continued until Week 39, then discontinued [not shown in figure]). AChR – acetylcholine receptor; MG-ADL – Myasthenia Gravis Activities of Daily Living; MuSK – muscle-specific kinase; PLEX – plasma exchange.

## Discussion

This case study may be familiar to some clinicians: a patient whose disease is refractory to standard MG treatments, undergoing frequent PLEX, but with only partial resolution of symptoms. Such patients have very limited treatment options. Eculizumab is licensed in the USA, Europe, and Japan for the treatment of gMG (refractory MG in Europe and symptoms “difficult to control with high-dose IVIG or PLEX” in Japan) in AChR antibody-positive patients [9–11] (i.e., the subgroup included in key clinical trials [5–7]). In the current case, eculizumab was effective and well tolerated in a patient with treatment-refractory, AChR antibody- and MuSK antibody-negative disease. Importantly, the patient experienced substantial improvements in daily activities affected by MG symptoms; her MG-ADL score decreased to 1 or 2 at most assessments and although there was a transient increase to a score of 4 or 5 between Weeks 19 and 27 (possibly related to interruptions in eculizumab treatment), the reduction from pre-treatment levels was nevertheless greater than the clinically relevant change of 2 points [12]. Initiation of eculizumab also permitted a reduction in the frequency and eventual discontinuation of PLEX therapy, which had been administered 3-times weekly for over a year at the time of eculizumab initiation. Given that there were no other changes in the patient’s treatment regimen (azathioprine, mycophenolate mofetil, and pyridostigmine), the improvements in her condition appear to be associated with the eculizumab treatment.

The patient’s antibody status was assessed using standard assays for AChR and MuSK antibodies. It is possible that the patient had AChR-antibody titers that were below the limit of sensitivity of the assays used. High-sensitivity assays can detect AChR antibodies in 35% of patients who are “seronegative” [13]. It is also possible that the patient had antibodies against LRP4; these were not measured at diagnosis as an assay was not commercially available and there are no targeted

therapies based on presence of these antibodies. It is estimated that 6–8% of patients with “seronegative” MG are anti-LRP4 positive, although it has been suggested that in reality, these patients are not truly seronegative for AChR antibodies [13]. Either way, patients with seronegative or anti-LRP4-positive MG respond to the same treatment as disease more commonly recognized as AChR-antibody positive [13]. The effect of eculizumab in patients with other antibodies thought to be involved in MG (e.g., against agrin and titin) is unknown, but these antibodies occur less frequently than anti-AChR or anti-MuSK antibodies. Concentrations of complement components were not measured before the patient initiated eculizumab treatment as she was undergoing PLEX therapy.

A number of instruments are available with which to assess health-related outcomes in patients with MG. The MG-ADL questionnaire was chosen in this case as it is a validated assessment tool that can be easily used in clinical practice and has the advantage of evaluating disease impact from the patient’s perspective. Another tool frequently used in clinical trials is the quantitative myasthenia gravis score; however, this is a physician-evaluated outcome measure that requires instrumentation and takes longer to complete [12,14,15].

The case also provides information on how to transition patients from PLEX to eculizumab. Guidance on this is lacking, even in AChR-positive patients. In the current case, PLEX frequency was gradually reduced and eventually discontinued approximately 9 months after eculizumab initiation. It is possible that PLEX could have been discontinued more quickly, potentially guided by combined clinical examination and MG-ADL scores. In a clinical-trial setting, eculizumab’s maximal efficacy appears to be attained after 12 weeks of treatment [6].

For this patient, however, the focus was on ensuring a safe transition without symptom re-emergence.

PLEX is an established therapy for MG but is usually reserved for patients with acute disease [16]. It is generally well tolerated, although excessive fluid shifts can cause hypotension or fluid overload [17]. PLEX is, however, associated with similar issues to those encountered with hemodialysis. Quality of life is affected as this therapy usually takes 2.5 hours to complete and is often associated with considerable post-treatment fatigue. Blood access is also a primary concern as using a Permacath often leads to infectious complications or the creation of an arteriovenous fistula that may cause vascular complications. The procedure is expensive and, for this patient, imposed a significant burden that required clinic visits 3 times each week for more than a year. The patient reported “feeling sick after plasma treatment”. The transition to eculizumab, administered every 2 weeks as maintenance therapy, substantially reduced this burden.

## References:

1. Gilhus NE, Skeie GO, Romi F et al: Myasthenia gravis – autoantibody characteristics and their implications for therapy. *Nat Rev Neurol*, 2016; 12: 259–68
2. Gilhus NE, Verschuuren JJ: Myasthenia gravis: Subgroup classification and therapeutic strategies. *Lancet Neurol*, 2015; 14: 1023–36
3. Suh J, Goldstein JM, Nowak RJ: Clinical characteristics of refractory myasthenia gravis patients. *Yale J Biol Med*, 2013; 86: 255–60
4. Davis J: Eculizumab. *Am J Health Syst Pharm*, 2008; 65: 1609–15
5. Howard JF Jr, Barohn RJ, Cutter GR et al: A randomized, double-blind, placebo-controlled phase II study of eculizumab in patients with refractory generalized myasthenia gravis. *Muscle Nerve*, 2013; 48: 76–84
6. Howard JF Jr, Utsugisawa K, Benatar M et al: Safety and efficacy of eculizumab in anti-acetylcholine receptor antibody-positive refractory generalised myasthenia gravis (REGAIN): A phase 3, randomised, double-blind, placebo-controlled, multicentre study. *Lancet Neurol*, 2017; 16: 976–86
7. Muppidi S, Utsugisawa K, Benatar M et al: Long-term safety and efficacy of eculizumab in generalized myasthenia gravis. *Muscle Nerve*, 2019; 60: 14–24
8. Wolfe GI, Herbelin L, Nations SP et al: Myasthenia gravis activities of daily living profile. *Neurology*, 1999; 52: 1487–89
9. Alexion Pharmaceuticals, Inc. Soliris Prescribing Information 2018. Available at: [https://alexion.com/Documents/Soliris\\_USPI.aspx](https://alexion.com/Documents/Soliris_USPI.aspx)
10. Alexion Europe SAS. Soliris European Summary of Product Characteristics 2018. Available at: [https://www.ema.europa.eu/documents/product-information/soliris-epar-product-information\\_en.pdf](https://www.ema.europa.eu/documents/product-information/soliris-epar-product-information_en.pdf)
11. Pharmaceuticals and Medical Devices Agency, Japan. Soliris Intravenous Infusion 300 mg (Japanese Package Insert), Revised: February 2019 (Version 11). Available at: [http://www.soliris.jp/common/pdf/tempu\\_bunsho.pdf](http://www.soliris.jp/common/pdf/tempu_bunsho.pdf)
12. Muppidi S, Wolfe GI, Conaway M, Burns TM, MG Composite and MG-QOL15 Study Group: MG-ADL: Still a relevant outcome measure. *Muscle Nerve*, 2011; 44: 727–31
13. Dalakas MC: Immunotherapy in myasthenia gravis in the era of biologics. *Nat Rev Neurol*, 2019; 15: 113–24
14. Barnett C, Herbelin L, Dimachkie MM, Barohn RJ: Measuring clinical treatment response in myasthenia gravis. *Neurol Clin*, 2018; 36: 339–53
15. Muppidi S: Outcome measures in myasthenia gravis: Incorporation into clinical practice. *J Clin Neuromuscul Dis*, 2017; 18: 135–46
16. Sieb JP: Myasthenia gravis: An update for the clinician. *Clin Exp Immunol*, 2014; 175: 408–18
17. Juel VC, Massey JM: Myasthenia gravis. *Orphanet J Rare Dis*, 2007; 2: 44

## Conclusions

To conclude, a patient with treatment-refractory, AChR antibody- and MuSK antibody-negative gMG was successfully transitioned from 3-times weekly PLEX to eculizumab. The patient experienced clinically significant improvements in everyday activities affected by MG symptoms and eculizumab was well tolerated. This is the first report of eculizumab use in an antibody-negative patient; further investigation under more rigorous conditions is now required.

## Acknowledgements

Editorial support was provided by Dr. Nicky French of Anthemis Consulting Ltd., funded by Alexion Pharmaceuticals, Inc. Alexion Pharmaceuticals provided a courtesy medical-accuracy review of the final manuscript.

## Conflicts of interest

Dr. Gregory T. Greenwood has served as a paid consultant for Alexion Pharmaceuticals. Mr. Zachary Lynch has no conflicts of interest.

## Department and Institution where work was done

Nephrology Associates, Winston-Salem, NC, U.S.A.