

Lowering Intraocular Pressure: A Potential Approach for Controlling High Myopia Progression

Peiyuan Wang,¹ Shida Chen,¹ Yaoming Liu,¹ Fengbin Lin,¹ Yunhe Song,¹ Tuozhang Li,² Tin Aung,³ and Xiulan Zhang¹; for the GSHM study group

¹State Key Laboratory of Ophthalmology, Zhongshan Ophthalmic Center, Sun Yat-sen University, Guangzhou, China

²Zhongshan School of Medicine, Sun Yat-sen University, Guangzhou, China

³Singapore National Eye Center, National University of Singapore, Singapore

Correspondence: Xiulan Zhang, State Key Laboratory of Ophthalmology, Zhongshan Ophthalmic Center, Sun Yat-sen University, No.7 Jinsui Road, Guangzhou 510060, China; zhangxl2@mail.sysu.edu.cn.

PW and SC contributed equally to this work.

Received: May 31, 2021

Accepted: October 21, 2021

Published: November 17, 2021

Citation: Wang P, Chen S, Liu Y, et al. Lowering intraocular pressure: A potential approach for controlling high myopia progression. *Invest Ophthalmol Vis Sci.* 2021;62(14):17. <https://doi.org/10.1167/iovs.62.14.17>

High myopia is among the most common causes of vision impairment, and it is mainly characterized by abnormal elongation of the axial length, leading to pathologic changes in the ocular structures. Owing to the close relationship between high myopia and glaucoma, the association between intraocular pressure (IOP) and high myopia progression has garnered attention. However, whether lowering IOP can retard the progression of high myopia is unclear. On reviewing previous studies, we suggest that lowering IOP plays a role in progressive axial length elongation in high myopia, particularly in pathologic myopia, wherein the sclera is more remodeled. Based on the responses of the ocular layers, we further proposed the potential mechanisms. For the sclera, lowering the IOP could inhibit the activation of scleral fibroblasts and then reduce scleral remodeling, and a decrease in the scleral distending force would retard the ocular expansion like a balloon. For the choroid, lowering IOP results in an increase in choroidal blood perfusion, thereby reducing scleral hypoxia and slowing down scleral remodeling. The final effect of these pathways is slowing axial elongation and the development of scleral staphyloma. Further animal and clinical studies regarding high myopia with varied degree of IOP and the changes of choroid and sclera during IOP fluctuation in high myopia are needed to verify the role of IOP in the pathogenesis and progression of high myopia. It is hoped that this may lead to the development of a prospective treatment option to prevent and control high myopia progression.

Keywords: high myopia, intraocular pressure, axial elongation, sclera, choroid

High myopia is a leading cause of visual impairment and blindness worldwide, which is defined as a refractive error ≤ -6.00 diopters (D) or axial length (AL) ≥ 26.5 mm.¹ It is characterized by excessive axial elongation and associated with a high risk of other ocular complications such as retinal detachment, glaucoma, and cataracts.² Pathologic myopia is possibly a consequence of high myopia, with additional abnormal choroidal vasculature and degenerative changes.³ These features make high myopia a challenging global public health problem, especially in East Asian countries.^{4,5}

Highly myopic eyes, due to the abnormal elongation of AL, result in different anatomic changes such as posterior staphyloma, atrophy of retina and choroid, deformation of the optic nerve, and retinoschisis, which will lead to irreversible vision impairment.^{6,7} New loci associated with high myopia have been constantly identified, and an important role of the nervous system was suggested in the etiology of this highly hereditary disease,^{8,9} whereas the exact pathogenesis and biological mechanisms of high myopia remain to be elucidated. A few theories have been put forward: scleral remodeling and mechanical property weakening are underlining the development of high myopia and posterior staphyloma.¹⁰ In addition, Bruch's membrane opening has a role in

the process of axial elongation of high myopia,⁶ while high myopia may also be influenced by defects in choroidal circulation.¹¹ Based on current medical technology, high myopia is considered an irreversible ocular degeneration without effective interventions.

More and more evidence has suggested that high myopia is closely related to the occurrence of glaucoma. Most studies have reported that people with high myopia have a twofold to fourfold increased risk of open-angle glaucoma,¹²⁻¹⁶ although a few studies have indicated that they are unrelated.^{17,18} A meta-analysis showed that the pooled odds ratios of the association with glaucoma were 1.77 for low myopia and 2.46 for high myopia.¹⁹ The Collaborative Longitudinal Evaluation of Ethnicity and Refractive Error study has determined that the mean intraocular pressure (IOP) before myopia onset was significantly higher ($P < 0.001$) than that of emmetropes in children, but the IOP difference (0.57 mm Hg) was relatively small to suggest a role for IOP in the onset of myopia.²⁰ At the genetic level, a meta-analysis of genome-wide association studies has further explored the significant genetic correlation between refractive error and IOP ($P = 1.04 \times 10^{-12}$). A Mendelian randomization model was built to demonstrate that on average, every 1-mm Hg increase in IOP predicts a 0.05- to 0.09-D decrease

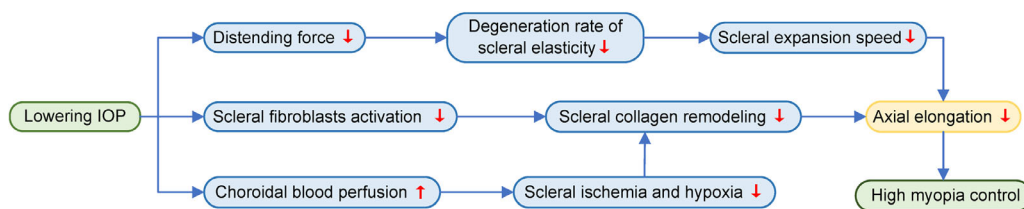


FIGURE. The potential mechanisms for the control of high myopia progression through the lowering of IOP.

in spherical equivalent,²¹ which means exposure to higher IOP may inadvertently raise the prevalence of myopia.

IOP contributes to the regulation of retinal and choroidal microcirculation and deformation of the optic disc, which is involved in glaucoma and also in myopic optic neuropathy.^{22,23} The above evidence implies that IOP may play a role in the pathogenesis of high myopia. Combined with previous animal and clinical studies, we propose that lowering the IOP can control high myopia progression based on the responses of the scleral and choroidal layers. The potential mechanism underlying this perspective is illustrated (Fig.) and may provide multiple potential targets for the prevention and control of high myopia, which is expected to help in the management and prognosis of high myopia.

EVIDENCE IN ANIMAL EXPERIMENTS

In animal experiments, the effect of lowering IOP in controlling AL and the refractive error changes caused by ocular hypotensive medications are varied. Timolol, a β -adrenergic receptor blocker, was shown to be unable to control myopia progression in chicks,²⁴ and carteolol also showed no significant correlation with axial elongation in young guinea pigs.²⁵ However, a selective prostaglandin F2 α receptor agonist called latanoprost was proved to induce the remodeling of scleral collagen and normalize the scleral microstructure in the guinea pig myopia models, leading to reduced AL elongation and refractive error changes.^{26,27} Others have suggested that latanoprost acid can also inhibit the progression of form-deprivation myopia in guinea pigs, probably by hypotensive effects, and strengthen the scleral framework to reduce AL elongation.²⁸ In addition, both brimonidine eye drops and intravitreal injections were reported to be effective in inhibiting progressing myopia, mainly through slowing AL elongation.^{29,30}

There are some possible explanations for the inconsistent effect of IOP-lowering medications on myopia progression in animal models. First, the chick's sclera has an inner cartilage layer that is more resistant to IOP fluctuations than guinea pigs. The older the animal, the lower the elasticity of the sclera and the weaker the response to IOP changes. Second, different types of medications have different IOP-lowering efficacy, and medication such as β -receptor blockers cannot maintain a low and stable level of IOP during nighttime compared with prostaglandins, as IOP diurnal fluctuation tends to play an important role in axial elongation.³¹ Third, differences in pharmacodynamics, specific receptors, and the impact on vascular flow density as well as choroidal blood perfusion may also contribute to these different results, which require further elucidation.

EVALUATIONS IN CLINICAL PRACTICES

During clinical practice, many studies have shown that AL elongation is associated with IOP to some extent at different ages. As for young children, a population-based predicted model showed that AL was most strongly influenced by age and reached a plateau around 3 years, as the sclera becomes much less distensible after that.³² This association was also significantly influenced by IOP; for example, in children with congenital glaucoma with increased IOP, the predicted curve of AL was approximately 1 to 2 mm higher for the same age and sex. Another retrospective study proved that in children with congenital glaucoma with an average age of 10 months, the postoperative IOP after trabeculectomy or goniotomy was remarkably correlated with AL growth.³³ With IOP controlled in congenital glaucoma, AL may decrease or the axial growth pattern may parallel the normal growth curve.³⁴ To our knowledge, no long-term follow-up of infants' AL under different IOP has been reported. During the rapid growth of the sclera and eyeball in young children, AL seems to be very sensitive to changes in IOP. In 6- to 11-year-old myopic children, a 5-year follow-up study by the Correction of Myopia Evaluation Trial suggested that IOP was not associated with myopia progression or change in AL.³⁵ Concerning teens and those in their early 20s, the Singapore Cohort Study of the Risk Factors for Myopia (SCORM) study suggested that there were no significant IOP differences between high or low myopia and emmetropes, and it did not support an association between IOP and AL or refractive error in children.³⁶ Conversely, the Anyang Childhood Eye Study indicated that IOP was about 1 to 2 mm Hg higher in myopic eyes than in emmetropic or hyperopia eyes using noncontact tonometry. However, in eyes with greater myopia progression, IOP was significantly lower, which indicated that progressing myopic eyes have higher scleral compliance.³⁷ A multivariate linear regression analysis used in the Anyang University Students Eye Study described that higher IOP is associated with higher myopic refractive error and shorter AL. As the sclera has a certain compliance, below the threshold, the correlation between IOP and AL was negative, while above a certain degree, the correlation was positive.^{38,39} Therefore, the true value of IOP tends to be underestimated in progressive high myopic eyes, and the compliance of the sclera should be taken into consideration. In healthy teenagers' eyes, after an immediate IOP elevation of 10 and 20 mm Hg that was induced by a suction cup, the AL significantly increased by 23 and 39 μ m, respectively.⁴⁰ The result indicates that the elasticity of the sclera still exists in teenagers; however, we should acknowledge that the AL change in teenagers was far less than that in young children under different IOPs.

The relationship between IOP and myopia was even more inconsistent in older adults. A Japanese survey confirmed

that the mean IOP in advancing degrees of myopia was slightly higher than that of nonmyopic eyes, even after adjusting the age and central corneal thickness.⁴¹ As for the population over 40 years old, the Japanese Kumejima study demonstrated that higher IOP was significantly correlated with longer AL ($P < 0.018$),⁴² while the Los Angeles Latino Eye Study showed there was no significant association between IOP and AL ($P = 0.13$).⁴³ In addition, the Lingtong Eye Cohort Study manifested that longitudinal changes in IOP were positively related to myopic progression (based on spherical equivalent, $P < 0.001$).⁴⁴ The Northern Ireland Cohort for the Longitudinal Study of Ageing study, which enrolled participants older than 50 years, demonstrated that increased IOP was associated with increased myopic refractive error in adjusted multivariate analysis ($P < 0.01$), but the AL parameters were not included in the analysis.⁴⁵ Moreover, in elderly patients with open-angle glaucoma, AL reduction after trabeculectomy or glaucoma drainage device surgery was related to postoperative IOP and the amount of IOP reduction.⁴⁶ More accurately, the Wilmer Eye Institute indicated that for every 1-mm Hg IOP decrease after trabeculectomy, there was a mean decrease of 6.8 μm in AL.⁴⁷ A Japanese 6-year follow-up study found that the lack of using IOP-lowering medications in high myopic adult patients was a prognostic factor for increased AL in the multivariate analysis.⁴⁸ However, the postoperative AL change by IOP in adults was much less significant than that in young children, in both the value and the proportion of total AL. In addition, in adult patients with glaucoma who had emmetropia or mild myopia, AL decreased by only 0.16 mm after trabeculectomy,⁴⁹ which was far less than that in the young children. Due to the difference in AL change between children and adults, scleral rigidity and elasticity need to be taken into consideration in IOP measurement.

Moreover, most of the AL was measured from the corneal surface to the retinal pigment epithelium, excluding the choroidal thickness. When IOP decreases, choroidal blood perfusion and choroidal thickness increase accordingly,⁴⁷ which diminish the real AL value change. In vivo elastic responses of the sclera were different between myopic and normal eyes,⁵⁰ and the elasticity of the posterior retina-choroid-sclera complex increased as the AL increased in eyes with high myopia.⁵¹ We hypothesized that the AL is rarely changed by lowering the IOP in normal adults or patients with mild myopia, whose sclera are rigid and relatively inflexible. However, in progressive high myopia, especially pathologic myopia, it has been reported that the sclera of these patients was continually prolonged and had higher compliance and, consequently, was more elastic and more sensitive to IOP change.^{37,51} In summary, we hold the view that lowering the IOP can slow down AL increase, especially in progressive high myopia populations.

SCLERAL RESPONSE TO IOP

As the ocular outer coat, the sclera is considered an indispensable target and has been studied extensively with respect to high myopia pathogenesis. The scleral response to IOP can be divided into two stages—acute and chronic IOP elevation. Changes in scleral structure, composition variation, and weakening of biomechanical properties can result in axial elongation, which is one of the most significant changes in both the early and late stages of high myopia.¹⁰

For decades, Laplace's law has been implemented as a theoretical model in ophthalmology to describe the mecha-

nism of the corneoscleral shell. Although it was proven to be inappropriate, it roughly illustrated the interaction between IOP and stress to the corneoscleral tissues.^{52,53} During ocular growth in childhood or high myopia progression, once IOP is elevated, it is likely to increase ocular stress directly and result in a balloon-like expansion, particularly in the sclera's posterior pole.⁵⁴ After a long stretching period, scleral elasticity may decrease, affecting the scleral growth rate and expansion speed, ultimately leading to axial elongation.⁵⁵ The subsequent scleral rigidity may increase the susceptibility of intraocular structures to the distending force of IOP. This vicious circle might be halted when IOP lowering is practiced. For instance, lowering the IOP can increase scleral resistance and, in turn, reduce the incidence of ocular stretching, which appears to be the fundamental step in avoiding permanent vision loss in high myopia.⁵⁶

It is known that scleral fibroblasts can produce matrix metalloproteinases (MMPs) to induce type I collagen degradation and remodeling of other extracellular matrices, leading to scleral thinning during myopia progression.^{57,58} Another mechanical stretching in vitro model demonstrated that the production of tissue inhibitor of metalloproteinase 1 by human scleral fibroblasts was suppressed and raised the proportion of MMPs and scleral remodeling.⁵⁹ Moreover, mechanical strain-induced Ras homolog family member A/Rho-associated protein kinase 2 pathway and transforming growth factor $\beta 1$ mediation were demonstrated to regulate scleral remodeling.^{60,61} Therefore, IOP lowering may be perceived by the mechanical response genes of scleral fibroblasts and lead to depressed scleral remodeling and reduced axial elongation by inhibiting fibroblast activation.

CHOROIDAL RESPONSE TO IOP

One of the main functions of choroid, a blood-rich tissue, is to supply oxygen and nutriment to the outer retina and overlying sclera. Reduced choroidal blood flow can result in scleral ischemia and hypoxia, contributing to the onset of ocular elongation and myopia.⁶² Choroidal thickness (CT) is a measurable indicator of choroidal blood perfusion (ChBP) and was reported to be thinner in myopia than in emmetropia and hyperopia; specifically, CT decreases by 5 μm per refraction diopter of myopia.^{63,64} Furthermore, in high myopic eyes, CT was reported to be negatively correlated with AL,⁶⁵ and CT reduction occurred before retinal thinning in the early progression of myopia.⁶⁶ Hence, choroidal thinning was supposed to serve as a new target or predictor biomarker for myopic development and progression.^{67,68}

It is worth noting that lowering the IOP can promote ChBP. For example, topical ocular hypotensive drugs such as bimatoprost and dorzolamide have been shown to increase ChBP and cause a marked increase in CT.^{69,70} For every 1-mm Hg decrease in IOP after trabeculectomy, the mean increase in CT was 3.4 μm , and these postoperative changes were maintained for at least 6 months.^{47,71} Interestingly, several interventions to retard myopia progression in children and teenagers, such as orthokeratology treatment and low-dose atropine, also increased ChBP or CT.^{72,73} This suggested that increasing ChBP may be a significant target in high myopia control. Remarkably, increased ChBP has recently been reported to inhibit high myopia progression by reducing scleral ischemia and hypoxia and further leads to changes in the scleral extracellular matrix and collagen remodeling in guinea pigs,⁷⁴ indicating that lowering the

IOP is a promising mechanism for controlling high myopic development by increasing the blood supply to the choroid.

FUTURE DIRECTIONS AND CHALLENGES

Currently, there is no direct evidence for the role of IOP in the pathogenesis of high myopia, and many unanswered questions remain about the effect of reducing the IOP on the progression of high myopia. We propose that the following issues should be answered: (1) How does the AL change in high myopia under varied IOP degrees? Will higher IOP contribute to longer AL? (2) What is the underlying mechanism of scleral and choroid change in high myopia under higher IOP? (3) Will reducing IOP slow down the progression of high myopia that showed as AL elongation, atrophy of the retina and choroid, or tractional change of the retina? If so, animal experiments are needed to further clarify the effect of varied degrees of IOP on sclera and choroid and their exact role in AL growth. Further longitudinal clinical data regarding the AL changes in patients with high myopia who have used or are currently using ocular hypotension medications and even randomized controlled trials with interventions to reduce IOP in patients with progressive high myopia are also significant to confirm the feasibility of reducing IOP for controlling progressive high myopia or continuous axial elongation.

CONCLUSION

High myopia comprises multiple etiologic factors, and the mechanisms for controlling high myopia are more complex. There is contradictory clinical and experimental evidence for the relationship between high myopia and glaucoma as well as between IOP and myopia progression. By summarizing the findings of previous studies, we concluded that lowering the IOP may control high myopia progression, particularly in progressive high myopia and pathologic myopia, wherein the sclera is more elastic, grows faster, and is more susceptible to IOP changes. The potential mechanisms based on the responses of the scleral and choroidal layers were proposed. First, lowering the IOP can decrease the distending force on the sclera and slow down the scleral elasticity degeneration rate and expansion speed. Second, lowering the IOP may be perceived by the mechanical response genes of scleral fibroblasts and inhibit the activation of scleral fibroblasts. Third, the ocular hypotension effect can result in an increase of ChBP, thereby reducing scleral ischemia and hypoxia. The final effect is the reduction of scleral collagen remodeling and the attenuation of axial elongation. This perspective may serve as a basis for delaying high myopia progression and controlling high myopia combined with glaucoma. However, further animal and clinical studies are in urgent need to confirm the role of IOP in the pathogenesis and progression of high myopia.

Acknowledgments

We thank all members of the Glaucoma Suspects with High Myopia (GSHM) study group who contributed and supported this series of studies.

Supported by the High-Level Hospital Construction Project, Zhongshan Ophthalmic Center, Sun Yat-sen University (303020104) and the Science and Technology Program of

Guangzhou, China (202102010209). The funding organizations had no role in the design or conduct of this research.

Disclosure: **P. Wang**, None; **S. Chen**, None; **Y. Liu**, None; **F. Lin**, None; **Y. Song**, None; **T. Li**, None; **T. Aung**, None; **X. Zhang**, None

References

- Flitcroft DI, He M, Jonas JB, et al. IMI—defining and classifying myopia: a proposed set of standards for clinical and epidemiologic studies. *Invest Ophthalmol Vis Sci*. 2019;60(3):M20–M30.
- Ikuno Y. Overview of the complications of high myopia. *Retina*. 2017;37(12):2347–2351.
- Ohno-Matsui K, Lai TYY, Lai CC, Cheung CMG. Updates of pathologic myopia. *Prog Retin Eye Res*. 2016;52:156–187.
- Morgan IG, Ohno-Matsui K, Myopia Saw SM. *Lancet*. 2012;379(9827):1739–1748.
- Wong YL, Saw SM. Epidemiology of pathologic myopia in Asia and worldwide. *Asia Pac J Ophthalmol (Phila)*. 2016;5(6):394–402.
- Jonas JB, Wang YX, Dong L, Guo Y, Panda-Jonas S. Advances in myopia research anatomical findings in highly myopic eyes. *Eye Vis (Lond)*. 2020;7:45.
- Jonas JB, Ohno-Matsui K, Panda-Jonas S. Myopia: anatomic changes and consequences for its etiology. *Asia Pac J Ophthalmol (Phila)*. 2019;8(5):355–359.
- Tedja MS, Haarman AEG, Meester-Smoor MA, et al. IMI—myopia genetics report. *Invest Ophthalmol Vis Sci*. 2019;60(3):M89–M105.
- Meguro A, Yamane T, Takeuchi M, et al. Genome-wide association study in asians identifies novel loci for high myopia and highlights a nervous system role in its pathogenesis. *Ophthalmology*. 2020;127(12):1612–1624.
- McBrien NA, Gentle A. Role of the sclera in the development and pathological complications of myopia. *Prog Retin Eye Res*. 2003;22(3):307–338.
- Wu Q, Chen Q, Lin B, et al. Relationships among retinal/choroidal thickness, retinal microvascular network and visual field in high myopia. *Acta Ophthalmol*. 2020;98(6):e709–e714.
- Mitchell P, Hourihan F, Sandbach J, et al. The relationship between glaucoma and myopia: the Blue Mountains Eye Study. *Ophthalmology*. 1999;106(10):2010–2015.
- Wong TY, Klein BE, Klein R, et al. Refractive errors, intraocular pressure, and glaucoma in a white population. *Ophthalmology*. 2003;110(1):211–217.
- Kuzin AA, Varma R, Reddy HS, et al.; Los Angeles Latino Eye Study Group. Ocular biometry and open-angle glaucoma: the Los Angeles Latino Eye Study. *Ophthalmology*. 2010;117(9):1713–1719.
- Pan CW, Cheung CY, Aung T, et al. Differential associations of myopia with major age-related eye diseases: the Singapore Indian Eye Study. *Ophthalmology*. 2013;120(2):284–291.
- Shen L, Melles RB, Metlapally R, et al. The association of refractive error with glaucoma in a multiethnic population. *Ophthalmology*. 2016;123(1):92–101.
- Kass MA, Heuer DK, Higginbotham EJ, et al. The Ocular Hypertension Treatment Study: a randomized trial determines that topical ocular hypotensive medication delays or prevents the onset of primary open-angle glaucoma. *Arch Ophthalmol*. 2002;120(6):701–713; discussion 829–830.
- Chao DL, Shrivastava A, Kim DH, et al. Axial length does not correlate with degree of visual field loss in myopic Chinese individuals with glaucomatous appearing optic nerves. *J Glaucoma*. 2010;19(8):509–513.

19. Marcus MW, de Vries MM, Junoy Montolio FGJ, et al. Myopia as a risk factor for open-angle glaucoma: a systematic review and meta-analysis. *Ophthalmology*. 2011;118(10):1989–1994.e2.
20. Manny RE, Mitchell GL, Cotter SA, et al. Intraocular pressure, ethnicity, and refractive error. *Optom Vis Sci*. 2011;88(12):1445–1453.
21. Hysi PG, Choquet H, Khawaja AP, et al. Meta-analysis of 542,934 subjects of European ancestry identifies new genes and mechanisms predisposing to refractive error and myopia. *Nat Genet*. 2020;52(4):401–407.
22. Shin JW, Kwon J, Lee J, Kook MS. Relationship between vessel density and visual field sensitivity in glaucomatous eyes with high myopia. *Br J Ophthalmol*. 2018;103:585–591.
23. Tan NYQ, Sng CCA, Ang M. Myopic optic disc changes and its role in glaucoma. *Curr Opin Ophthalmol*. 2019;30(2):89–96.
24. Schmid KL, Abbott M, Humphries M, Pyne K, Wildsoet CF. Timolol lowers intraocular pressure but does not inhibit the development of experimental myopia in chick. *Exp Eye Res*. 2000;70(5):659–666.
25. Dong L, Li YF, Wu HT, et al. Lens-induced myopization and intraocular pressure in young guinea pigs. *BMC Ophthalmol*. 2020;20(1):343.
26. El-Nimri NW, Wildsoet CF. Effects of topical latanoprost on intraocular pressure and myopia progression in young guinea pigs. *Invest Ophthalmol Vis Sci*. 2018;59(6):2644–2651.
27. El-Nimri NW, Yao M, Huerta A, Hoang M, Wildsoet CF. Effect of chronic topical latanoprost on the sclera and lamina cribrosa of form-deprived myopic Guinea pigs. *Exp Eye Res*. 2019;186:107740.
28. Yang J, Pan M, Reinach PS, et al. Prostaglandin F2 α receptor modulation affects eye development in guinea pigs. *Basic Clin Pharmacol Toxicol*. 2018;123(3):263–270.
29. Liu Y, Wang Y, Lv H, Jiang X, Zhang M, Li X. Alpha-adrenergic agonist brimonidine control of experimentally induced myopia in guinea pigs: a pilot study. *Mol Vis*. 2017;23:785–798.
30. Yang Y, Wu J, Wu D, et al. Intravitreal brimonidine inhibits form-deprivation myopia in guinea pigs. *Eye Vis (Lond)*. 2021;8(1):27.
31. Chakraborty R, Read SA, Collins MJ. Diurnal variations in axial length, choroidal thickness, intraocular pressure, and ocular biometrics. *Invest Ophthalmol Vis Sci*. 2011;52(8):5121–5129.
32. Al-Obaida I, Al Owaifeer AM, Ahmad K, Malik R. The relationship between axial length, age and intraocular pressure in children with primary congenital glaucoma. *SCI REP-UK Sci Rep*. 2020;10(1):17821.
33. Kiefer G, Schwenn O, Grehn F. Correlation of postoperative axial length growth and intraocular pressure in congenital glaucoma—a retrospective study in trabeculectomy and goniotomy. *Graefes Arch Clin Exp Ophthalmol*. 2001;239(12):893–899.
34. Law SK, Bui D, Caprioli J. Serial axial length measurements in congenital glaucoma. *Am J Ophthalmol*. 2001;132(6):926–928.
35. Manny RE, Deng L, Crossnoe C, Gwiazda J. IOP, myopic progression and axial length in a COMET subgroup. *Optom Vis Sci*. 2008;85(2):97–105.
36. Lee AJ, Saw SM, Gazzard G, Cheng A, Tan DTH. Intraocular pressure associations with refractive error and axial length in children. *Br J Ophthalmol*. 2004;88(1):5–7.
37. Li SM, Iribarren R, Li H, et al. Intraocular pressure and myopia progression in Chinese children: the Anyang Childhood Eye Study. *Br J Ophthalmol*. 2019;103(3):349–354.
38. Ma D, Wei S, Sun Y, et al. Distribution of IOP and its relationship with refractive error and other factors: the Anyang University Students Eye Study. *Int J Ophthalmol*. 2021;14(4):554–559.
39. Chan MP, Grossi CM, Khawaja AP, et al. Associations with intraocular pressure in a large cohort: results from the UK Biobank. *Ophthalmology*. 2016;123(4):771–782.
40. Leydolt C, Findl O, Drexler W. Effects of change in intraocular pressure on axial eye length and lens position. *Eye (Lond)*. 2008;22(5):657–661.
41. Nomura H, Ando F, Niino N, Shimokata H, Miyake Y. The relationship between intraocular pressure and refractive error adjusting for age and central corneal thickness. *Ophthalmic Physiol Opt*. 2004;24(1):41–45.
42. Tomoyose E, Higa A, Sakai H, et al. Intraocular pressure and related systemic and ocular biometric factors in a population-based study in Japan: the Kumejima study. *Am J Ophthalmol*. 2010;150(2):279–286.
43. Memarzadeh F, Ying-Lai M, Azen SP, Varma R; Los Angeles Latino Eye Study Group. Associations with intraocular pressure in Latinos: the Los Angeles Latino Eye Study. *Am J Ophthalmol*. 2008;146(1):69–76.
44. Han X, Yang T, Zhang J, et al. Longitudinal changes in intraocular pressure and association with systemic factors and refractive error: Lingtong Eye Cohort Study. *BMJ Open*. 2018;8(2):e019416.
45. McCann P, Hogg R, Wright DM, et al. Intraocular pressure and circumpapillary retinal nerve fibre layer thickness in the Northern Ireland Cohort for the Longitudinal Study of Ageing (NICOLA): distributions and associations. *Br J Ophthalmol*. 2021;105(7):948–956.
46. Francis BA, Wang M, Lei H, et al. Changes in axial length following trabeculectomy and glaucoma drainage device surgery. *Br J Ophthalmol*. 2005;89(1):17–20.
47. Saeedi O, Pillar A, Jefferys J, Arora K, Friedman D, Quigley H. Change in choroidal thickness and axial length with change in intraocular pressure after trabeculectomy. *Br J Ophthalmol*. 2014;98(7):976–979.
48. Igarashi-Yokoi T, Shinohara K, Fang Y, et al. Prognostic factors for axial length elongation and posterior staphyloma in adults with high myopia: a Japanese observational study. *Am J Ophthalmol*. 2021;225:76–85.
49. Husain R, Li W, Gazzard G, et al. Longitudinal changes in anterior chamber depth and axial length in Asian subjects after trabeculectomy surgery. *Br J Ophthalmol*. 2013;97(7):852–856.
50. Backhouse S, Phillips JR. Effect of induced myopia on scleral myofibroblasts and in vivo ocular biomechanical compliance in the guinea pig. *Invest Ophthalmol Vis Sci*. 2010;51(12):6162–6171.
51. Pekel G, Ağladoğlu K, Acer S, Bozkurt K, Çetin EN, Yağcı R. Evaluation of ocular elasticity in high myopia. *Optom Vis Sci*. 2015;92:573–578.
52. Cahane M, Bartov E. Axial length and scleral thickness effect on susceptibility to glaucomatous damage: a theoretical model implementing Laplace's law. *Ophthalmic Res*. 1992;24(5):280–284.
53. Chung CW, Girard MJA, Jan N, Sigal IA. Use and misuse of Laplace's law in ophthalmology. *Invest Ophthalmol Vis Sci*. 2016;57(1):236–245.
54. McMonnies CW. An examination of the baropathic nature of axial myopia. *Clin Exp Optom*. 2014;97(2):116–124.
55. Schmid KL, Li RWH, Edwards MH, Lew JKF. The expandability of the eye in childhood myopia. *Curr Eye Res*. 2003;26(2):65–71.
56. McMonnies CW. An examination of the relation between intraocular pressure, fundal stretching and myopic pathology. *Clin Exp Optom*. 2016;99(2):113–119.

57. Shelton L, Rada JS. Effects of cyclic mechanical stretch on extracellular matrix synthesis by human scleral fibroblasts. *Exp Eye Res.* 2007;84(2):314–322.
58. Zhao F, Wu H, Reinach PS, et al. Up-regulation of matrix metalloproteinase-2 by scleral monocyte-derived macrophages contributes to myopia development. *Am J Pathol.* 2020;190(9):1888–1908.
59. Yamaoka A, Matsuo T, Shiraga F, Ohtsuki H. TIMP-1 production by human scleral fibroblast decreases in response to cyclic mechanical stretching. *Ophthalmic Res.* 2001;33(2):98–101.
60. Yuan Y, Li M, To CH, et al. The role of the RhoA/ROCK signaling pathway in mechanical strain-induced scleral myofibroblast differentiation. *Invest Ophthalmol Vis Sci.* 2018;59(8):3619–3629.
61. Xie Y, Ouyang X, Wang G. Mechanical strain affects collagen metabolism-related gene expression in scleral fibroblasts. *Biomed Pharmacother.* 2020;126:110095.
62. Zhang S, Zhang G, Zhou X, et al. Changes in choroidal thickness and choroidal blood perfusion in guinea pig myopia. *Invest Ophthalmol Vis Sci.* 2019;60(8):3074–3083.
63. Jiang R, Wang YX, Wei WB, Xu L, Jonas JB. Peripapillary choroidal thickness in adult Chinese: the Beijing Eye Study. *Invest Ophthalmol Vis Sci.* 2015;56(6):4045–4052.
64. Prousalis E, Dastiridou A, Ziakas N, Androudi S, Mataftsi A. Choroidal thickness and ocular growth in childhood. *Surv Ophthalmol.* 2021;66(2):261–275.
65. Flores-Moreno I, Lugo F, Duker JS, Ruiz-Moreno JM. The relationship between axial length and choroidal thickness in eyes with high myopia. *Am J Ophthalmol.* 2013;155(2):314–319.e1.
66. Jin P, Zou H, Xu X, et al. Longitudinal changes in choroidal and retinal thicknesses in children with myopic shift. *Retina (Philadelphia, Pa.).* 2019;39:1091–1099.
67. Zhou X, Ye C, Wang X, Zhou W, Reinach P, Qu J. Choroidal blood perfusion as a potential “rapid predictive index” for myopia development and progression. *Eye Vis (Lond).* 2021;8(1):1.
68. Liu Y, Wang L, Xu Y, Pang Z, Mu G. The influence of the choroid on the onset and development of myopia: From perspectives of choroidal thickness and blood flow. *Acta Ophthalmol.* 2021;99(7):730–738.
69. Akyol N, Kalkisim A, Turk A, Kola M, Imamoglu HI. Evaluation of the effects on choroidal thickness of bimatoprost 0.03% versus a brinzolamide 1.0%/timolol maleate 0.5% fixed combination. *Cutan Ocul Toxicol.* 2017;36(4):397–403.
70. Chandra S, Muir ER, Deo K, Kiel JW, Duong TQ. Effects of dorzolamide on retinal and choroidal blood flow in the DBA/2J mouse model of glaucoma. *Invest Ophthalmol Vis Sci.* 2016;57(3):826–831.
71. Yoshikawa M, Akagi T, Nakanishi H, et al. Longitudinal change in choroidal thickness after trabeculectomy in primary open-angle glaucoma patients. *Jpn J Ophthalmol.* 2017;61(1):105–112.
72. Chen Z, Xue F, Zhou J, Qu X, Zhou X. Effects of orthokeratology on choroidal thickness and axial length. *Optom Vis Sci.* 2016;93(9):1064–1071.
73. Sander BP, Collins MJ, Read SA. Short-term effect of low-dose atropine and hyperopic defocus on choroidal thickness and axial length in young myopic adults. *J Ophthalmol.* 2019;2019:4782536.
74. Zhou X, Zhang S, Zhang G, et al. Increased choroidal blood perfusion can inhibit form deprivation myopia in guinea pigs. *Invest Ophthalmol Vis Sci.* 2020;61(13):25.