


Contents lists available at [ScienceDirect](http://www.sciencedirect.com)

## International Journal of Surgery Case Reports

journal homepage: [www.casereports.com](http://www.casereports.com)

## A case report of a de Garengeot hernia in a nonagenarian veteran



Luis R. Taveras, Sergio Huerta\*

VA North Texas Health Care System, University of Texas Southwestern, Department of Surgery, Dallas, TX, United States

## ARTICLE INFO

## Article history:

Received 9 September 2017

Accepted 29 October 2017

Available online 3 November 2017

## Keywords:

Femoral hernia

Groin hernia

Appendicitis

Case report

## ABSTRACT

**INTRODUCTION:** A hernia containing the vermiform appendix [de Garengeot hernia (DGH)] is an exceedingly rare event. Appendicitis occurring in this setting is further unusual. Most cases of DGH are made during inguinal exploration. In the present report, we discuss a patient who underwent an operation which revealed a DGH with appendicitis.

**PRESENTATION OF A CASE:** A 94-year-old man with a past medical history significant for hypertension and Parkinson's disease was admitted to the hospital for the management of an event of CHF exacerbation. He developed acute onset of a painful right inguinal bulge. He had no prior hernia history. On physical exam, he had a 3-cm, tender, non-reducible right inguinal bulge without skin changes. Laboratory analyses were normal without leukocytosis. An acute abdominal series was obtained and demonstrated no obstruction. A groin exploration was performed under local anesthetic. An abscess was found associated with a femoral hernia containing the vermiform appendix. An appendectomy was performed through the hernia sac. The hernia was repaired via a McVay technique. At thirty days after his procedure, he had no complications and no signs of recurrence.

**CONCLUSION:** Most cases of DGH are diagnosed intraoperatively. Limited work up might be sufficient for adequate management. Several surgical strategies are acceptable. Groin exploration, plus and minus an appendectomy, and tissue repair versus mesh placement are acceptable surgical strategies. Laparoscopic approach for the management of DGH has been reported.

Published by Elsevier Ltd on behalf of IJS Publishing Group Ltd. This is an open access article under the CC BY-NC-ND license (<http://creativecommons.org/licenses/by-nc-nd/4.0/>).

## 1. Introduction

With over 20 million inguinal hernias performed every year around the world, groin hernias are one of the most common operations performed in the United States by general surgeons [1]. Groin Hernias are also the most common operations performed by general surgeons at the Veteran Affairs (VA) North Texas Health Care System (VANTHCS) [2,3].

Of the two types of groin hernias (inguinal and femoral), hernias of the femoral canal are much less common than inguinal hernias. Femoral hernias are more common in women compared to men, and are more likely to present with complications [4]. Any viscus within the abdominal cavity with proximity to the groin hernia sac has the potential to become part of the hernia contents.

Some hernias with specific bowel contents have been named according to the surgeon who described the entity. For instance, the eponym Littre's hernia refers to a groin hernia that contains a Meckel's diverticulum within the hernia sac, which was named after Alexis de Littre [5]. Similarly, When the appendix is found within the inguinal canal, the hernia is called an Amyand's her-

nia, after Claudius Amyand [6]. A hernia that contains two loops of incarcerated small bowel in a "W" configuration is called a Maydl's hernia, first described by Karel Maydl [7]. Of the many hernias with specific eponyms, the one that contains the appendix within the femoral canal is one of the most uncommon types. This hernia is called a de Garengeot hernia (DGH), named after the French surgeon René-Jacques Croissant de Garengeot who first described it [8]. Owing to its rarity, incidence of DGH is typically reported in terms of case reports rather than the incidence in the general population.

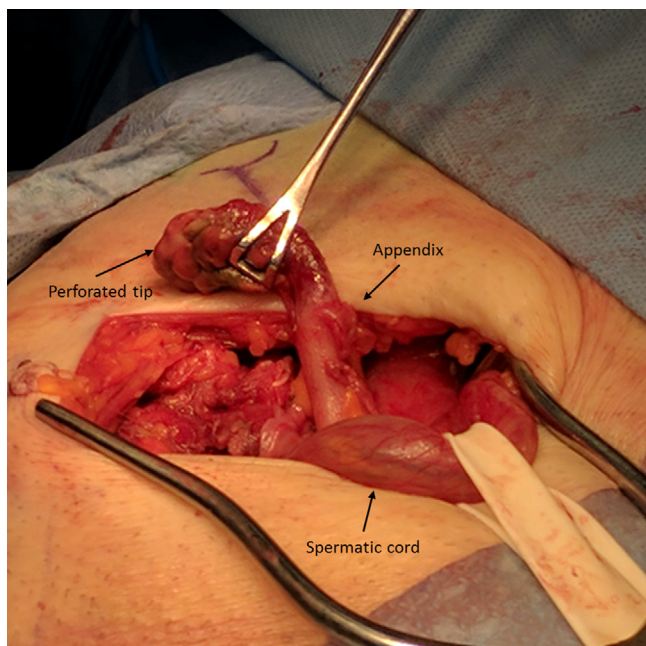
In the present report, we discuss a patient who had a DGH during exploration of the inguinal canal. This case is unusual because it occurred in a nonagenarian male veteran patient. The unique aspect of this case is that it was performed in its entirety under local anesthetic.

## 2. Methods

This is a case report of a patient who presented with this disease at the VA North Texas Health Care System (VANTHCS). The medical records were reviewed for this patient in the computer patient record system. Informed consent was obtained from the patient for the publication of this report. This work has been reported according with the SCARE criteria [9].

\* Corresponding author at: VA North Texas Health Care System, Dallas, TX 75216, United States.

E-mail address: [Sergio.Huerta@UTSouthwestern.edu](mailto:Sergio.Huerta@UTSouthwestern.edu) (S. Huerta).



**Fig. 1.** Groin exploration revealed a femoral defect containing the appendix and tip appendicitis.

### 3. Case report

A 94-year-old Caucasian man with a past medical history significant for hypertension and Parkinson's disease was brought to the Emergency Department by his family with complaints of fatigue. He needed intermittent assistance with daily life activities. He was admitted to the medical service for the management of an acute event of CHF exacerbation. As he improved from his respiratory status, he developed acute onset of a painful right inguinal bulge. He had no prior hernia history. His bowel function was normal.

On physical exam he appeared frail, but in no acute distress. His BMI was 17.6 kg/m<sup>2</sup>. He had no fever and normal vital signs. Examination of his right groin showed a had a 3-cm, tender, bulge without skin changes. Laboratory analysis was normal without leukocytosis. An acute abdominal series was obtained and demonstrated no distention of the bowel and no air fluid levels.

Patient was made nil by mouth; judicious intravenous fluids were administered. A dose of hydromorphone was given and reduction by taxis was attempted. Patient was placed in Trendelenburg with slight hip flexion and abduction. Gentle and sustained pressure was applied to the right groin bulge. Discomfort ensued and no improvement in hernia size was perceived. It was then clear that we were facing an acutely incarcerated groin hernia.

After discussing all options with the patient and his family, the consensus decision was operative intervention with the presumptive diagnosis of an incarcerated inguinal hernia. Informed consent was obtained. A right groin exploration was undertaken under local anesthetic in combination with monitored care anesthesia by the senior author (SH), who is a staff general surgeon at the VANTHCS. An incision was made on the skin overlying the right inguinal canal with a technique previously described for the repair of inguinal herniorrhaphy [3]. Examination of the inguinal canal demonstrated an intact transversalis fascia and no indirect hernia sac within the spermatic cord (Fig. 1).

We then proceeded with examination of the femoral canal. An abscess was encountered and evacuated. Contiguous with the abscess cavity, the hernia sac was encountered. It was necrotic, and contained the distal appendix which was perforated and necrotic (Fig. 1). The sac was opened and this revealed tip appendicitis.

The entire appendix was eviscerated within the femoral canal and amputated at the base with a gastrointestinal stapling device. The hernia sac was then closed. The hernia was repaired using a McVay technique approximating the conjoint tendon to Cooper's ligament. Relaxing incisions were performed. A Penrose drain placed within the abscess cavity and externalized inferiorly in the thigh. The skin was left open to heal by secondary intention.

Pathological examination demonstrated acute appendicitis with transmural necrosis and peri-appendicitis. The patient underwent wound care with wet to dry dressings. He was discharged from the hospital 6 days after the procedure. At the last follow up, 30 days after the operation, he was doing well. The incision was well-healed. He had no complications and no signs of recurrence. Review of the chart at the time of manuscript preparation demonstrated that the patient was doing well at 95-years of age now. No complaints related to his operation were noted. There was no evidence of recurrence five months after the operation.

### 4. Discussion

Hernia surgery constitutes one third of the practice of the senior author of the present report (SH). Over a thirteen-year operative experience with hernia surgery 1153 groin hernias have been performed by the same surgeon. Only one has demonstrated to be a DGH with appendicitis and necrosis leading to abscess formation. A DGH with appendicitis and an abscess has been previously described [10,11]. In contrast to the 81- and 72-year-old women previously reported, our case differs in that our patient was male, nonagenarian, did not have an ultrasound or computed tomography studies, and the entire operation was performed under local anesthetic.

Owing to the higher rate of femoral hernias in women, DGH is one fourth the incidence in men compared to women [12]. Because the Veteran patient population is primarily composed of men, the incidence of both femoral and DGH hernias is much lower [2,3]. A comprehensive review of 36 patients with DGH (8 men and 28 women) showed an average age of 75.5 years with a range of 36–90 years. The patient in the present report is, therefore, on the older side of the spectrum and might be the oldest male patient with a DGH reported today.

Inguinal hernia surgery does not typically rely on pre-operative diagnostic imaging. Previous studies have shown that 31% of patients with a DGH undergo abdominal radiography and 25% had a pre-operative CT [8]. While pre-operative knowledge of an appendix containing femoral hernia might facilitate surgical planning, this strategy might cause a delay in therapeutic interventions. Further, these tests are not always diagnostic [8]. Thus, in the present case, we elected to proceed with groin exploration that incidentally revealed a DGH, which is consistent with most reported cases of a DGH [8].

A unique aspect in the management of this patient was the choice of local anesthetic for the surgical approach. This approach has also been previously reported on a 71-year-old woman [11]. However, most cases of DGH have been performed under general anesthesia [8]. In the experience of the hernia surgeon of the present report, 8% of all groin hernias (n=87) have been successfully performed under local anesthetic. This has included, sliding hernias, incarcerated hernias, femoral hernias, and now DGH with an appendectomy. Thus, in agreement with previous reports [11], we support the feasibility of local anesthetic for the management of DGH especially in older patients with multiple comorbid conditions.

While laparoscopy might be a good option for some patients with DGH if the diagnosis is known preoperatively [13,14], most cases of DGH are made during groin exploration. Further,

laparoscopy limits the use of local anesthetic for the repair. Once the appendix is identified within the femoral canal, reduction is an option if appendicitis is clearly excluded [15]. An appendectomy can be performed through the groin hernia incision in cases of appendicitis [16].

An open repair of the femoral hernia defect has been the most commonly performed strategy with obliteration of the defect by bringing the conjoint tendon to Cooper's ligament and performing relaxing incision over the internal oblique fascia (McVay technique) [8]. This approach is further favored in cases of infection or abscess formation. However, prosthetic mesh has been used in cases when the appendix is reduced rather than amputated [17,18].

## 5. Conclusion

DGH is an usual type of hernia that is typically found incidentally. Pre-operative imaging via US or CT is might be useful, but typically not employed. Local anesthetic is feasible for the repair of DGH. An appendectomy should be performed in cases of appendicitis, but reduction is acceptable without. The McVay technique is the most common repair, but laparoscopy and mesh might be utilized in some cases.

## Conflicts of interest

None of the authors have any interest to disclose.

## Funding source

No funding was provided for the production of this manuscript.

## Ethical approval

Informed consent was obtained from the patient and it is available upon request.

## Consent

Informed consent was obtained from the patient and it is available upon request.

## Author contribution

Luis R. Taveras, M.D.: Drafting, revising of the manuscript and participated in the care of the patient.

Sergio Huerta, M.D.: Drafting, revising of the manuscript and participated in the care of the patient.

## Guarantor

Sergio Huerta, MD.

## References

- [1] A. Kingsnorth, K. LeBlanc, Hernias: inguinal and incisional, *Lancet* 362 (9395) (2003) 1561–1571.
- [2] S. Huerta, T. Pham, S. Foster, E.H. Livingston, S. Dineen, Outcomes of emergent inguinal hernia repair in veteran octogenarians, *Am. Surg.* 80 (5) (2014) 479–483.
- [3] S. Huerta, P.M. Patel, A.A. Mokdad, J. Chang, Predictors of inguinodynia, recurrence, and metachronous hernias after inguinal herniorrhaphy in veteran patients, *Am. J. Surg.* 212 (3) (2016) 391–398.
- [4] U. Dahlstrand, S. Wollert, P. Nordin, G. Sandblom, U. Gunnarsson, Emergency femoral hernia repair: a study based on a national register, *Ann. Surg.* 249 (4) (2009) 672–676.
- [5] T.M. Dunn, W.H. Markgraf, Littre hernia-incarcerated Meckel's diverticulum, *Am. J. Surg.* 103 (1962) 144–145.
- [6] A. Michalinos, D. Moris, S. Vernadakis, Amyand's hernia: a review, *Am. J. Surg.* 207 (6) (2014) 989–995.
- [7] M. Ganesaratnam, Maydl's hernia: report of a series of seven cases and review of the literature, *Br. J. Surg.* 72 (9) (1985) 737–738.
- [8] V. Kalles, A. Mekras, D. Mekras, et al., De Garengeot's hernia: a comprehensive review, *Hernia* 17 (2) (2013) 177–182.
- [9] R.A. Agha, A.J. Fowler, A. Saeta, et al., The SCARE statement: consensus-based surgical case report guidelines, *Int. J. Surg.* 34 (2016) 180–186.
- [10] H. Mashima, M. Banshodani, M. Nishihara, et al., De Garengeot hernia with perforated appendicitis and a groin subcutaneous abscess: a case report, *Int. J. Surg. Case Rep.* 33 (2017) 8–11.
- [11] R.M. Watkins, Appendix abscess in a femoral hernial sac—case report and review of the literature, *Postgrad. Med. J.* 57 (667) (1981) 306–307.
- [12] S.S. Rajan, H.R. Girn, W.G. Ainslie, Inflamed appendix in a femoral hernial sac: de Garengeot's hernia, *Hernia* 13 (5) (2009) 551–553.
- [13] A. Comman, P. Gaetzschmann, T. Hanner, M. Behrend, De Garengeot hernia: transabdominal preperitoneal hernia repair and appendectomy, *JSLs* 11 (4) (2007) 496–501.
- [14] M. Beysens, L. Haeck, K. Vindevoghel, Laparoscopic appendectomy combined with TEP for de Garengeot hernia: case report, *Acta Chir. Belg.* 113 (6) (2013) 468–470.
- [15] H. Sharma, P. Jha, N. Shekhawat, B. Memon, M. Memon, De Garengeot hernia: an analysis of our experience, *Hernia* 11 (3) (2007) 235–238.
- [16] P. Priego, E. Lobo, I. Moreno, et al., Acute appendicitis in an incarcerated crural hernia: analysis of our experience, *Rev. Esp. Enferm. Dig.* 97 (10) (2005) 707–715.
- [17] K. Ebisawa, S. Yamazaki, Y. Kimura, et al., Acute appendicitis in an incarcerated femoral hernia: a case of de garengeot hernia, *Case Rep. Gastroenterol.* 3 (3) (2009) 313–317.
- [18] C. Garcia-Amador, R. De la Plaza, V. Arteaga, A. Lopez-Marcano, J. Ramia, Garengeot's hernia: two case reports with CT diagnosis and literature review, *Open Med. (Wars)* 11 (1) (2016) 354–360.

## Open Access

This article is published Open Access at [sciencedirect.com](https://www.sciencedirect.com). It is distributed under the [IJSCR Supplemental terms and conditions](#), which permits unrestricted non commercial use, distribution, and reproduction in any medium, provided the original authors and source are credited.