

Intraductal radiofrequency ablation plus biliary stent versus stent alone for malignant biliary obstruction: a systematic review and meta-analysis

OPEN
ACCESS

Authors

Matheus de Oliveira Veras¹, Diogo Turiani Hourneaux de Moura¹, Thomas R McCarty², Guilherme Henrique Peixoto de Oliveira¹, Rômulo Sérgio Araújo Gomes¹, Davi Lucena Landim¹, Felipe Giacobbo Nunes¹, Tomazo Antônio Prince Franzini¹, Marcos Eduardo Lera dos Santos¹, Wanderley Marques Bernardo³, Eduardo Guimarães Hourneaux de Moura¹

Institutions

- 1 Gastrointestinal Endoscopy Unit, University of Sao Paulo Hospital of Clinics, Sao Paulo, Brazil
- 2 Internal Medicine, Yale University School of Medicine, New Haven, United States
- 3 Gastroenterology, University of Sao Paulo Hospital of Clinics, Sao Paulo, Brazil

Key words

Strictures, PTCD/PTCS

received 30.7.2023

accepted after revision 24.10.2023

accepted manuscript online 06.11.2023

Bibliography

Endosc Int Open 2024; 12: E23–E33

DOI 10.1055/a-2204-8316

ISSN 2364-3722

© 2024. The Author(s).

This is an open access article published by Thieme under the terms of the Creative Commons Attribution-NonDerivative-NonCommercial License, permitting copying and reproduction so long as the original work is given appropriate credit. Contents may not be used for commercial purposes, or adapted, remixed, transformed or built upon. (<https://creativecommons.org/licenses/by-nc-nd/4.0/>)

Georg Thieme Verlag KG, Rüdigerstraße 14,
70469 Stuttgart, Germany

Corresponding author

Dr. Matheus de Oliveira Veras, University of Sao Paulo Hospital of Clinics, Gastrointestinal Endoscopy Unit, Sao Paulo, Brazil
matheusoveras@icloud.com

Additional material is available at
<https://doi.org/10.1055/a-2204-8316>

ABSTRACT

Background and study aims Recurrent biliary stent occlusion and tumor ingrowth remain a major concern among patients with malignant biliary obstruction (MBO) with significant impact on patient morbidity and survival. Intraductal radiofrequency ablation (RFA) has emerged as a promising treatment that seeks to extend stent patency. This study aimed to evaluate the impact of RFA on overall survival (OS) and stent patency among patients with unresectable MBO.

Methods A comprehensive search of electronic databases was performed for randomized controlled trials (RCTs) comparing RFA plus biliary stent (RFA+S) versus biliary stent alone (S-alone). Outcomes assessed included overall survival, stent patency, and adverse events (AEs) with mean difference (MD) calculated from pooled proportions. Subgroup analyses were performed for hilar strictures and cholangiocarcinoma (CCA).

Results Six RCTs (n=439 patients) were included and demonstrated improved survival among patients who received RFA+S (MD 85.80 days; 95% confidence interval [CI] 35.02–136.58; $I_2=97%$; $P<0.0009$). The pooled MD for total stent patency was 22.25 days (95% CI 17.38–61.87; $I_2=97%$; $P=0.27$). There was no difference in AEs between RFA+S vs S-alone ($P>0.05$). On subgroup analyses, RFA+S was associated with improved stent patency (MD 76.73 days; 95% CI 50.11–103.34; $I_2=67%$; $P<0.01$) and OS (MD 83.14 (95% CI 29.52–136.77; $I_2=97%$; $P<0.01$) for CCA. For hilar strictures, stent patency was improved among patients with RFA+S [MD 83.71 days (95% CI 24.85–142.56; $I_2=84%$; $P<0.01$).

Conclusions RFA+S improved OS in the treatment of MBO when compared with S-alone. Moreover, the RFA therapy prolonged stent patency in hilar strictures and CCA, with similar rates of AEs.

Introduction

Malignant biliary obstruction (MBO) is a condition related to cancer of the biliary tract and extrinsic compression by local extension of adjacent tumors or lymph nodes. The most common causes of MBO are cholangiocarcinoma (CCA) and pancreatic cancer (PC) [1]. The current management of MBO remains a significant challenge for diagnosis and treatment because many patients present with unresectable disease, leading to increased morbidity and mortality [2]. For patients who are not candidates for surgery or transplantation, the bedrock of palliative treatment of MBO involves biliary drainage, accomplished through a combination of therapeutic endoscopy, radiotherapy, and/or chemotherapy.

Searching for less invasive and cost-effective approaches for bile duct decompression, stent placement either endoscopically or percutaneously has proven to be effective for the treatment of MBO. At present, endoscopic biliary decompression and drainage remains the preferred modality for patients with amenable disease [3]. However, despite being a first-line treatment strategy, stent occlusion of biliary stents may occur due to biliary sludge accumulation, stent migration, or tumor ingrowth [4]. Self-expanding metal stents (SEMS) have been shown to reduce the risk of stent occlusion and remain a reasonable treatment option for patients with unresectable disease, due to larger luminal diameter, increased stent patency, and lower reintervention rates [4, 5]. However, in recent years, the development of novel anticancer therapies has increased overall survival among these patients [6], subsequently resulting in a greater incidence of stent occlusion. Given the increased life expectancy with SEMS, newer ablation techniques have emerged in an attempt to prolong stent patency [7].

Intraductal radiofrequency ablation (RFA) is a novel therapy in treatment of MBO. RFA works by promoting coagulation necrosis on the targeted area and, consequently, local control of tumor growth [8]. Given the mechanisms of intraductal RFA, research has been undertaken to determine whether RFA could not only improve survival, but also prolong stent patency [9, 10, 11, 12, 13]. Despite increased adoption of intraductal RFA in advanced endoscopy practice, typically limited to high-volume or tertiary centers, there is a paucity of data and guidelines to suggest its use. Intraductal RFA remains a priority area for investigation by current guidelines and consensus [14, 15]. As such, the primary aim of this study was to perform a structured systematic review and meta-analysis to evaluate the impact of RFA combined with biliary stent placement (RFA+S) on survival and stent patency among patients with MBO.

Methods

Eligibility criteria

This systematic review and meta-analysis was performed in conformity with the Preferred Reporting Items for Systematic Reviews and Meta-Analyses (PRISMA) guidelines [16]. Only randomized controlled trials (RCTs) comparing RFA+S versus biliary stent alone (S-alone) among patients diagnosed with unresectable MBO were included. Studies were searched from in-

ception through January 2023. For inclusion, the study was required to compare the clinical outcomes of interest, including patient survival and stent patency. Patients undergoing oncologic palliative treatment were not excluded.

Search and study selection

All relevant published abstracts and full-text manuscripts of RCTs in English, regardless of year of publication, were included in this systematic review and meta-analysis. For duplicate data, or among studies with the same authors, care was taken to avoid duplication of data and the most recent study was selected for inclusion. Individualized searches of electronic databases (MEDLINE, EMBASE, Central Cochrane and Clinical Trials) were performed based upon a standardized protocol from inception through January 2023. Eligibility evaluation and the selection of screened trials were performed independently in an unblinded standardized fashion by two reviewers. Appendix 1 details the search criteria utilized.

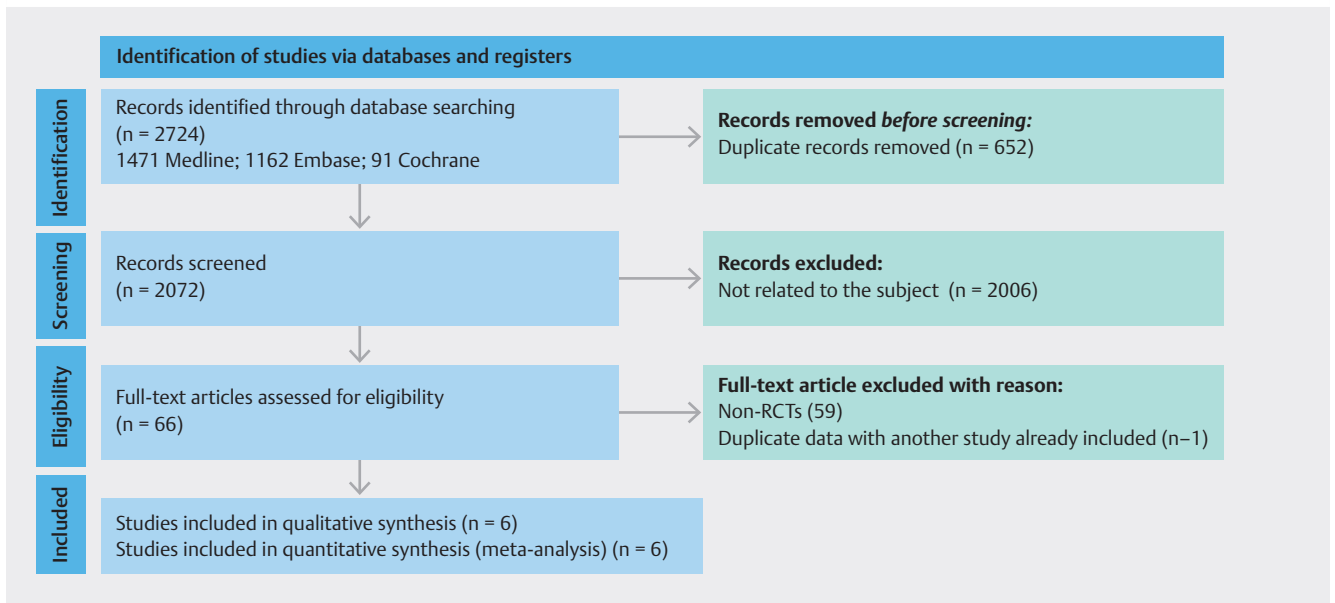
Risk of bias and quality of evidence

The risk of bias was assessed by Revised Cochrane risk-of-bias tool for randomized trials (RoB 2). Each endpoint was classified as high risk, low risk, or some concerns. The quality of evidence was assessed using standards from the Grading of Recommendations Assessment, Development, and Evaluation (GRADE) working group [17], which uses four levels for certainty of evidence: high, moderate, low, and very low.

Measured outcomes

The primary study outcomes were difference in overall survival, defined from enrollment to death, and total stent patency, described as the period from stent insertion to stent occlusion or death (measured in days). Secondary outcomes were 3- and 6-month survival as well as stent patency rates for all MBO etiologies. Additional outcomes included adverse events (AEs) specifically related to biliary drainage performed by endoscopic retrograde cholangiopancreatography (ERCP) within the first 30 days. Types of AEs included mild bleeding, pancreatitis, cholangitis, and acute cholecystitis. Subgroup analyses of survival and stent patency were also conducted according to type of stent performed, strictures due to CCA, and hilar MBO.

Stent occlusion was determined by associated imaging findings of increased proximal biliary duct dilation combined with the presence of lumen obliteration in the stent. Mild post-procedure bleeding was reported when endoscopic therapy could control the event without blood transfusion. Pancreatitis was defined as the serum amylase level higher than the standard limit of three times or more at >24 hours after the operations, combined with the presence of new or worsened abdominal pain. In this study, fever was defined as > 38°C for 24 to 48 hours after surgery and high indicators of infectious disease combined with elevated cholestatic parameters, which were treated as cholangitis.



► **Fig. 1** Flow diagram showing study selection process for meta-analysis.

Statistical analysis and assessment of heterogeneity

In this study, all statistical analyses were performed using Review Manager software (Rev Man 5.4, The Cochrane Collaboration) [18]. Total stent patency and overall survival were meta-analyzed using the inverse variance test and assessed by mean difference (MD). Dichotomous variables were calculated by risk difference (RD), using the Mantel-Haenszel method. All pooled results were calculated using the random-effects model and $P < 0.05$ was considered statistically significant. Absolute numbers, means, and standard deviations were used for the statistical analysis. Stent patency and survival rates reported in months were converted to days. In studies that expressed the results in median and interquartile ranges, mathematical formulas were used for the data conversion. Heterogeneity (inconsistency) was assessed and quantified according to the chi-square (χ^2) and Higgins method. Heterogeneity (I^2) values $> 50\%$ were considered high.

Results

Descriptive results

Study selection and characteristics of included studies

We identified 2724 articles in our initial protocolized search. After removing duplicate records and screening based on eligibility criteria, six RCTs were included in the systematic review and meta-analysis (► **Fig. 1**) [19, 20, 21, 22, 23, 24]. One eligible abstract was excluded because it presented duplicated data in another study already included in the analysis [25]. From selected studies, the number of patients included was 479, in whom RFA+S was performed in 236 patients, while 245 patients were allocated to receive S-alone. ► **Table 1** summarizes individual study data.

Route and stents

Cholangiogram was routinely performed to identify the location, diameter, and length of biliary stricture. Biliary stent placement with or without RFA was performed only endoscopically in four studies [19, 21, 23, 24], percutaneously in one study [22]. One study included both percutaneous and endoscopic biliary stent placement [20]. Three RCTs exclusively used SEMS [20, 22, 24] while two studies utilized plastic stents [19, 21]. In one study, use of both SEMSs and plastic stents was described (► **Table 1**) [23].

Radiofrequency ablation technique

The Habib EndoHBP probe (Boston Scientific) delivered RFA in all studies except one [20], which used an ELRA RF catheter (Taewoong Medical). The whole length of the stricture was ablated in all studies and biliary stents were deployed immediately after the application of RFA in five studies [19, 20, 21, 23, 24]. In one study protocol, the patient first underwent percutaneous cholangiography followed by transhepatic drainage with stent deployment a few days later [22]. Four RCTs [20, 21, 23, 26] recorded stricture length with a mean length of 26.62 mm (SD 6.8). More than one biliary ablation was performed in half of the included studies [19, 21, 23].

Quality of evidence

Risk of bias and quality of evidence

The risk of bias assessed was low in four RCTs [20, 21, 22, 23] and with some concerns in two [19, 24]. RoB-2 is summarized in ► **Fig. 2**. The quality of evidence was assessed by GRADE for each outcome as shown in data highlighted in the Appendix.

► **Table 1** Characteristics of studies and patient demographics.

	Sample (I/C)	Route	Stent	Etiology	Tumor location	Mean age	Adjuvant therapies
Albers D [24] (2022)	86 (42/44)	ERCP	SEMS	CCA (24%) PC (63%) Others (3%)	Distal (63%), middle (23%), proximal (14%)	71.6	CTx (62%)
Kang H [23] (2022)	31 (15/16)	ERCP	Plastic stent + SEMS (3 mo later)	CCA (87%) GBC (13%)	Proximal*	74.0	CTx (33%)
Andrasina T [22] (2021)	76 (36/40)	PTC	SEMS	CCA (60%) PC (17%) GBC (9%) Others (4%)	Proximal (63%) Middle/distal (37%)	65.5	CTx (62%) BT (58%)
Gao DJ [21] (2021)	174 (87/87)	ERCP	Plastic stent (repeat 3 mo later)	CCA (84%) AC (16%)	Distal (73%), proximal† (27%)	68.2	CTx (0.6%) IMT (1.1%)
Kang H [20] (2021)	49 (24/25)	PTBD/ERCP	SEMS	CCA (52%) PC (30%) GBC (10%) Others (8%)	Distal (79%), proximal (21%)	70.0	CTx (69%)
Yang J [19] (2018)	65 (32/33)	ERCP	Plastic stent (repeat every 3 mo)	CCA	Distal (71%), proximal‡ (29%)	63.2	None

ERCP, endoscopic retrograde cholangiopancreatography; PTC, percutaneous transhepatic cholangiography; SEMS, self-expanding metal stent; NM, not mentioned; CCA, cholangiocarcinoma; PC, pancreatic cancer; GBC, gallbladder cancer; CTx, chemotherapy; BT, brachytherapy; IMT, immunotherapy. Proximal = Bismuth I-IV or intrahepatic strictures.

Distal = Ampullary cancer, distal common bile duct strictures.

*This study considered Bismuth type I cholangiocarcinoma as a middle/distal location of biliary stenosis.

†Gao et al did not consider Bismuth type IV as an extrahepatic location.

‡Yang et al excluded Bismuth types III and IV from their study.

Risk-of-bias assessment

Study	D1	D2	D3	D4	D5	Overall
Albers D (2022)						
Kang H (2022)						
Andrasins T (2021)						
Gao DJ (2021)						
Kang H (2021)						
Yang J (2018)						

► **Fig. 2** Risk-of-bias assessment.

Meta-analysis

Survival

Overall survival was reported in five studies [19, 20, 21, 22, 23]. The pooled MD was 85.70 days (95% confidence interval [CI] 34.29 to 137.10; $I^2=98\%$; $P=0.001$) (► **Fig. 3**). The RDs for survival rate after 3 and 6 months between the two groups were -0.01 (95% CI -0.15 to 0.13; $I^2=39\%$; $P=0.9$) and 0.17 (95% CI 0.09 to 0.25; $I^2=0\%$; $P<0.001$), available in three and four RCTs, respectively (► **Fig. 4**).

Survival analysis for patients diagnosed with CCA revealed a MD of 83.14 in favor of RFA+S (95% CI 29.52 to 136.77; $I^2=97\%$; $P=0.002$) (► **Fig. 5**).

Stent patency

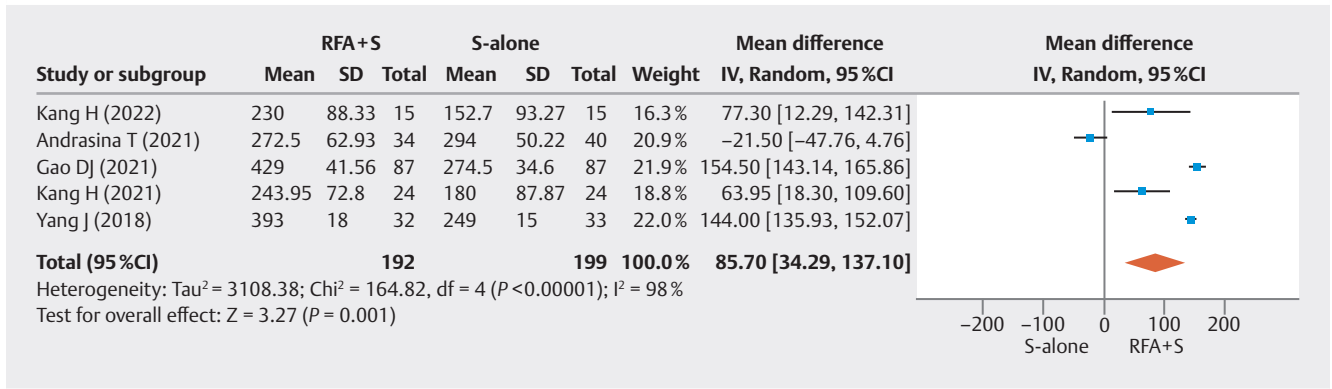
Total stent patency was reported in five studies (► **Fig. 6**). The pooled MD for all MBO etiologies was 22.20 days (95% CI -17.24 to 61.63; $I^2=97\%$; $P=0.27$). The RDs for stent patency rate after 3 months (5 RCTs) and 6 months (4 RCTs) between the two groups were 0.04 (95% CI -0.11 to 0.19; $I^2=67\%$; $P=0.56$) and 0.03 (95% CI -0.10 to 0.16; $I^2=51\%$; $P=0.66$), respectively (► **Fig. 7**).

Subgroups analyses based upon type of stent demonstrated non-significant differences for total stent patency for SEMS (24.14 [95% CI -28.08 to 76.36; $I^2=92\%$; $P=0.36$]) and plastic stents (29.71 [95% CI -54.47 to 113.88; $I^2=99\%$; $P=0.49$]) in the treatment of MBO (► **Fig. 8**).

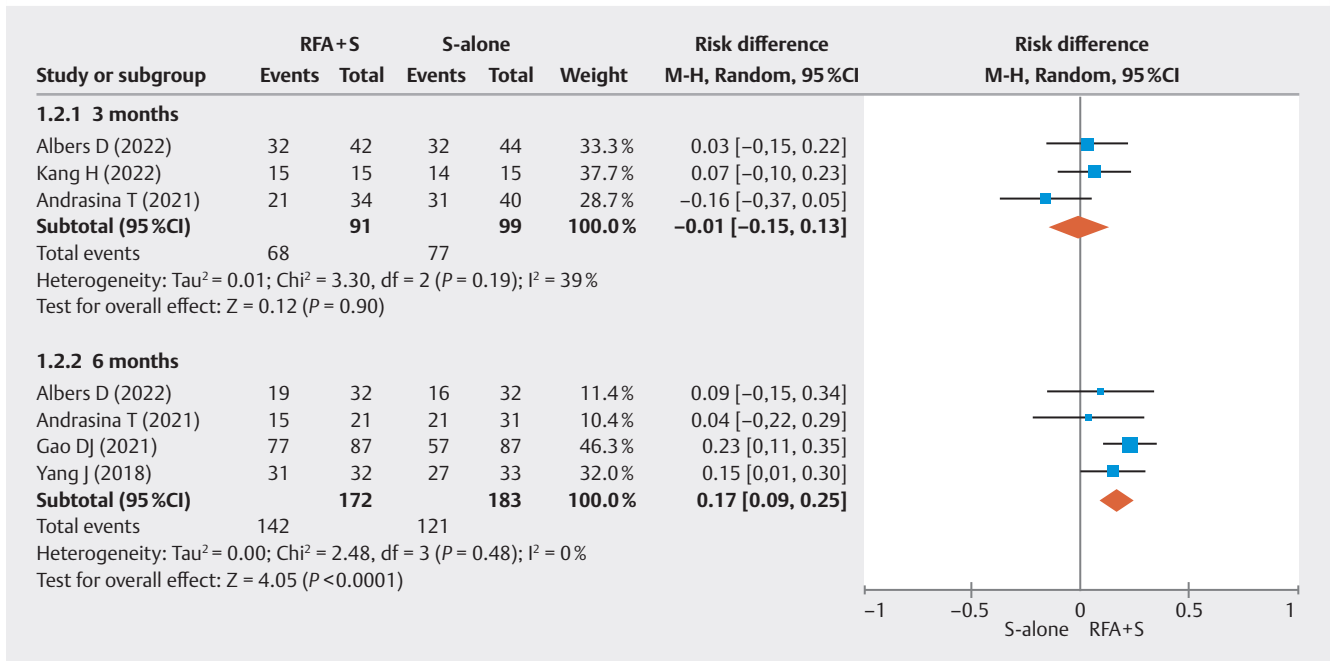
Among patients diagnosed with CCA, there was a MD 76.73 days (95% CI 50.11 to 103.34; $I^2=67\%$; $P<0.001$) in overall stent patency analysis (► **Fig. 9**) and RD of 0.23 (95% CI -0.13 to 0.58; $I^2=81\%$; $P=0.21$) and 0.13 (95% CI 0.02 to 0.23; $I^2=0\%$; $P=0.02$) for stent patency rate after 3 and 6 months, respectively (► **Fig. 10**). For patients with hilar strictures, the MD was 83.71 (95% CI 24.85 to 142.56; $I^2=84\%$; $P=0.005$) and RDs of 0.23 (95% CI -0.13 to 0.58; $I^2=81\%$; $P=0.21$) and 0.13 (95% CI 0.02 to 0.23; $I^2=0\%$; $P=0.02$) for stent patency rate after 3 and 6 months, respectively (► **Fig. 11**, ► **Fig. 12**).

Adverse events

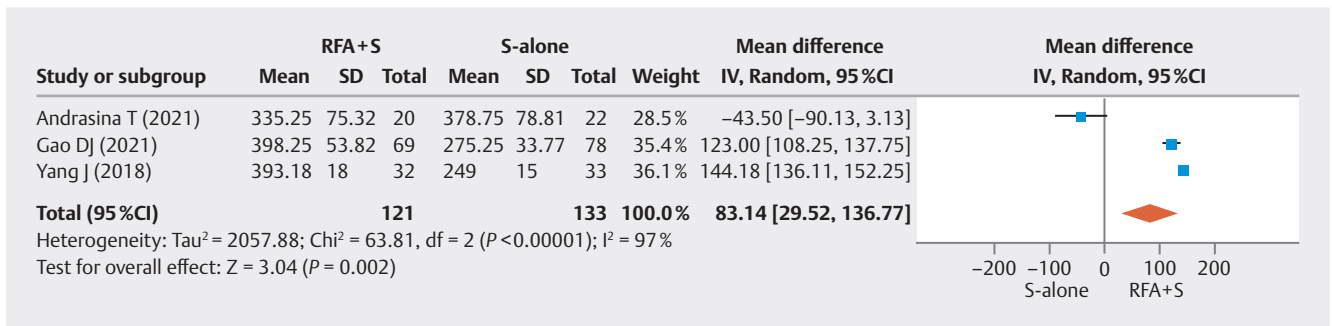
Total AEs specifically related to biliary drainage performed by ERCP were reported in four studies [19, 21, 23, 24]. One study [20] allowed RFA and stent placement through a percutaneous



► Fig. 3 Forest plots: RFA + S vs S-alone – overall survival.

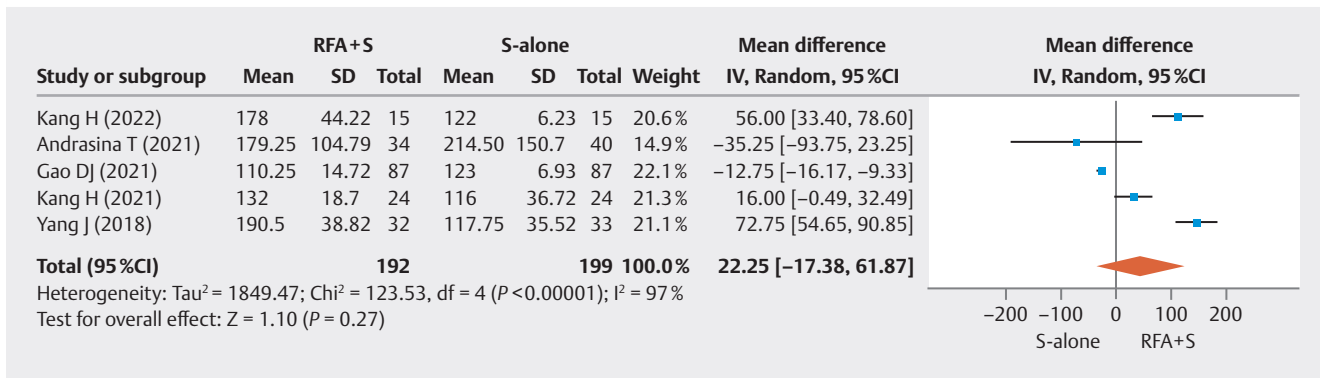


► Fig. 4 Forest plots: RFA + S vs S-alone – 3- and 6-month survival rates.

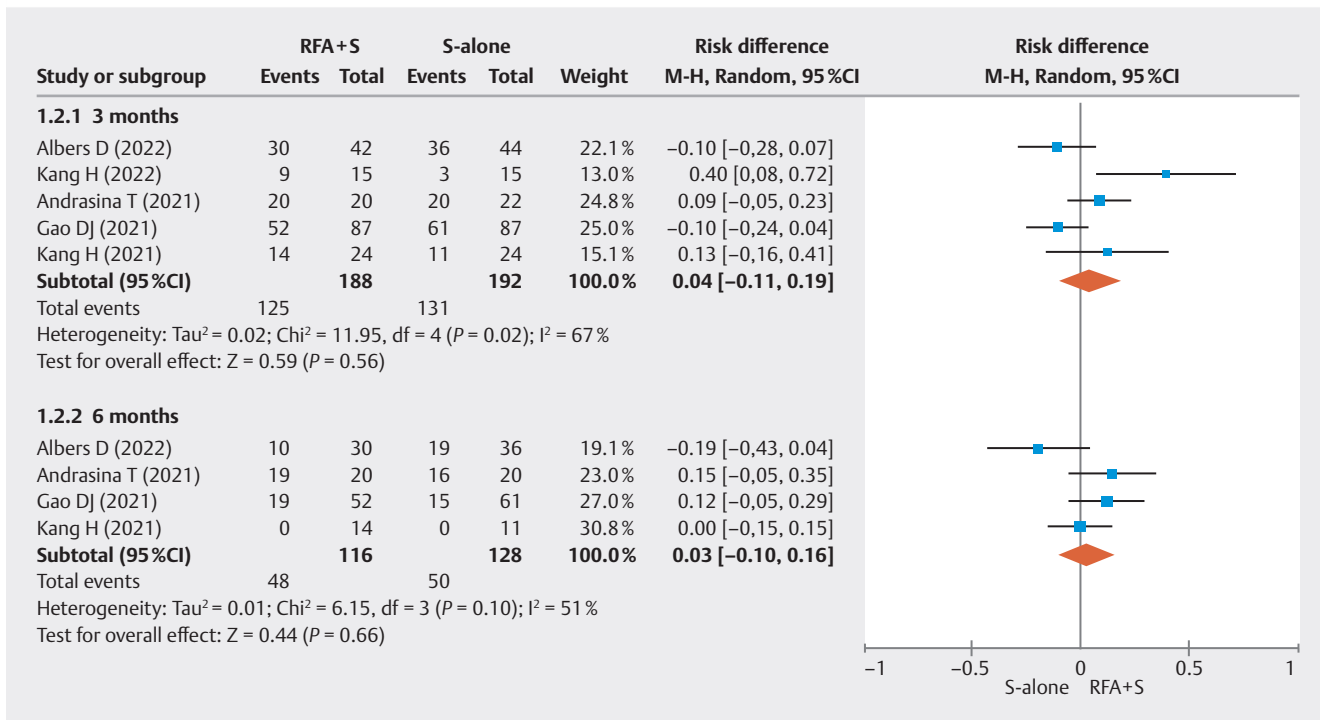


► Fig. 5 Forest plots: RFA + S vs S-alone – overall survival in patients with CCA.

or endoscopic route and was excluded from the quantitative synthesis. The analysis of total events revealed a RD of 0.03 (95% CI -0.05 to 0.011; I² = 27%; P = 0.44)] (► Fig. 13). All AEs are detailed in ► Fig. 14.



► Fig. 6 Forest plots: RFA+S vs S-alone – total stent patency.



► Fig. 7 Forest plots: RFA+S vs S-alone – 3- and 6-month stent patency rates.

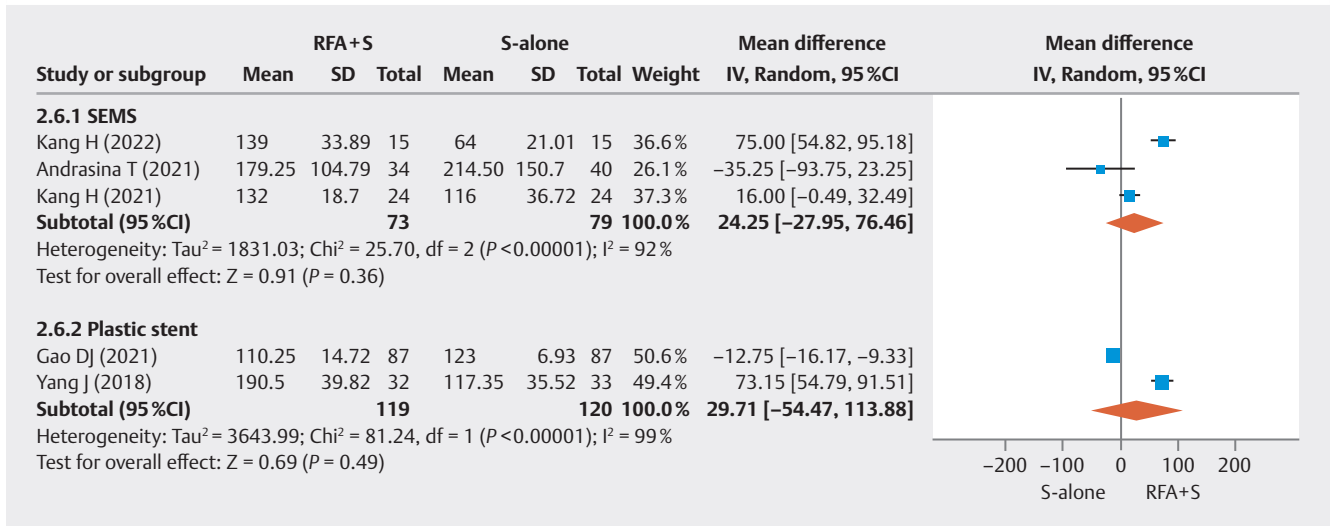
Discussion

This is the first systematic review and meta-analysis of RCTs (Evidence 1A) comparing RFA+S versus S-alone for management of MBO. The results of this study revealed that intraductal RFA was associated with increased overall survival in all patients with MBO, with no difference in adverse events compared to stent alone therapy. Furthermore, RFA combined with a biliary stent demonstrated enhancement of stent patency in patients diagnosed with CCA and/or hilar strictures.

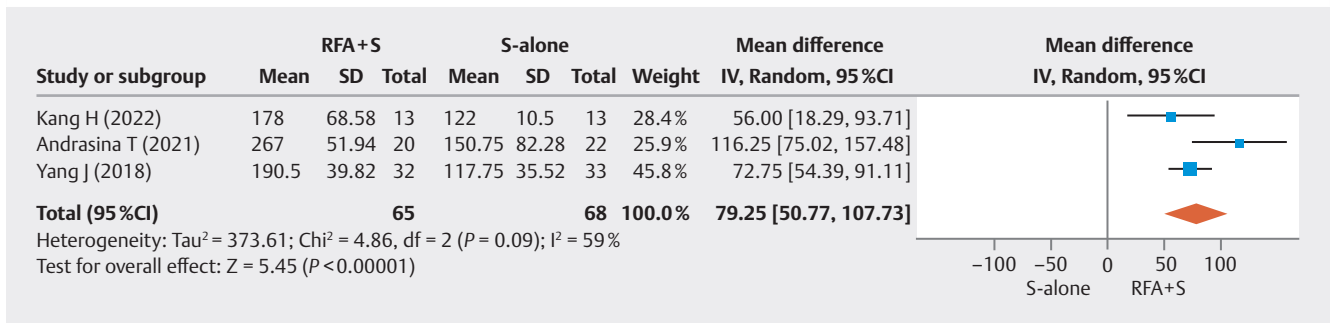
Four previous meta-analyses have investigated stent patency comparing groups with and without RFA; however, there have been discrepant results [27,28,29,30]. In these prior meta-analyses, most eligible studies were observational or retrospective; there were few RCTs, and limited data regarding type of stent utilized, treatment route (endoscopic or percuta-

neous), tumor location, and etiology of MBO. These factors are critically important to accurately assess stent patency, especially when studying such a heterogeneous population. Another meta-analysis included duplicate data, which also limited interpretability of the results [30]. Our current systematic and meta-analysis is strengthened by including only RCTs, and thus, presents the highest evidence level.

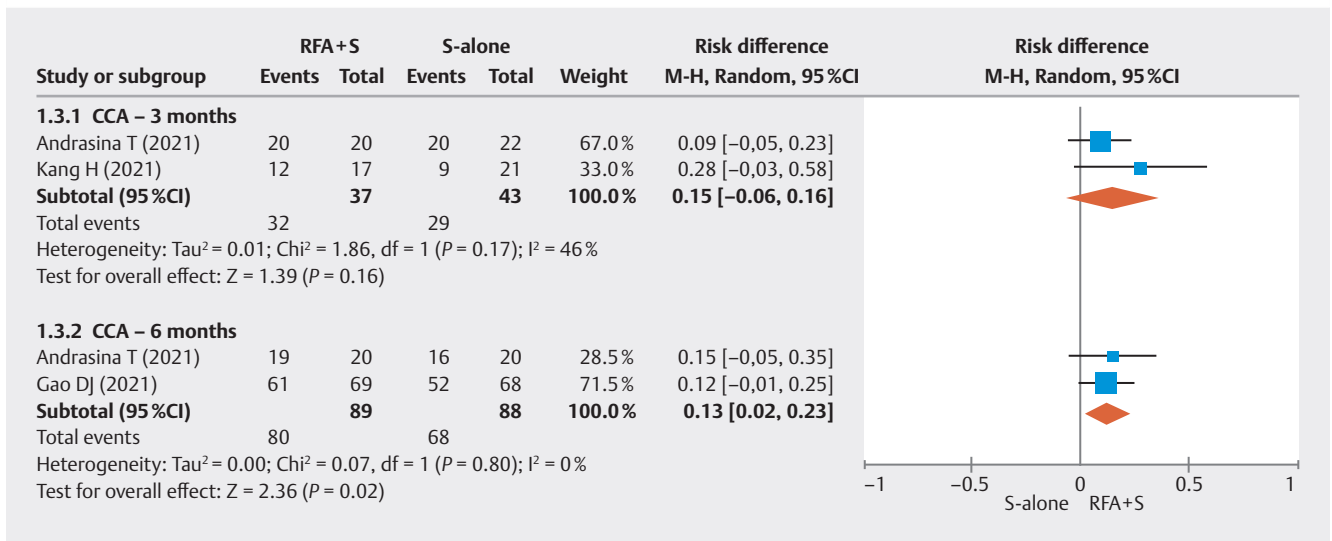
Our analysis demonstrated that RFA+S therapy is not superior in the global assessment of stent patency, regardless of whether examined in the short (3 and 6 months) or long-term. However, the superiority of biliary ablation was found for almost all these outcomes when patients with CCA were investigated. This favorable result has been previously well elucidated and can be explained by the fact that primary biliary tumors emerging from the biliary epithelium offer a better response to local ablation given the direct involvement of the biliary lin-



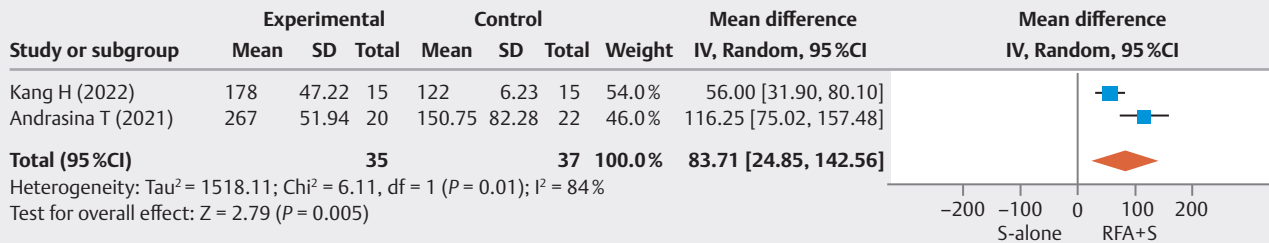
► Fig. 8 Forest plots: RFA + S vs S-alone – stent patency concerning type of stent.



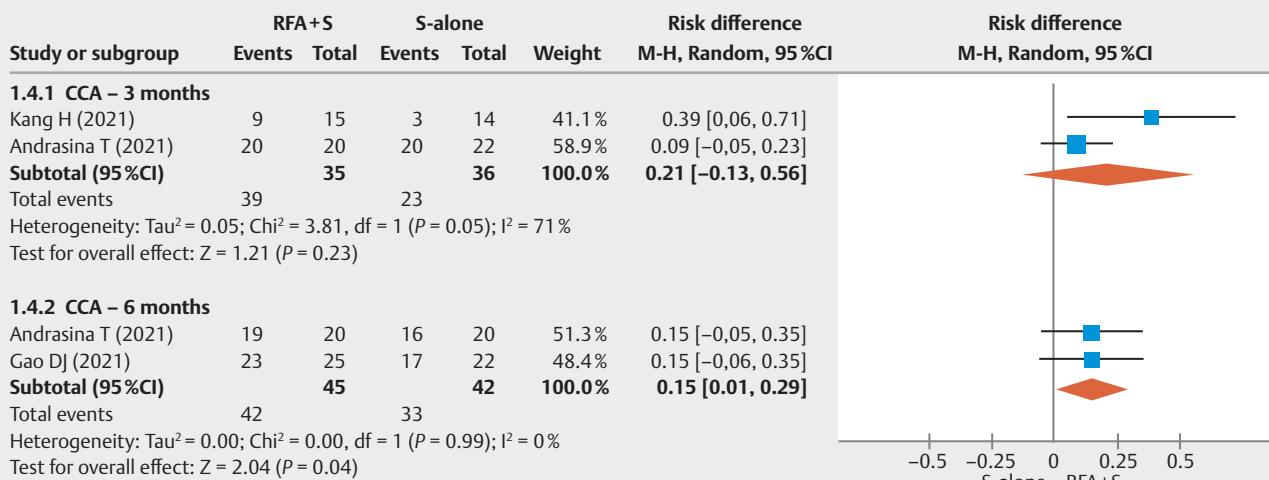
► Fig. 9 Forest plots: RFA + S vs S-alone – stent patency in patients with CCA.



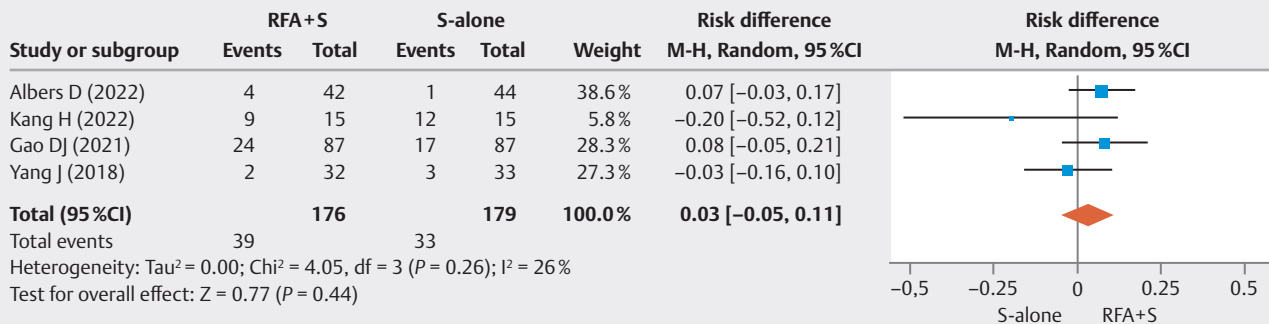
► Fig. 10 Forest plots: RFA + S vs S-alone – 3- and 6-month stent patency rate in CCA.



► Fig. 11 Forest plots: RFA + S vs S-alone – stent patency in patients in hilar strictures.



► Fig. 12 Forest plots: RFA + S vs S-alone – 3- and 6-month stent patency rates in hilar strictures.

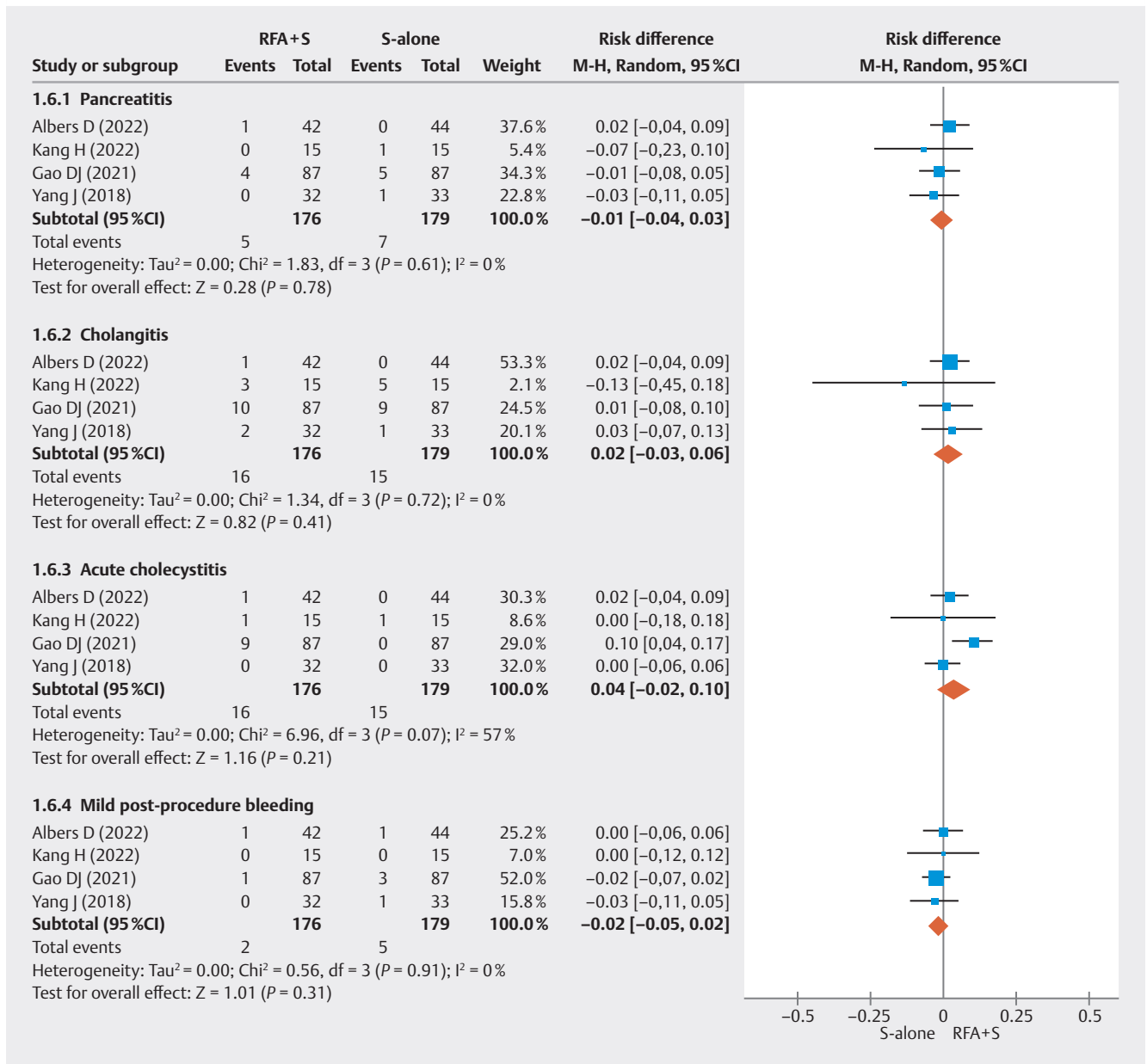


► Fig. 13 Forest plots: RFA + S vs S-alone – total procedure-related AEs in the initial 30 days.

ing. Extrinsic etiologies of MBO may not respond as well given the intraductal nature of ablation. It is known that RFA acts to reduce tumor ingrowth occlusion through direct action (coagulative necrosis) on neoplasm tissue [8]. Although the majority of MBOs in our study were caused by CCA, almost 30% were not, which certainly hindered the possible benefits that could be demonstrated in our global analysis. In addition, for hilar strictures, we investigated the same outcomes as for CCA, and

observed similar benefits for RFA + S. This result only reflects the already mentioned advantage of using RFA according to the etiology of the MBO, because most of the hilar tumors analyzed in this study were CCAs.

Regarding safety, there was no difference in AEs between the two groups, including in pancreatitis, cholangitis, acute cholecystitis, and mild post-procedure bleeding. No procedure-related deaths were reported. Intraductal RFA appeared



► Fig. 14 Forest plots: RFA + S vs S-alone – detailed analysis of AEs.

safe and has been validated in previous studies [28,31], with the most common AE being pancreato-biliary illnesses. However, more novel applications seek to introduce the concept of a new ablation technology, including the tempered-controlled RFA system [20,23], which seeks to reduce overheating injury of the bile duct during ablation, which has been responsible for rare cases of serious complications. Not only the intensity, but also the site of ablation can be a predisposing factor for AEs. Performing intraductal RFA close to the cystic duct implantation area, for example, may cause edema and local injury, leading to an increase in cases of acute cholecystitis [21].

Despite the fact that this meta-analysis included data only from RCTs, it is not without limitations. The overall quality of evidence by GRADE methodology remains low with increased

heterogeneity of the included trials. In addition, multiple stent types, stent sizes, treatment regimens, adjunctive oncological therapies, MBO etiologies, stricture locations, and presence or absence of metastases also make arriving at concrete conclusions difficult. While this may improve generalizability of our results, subgroup analyses were designed to provide stent-, etiology-, and location-specific conclusions. To overcome these limitations, we performed subgroups analyses such as for type of stent, CCA, hilar location, and 3- and 6-month outcomes.

In summary, this study showed the effectiveness of intraductal RFA, especially in relation to CCA. These results suggest an increased role for intraductal RFA to aid in survival for these patients and potential consideration in future guidelines. Current guidelines recommend metal stents in the palliative drain-

age of MBO [1, 4, 15]; however, the decision regarding optimal stent type remains unclear for hilar CCA. While European guidelines suggest a role for uncovered SEMS for hilar strictures [4], plastic stents are typically utilized in the United States, with uncovered stents adopted for select cases [14]. The major concern with uncovered stents remains the risk for obstruction by tumor ingrowth, resulting in recurrent cholangitis. For this reason, some groups have opted for new therapy modalities using plastic or intraductal papillary stents [32, 33]. RFA has great potential in this regard, with results that demonstrated improved stent patency and improved patient survival.

Conclusions

Combining RFA + S improved overall survival in the treatment of MBO when compared with S-alone. Moreover, intraductal ablation therapy prolonged stent patency in patients with hilar strictures and CCA, with similar rates of AEs. The results of our meta-analysis, including only RCTs, demonstrate the efficacy of this therapy and suggest an increased role and further adoption of this novel technology.

Acknowledgement

I would like to express my deepest gratitude to God, my family, and my wife for their unwavering support throughout this journey. Additionally, I extend my heartfelt appreciation to the faculty of the Hospital das Clínicas at the University of São Paulo for their invaluable guidance and expertise. Your collective contributions have been instrumental in the realization of this endeavor.

Conflict of Interest

Dr. Diogo Turiani Hourneaux De Moura: BariaTek Medical - Advisory Board Member (Consulting fees). This was not relevant to this study. Dr. Eduardo Guimaraes Hourneaux De Moura: Olympus - Consultant (Consulting fees) and Boston Scientific - Consultant (Consulting fees). These were not relevant to this study. The other authors declare no potential conflict of interest.

References

- [1] Adler D, Byrne K. Endoscopic stenting for malignant biliary obstruction. Post TW, ed UpToDate Waltham, MA: UpToDate Inc. Accessed March 05, 2023: <https://www.uptodate.com>
- [2] Chandrasekar VT, Faigel D. Diagnosis and treatment of biliary malignancies: biopsy, cytology, cholangioscopy and stenting. *Mini-invasive Surgery* 2021; doi:10.20517/2574-1225.2021.12
- [3] Canakis A, Kahaleh M. Endoscopic palliation of malignant biliary obstruction. *World J Gastrointest Endosc* 2022; 14: 581–596 doi:10.4253/wjge.v14.i10.581
- [4] Dumonceau JM, Tringali A, Papanikolaou IS et al. Endoscopic biliary stenting: Indications, choice of stents, and results: European Society of Gastrointestinal Endoscopy (ESGE) Clinical Guideline - Updated October 2017. *Endoscopy* 2018; 50: 910–930 doi:10.1055/a-0659-9864
- [5] Zorrón Pu L, De Moura EGH, Bernardo WM et al. Endoscopic stenting for inoperable malignant biliary obstruction: A systematic review and meta-analysis. *World J Gastroenterol* 2015; 21: 13374–13385
- [6] Yan X, Zou H, Lai Y et al. Efficacy and safety of first-line targeted treatment and immunotherapy for patients with biliary tract cancer: a systematic review and meta-analysis. *Cancers (Basel)* 2022; 15: 39
- [7] Weismüller TJ. Role of intraductal RFA: a novel tool in the palliative care of perihilar cholangiocarcinoma. *Visc Med* 2021; 37: 39–47 doi:10.1159/000513970
- [8] Inoue T, Yoneda M. Updated evidence on the clinical impact of endoscopic radiofrequency ablation in the treatment of malignant biliary obstruction. *Digest Endosc* 2022; 34: 345–358 doi:10.1111/den.14059
- [9] Sharaiha RZ, Natov N, Glockenberg KS et al. Comparison of metal stenting with radiofrequency ablation versus stenting alone for treating malignant biliary strictures: Is there an added benefit? *Dig Dis Sci* 2014; 59: 3099–310
- [10] Liang H, Peng Z, Cao L et al. Metal stenting with or without endobiliary radiofrequency ablation for unresectable extrahepatic cholangiocarcinoma. *J Cancer Ther* 2015; 06: 981–992
- [11] Oh D, Chong J, Song TJ et al. The usefulness of endobiliary radiofrequency ablation before metal stent placement in unresectable malignant hilar obstruction. *J Gastroenter Hepatol (Australia)* 2022; doi:10.1111/jgh.15967
- [12] Xia MX, Wang SP, Yuan JG et al. Effect of endoscopic radiofrequency ablation on the survival of patients with inoperable malignant biliary strictures: A large cohort study. *J Hepatobiliary Pancreat Sci* 2022; 29: 693–702
- [13] Inoue T, Naitoh I, Kitano R et al. Endobiliary radiofrequency ablation combined with gemcitabine and cisplatin in patients with unresectable extrahepatic cholangiocarcinoma. *Curr Oncology* 2022; 29: 2240–2251
- [14] Qumseya BJ, Jamil LH, Elmunzer BJ et al. ASGE guideline on the role of endoscopy in the management of malignant hilar obstruction. *Gastrointest Endosc* 2021; 94: 222–234.e22
- [15] Nakai Y, Isayama H, Wang HP et al. International consensus statements for endoscopic management of distal biliary stricture. *J Gastroenterol Hepatol (Australia)* 2020; 35: 967–979 doi:10.1111/jgh.14955
- [16] Moher D, Shamseer L, Clarke M et al. Preferred reporting items for systematic review and meta-analysis protocols (PRISMA-P) 2015 statement. *Revista Espanola de Nutricion Humana y Dietetica* 2016; 20: 148–160 doi:10.1186/2046-4053-4-1
- [17] GRADEpro GDT: GRADEpro Guideline Development Tool Software. McMaster University and Evidence Prime, 2023. Accessed January 01, 2000: <https://grade.pro>
- [18] The Cochrane Collaboration. Review Manager (RevMan) Computer program. Version 5.4. 2020: doi:10.4103/jips.jips_158_21
- [19] Yang J, Wang J, Zhou H et al. Efficacy and safety of endoscopic radiofrequency ablation for unresectable extrahepatic cholangiocarcinoma: A randomized trial. *Endoscopy* 2018; 50: 751–760 doi:10.1055/s-0043-124870
- [20] Kang H, Chung MJ, Cho IR et al. Efficacy and safety of palliative endobiliary radiofrequency ablation using a novel temperature-controlled catheter for malignant biliary stricture: a single-center prospective randomized phase II TRIAL. *Surg Endosc* 2021; 35: 63–73 doi:10.1007/s00464-020-07689-z
- [21] Gao DJ, Yang JF, Ma SR et al. Endoscopic radiofrequency ablation plus plastic stent placement versus stent placement alone for unresectable extrahepatic biliary cancer: a multicenter randomized controlled trial. *Gastrointest Endosc* 2021; 94: 91–100.e2
- [22] Andrasina T, Rohan T, Panek J et al. The combination of endoluminal radiofrequency ablation and metal stent implantation for the treat-

- ment of malignant biliary stenosis - Randomized study. *Eur J Radiol* 2021; 142: doi:10.1016/j.ejrad.2021.109830
- [23] Kang H, Han SY, Cho JH et al. Efficacy and safety of temperature-controlled intraductal radiofrequency ablation in advanced malignant hilar biliary obstruction: A pilot multicenter randomized comparative trial. *J Hepatobiliary Pancreat Sci* 2022; 29: 469–478 doi:10.1002/jhbp.1082
- [24] Albers D, Schmidt A, Schiemer M et al. Impact of endobiliary radiofrequency ablation on biliary drainage in patients with malignant biliary strictures treated with uncovered self-expandable metal stents: a randomized controlled multicenter trial. *Gastrointest Endosc* 2022: doi:10.1016/j.gie.2022.05.022
- [25] Hu B, Gao D-J, Zhang X et al. 21 Endobiliary radiofrequency ablation improve overall survival of cholangiocarcinoma: a multi-center randomized control study. *Gastrointest Endosc* 2016; 83: AB126
- [26] Yang J, Wang J, Zhou H et al. Endoscopic radiofrequency ablation plus a novel oral 5-fluorouracil compound versus radiofrequency ablation alone for unresectable extrahepatic cholangiocarcinoma. *Gastrointest Endosc* 2020; 92: 1204–1212.e1
- [27] Cha BH, Jang MJ, Lee SH. Survival benefit of intraductal radiofrequency ablation for malignant biliary obstruction: A systematic review with meta-analysis. *Clin Endosc* 2021; 54: 100–106 doi:10.5946/ce.2020.254
- [28] Sofi AA, Khan MA, Das A et al. Radiofrequency ablation combined with biliary stent placement versus stent placement alone for malignant biliary strictures: a systematic review and meta-analysis. *Gastrointest Endosc* 2018; 87: 944–951.e1
- [29] Song S, Jin H, Cheng Q et al. Local palliative therapies for unresectable malignant biliary obstruction: radiofrequency ablation combined with stent or biliary stent alone? An updated meta-analysis of nineteen trials *Surg Endosc* 2022; 36: 5559–5570 doi:10.1007/s00464-022-09181-2
- [30] Khizar H, Hu Y, Wu Y et al. Efficacy and safety of radiofrequency ablation plus stent versus stent-alone treatments for malignant biliary strictures. *J Clin Gastroenterol* 2023; 57: 335–345 doi:10.1097/MCG.0000000000001810
- [31] Zheng X, Bo ZY, Wan W et al. Endoscopic radiofrequency ablation may be preferable in the management of malignant biliary obstruction: A systematic review and meta-analysis. *J Dig Dis* 2016; 17: 716–724 doi:10.1111/1751-2980.12429
- [32] Kanno Y, Ito K, Nakahara K et al. Suprapapillary placement of plastic versus metal stents for malignant biliary hilar obstructions: A multicenter randomized trial. *Gastrointest Endosc* 2023: doi:10.1016/j.gie.2023.03.007
- [33] Kovács N, Pécsi D, Sipos Z et al. Suprapapillary biliary stents have longer patency times than transpapillary stents – a systematic review and meta-analysis. *J Clin Med* 2023; 12: 898 doi:10.3390/jcm12030898