



# Evidence-Based Review of Clinical Diagnostic Tests and Predictive Clinical Tests That Evaluate Response to Conservative Rehabilitation for Posterior Glenohumeral Instability: A Systematic Review

Jasdeep Dhir, PT, MCISc, FCAMPT,<sup>†</sup> Myles Willis, PT, MCISc, FCAMPT,<sup>†</sup>  
Lyn Watson, PT, Prof Doc,<sup>‡</sup> Lyndsay Somerville, PhD,<sup>§</sup> and Jackie Sadi, PT, MSc, FCAMPT\*<sup>†</sup>

**Context:** Posterior glenohumeral instability is poorly understood and can be challenging to recognize and evaluate. Using evidence-based clinical and predictive tests can assist clinicians in appropriate assessment and management.

**Objective:** To review evidence-based clinical diagnostic tests for posterior glenohumeral instability and predictive tests that identify responders to conservative management.

**Data Sources:** A comprehensive electronic bibliographic search was conducted using Embase, Ovid MEDLINE, PEDro, and CINAHL databases from their date of inception to February 2017.

**Study Selection:** Studies were included for further review if they (1) reported on clinical diagnostic tests for posterior or posteroinferior instability of the glenohumeral joint, (2) assessed predictive clinical tests for posterior instability of the glenohumeral joint, and (3) were in English.

**Study Design:** Systematic review.

**Level of Evidence:** Level 4.

**Data Extraction:** Data were extracted from the studies by 2 independent reviewers and included patient demographics and characteristics, index/reference test details (name and description of test), findings, and data available to calculate psychometric properties.

**Results:** Five diagnostic and 2 predictive studies were selected for review. There was weak evidence for the use of the jerk test, Kim test, posterior impingement sign, and O'Brien test as stand-alone clinical tests for identifying posterior instability. Additionally, there was weak evidence to support the use of the painless jerk test and the hand squeeze sign as predictive tests for responders to conservative management. These findings are attributed to study design limitations, including small and/or nonrepresentative samples.

**Conclusion:** Clustering of thorough history and physical examination findings, including the aforementioned tests, may identify those with posterior glenohumeral instability and assist in developing management strategies.

**Keywords:** dislocation; physiotherapy; posterior; shoulder; diagnosis

From <sup>†</sup>School of Physical Therapy, University of Western Ontario, London, Ontario, Canada, <sup>‡</sup>LifeCare Prahran Sports Medicine Centre and Melbourne Orthopaedic Group, South Yarra, Victoria, Australia, and <sup>§</sup>Department of Surgery, University of Western Ontario, London, Ontario, Canada

\*Address correspondence to Jackie Sadi, PT, MSc, FCAMPT, Field Leader of the MCISc (manipulative therapy field), School of Physical Therapy, Elborn College, Room 1588, University of Western Ontario, London, Ontario N6G 1H1, Canada (email: jsadi2@uwo.ca).

The authors report no potential conflicts of interest in the development and publication of this article.

DOI: 10.1177/1941738117752306

© 2018 The Author(s)

Posterior shoulder instability (PI) is less common than anterior instability. PI accounts for approximately 2% to 10% of all glenohumeral (GH) instability cases.<sup>2-5,17,19,28</sup> Presentation can often be vague, and given the overall lower incidence, when compared with other more common shoulder pathologies, it is a clinical diagnosis that is often overlooked.<sup>26</sup> A more recent study looking at a young, athletic population found that the incidence of PI and combined instability could be as high as 40%.<sup>29</sup> This evidence suggests the need to develop strategies to interpret and combine diagnostic tests and subjective history to aid in the clinical diagnosis of PI and to establish pathways for management.<sup>7,22,26,31</sup>

Several anatomical features contribute to the stability of this mobile joint.<sup>8,9,24,30,34</sup> Efficient contribution from all dynamic and static stabilizers is vital in ensuring stability of the GH complex.<sup>8,9,18,24,30,34</sup>

GH retroversion is one risk factor that has been identified in the development of PI.<sup>6,10,13,20,25</sup> Additionally, individuals engaging in activities and tasks such as overhead throwing, swimming, volleyball, football, tennis, and weightlifting are at an increased risk of PI.<sup>22,26,27,31</sup> These sports involve activities that consistently place the shoulder in flexion, adduction, and internal rotation and/or involve applied longitudinal or direct stress to the shoulder posteriorly.<sup>7,22,23,31</sup>

To date, no gold standard testing method has been established in the diagnosis of PI. Extrapolation of the literature can lead clinicians to believe that arthroscopic evaluation may be the best reference test; however, the need to identify key subjective findings and clinical tests that assist in a diagnosis may be more efficient.<sup>14,18</sup>

Given the myriad of structures that contribute to stability of the posterior GH joint, successful clinical diagnosis relies on a combination of patient history, physical examination, and symptom presentation.<sup>11,26</sup> Taking into account the possible increased prevalence of posterior shoulder instability,<sup>29</sup> especially in the young, athletic population, the aim of this article is to systematically search and review the available literature to identify evidenced-based clinical tests that could be used in the diagnosis of PI. In addition, we aimed to evaluate predictive clinical tests that could be used to identify those patients with PI who are likely to respond to conservative management.

## METHODS

### Literature Search

A comprehensive electronic bibliographic search was conducted using Embase, Ovid MEDLINE, PEDro, and CINAHL databases from their date of inception to February 2017. We used database-appropriate search terms to identify relevant articles involving diagnosis of posterior or posteroinferior shoulder instability. When appropriate, we modified the search terms and included specific known diagnostic test names to optimize the search strategy in individual databases. The search was limited to studies involving humans and to articles published in the

English language. We reviewed the reference lists of potentially relevant articles and previously published reviews to ensure robustness of the initial search. The specific search strategy is listed in Figure 1.

### Study Selection

Two pairs of independent examiners screened the titles and abstracts of studies retrieved from the database search. We included studies for further review if they (1) reported on clinical diagnostic tests for posterior or posteroinferior instability of the GH joint, (2) assessed predictive clinical tests for posterior instability of the GH joint, and (3) were in English. All studies meeting the inclusion criteria, or marked uncertain, were obtained in full text and independently reviewed using the same criteria. Any discrepancies with respect to inclusion or exclusion between the reviewers were debated and, if consensus could not be reached, a third reviewer was available for final determination. An unweighted kappa was calculated for the titles, abstracts, and final full-text articles. The systematic review process is outlined in Figure 1.

### Risk of Bias Appraisal Tools

The internal validity of the eligible diagnostic studies was assessed using the modified QUADAS-2 (see Table A1 in the Appendix, available in the online version of this article). This tool appraised 4 bias domains: patient selection, index test, reference test, and flow and timing (see Appendix 1, available online). The domains of the tool were assessed with 1 to 3 signaling questions that were rated as low, high, or unclear risk of bias. Based on the answers to these questions, the overall risk of bias for the entire study was assessed using the same scale.

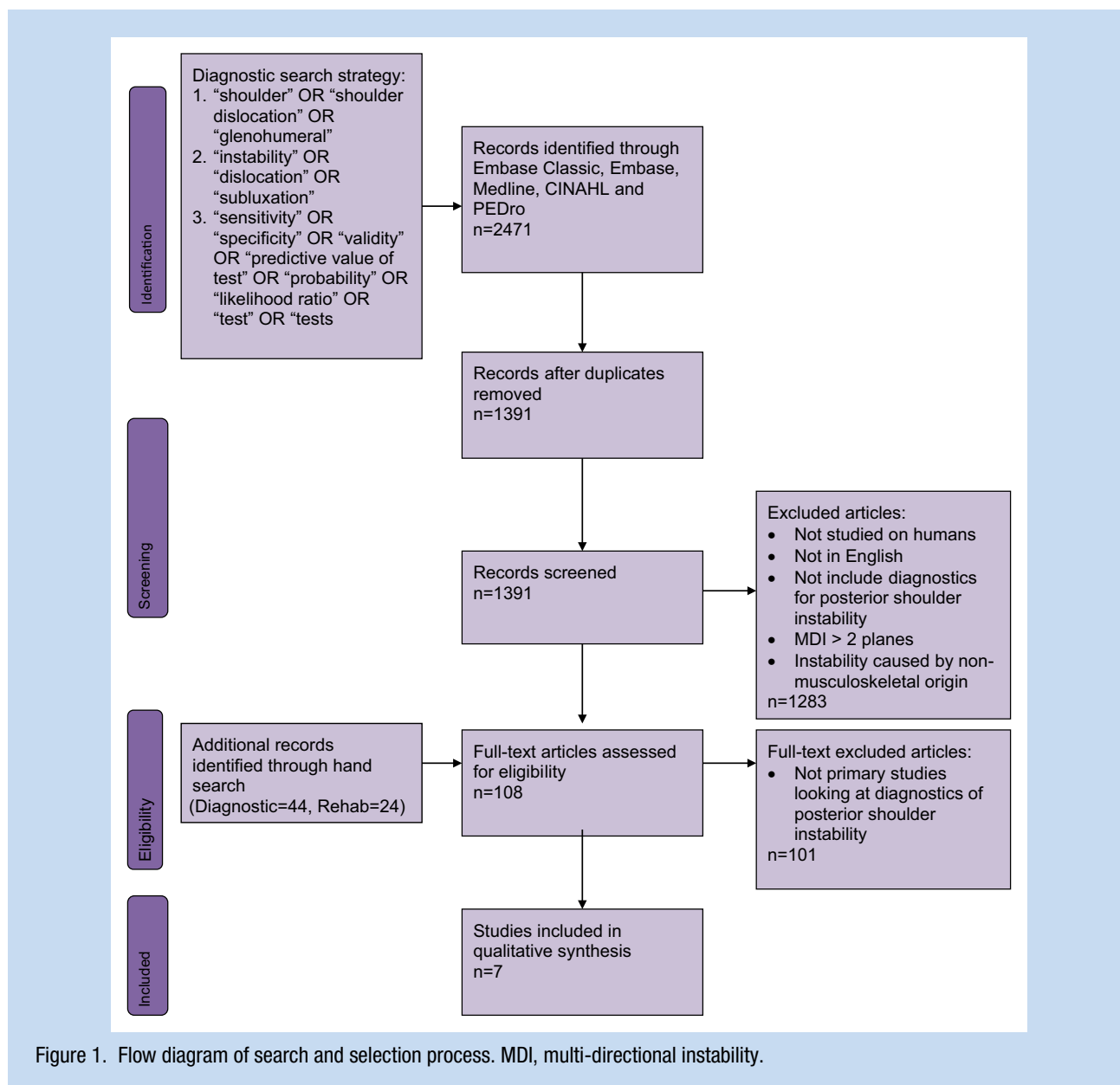
All reviewers completed a training session for the risk of bias assessment tool to standardize the interpretation of the tool.

### Data Extraction

Two reviewers independently extracted data from eligible studies. Author names, study title, journal name, issue, and page numbers were collected for each article. Data extracted from the studies included patient demographics and characteristics, index/reference test details (name and description of test; see Appendix 2, available online), findings, and data available to calculate psychometric properties (see Table A2 in the Appendix, available online). Disagreements were resolved by consensus or communication with a third party.

## RESULTS

The initial search strategy yielded 1391 articles. Screening of titles and abstracts reduced the initial search to 108 articles. After full-text review, 7 diagnostic and predictive studies were considered eligible and were included in the systematic review. The unweighted kappa for the entire article selection process was 0.75.



### Risk of Bias Appraisal Tools

Of the 7 included studies, 3 had a high risk of bias, 1 had a low risk of bias, and 3 were unclear based on the adapted QUADAS-2 (see Table A1 in the Appendix, available online). Reviewer agreement was high for the individual domain scores for each study, with complete agreement on the overall risk of bias on all 7 included studies. None of the studies had a low risk of bias for all 4 domains.

### Data Extraction

These studies show that there is weak evidence to support the clinical diagnosis of PI using the tests evaluated (see Table A2 in the Appendix, available online). Of the 7 studies, 5 evaluated

specific diagnostic tests for PI.<sup>1,14,18,21,33</sup> Kim et al<sup>14</sup> evaluated the jerk and Kim tests. Both the jerk and the Kim test were determined to have good psychometric properties. The Kim test was found to have a sensitivity of 80% and specificity of 94%. The reported diagnostic accuracy for the jerk test was a sensitivity of 73% and specificity of 98%. When the 2 tests were used in combination, the sensitivity increased to 97%. Two studies evaluated the prognostic application of the clinical tests that would identify cohorts of patients, with a diagnosis of PI, who would respond well to conservative management.<sup>15,32</sup> Kim et al<sup>15</sup> reported that patients who presented with a painful jerk test had a higher failure rate to nonoperative care, and Von Tongel et al<sup>32</sup> reported that a positive hand squeeze test may be used to predict a patient's success with conservative management.

A summary of the 7 studies including results and clinical utility is provided in Table A2 in the Appendix (available online).

## DISCUSSION

The methodological quality of the included studies is extremely low, and this limits both the strength and the clarity of our recommendations.

Amadi et al<sup>1</sup> used a computational model to evaluate stresses on the structures of the GH joint, thus restricting its applicability. The findings from this study looked solely at the strain imparted to the anatomical structures in the absence of patient symptoms, which can limit its clinical application. The Kim and jerk tests were demonstrated to have good clinical utility.<sup>14,15</sup> However, the patients included in those studies were predetermined to be surgical candidates, thereby increasing the risk of selection bias and possible inflated test sensitivity.

The posterior impingement sign has good psychometric properties.<sup>18</sup> Despite limitations with regard to sample population and size, this study showed that this test may be valuable to include in clinical examination, particularly with young, overhead athletes presenting with a noncontact injury.

Von Raebrox et al<sup>33</sup> found the posterior dimple sign was associated with PI; however, this study was underpowered for any strong clinical recommendations. Furthermore, the reference test used in that study was the jerk test, which has not been established as a gold standard in the diagnosis of PI. The control group that was selected may not have been appropriate as a comparison group given that they presented with lower extremity impairments and were not screened for PI with the same reference test.

Owen et al<sup>21</sup> assessed a population using the O'Brien test; these patients were suspected of having posterior labral tear and were scheduled for arthroscopic interventions, which introduced a potential for selection bias. Although information was provided on the timing between the reference and index tests, blinding of the assessors was not adequate and may have affected outcomes. The O'Brien test can have some clinical value, specifically when used in a young, noncontact population in overhead athletics with a high incidence of posterior labral tears.

The majority of cases within the studies in this systematic review were reported from secondary and tertiary centers, which are likely to encounter a population with chronic symptoms. Using these populations may have resulted in inflated psychometric properties. However, these patients may have been included purposely to ensure individuals with the condition.

## CONCLUSION

Given the weak evidence for any single clinical diagnostic test, clinicians must rely on a thorough history, including mechanism of injury and recognition of risk factors. Clustering of the jerk test, Kim test, posterior impingement sign, and O'Brien test may

help paint a clearer clinical picture. This approach may be the best current diagnostic strategy available to clinicians.

Recognized risk factors are pertinent to the clinical diagnosis of PI, including glenoid retroversion,<sup>6,10,13,20,22,25,27</sup> rotator cuff strength,<sup>8,12,26</sup> and GH joint laxity.<sup>16</sup>

## REFERENCES

- Amadi HO, Emery RJ, Wallace A, Bull A. Specificity of clinical examinations for testing glenohumeral ligament integrity: a computational study. *Comput Methods Biomech Biomed Eng*. 2014;17:933-943.
- Antoniou J, Duckworth DT, Hartyman DT 2nd. Capsulolabral augmentation for the management of postero-inferior instability of the shoulder. *J Bone Joint Surg Am*. 2000;82:1220-1230.
- Blomquist J, Solheim E, Liavaag S, Schroder CP, Espehaug B, Havelin LI. Shoulder instability surgery in Norway: the first report from a multicenter register, with 1-year follow-up. *Acta Orthop*. 2012;83:165-170.
- Bottoni CR, Franks BR, Moore JH, DeBerardino TM, Taylor DC, Arciero RA. Operative stabilization of posterior shoulder instability. *Am J Sports Med*. 2005;33:996-1002.
- Boyd HB, Sisk TD. Recurrent posterior dislocation of the shoulder. *J Bone Joint Surg Am*. 1972;54:779-786.
- Bradley JP, Baker CL 3rd, Kline AJ, Armfield DR, Chhabra A. Arthroscopic capsulolabral reconstruction for posterior instability of the shoulder: a prospective study of 100 shoulders. *Am J Sports Med*. 2006;34:1061-1071.
- Bradley JP, Forsythe B, Mascarenhas R. Arthroscopic management of posterior shoulder instability: diagnosis, indications and technique. *Clin Sports Med*. 2008;27:649-670.
- Debski RE, Sakone M, Woo SL, et al. Contribution of the passive properties of the rotator cuff to glenohumeral stability during anterior-posterior loading. *J Shoulder Elbow Surg*. 1999;8:324-329.
- Funk L, Owen JM, Bonner C. Clinical assessment of posterior shoulder joint instability. *J Arthrosc Joint Surg*. 2014;1:53-58.
- Gotschalk MB, Ghasem A, Todd D, Daruwalla J, Xerogeanes J, Karas S. Posterior shoulder instability: does glenoid retroversion predict recurrence and contralateral instability? *Arthroscopy*. 2015;31:488-493.
- Hill AM, Bull AMJ, Richardson J, et al. The clinical assessment and classification of shoulder instability. *Curr Orthop*. 2008;22:208-225.
- Hölscher T, Weber T, Lazorav I, Englert C, Dendorfer S. Influence of rotator cuff tears on glenohumeral stability during abduction tasks. *J Orthop Res*. 2016;34:1628-1635.
- Hurley JA, Anderson TE, Dear W, Andrich JT, Bergfeld JA, Weiker GG. Posterior shoulder instability: surgical versus conservative results with evaluation of glenoid version. *Am J Sports Med*. 1992;20:396-400.
- Kim S, Park J, Jeong W, Shin S. The Kim test: a novel test for postero-inferior labral lesion of the shoulder—a comparison to the jerk test. *Am J Sports Med*. 2005;33:1188-1192.
- Kim S, Park J, Park J, Oh I. Painful jerk test: a predictor of success in nonoperative treatment of postero-inferior instability of the shoulder. *Am J Sports Med*. 2004;32:1849-1855.
- McFarland EG, Campbell G, McDowell J. Posterior shoulder laxity in asymptomatic athletes. *Am J Sports Med*. 1996;24:468-471.
- McLaughlin HI. Posterior dislocation of the shoulder. *J Bone Joint Surg Am*. 1952;24:584-590.
- Meister K, Buckley B, Batts J. The posterior impingement sign: diagnosis of rotator cuff and posterior labral tears secondary to internal impingement in overhead athletes. *Am J Orthop*. 2004;33:412-415.
- Millett PJ, Clavert P, Hatch GF 3rd, Warner JJ. Recurrent posterior shoulder instability. *J Am Acad Orthop Surg*. 2006;14:464-476.
- Nace J, Abboud JA. Hypoplastic glenoid with hyperplastic labrum: a case report. *J Shoulder Elbow Surg*. 2009;18:e17-e20.
- Owen JM, Boulter T, Walton M, Funk L, Mackenzie TA. Reinterpretation of O'Brien test in posterior labral tears of the shoulder. *J Shoulder Surg*. 2015;9:6-8.
- Owens BD, Campbell SE, Cameron KL. Risk factors for posterior shoulder instability in young athletes. *Am J Sports Med*. 2013;41:2645-2649.
- Pagnani MJ, Warren RF. Stabilizers of the glenohumeral joint. *J Shoulder Elbow Surg*. 1994;3:173-190.
- Pollock RG, Bigliani LU. Recurrent posterior shoulder instability: diagnosis and treatment. *Clin Orthop*. 1993;29:85-96.

25. Privitera DM, Siegel EJ, Miller LR, Sinz NJ, Higgins LD. Glenoid version and its relationship to glenohumeral instability and labral tears. *J Shoulder Elbow Surg.* 2016;25:1056-1063.
26. Provencher MT, LeClere LE, King S, et al. Posterior instability of the shoulder: diagnosis and management. *Am J Sports Med.* 2011;39:874-886.
27. Raynor MB, Kuhn JE. Utility of features of the patient's history in the diagnosis of atraumatic shoulder pain: a systematic review. *J Shoulder Elbow Surg.* 2016;25:688-694.
28. Robinson CM, Aderinto J. Recurrent posterior shoulder instability. *J Bone Joint Surg Am.* 2005;87:883-892.
29. Song DJ, Cook JB, Krul KP, et al. High frequency of posterior and combined shoulder instability in young active patients. *J Shoulder Elbow Surg.* 2015;24:186-190.
30. Tannenbaum E, Sekiya JK. Evaluation and management of posterior shoulder instability. *Sports Health.* 2011;3:253-263.
31. Tibone JE, Bradley JP. The treatment of posterior subluxation in athletes. *Clin Orthop Relat Res.* 1993;291:124-137.
32. Van Tongel A, Atoun E, Narvani A, Sforza G, Levy O. The 'hand squeeze' test for posterior 'muscle patterning instability' of the shoulder. *Acta Orthop Belg.* 2013;79:31-35.
33. Von Raebroex A, Campbell B, Ramesh R, Bunker T. The association of subacromial dimples with recurrent posterior dislocation of the shoulder. *J Shoulder Elbow Surg.* 2006;15:591-593.
34. Wang VM, Flatow EL. Pathomechanics of acquired shoulder instability: a basic science perspective. *J Shoulder Elbow Surg.* 2005;14(1 suppl S):2S-11S.

For reprints and permission queries, please visit SAGE's Web site at <http://www.sagepub.com/journalsPermissions.nav>.