

Received: 2018.09.04
Accepted: 2018.10.10
Published: 2018.11.22

Uterus Allo-Transplantation in a Swine Model: Long-Term Graft Survival and Reproductive Function

Authors' Contribution:
Study Design A
Data Collection B
Statistical Analysis C
Data Interpretation D
Manuscript Preparation E
Literature Search F
Funds Collection G

BCE 1 Xiaoli Zhang*
BF 2 Jiajia Liu*
BC 3 Qiuxiang Wu*
ABE 4 Zhongyu Liu
ADG 4 Zhifeng Yan

1 Department of Obstetrics and Gynecology, Chinese People's Armed Police Force (CAPF) General Hospital, Beijing, P.R. China
2 Department of Animal Experiments, First Affiliated Hospital of People's Liberation Army (PLA) General Hospital, Beijing, P.R. China
3 Department of Ophthalmology and Otorhinolaryngology, People's Liberation Army (PLA) 425 Hospital, Sanya, Hainan, P.R. China
4 Department of Obstetrics and Gynecology, People's Liberation Army (PLA) General Hospital, Beijing, P.R. China

* Xiaoli Zhang, Jiajia Liu, and Qiuxiang Wu contributed equally to this article, and they are the co-first authors

Corresponding Authors: Zhongyu Liu, e-mail: liuzhongyudayu@163.com, Zhifeng Yan, e-mail: yanzhifeng2002@163.com
Source of support: Departmental sources

Background: The present study examined the feasibility and safety of allogeneic uterus transplantation (UTx) from a living donor and assessed long-term graft survival and the resumption of reproductive function in a swine model.

Material/Methods: Ten female miniature swine with regular menstrual cycles were used; the animals were either donors or recipients (n=5) depending on the sibling. Retrieval surgery included uterus and uterine arteries together with the anterior branches of the internal iliacs from the living donor; the vaginal canal was cut. After the back-table had been prepared, bilateral internal iliac arteries were anastomosed end-to-side with the external iliac arteries. The transplanted uterus was evaluated based on the arterial blood flow by transabdominal ultrasonography and observed by secondary laparotomy after surgery; estrus recovery was stimulated by mating with a male, and artificial embryo transfer was performed in healing swine.





Results: All 5 pigs revealed successful surgery without any surgical complications, injuries to other organs, or unanticipated vascular injury. All recipients survived for >3 months after the surgery, except pig 5, which died due to uterus necrosis 3 days post-surgery. A 100% surgical success rate and 80% long-term survival rate of the receptor were observed. Pig 2 had temporary estrus resumed, and the artificial embryo was transplanted 3 months after surgery; however, apparent gestation was not found by ultrasonography.

Conclusions: This study evaluated the safety and feasibility of the technology of allogeneic UTx, which was performed only by transplant uterine artery system from living-donor surgery in a swine model. Laboratory animals can show long-term survival and resumed estrous after UTx, which can be monitored by ultrasonography to assess the arterial blood flow of the grafted uterus.

MeSH Keywords: Sterilization, Reproductive • Swine • Translations • Uterus

Abbreviations: **UTx** – uterus transplantation; **AUFI** – absolute uterine factor infertility; **ART** – assisted reproductive technology; **MHC** – major histocompatibility complex

Full-text PDF: <https://www.medscimonit.com/abstract/index/idArt/913051>

 3250  2  4  25



Background

Absolute uterine factor infertility (AUI) is the only major type of female infertility that is still considered untreatable. The major causes of this disease are either congenital absence of the uterus (Mayer-Rokitansky-Küster-Hauser syndrome), hysterectomy at an early age (which is often a life-saving procedure following early-stage cervical cancer or intractable peripartum hemorrhage), and a non-functional uterus due to severe intrauterine adhesions. Based on data from the UK [1], 1: 500 women of reproductive age have UFI, and approximately 3–5% of the general population in North America have UFI, that would correspond to >50 000 women. Available options include surrogacy or adoption; however, surrogacy is illegal in China [2–5], whereas adoption is not as common as in the USA and Europe owing to the traditional Asian culture. Thus, neither of these options suit every woman desiring to produce her own genetic offspring. Recently, uterus transplantation (UTx) has become the first choice for the treatment of AUI, demonstrating successful live births [6]. The purpose of UTx is to provide a uterus and enable live birth from a woman who lacks a uterus or has a defective uterus.

In recent decades, solid organ transplantation has been used in clinical practice and is now an established procedure for several organs. Assisted reproductive technology (ART) has progressed rapidly for live births after *in vitro* fertilization (IVF). Thus, these 2 technologies have contributed to the successful development of the technology of modern human UTx. According to the available data, 13 human UTx procedures have been carried out worldwide: 1 in Saudi Arabia [7], 1 in Turkey [8], 9 in Sweden [6], 1 in China, and 1 in the USA (unpublished data). Of these, a total of 9 UTx were successful, with 4 births of healthy babies [9], and more pregnancies are ongoing with expected deliveries in the first half of 2017 [10–12]. These data were from the Swedish trial; the success of UTx was 46.9% pregnancy, and a 38.1% live birth rate was reported for ART [13].

The potential challenges associated with UTx include surgical techniques, ischemia-reperfusion injury and rejection, delicate surgical techniques with dissection, and vascular anastomosis. The evaluation criteria for the success of UTx are long-term survival and recovery of reproductive function in the transplant animal. The anatomical characteristics of the internal genital organs of the swine differ from those of humans; the bicornis uterus is funicular and tortuous, and is approximately 26 cm in size. Moreover, the anatomical features of the iliac vessels in swine are similar to those of a woman as compared to the lack of the internal iliac vein in cynomolgus monkeys; the uterus allo-transplantation in this species has a low success rate and is less used owing to their small vessels and deep pelvic.

The present study evaluated whether the success of the surgical techniques and arterial vascular supply affects the fertility potential of the uterine allo-transplant in a swine model. Improving the surgical method might improve the survival rate of long-term transplant recipients. In addition, the effects of immunosuppressant drugs administered during allogeneic transplantation were evaluated and the estrus and resumed reproductive function after the operation was examined in the swine.

Material and Methods

Animals

Ten female miniature swine, with regular menstrual cycles, were purchased from a local breeder; the mean body weight of all the animals was 39.54±4.26 kg, and no pregnancy was noted preoperatively. Major histocompatibility complex (MHC) tissue matching was not obtained; however, the animals were either donors or recipients (n=5) depending on whether a sibling was born, in order to reduce the postoperative immune rejection. Swine breeding conditions were as follows: the temperature of the compartment was maintained at 18–22°C, humidity 47–62%, SPF and clean environment, and subjects were monitored for 1–2 weeks before surgery. All animal studies were approved by the Chinese People's Liberation Army PLA Medical School Committee on Ethics and Animal Experiments (No: 2015-D10-09).

Anesthesia protocol

The hair of swine was clipped on the lower abdominal region and food was withdrawn 24 h before the day of surgery. After sedation with intramuscular ketamine (Huamu, Jilin, China) and midazolam (Enhua, Jiangsu, China), 3% pentobarbital sodium (Haling, Shanghai, China) 5 mg/kg was injected. The abdomen was sterilized, the animal was placed in supine position, and vein puncture catheterization was performed. A tracheal tube was inserted with a positive airway pressure breathing machine connected and anesthesia maintained by isoflurane inhalation (0.5–1.5%; Yipin, Hebei, China). All animals received continuous intravenous infusion to compensate the loss of fluid during surgery. Antibiotics, as prophylaxis, were administered from the initiation of the operation and 3 days after surgery.

Surgical procedure

All surgical procedures were performed using sterile techniques, and uterine vascular anastomosis was carried out using surgical micro-instruments. Firstly, the operation was performed on the uterus and major blood vessels for retrieval from the living donor; the isolated uterine tissue was perfused and

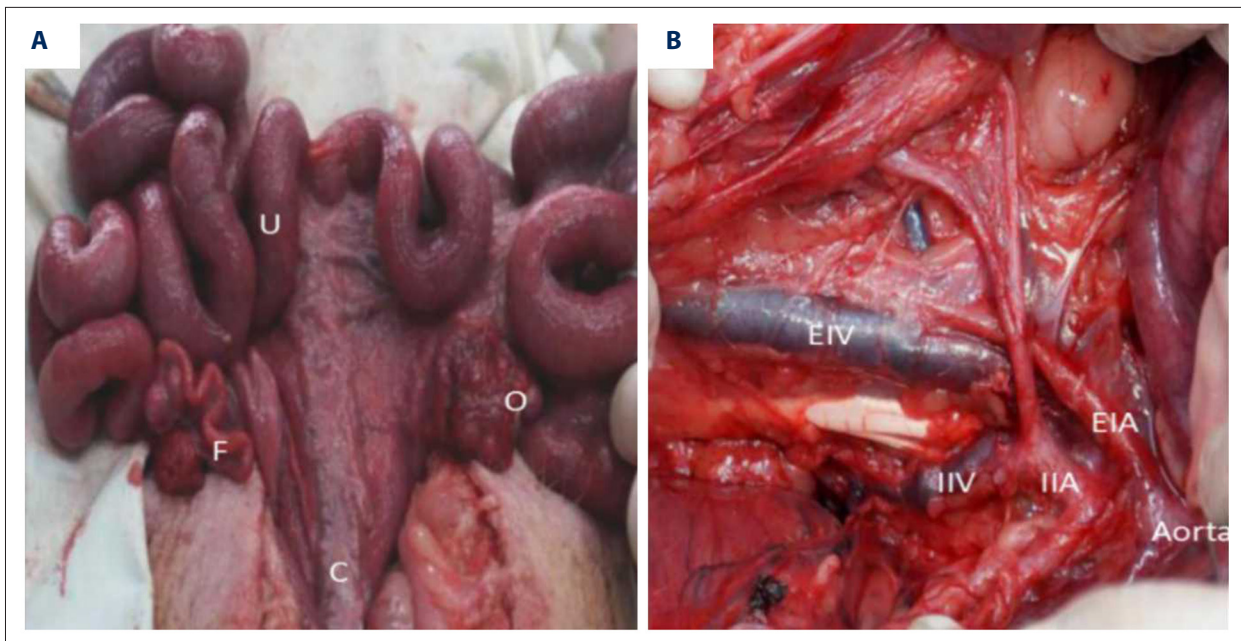


Figure 1. Overview of the anatomical reproduction and iliac vessels in the swine model (**A, B**). U – uterine horn, F – fallopian tube, O – ovary, C – cervical; Aorta – common iliac arteries, EIA – external iliac artery, EIV – external iliac vein, IIA – internal iliac artery, IIV – internal iliac vein.

cold-stored. The recipient was also operated on simultaneously. Uterus retrieval in the living-donor swine showed large total size with long uterine bicornis (Figure 1), small uterine vessels in the deeper pelvic cavity, and the internal iliac arteries and veins began proximally at the bifurcation and extended distally to incorporate the uterine vessels. Alternatively, the uterine veins have several dorsal branches, including the superficial and deep uterine veins, ovarian venous structure, abundant microvasculature, the deep uterine vein inside the deeper pelvic cavity, and the superficial uterine vein running parallel with the uterine artery. An abdominal midline longitudinal incision (from the pubic bone to the level of the second mammary gland) was fashioned by monopole diathermy (40-W power) after general anesthesia. The intestines were packed into the upper abdomen using wet gauze, and the laparotomy incision was held open by a self-retaining retractor. The uterine arteries and internal iliac arteries were selected as vascular grafts in this surgical procedure. The initial steps of the retrieval surgery were the dissection of the bladder peritoneum from the anterior portion of the cervix, followed by separation of the rectum by unipolar diathermy. After identifying the closely associated uterine artery with the superficial uterine vein, the ureter was separated from the uterine artery and vein and detached until bladder influx; the uterine artery and the superficial uterine vein were separated. Then, the surgery was continued on the pelvic sidewall, and the uterine artery bifurcation was divided at around 4–5 cm distal to the level of the internal iliac vessels. Internal iliac arteries were ligated with the branches of the uterine arteries and transected up

to the extension of bifurcation of the internal iliac arteries. Subsequently, the cervical-vaginal was divided by unipolar diathermy at that level. The specimen, including the uterus with a cervical-vaginal rim, uterine artery, or the anterior portions of the iliac arteries, were removed and placed on back-table reparation using sterile 4°C organ preservation solutions.

Cold ischemic storage

After completing all mobilizations, the isolated organ and internal iliac arteries were trimmed by microscopic surgical instruments and stored at 4°C using organ preservation solutions (Shenbao, Changzheng Hospital, China). A perfusion catheter (24-G intravenous needle) was inserted into one femoral artery or internal iliac artery and perfused with 100 mL of cold Shenbao solution via the catheter at 100/60 mmHg pressure.

Recipient surgery

In the recipient, after general anesthesia and laparotomy were prepared, heparin was administered intravenously 10 min before clamping each arterial blood flow in order to prevent thrombosis; methylprednisolone (0.1g/kg) was administered to prevent rejection of the treatment intraoperatively. A total hysterectomy with the uterus and the vaginal canal was performed, and the transplanted uterus was placed in the pelvic cavity of the recipient. The external iliac artery was exposed and dissected free over a distance of about 4 cm, and vascular clamps were placed on both ends of the isolated segments of

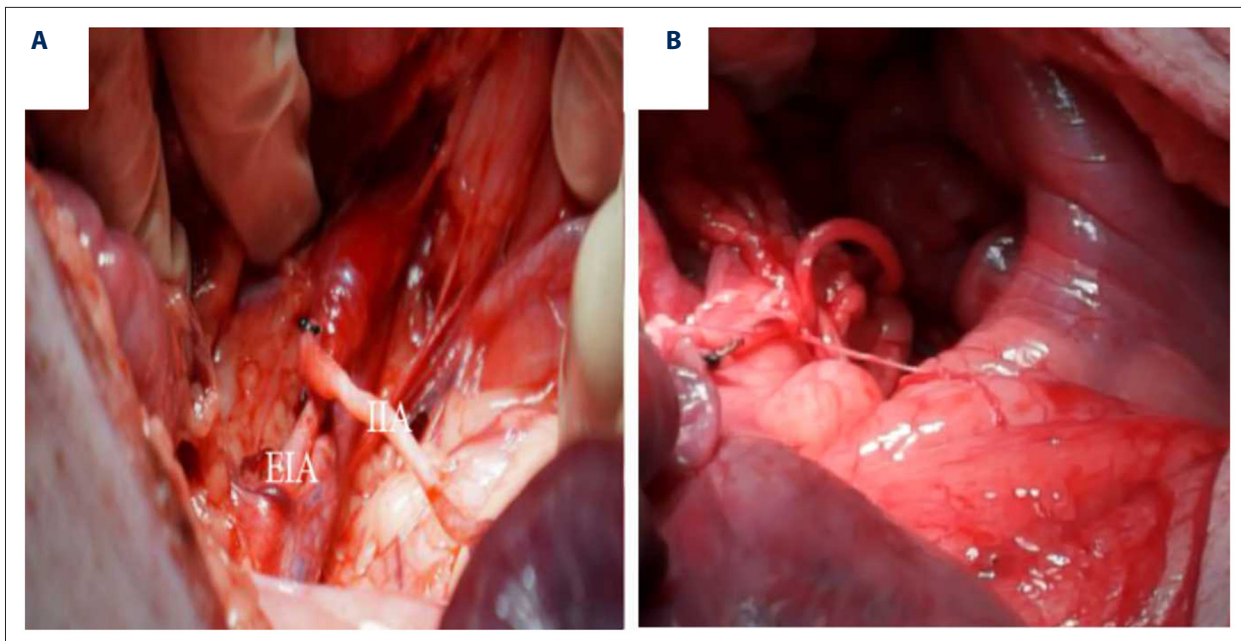


Figure 2. Transplantation of the internal iliac artery end-to-side anastomosis with the external iliac artery from the recipient (A), grafting rapid vascular filling after anastomosis (B).

the external iliac artery. Incisions were made in the external iliac artery of the specimen that was end-to-side anastomosed (Figure 2) by non-continuous sutures (7-0 polypropylene). The clamps were released after the conclusion of all vascular anastomoses, and hemostasis was evaluated; any large leakage was controlled by placing additional sutures. Anastomotic patency and blood flow were assessed by visual inspection of the pulsations of the uterine arteries and color of the uterus. The vaginal cuff was then reattached to the vagina by interrupted sutures (1-0 polyglactin). The vaginal canal was sutured with the residual of the receptor; the uterus was then fixed to the peritoneum and ligaments in order to prevent the prolapsing of the uterus from the mesosalpinx and residual suture (1-0 polyglactin). Adequate uterine blood flow after reanastomosis was judged by pulsations of the uterine arteries and the color of the uterus surface, which altered from whitish to reddish after vessels anastomosis capillary refill of the serosal fluid. The abdomen wand skin was closed with continuous sutures of the fascia (1-0, 3-0 polydioxanone).

Graft follow-up

The duration of surgery, intraoperative organ cold storage and refusion, and vascular anastomosis were evaluated in all animals. Each of the 5 pigs with a transplanted uterus were treated with immunosuppressants and monitored for potential complications post-surgery; a daily record of the appetite, behavior, stool, responsiveness, and heating was maintained. The size and blood flow of the transplanted uterus were determined by transabdominal ultrasonography 1- and 4-weeks

post-surgery and observed by secondary laparotomy under anesthesia after 1 month. In addition, the biopsy of the transplanted uterus was conducted in the event of the death of any of the animals. The biopsies (uterus) were fixed in formaldehyde, embedded in paraffin, sectioned, and stained with hematoxylin and eosin (HE). Five transplanted animals were returned to the breeder for mating, and their heating recovery was monitored 4 weeks after the surgery; the artificial embryo transfer was performed in heating animals.

Immunosuppression

All the animals were administered methylprednisolone 0.1g/kg intravenously on postoperative day (POD) 0 (day 0 indicates the day of surgery) as an induction treatment (Table 1). Mycophenolate mofetil (MMF), cyclosporine (CyA), and methylprednisolone were administered orally in the case of severe rejection. The target trough levels for CyA and MMF up to 1-month post-surgery were planned within the range of 0.1–2 g, respectively, and the dose of methylprednisolone was gradually raised to 0.01 g until the end of observation.

Statistical analysis

Data are expressed as mean \pm SD. The data were compared using SPSS ver. 19, $P < 0.05$ was considered statistically significant.

Table 1. Immunosuppressant therapy project.

Drug	Methods	Dose			
		Intraoperative	1–30 d	30–90 d	90 d–
Induction treatment					
Methylprednisolone	Intravenously	0.5 g	0	0	0
Maintenance treatment					
Mycophenolate Mofetil	Orally	0	1 g, 2/d	1 g, 1/d	0
Cyclosporine	Orally	0	0.1 g, 1/d	0.1 g, 1/d	0
Methylprednisolone	Orally	0	0.05 g, 1/d	0.02 g, 1/d	0.01 g, 1/d
Pulse therapy					
Methylprednisolone	Intravenously	0.5 g/d×3			

Table 2. Uterine transplantation operation time in 5 pigs (n=5, $\bar{x}\pm SD$).

Number	Operation (min)	Retrieval (min)	warm ischemia (min)		Cold ischemia* (min)	Perfusion (min)	Vascular anastomosis (min)	Hemorrhage (ml)
			1*	2*				
UTx1	380	160	5	150	60	20	150	200
UTx2	400	180	5	160	50	15	160	400
UTx3	360	150	5	120	50	15	120	300
UTx4	310	130	5	140	60	20	140	400
UTx5	340	100	5	150	50	20	150	100
Standard	358±34.9	144±30.4	5	144±15.1	54±5.47	18±2.7	144±15.1	280±130.3

* Warm ischemia 1 (donor): ischemia during implantation, from removal of the organ from ice until reperfusion, warm ischemia 2 (recipient): from cold storage to transplant vascular anastomosis finished and re-warm; cold ischemia: from organ retrieval to before vascular anastomosis.

Results

Surgical parameters

Ten animals were used in this study (5 donor and 5 recipients). The details of the operation \pm standard deviation of the uterus transplant and the average time in 5 pigs are summarized in (Table 2). The total average operating time: 358±34.9 min, uterine retrieval time: 144±30.4 min, warm ischemia time 2: 144±15.1 min, cold ischemia time 54±5.47 min, perfusion 18±2.7 min, vascular anastomosis time: 144±15.1 min, and hemorrhage 280±130.3 mL.

Assessment of graft viability

The long-term outcome was evaluated based on the pulsation of the transplanted vessels showing satisfactory intraoperative condition in all pigs. Doppler ultrasonography revealed that the blood flow of both external iliac artery and venous was stable in 4 pigs at 1 and 4 weeks post-surgery. The average peak systolic velocity (PSV) of the bilateral external iliac

artery blood flow was 22.3±1.8 cm/s. Ultrasonography in pig 1 showed flow resistance index (RI) on the right side: 28.8 cm/s, flow resistance index (RI) on the left side: 57 cm/s, PSV: 23.1 cm/s, cervical length: 2.51 cm (Figure 3) 1 week after surgery. Subsequently, pigs 1 and 2 were secondary laparotomies under anesthesia 1 month after surgery that showed normal gross morphology of the graft uterus, as well as, the vascular and vaginal anastomosis sites appeared completely healed with a filled and pulsating uterine artery due to severe adhesion not exposed to external iliac vascular anastomosis (Figure 4).

Overall outcome and fertility

The overall outcome of the 5 pigs used in the present study is summarized. The anastomosis of the bilateral iliac artery was successful, and no surgical complications, including injuries to other organs and unanticipated vascular injury intraoperative, were observed; the animals demonstrated normal eating habits and behaviors postoperatively. Survival was observed for more than 3 months after surgery in 4/5 transplanted pigs. Taken together, the surgical success rate was 100%, and the recipient

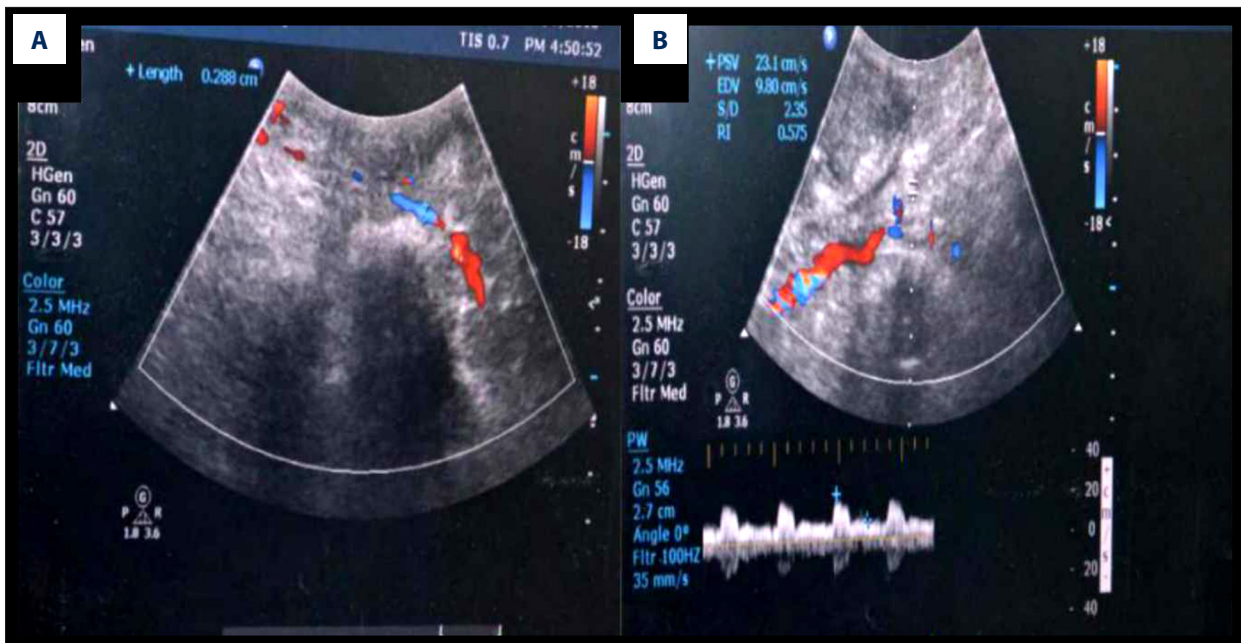


Figure 3. Doppler ultrasonography 1 week after UTx. flow resistance index (RI) on the right side: 28.8 cm/s (A); flow resistance index (RI) on the left side: 57 cm/s (B).

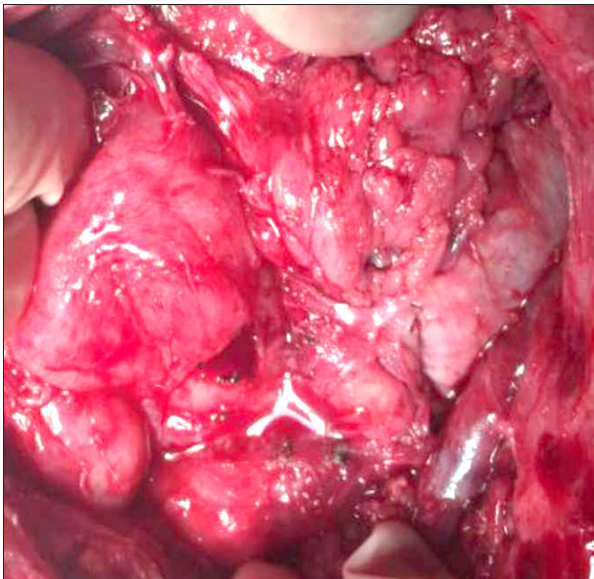


Figure 4. Secondary laparotomy in pig 1 after UTx 1 month.

long-term survival rate was 80%. Pig 5 died, and the autopsy showed uterine necrosis, possibly due to acute rejection or infection, at day 3 after surgery. Pigs 1, 3, and 4 did not show any signs of a cyclic estrus pattern after surgery; however, pig 2 showed resumed heating with the single mating event and was subjected to artificial embryo transplant (ET) 3 months after UTx using homologous frozen embryos from others. The pregnancy was estimated by Doppler ultrasonography under isoflurane anesthesia at 4 weeks after ET; no caesarean section was performed in the transplantation uterus cavity.

Discussion

To develop UTx into a safe clinical procedure for humans with respect to pregnancy and live birth outcome, several aspects involved in the method need to be thoroughly addressed in animal models. Therefore, using models in different species of animals in appropriate contexts is essential [14,15], especially in a large experimental study. In the last decade, animal research on clinical experimental UTx has involved rodents, including mouse, rats, and rabbits, and large domestic animals such as sheep and pigs. In addition, non-human primate research with vascular UTx was initiated, and pregnancies and births were achieved in some of these animals. The first ever offspring after UTx was demonstrated in a mouse model in a syngeneic setting [16]. Subsequent experiments in these species have been carried out with respect to the tolerance for cold ischemia [17] and effects of immunosuppressant drugs on the rejection of UTx. Pregnancies were demonstrated after allogeneic UTx in the rat with tacrolimus treatment, and normal growth of the offspring was observed [18]. The large animals have larger organs and uterine vasculature as compared to small animals, which is a major advantage in UTx research. Studies using swine as an animal model of uterine transplants is rare because the operation for vascular anastomosis is rather complicated because the vessels are small in diameter and are located deeper in the pelvic cavity. Swine were initially used as an autologous UTx model to examine the surgical technique and early reperfusion events in living or dead animals [19]. Subsequently, long-term survival after allo-UTx (0.5–12 months) was approximately 50% in the pigs

with tacrolimus [20]; however, there was no reported pregnancy or reproductive function recovery in swine models of uterus allo-transplantation.

The present study is the first report of allo-transplants performed in swine in China. The objective of this study was to find the optimal conditions for the microsurgery approach for vascular anastomosis and to investigate a vascular supply that affects the fertility potential of the transplanted uterus. We successfully created a stable allogeneic transplantation technique by performing the vascular end-to-side anastomosis with internal and external iliac arteries. In the present study, all recipients remained stable during the transplantation procedures, and the transplanted uterus had normal blood flow as assessed by macroscopic appearance during surgery and ultrasonography after surgery.

A limitation of this study is the difference between swine and other animals in the vessel features with respect to the pelvis, in which filling of blood vessels is connected with estrus, and anastomosis vasculature is easy in female pigs; however, the disadvantage is bleeding during the separation blood vessels. We selected the pigs depending on the sibling born and healing in order to match the donor and recipient for weight, size of the uterus, and diameter of the blood vessels. The uterine vessels include the uterine artery, superficial uterine vein, deep uterine vein, and ovarian vein [21,22] for maintaining the uterine blood supply; perfusion and drainage of the uterus by the arterial and venous structure is necessary. The superficial uterine vein is separated in the upper part of the pelvic floor running in parallel with the uterine artery. The deep uterine vein at the bottom of the pelvic floor is dissected, which can cause hemorrhage and ureter or vessels injury in the hand of a surgeon with limited anatomical knowledge, and causes the venous system to prevent congestion by drainage of the uterine blood flow and heparin; however, the veins of swine are prone to thrombosis and heparin does not have a distinct effect. Thus, we used the internal iliac artery for vascular anastomosis and obtained uterus arterial vascular pedicles up to the anterior branch of the internal iliac artery on each side in all the animals. This was because the model animals had small uterine vessels and the uterine procurement technique avoids dissection of the uterine vein, which is crucial in shortening the operation time and minimizing the surgical risks to live donors. This approach also provides sufficient time to complete the anastomoses on both sides in the absence of anastomosis veins. Therefore, the outcomes of this study showed that veins are not required for UTx, and uterine arteries can adequately support a UTx owing to the abundance of the uterine vein network, which can supply the discharge system by residual anastomosis for the vagina with severance of the arteries and veins and warming the re-infusion rapidly after vascular anastomosis. We were able to successfully perform the

anastomosis of the internal iliac artery on both sides, and the blood circulation to the transplanted uterus was satisfactory. Additionally, because vascular anastomosis was performed on vessels, anastomosis with stabilization of the learning curve for transplantation surgery using the internal iliac arteries as a pedicle in swine requires experience. After 3 surgeries, due to of the increased knowledge of uterus anatomy in swine, improved isolation technique of the uterine artery and internal iliac arteries, the uterine artery was separated from the surrounding tissues and iliac vessels, requiring less operation time. Thus, the procedure was less complicated, and we effectively reduced the warm ischemic time.

There have already been several reports of animal models using anastomosis of the internal iliac arteries and veins [23,24], demonstrating satisfactory outcomes; however, none of these reports used only the arterial system for uterine transplantation and long-term survival after UTx. In addition, reports on stable surgical procedures of allogeneic UTx in swine models are lacking; resumed cyclicity and pregnancy would indicate a successful allo-transplantation procedure. In the present study, 3 animals showed no signs of estrus except for pig 2, with a late resumed estrus by stimulated mating with a male 3 months after UTx. The low rate of pregnancy showed that surgeries cause abundant adhesions around the pelvic floor and ovaries. The support of lymphatic drainage, altered uterine structure, and certain influences could not induce the estrus cycle, the ischemic damage to the tissue that occurs after a vascular transplantation seems to be especially harmful to the organs [25], and thus, the chance for spontaneous pregnancy was relatively low.

Conclusions

This report shows the acceptable safety and feasibility of allogeneic UTx technology, which was only done by transplanting the uterine artery system and removal of the uterine artery (a crucial vessel) from a living donor in UTx. This is the first report evaluating the functions and recovery based on healing in a swine model; 5 allo-transplant attempts were made in different pigs, and no organ or vessel injury was observed in any of the animals.

Acknowledgements

We thank the Animal Examination Department at our hospital for agreeing to support our research. We also thank all of the staff involved in this project. The language corrections in this study were made with the help of MedSci.

Conflict of interests

None.

References:

1. Sieunarine K, Zakaria FB, Boyle DC et al: Possibilities for fertility restoration: A new surgical technique. *Int Surg*, 2005; 90(5): 249–56
2. Chambers GM, Sullivan EA, Ishihara O et al: The economic impact of assisted reproductive technology: A review of selected developed countries. *Fertil Steril*, 2009; 91(6): 2281–94
3. International Federation of Fertility Societies International Conference. IFFS Surveillance 04. *Fertil Steril*, 2004;71: 1S–54S.
4. Semba Y, Chang C, Hong H et al: Surrogacy: Donor conception regulation in Japan. *Bioethics*, 2010; 24(7): 348–57
5. Brinsden PR: Gestational surrogacy. *Hum Reprod Update*, 2003; 9(5): 483–91
6. Brännström M, Johannesson L, Bokström H et al: Livebirth after uterus transplantation. *Lancet*, 2014; 385(9968): 607–16
7. Fageeh W, Raffa H, Jabbad H et al: Transplantation of the human uterus. *Int J Gynaecol Obstet*, 2002; 76(3): 245–51
8. Ozkan O, Erman Akar M, Ozkan O et al: Preliminary results of the first human uterus transplantation from a multiorgan donor. *Fertil Steril*, 2013; 99(2): 470–76
9. Brännström M, Johannesson L, Dahm-Kähler P et al: The first clinical uterus transplantation trial: A six months report. *Fertil Steril*, 2014; 101(5): 1228–36
10. Brännström M: Uterus transplantation and beyond. *J Mater Sci Mater Med*, 2017; 28(5): 70
11. Johannesson L, Kvarnstrom N, Molne J et al: Uterus transplantation trial: 1-year outcome. *Fertil Steril*, 2015; 103(1): 199–204
12. Brännström M, Bokström H, Dahm-Kähler P et al: One uterus bridging three generations: First live birth after mother-to-daughter uterus transplantation. *Fertil Steril*, 2016; 106(2): 261–66
13. Sunderam S, Kissin DM, Crawford SB et al., Centers for Disease Control and Prevention (CDC): Assisted reproductive technology surveillance – United States, 2012. *MMWR Surveill Summ*, 2015; 64(6): 1–29
14. Johannesson L, Enskog A: Experimental uterus transplantation. *Best Pract Res Clin Obstet Gynaecol*, 2014; 28: 1198–210
15. Hanafy H, Diaz-Garcia C, Olausson M et al: Uterine transplantation: One human case followed by a decade of experimental research in animal models. *Aust N Z J Obstet Gynaecol*, 2011; 51: 199–203
16. Racho El-Akouri R, Kurlberg G, Brännström M: Successful uterine transplantation in the mouse: Pregnancy and postnatal development of offspring. *Hum Reprod*, 2003; 18(10): 2018–23
17. Racho El-Akouri R, Wranning CA, Molne J et al: Pregnancy in transplanted mouse uterus after long-term cold ischaemic preservation. *Hum Reprod*, 2003; 18(10): 2024–30
18. Diaz-Garcia C, Johannesson L, Shao R et al: Pregnancy after allogeneic uterus transplantation in the rat: Perinatal outcome and growth trajectory. *Fertil Steril*, 2014; 102: (6)1545–52
19. Wranning CA, Racho El-Akouri R, Lundmark C et al: Auto-transplantation of the uterus in the domestic pig (*sus scrofa*): Surgical technique and early reperfusion events. *J Obstet Gynaecol Res*, 2006; 32(4): 358–67
20. Avison DL, DeFaria W, Tryphonopoulos P et al: Heterotopic uterus transplantation in a swine model. *Transplantation*, 2009; 88: 465–69
21. Fujii S, Takakura K, Matsumura N et al: Precise anatomy of the vesico-uterine ligament for radical hysterectomy. *Gynecol Oncol*, 2007; 104: 186–91
22. Yabuki Y, Asamoto A, Hoshiba T et al: Radical hysterectomy: An anatomic evaluation of parametrial dissection. *Gynecol Oncol*, 2000; 77: 155–63
23. Johannesson L, Enskog A, Dahm-Kähler P et al: Uterus transplantation in a non-human primate: Long-term follow-up after autologous transplantation. *Hum Reprod*, 2012; 27(6): 1640–48
24. Johannesson L, Enskog A, Molne J et al: Preclinical report on allogeneic uterus transplantation in non-human primates. *Hum Reprod*, 2013; 28(1): 189–98
25. Enskog A, Johannesson L, Chai DC et al: Uterus transplantation in the baboon: Methodology and long-term function after auto-transplantation. *Hum Reprod*, 2010; 25(8): 1980–87