

Early Clinical Outcomes of Polydioxanone Mesh for Prepectoral Prosthetic Breast Reconstruction

Cecil S. Qiu, MD*
Akhil K. Seth, MD†

Background: Many biologic matrices and synthetic meshes are available as adjuncts for prosthetic and autologous breast reconstructions to help control implant position and to reinforce abdominal flap donor sites. Absorbable synthetic meshes may have advantages over biologic matrices and permanent meshes, such as lower cost and better long-term biocompatibility. We present a prospective case series of patients undergoing two-stage, prepectoral breast reconstruction with polydioxanone (PDO) mesh.

Methods: This prospective, consecutive single-surgeon series of patients who received PDO mesh during two-stage, prepectoral breast reconstruction involved incorporation of the PDO mesh at stage 1 as an anterior tarp over the tissue expander. A detailed description of surgical technique is provided herein. Surgical complications monitored included surgical site infection, wound dehiscence, mastectomy skin flap necrosis, hematoma or seroma requiring operative intervention, and reconstructive failure.

Results: Seven patients with fourteen breast reconstructions were included in the study. All patients had unilateral cancer and underwent bilateral mastectomies with immediate reconstruction. The average age of patient was 50.0 (SD 7.4) and BMI was 29.3 (SD 2.7). Patients were followed for a median of 274 days, during which only one late infection (7.1%) occurred requiring expander removal.

Conclusions: PDO mesh has an acceptable short-term complication rate in two-stage prepectoral prosthetic breast reconstruction. Future investigations should elucidate its comparative efficacy and safety against alternative products with respect to long-term outcomes. (*Plast Reconstr Surg Glob Open* 2022;10:e4082; doi: 10.1097/GOX.0000000000004082; Published online 26 January 2022.)

INTRODUCTION

Continued improvement in surgical techniques and technologies drives the growing rate of breast reconstruction after mastectomy.¹ Chief among these advances is the use of meshes and matrices in prosthetic reconstruction, which enhances the surgeon's control of implant position within the mastectomy pocket and has led to improved aesthetic outcomes for both subpectoral and prepectoral reconstruction.^{2,3}

Supporting materials in breast reconstruction include biologic matrices and synthetic meshes. Most biologic matrices used in breast reconstruction are acellular dermal matrices (ADM), composed of the decellularized and water-insoluble extracellular matrix of human or porcine dermis. ADM provides structural support to the implant pocket while generating physiologic cues for cellular ingrowth and vascularization.⁴ There is a diversity of ADM brands that differ in source, processing, sterility, biomechanical properties, and thickness, many of which have been thoroughly studied in prosthetic breast reconstruction, and the United States Food and Drug Administration recently issued a safety communication highlighting different explantation, reoperation, and infection rates associated across brands.⁵ ADMs on the whole, however, have been identified as independent risk factors for infection and seroma, although these complications must be taken in context with other patient factors such as obesity and radiation therapy.^{6–11} Finally, ADMs are associated with high cost; the price of a single sheet of Alloderm (Allergan,

From the *Department of Plastic and Reconstructive Surgery, Johns Hopkins School of Medicine, Johns Hopkins University, Baltimore, Md.; †Division of Plastic and Reconstructive Surgery, NorthShore University Health System, Evanston, Ill.

Received for publication July 24, 2021; accepted November 29, 2021.

Copyright © 2022 The Authors. Published by Wolters Kluwer Health, Inc. on behalf of The American Society of Plastic Surgeons. This is an open-access article distributed under the terms of the [Creative Commons Attribution-Non Commercial-No Derivatives License 4.0 \(CCBY-NC-ND\)](https://creativecommons.org/licenses/by-nc-nd/4.0/), where it is permissible to download and share the work provided it is properly cited. The work cannot be changed in any way or used commercially without permission from the journal.

DOI: 10.1097/GOX.0000000000004082

Disclosure: AS receives research funding for an ongoing registry study of DuraSorb in real world use. CQ has no financial interest to declare in relation to the content of this article.

Irvine, Calif.), for example, generally ranges from \$2000 to \$9000 depending on the size of the sheet.^{11,12} These considerations are amplified in the context of prepectoral techniques, where larger sheets or multiple sheets are consistently needed.¹³

Like the sutures from which they are created, synthetic meshes include absorbable and nonabsorbable types. Nonabsorbable synthetic meshes, like titanium-coated polypropylene mesh (TiLOOP Bra, PFM Medical, Cologne, Germany), provide long-term structural support, but they are prone to palpability, erosion, biofilm formation, and sequelae from a chronic foreign body response.^{14–16} In recent years, absorbable synthetic meshes have garnered attention in breast reconstruction and are being studied for their viability as an effective, safe, and low-cost alternative to ADM.^{15,17–22} Absorbable synthetic meshes are differentiated by many factors, including their strength retention, absorption time, pliability, mono- versus multi-filamentous structure, and biocompatibility. In general, the ideal mesh is one that provides durable structural support, especially during tissue expansion and healing, but has minimal bioreactivity, good tissue incorporation, and low complication rates. Mesh materials that have been studied in breast reconstruction include multifilament polyglactin 910 (Vicryl, Johnson and Johnson, New Brunswick, N.J.), dual-filament polyglactin/poly-trimethylene carbonate (TIGR, Novus Scientific, Uppsala, Sweden), and monofilament poly-4-hydroxybutyrate (P4HB) (Galaflex, Galatea, Lexington, Mass. and Phasix, Bard Davol Inc., Warwick, R.I.).^{23–25} As the armamentarium of available meshes grows, understanding the implications of mesh design, manufacture, and clinical outcomes will help surgeons select the optimal mesh for their patients.

Polydioxanone (PDO) is a well-studied material that is widely used in sutures and other surgical devices. DuraSorb (SIA, Chicago, Ill.) is an absorbable PDO mesh that has recently become available as an attractive alternative for use in prosthetic breast reconstruction. It is monofilamentous and has an intermediate absorption time compared with polyglactin 910 (completely resorbed in 2–4 months) and P4HB (completely resorbed in 18–24 months), which may allow it to retain significant medium-term strength and structural support while avoiding long-term surgical site complications.²⁶ Preclinical studies of PDO mesh show good biocompatibility, 1- to 2-mm of neocollagenous tissue formation by 1 month, and resolution of ongoing foreign body reaction by 1 year.^{27–31} Since 2019, the senior author has participated in a prospective registry study of PDO mesh use in clinical practice in both prosthetic and autologous breast reconstruction. Herein, we report the technique and outcomes of the senior author's first patients receiving PDO mesh for two-stage, prepectoral, prosthetic breast reconstruction.

PATIENTS AND METHODS

Approval for this study was obtained from a central institutional review board (Western Institutional Review Board, Inc., Olympia, Wash.). This is a prospective, non-interventional, single-arm study of adult women who

Takeaways

Question: Is polydioxanone mesh safe for oncoplastic breast surgery?

Findings: This was a prospective, consecutive single-surgeon series of seven patients with 14 two-stage, prepectoral breast reconstructions. Patients were followed for a median of 274 days, during which only one late infection (7.1%) occurred, requiring expander removal.

Meaning: Polydioxanone mesh has an acceptable short-term complication rate in two-stage prepectoral prosthetic breast reconstruction.

received Durasorb PDO mesh for any form of soft tissue support in surgeries performed by the senior author (AS). Only two-stage, prepectoral breast reconstruction patients are included in this analysis, and type and timing of reconstructive surgery was decided by preoperative discussions with the patient and breast surgeon, considering the patient's desires, physical examination findings, and oncologic therapy plan.

All reconstructive procedures were performed by the senior author (AS) in two stages, with an expander placed during stage I in the prepectoral plane at the senior author's discretion, based upon patient comorbidities, quality and viability of mastectomy skin flap, and baseline level of breast ptosis and extent of available skin envelope. Candidacy for immediate prosthetic breast reconstruction was determined by the senior author, with strict exclusion criteria including active smoking history and uncontrolled diabetes mellitus. Among candidates for immediate prosthetic reconstruction, there were no specific selection criteria for patients undergoing PDO mesh-assisted prosthetic breast reconstruction. The potential risks and benefits of PDO mesh were explained during each patient consultation. PDO mesh was ultimately utilized in patients willing to participate in the prospective registry study.

An array of demographic and clinical data points were collected prospectively, displayed in [Tables 1 and 2](#). Primary outcomes included surgical site infection, wound dehiscence, mastectomy flap skin necrosis, seroma requiring operative intervention, hematoma, prosthetic exposure, mesh palpability, and reconstructive failure. Data were aggregated in a HIPAA-compliant electronic data capture software (Medrio, San Francisco, Calif.) and analyzed using Excel (Microsoft, Redmond, Wash.). Posthoc comparative analyses by surgical technique groups were performed using Fisher exact test for categorical variables, with a significance level of 0.05.

DESCRIPTION OF SURGICAL TECHNIQUE

In all cases, management of the mastectomy skin was achieved through a nipple-sparing or skin-sparing approach, with the choice dependent on patient desires, size, and location of the underlying breast cancer, patient comorbidities, and baseline breast ptosis and size. Skin sparing mastectomy was performed through a transverse elliptical or Wise pattern incision, whereas nipple-

Table 1. Demographics by Patient

	Mean	SD
Age (y)	50.0	7.4
BMI	29.3	2.7
	n (Total: 7)	%
Active smoking	0	0%
Diabetes	0	0%
Hypertension	0	0%
Bilateral mastectomy	7	100%
Prior radiation	0	0%
Adjuvant radiation	3	43%
Neoadjuvant chemotherapy	5	71%
Active cancer	7	100%
Grade of ptosis		
I	0	0%
II	4	57%
III	3	43%

Table 2. Operative Characteristics by Breast

	n (Total: 14) or Mean	% or SD
Mastectomy indication		
Prophylactic	7	50%
Therapeutic	7	50%
Mastectomy technique		
Nipple sparing mastectomy	0	0%
Skin sparing mastectomy	14	100%
Mastectomy weight	699 g	197.5 g
Reconstructive timing		
Delayed	0	0%
Immediate	14	100%
Size of mesh (in)		
8×16	4	29%
7×18	2	14%
8×17	2	14%
9×17	2	14%
10×18	4	29%
Percent initial fill of expander volume	43.5%	6.9%

sparing mastectomy was done through an inferolateral inframammary incision. The following paragraphs describe the reconstructive technique for transverse or inframammary incisions, and modifications for Wise pattern incisions are provided in the subsequent subtopic.

Following completion of the mastectomy, the mastectomy pocket was irrigated with polymyxin B and povidone-iodine solution, and hemostasis is achieved with electrocautery. Perfusion to the mastectomy skin was then interrogated with visual inspection and through intravenous injection of indocyanine green dye and use of fluorescent angiography (SPY Elite, Stryker Corporation, Kalamazoo, Mich.). Immediate reconstruction was aborted in patients deemed to have mastectomy skin flaps with unsatisfactory perfusion.³² A tissue expander was then selected based on the measured base diameter of the chest, evacuated of air, and irrigated with polymyxin B and povidone-iodine solution. Tissue expander placement was then performed using a prepectoral technique.

Prepectoral tissue expander placement was performed with placement of the tissue expander in the desired location anterior to the pectoralis major. Tissue expander tabs were similarly secured with interrupted 2-0 polydioxanone sutures (PDS, Ethicon Inc., Raritan, N.J.). The tissue expander was then filled to the desired volume with injectable saline. In the case of nipple-sparing or elliptical

skin excisions, the PDO mesh was then tailored to act as an anterior tarp for the lower pole of the expander. The edges of the mesh were secured with interrupted 2-0 polydioxanone sutures to the medial, lateral, and inferior borders of the mastectomy pocket. Spanning interrupted 2-0 polydioxanone sutures were then used to secure the superior border of the mesh to the upper edge of the pectoralis muscle to prevent retraction of the mesh inferiorly (Fig. 1). A drain was placed within the mastectomy pocket and secured to the skin with 3-0 polypropylene suture (Prolene, Ethicon Inc., Raritan, N.J.). Definitive closure of the incision was performed using 3-0 braided polyglactin 910 (Vicryl, Ethicon Inc., Raritan, N.J.) in the dermal layer and 4-0 poliglecaprone 25 suture (Monocryl, Ethicon Inc., Raritan, N.J.) as a running subcuticular. All patients received perioperative antibiotics but not postoperative antibiotics.

Modifications for Wise Pattern Incision

In the case of a Wise pattern incision, the lower mastectomy skin was deepithelialized and used as a lower dermal sling for the expander, with advancement of the upper pole mastectomy skin over top of this. Following assessment of flap perfusion, preparation of the pocket, and placement of the expander, the lower dermal sling was then secured to the chest wall around the lower pole of the expander with interrupted 2-0 polydioxanone sutures. The PDO mesh was then tailored to act as an anterior tarp along the upper pole of the expander, and secured

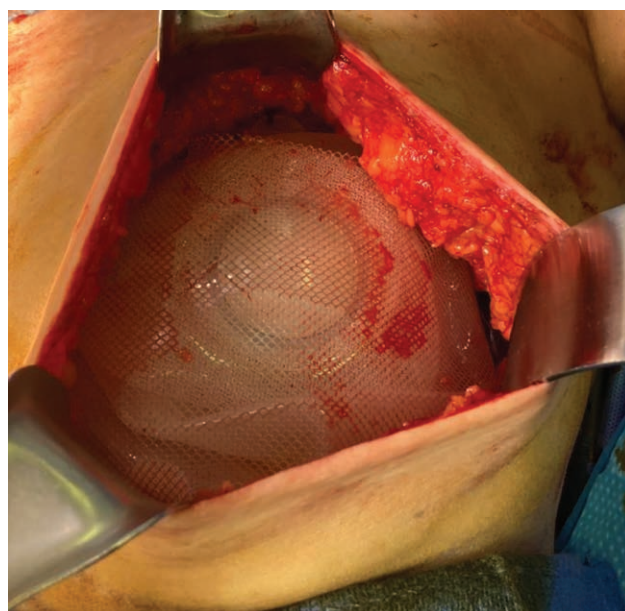


Fig. 1. Final prepectoral placement of tissue expander and polydioxanone mesh after elliptical mastectomy (left breast). The PDO mesh was then tailored to act as an anterior tarp for the lower pole of the expander. The edges of the mesh were secured with interrupted 2-0 polydioxanone sutures to the medial, lateral, and inferior borders of the mastectomy pocket. Spanning interrupted 2-0 polydioxanone sutures were then used to secure the superior border of the mesh to the upper edge of the pectoralis muscle to prevent retraction of the mesh inferiorly.

superiorly, medially, and laterally to the pectoralis major. The inferior border of the mesh was then secured to the upper border of the lower dermal sling to prevent its inferior retraction, thus creating a hybrid anterior tarp for the expander (Fig. 2). A drain was placed within the mastectomy pocket, and closure was performed in layers with the same technique as above.

RESULTS

During 2020, a total of seven consecutive patients accounting for 14 breast reconstructions were included in this series (Table 1). The average age of patient was 50.0 (SD 7.4), and average BMI was 29.3kg/m² (SD 2.7). No patients were active smokers nor did any have comorbid diabetes or hypertension. Five patients (71%) had neoadjuvant chemotherapy, and none had prior radiation to their breasts. All breasts had at least Regnault grade II ptosis.

All patients had unilateral cancer and underwent bilateral mastectomies with prepectoral expander placement with PDO mesh as internal support (Table 2). As such, half of the mastectomies were prophylactic and half were therapeutic, with a mean specimen size of 699 g (SD 198 g). All cases were immediate reconstructions, and only one breast had prior radiation. Sizes of PDO mesh used ranged from 8×16 to 10×18 inches.

Median follow-up time was 274 days. On average, each patient’s final surgical drain was removed on postoperative day 13 (SD 2.4). Three patients underwent adjuvant

radiation. No patients experienced complications within 3-months of postoperative follow-up. One patient experienced a later infection 9-months following initial reconstruction in an irradiated breast, necessitating expander removal. At the time of last follow-up, 12 of 14 (85.7%) breasts had completed second-stage reconstruction with deep inferior epigastric perforator free flap or permanent implant.

DISCUSSION

An ideal mesh for breast reconstruction should exhibit several qualities: it must have good biocompatibility with minimal foreign body response, be macroporous to allow for fluid egress, have good structural integrity during the healing process, promote fibroblast activity and connective tissue ingrowth, and be cost effective.^{33,34} Absorbable meshes seem to satisfy all these criteria, and have recently gained popularity as an alternative to biologic matrices and permanent meshes in breast reconstruction. In principle, they may obviate the risks of disease transmission and infection from biologic matrix, and they may also avoid the chronic foreign body responses, biofilms, and discomfort of permanent synthetic mesh.¹⁶ Empiric outcomes with absorbable meshes is an active field of study. This study reports on our early experience with PDO absorbable mesh as an internal support during immediate prepectoral breast reconstruction with a tissue expander.

We prospectively followed seven patients who underwent 14 reconstructions and observed no short-term surgical complications over a median follow up period of 274 days (Table 3). Example postoperative photographs are shown in Figure 3. All but one patient proceeded to completion of second-stage reconstruction without complication. The remaining patient experienced a late infection several months following initial reconstruction requiring expander removal (7.1% rate of complication). This patient notably had neoadjuvant chemotherapy, had the largest mastectomy specimen weight in our series (1050g versus mean 699g), and underwent postoperative radiation therapy 3 months before her explantation. At the time of expander removal, there were no remnants of the mesh visible within the breast pocket. Adjuvant radiation

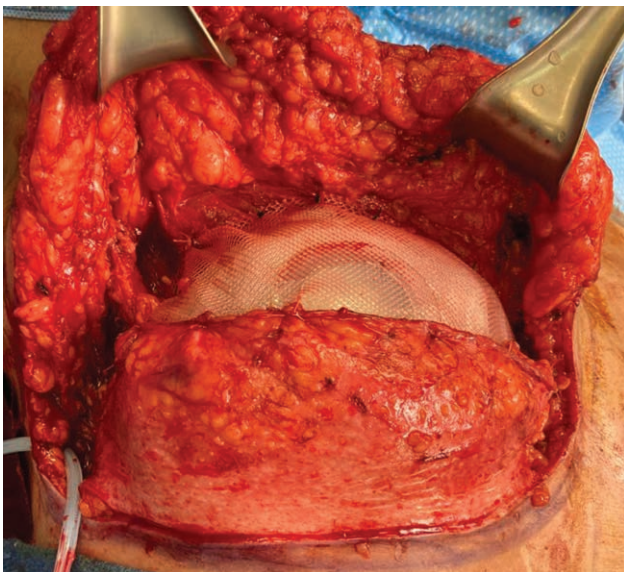


Fig. 2. Final placement of tissue expander and polydioxanone mesh after Wise pattern mastectomy (right breast). The lower mastectomy skin was deepithelialized and used as a lower dermal sling for the expander, secured to the chest wall with interrupted 2-0 polydioxanone sutures. The PDO mesh was then tailored to act as an anterior tarp along the upper pole of the expander and secured superiorly, medially, and laterally to the pectoralis major. The inferior border of the mesh was then secured to the upper border of the lower dermal sling to prevent its inferior retraction, thus creating a hybrid anterior tarp for the expander.

Table 3. Postoperative Outcomes by Breast, within and beyond 3 Months

	<3 mo		>3 mo	
	n (Total: 14)	%	n (Total: 14)	%
Infection	0	0.0%	1	7.1%
Wound dehiscence or mesh exposure	0	0.0%	0	0.0%
Mastectomy flap skin necrosis	0	0.0%	0	0.0%
Seroma	0	0.0%	0	0.0%
Hematoma	0	0.0%	0	0.0%
Mesh palpability	0	0.0%	0	0.0%
Reconstructive failure	0	0.0%	1	7.1%
Reconstructive outcome				
Completed DIEP flap			10	71.4%
Completed implant			2	14.2%
Awaiting DIEP flap			2	14.2%

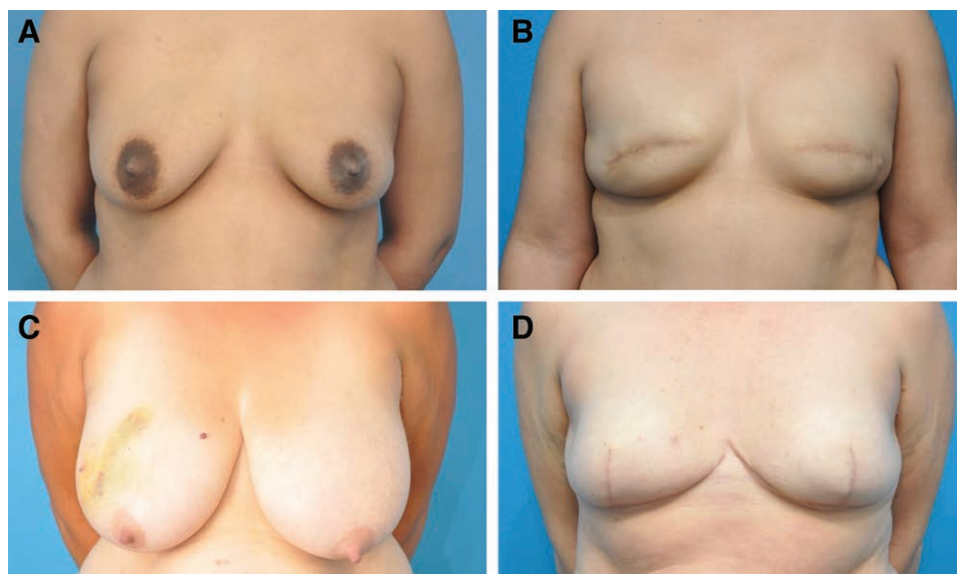


Fig. 3. Photographic results after two-stage prosthetic breast reconstruction using PDO mesh. Example patient 1 (A, B) shown before and 1 year after implant exchange following bilateral elliptical skin sparing mastectomy. Example patient 2 (C, D) shown before and 8 months after implant exchange following bilateral Wise pattern skin sparing mastectomy.

has been implicated in late complications in breast reconstruction, which may ultimately be the primary cause of this late complication.³⁵ Overall, this represents a favorable safety profile for PDO mesh in prepectoral breast reconstruction.

Benchmarking Mesh Complications in Prepectoral Breast Reconstruction

Prepectoral breast reconstruction has previously been associated with slightly lower complication rates than subpectoral reconstruction.³⁶ However, there has not been a clear explanation for this association. We believe that the low complication rate in our present series is partially attributed to confounding by patient selection, as these patients chosen for prepectoral reconstruction tended to have smaller, less ptotic breasts and had a few comorbidities. However, this systematic bias is true of patient selection for prepectoral breast reconstruction at any center, and various specific selection criteria for this technique abound in the literature. It is therefore useful to compare our experience to that of other published authors using other means of soft tissue support.

A recent systematic review and meta-analysis of mesh in prepectoral reconstruction reported a 4.2% rate of infection, 1.3% rate of hematoma, 4.4% rate of implant loss, and 2.9% rate of seroma.³⁷ In that analysis, the majority of included cases used biologic matrix, as only three of 58 included articles reported on the use of synthetic mesh. Reitsamer et al reported on a cohort of 87 prepectoral direct-to-implant reconstructions using TIGR mesh, concluding that there was no significant difference in complications versus biologic matrix.³⁸ Casella et al reported a 6.7% overall complication rate and acceptable patient-reported outcomes associated with prepectoral two-stage reconstruction using TiLOOP,

a permanent titanium-coated polypropylene mesh.³⁹ Kobraei et al reported prepectoral direct-to-implant reconstructions using absorbable Vicryl mesh with only one hematoma and three small nonoperative seromas.⁴⁰ The literature on absorbable synthetic mesh in two-stage prepectoral reconstructions continues to be sparse, but is an active field of study.

Additional benchmarks may be found in the literature on subpectoral reconstruction. Of synthetic meshes used in this context, polyglactin 910 (Vicryl) and polyglactin/TIGR are the most extensively studied. In the largest study of Vicryl mesh, 227 patients underwent direct-to-implant reconstruction with Vicryl mesh support in a subpectoral plane, and 22% of them experienced a complication.¹⁷ This was much higher than what was reported in a prior meta-analysis with a pooled sample of 112 patients with a 3% or lower risk of infection, seroma, or reconstructive failure associated with Vicryl mesh.⁴¹ The two largest TIGR studies, both with 49 patients, reported 23.1% and 23.3% rates of overall complications.^{24,42} Currently, there is only one study of P4HB (Phasix) mesh in breast reconstruction, reporting a 14.5% overall complication rate and 11.2% infection rate, although more studies are ongoing.⁴³ Considering these benchmarks, we found a favorable safety profile for PDO mesh in prosthetic breast reconstruction, which warrants further study on long-term efficacy and safety with increasing surgeon experience.

The Evolving Role of Absorbable Mesh in Breast Reconstruction

Mesh assisted breast reconstruction has evolved rapidly over the last two decades. The surge of biologic ADM research in the early to mid-2010s has led to its widespread adoption as an adjunct to subpectoral breast

reconstruction. In the later 2010s, we have observed even greater utilization of ADMs, given their necessity in establishing pocket control as more surgeons and patients elect for prepectoral prosthetic placement to avoid the drawbacks of subpectoral placement.⁴⁴ Naturally, the market has continued to innovate to solve the disadvantages of biologic ADMs, namely their significant cost. To this end, we predict that absorbable meshes will see increased research and adoption in the short term. Becker recently editorialized his personal exploration of mesh offerings, from starting with biologics to trialing permanent synthetics and finally settling on absorbable synthetics, with specific interest in Durasorb PDO mesh.³⁴ We envision that many surgeons may experience a similar evolution in their approach to mesh-assisted breast reconstruction. Ultimately, it is up to the surgeon to become familiar with the armamentarium of available tools, and to this end, PDO mesh fills a unique role as a monofilamentous, mesh of intermediate absorption profile with handling characteristics that are optimal for breast reconstruction. Additional studies in diverse patient populations will help clarify how to select the right mesh or matrix for any given patient.

Limitations

Limitations of this study are its case series design, small sample size, and limited follow-up (274 days). Our follow up period was adequate for capturing most major perioperative complications such as mastectomy flap necrosis, wound dehiscence, seroma, and infection after breast reconstruction, which have been shown to occur within 90 days. However, long-term complications that may be associated with mesh absorption like implant malposition or capsular contracture would not have been captured.⁴⁵ Our institution continues to collect data on a variety of techniques using this product for future analysis. Besides the foregoing discussion of intraoperative determination of prepectoral eligibility, we do not believe this study was subject to any specific selection bias, as the choice to use PDO mesh was presented to all patients eligible for immediate prosthetic breast reconstruction. Therefore, our findings should be extrapolatable to the general breast cancer population.

CONCLUSIONS

In this prospective consecutive series of patients undergoing prepectoral breast reconstruction with PDO mesh, we found a low short-term complication rate when PDO mesh was used for tissue expander support at stage I. Future investigations should elucidate both long-term outcomes, outcomes in association with other factors like radiation, and comparative efficacy and safety against alternative products currently being used in reconstructive breast surgery.

Akhil K. Seth, MD

Division of Plastic and Reconstructive Surgery
NorthShore University Health System
501 Skokie Boulevard, Suite 250
Northbrook, IL 60062
E-mail: aseth@northshore.org

REFERENCES

1. American Society of Plastic Surgeons. Plastic Surgery Statistics Report [Internet]. Available at: <https://www.plasticsurgery.org/documents/News/Statistics/2020/reconstructive-procedure-trends-2020.pdf>. Accessed December 5, 2020.
2. Kim JYS, Mlodinow AS. What's new in acellular dermal matrix and soft-tissue support for prosthetic breast reconstruction. *Plast Reconstr Surg*. 2017;140(5 suppl):30S–43S.
3. Jones G, Yoo A, King V, et al. Prepectoral immediate direct-to-implant breast reconstruction with anterior alloderm coverage. *Plast Reconstr Surg*. 2017;140(6S Prepectoral Breast Reconstruction):31S–38S.
4. Boháč M, Danišovič L, Koller J, et al. What happens to an acellular dermal matrix after implantation in the human body? A histological and electron microscopic study. *Eur J Histochem*. 2017;62:2873.
5. The U.S. Food and Drug Administration (FDA). Acellular dermal matrix (ADM) products used in implant-based breast reconstruction differ in complication rates: FDA safety communication | FDA [Internet]. 2021. Available at: <https://www.fda.gov/medical-devices/safety-communications/acellular-dermal-matrix-adm-products-used-implant-based-breast-reconstruction-differ-complication>. Accessed May 11, 2021.
6. Jordan SW, Khavanin N, Kim JYS. Seroma in prosthetic breast reconstruction. *Plast Reconstr Surg*. 2016;137:1104–1116.
7. Kim JYS, Connor CM. Focus on technique: two-stage implant-based breast reconstruction. *Plast Reconstr Surg*. 2012;130(5 Suppl 2):104S–115S.
8. Smith JM, Broyles JM, Guo Y, et al. Human acellular dermis increases surgical site infection and overall complication profile when compared with submuscular breast reconstruction: an updated meta-analysis incorporating new products. *J Plast Reconstr Aesthet Surg*. 2018;71:1547–1556.
9. Blacam C de, Momoh AO, Colakoglu S, et al. Cost analysis of implant-based breast reconstruction with acellular dermal matrix. *Ann Plast Surg*. 2012;69:516–520.
10. Krishnan NM, Chatterjee A, Rosenkranz KM, et al. The cost effectiveness of acellular dermal matrix in expander–implant immediate breast reconstruction. *J Plastic Reconstr Aesthetic Surg*. 2014;67:468–476.
11. Jansen LA, Macadam SA. The use of AlloDerm in postmastectomy alloplastic breast reconstruction: part II. A cost analysis. *Plast Reconstr Surg*. 2011;127:2245–2254.
12. Chepla KJ, Dagget JR, Soltanian HT. The partial AlloDerm™ sling: reducing allograft costs associated with breast reconstruction. *J Plast Reconstr Aesthet Surg*. 2012;65:924–930.
13. Nahabedian MY, Jacobson SR. Two-stage prepectoral breast reconstruction. *Gland Surg*. 2019;8:43–52.
14. Dieterich M, Stubert J, Gerber B, et al. Biocompatibility, cell growth and clinical relevance of synthetic meshes and biological matrices for internal support in implant-based breast reconstruction. *Arch Gynecol Obstet*. 2015;291:1371–1379.
15. Becker H, Lind JG II. The use of synthetic mesh in reconstructive, revision, and cosmetic breast surgery. *Aesthetic Plast Surg*. 2013;37:914–921.
16. Logan Ellis H, Asaolu O, Nebo V, et al. Biological and synthetic mesh use in breast reconstructive surgery: a literature review. *World J Surg Oncol*. 2016;14:121.
17. Faulkner HR, Shikowitz-Behr L, McLeod M, et al. The use of absorbable mesh in implant-based breast reconstruction: a 7-year review. *Plast Reconstr Surg*. 2020;146:731e–736e.
18. Tessler O, Reish RG, Maman DY, et al. Beyond biologics. *Plast Reconstr Surg*. 2014;133:90e–99e.
19. Rehnke RD, Schusterman MA II, Clarke JM, et al. Breast reconstruction using a three-dimensional absorbable mesh scaffold and autologous fat grafting: a composite strategy based on tissue-engineering principles. *Plast Reconstr Surg*. 2020;146:409e–413e.

20. Fine NA, Lehfeldt M, Gross JE, et al. SERI surgical scaffold, prospective clinical trial of a silk-derived biological scaffold in two-stage breast reconstruction: 1-year data. *Plast Reconstr Surg*. 2015;135:339–351.
21. Eichler C, Schulz C, Thangarajah F, et al. A retrospective head-to-head comparison between TiLoop Bra/TiMesh and Seragyn in 320 cases of reconstructive breast surgery. *Anticancer Res*. 2019;39:2599–605.
22. Casella D, Di Taranto G, Marcasciano M, et al. Nipple-sparing bilateral prophylactic mastectomy and immediate reconstruction with TiLoop Bra mesh in BRCA1/2 mutation carriers: a prospective study of long-term and patient reported outcomes using the BREAST-Q. *Breast*. 2018;39:8–13.
23. Haynes DF, Kreithen JC. Vicryl mesh in expander/implant breast reconstruction: long-term follow-up in 38 patients. *Plast Reconstr Surg*. 2014;134:892–899.
24. Pompei S, Evangelidou D, Arelli F, et al. The use of TIGR matrix in breast aesthetic and reconstructive surgery: is a resorbable synthetic mesh a viable alternative to acellular dermal matrices? *Clin Plast Surg*. 2018;45:65–73.
25. Adams WP Jr, Toriumi DM, Van Natta BW. Clinical use of GalaFLEX in facial and breast cosmetic plastic surgery. *Aesthet Surg J*. 2016;36(suppl 2):S23–S32.
26. Williams SF, Martin DP, Moses AC. The history of GalaFLEX P4HB scaffold. *Aesthet Surg J*. 2016;36(suppl 2):S33–S42.
27. Mehta-Ambalal SR. Neocollagenesis and neoclastinogenesis: from the laboratory to the clinic. *J Cutan Aesthet Surg*. 2016;9:145–151.
28. Mlodinow A, Kuzycz M, Hasse M, et al. Biomechanical and histologic evaluation of a novel absorbable polydioxanone mesh in a porcine model of abdominal wall repair [Internet]. 2019. Available at: <https://ps-rc.org/meeting/abstracts/2019/eP20.cgi#>. Accessed December 5, 2020.
29. Tang H, Xu Z, Qin X, et al. Chest wall reconstruction in a canine model using polydioxanone mesh, demineralized bone matrix and bone marrow stromal cells. *Biomaterials*. 2009;30:3224–3233.
30. Goonoo N, Jeetah R, Bhaw-Luximon A, et al. Polydioxanone-based bio-materials for tissue engineering and drug/gene delivery applications. *Eur J Pharm Biopharm*. 2015;97(Pt B):371–391.
31. Mlodinow A, Kuzycz M, Hasse M, et al. Proof-of-concept use of novel biosynthetic scaffold in a porcine model of abdominal wall repair. Oral presentation presented at: American College of Surgeons Congress 2018; Boston, MA.
32. Liu EH, Zhu SL, Hu J, et al. Intraoperative SPY reduces post-mastectomy skin flap complications: a systematic review and meta-analysis. *Plast Reconstr Surg Glob Open*. 2019;7:e2060.
33. Jordan SW, Fligor JE, Janes LE, et al. Implant porosity and the foreign body response. *Plast Reconstr Surg*. 2018;141:103e–112e.
34. Becker H. Update on the use of synthetic mesh in reconstructive and cosmetic breast surgery. *Aesthetic Plast Surg*. 2020;44:1128–1129.
35. Kronowitz SJ, Robb GL. Radiation therapy and breast reconstruction: a critical review of the literature. *Plast Reconstr Surg*. 2009;124:395–408.
36. Manrique OJ, Banuelos J, Abu-Ghname A, et al. Surgical outcomes of prepectoral versus subpectoral implant-based breast reconstruction in young women. *Plast Reconstr Surg Glob Open*. 2019;7:e2119.
37. DeLong MR, Tandon VJ, Bertrand AA, et al. Review of outcomes in prepectoral prosthetic breast reconstruction with and without surgical mesh assistance. *Plast Reconstr Surg*. 2021;147:305–315.
38. Reitsamer R, Peintinger F, Klaassen-Federspiel F, et al. Prepectoral direct-to-implant breast reconstruction with complete ADM or synthetic mesh coverage – 36-months follow-up in 200 reconstructed breasts. *Breast*. 2019;48:32–37.
39. Casella D, Di Taranto G, Marcasciano M, et al. Subcutaneous expanders and synthetic mesh for breast reconstruction: long-term and patient-reported BREAST-Q outcomes of a single-center prospective study. *J Plast Reconstr Aesthet Surg*. 2019;72:805–812.
40. Kobraei EM, Cauley R, Gadd M, et al. Avoiding breast animation deformity with pectoralis-sparing subcutaneous direct-to-implant breast reconstruction. *Plast Reconstr Surg Glob Open*. 2016;4:e708.
41. Rodriguez-Unda N, Leiva S, Cheng HT, et al. Low incidence of complications using polyglactin 910 (Vicryl) mesh in breast reconstruction: a systematic review. *J Plast Reconstr Aesthet Surg*. 2015;68:1543–1549.
42. Hallberg H, Lewin R, Elander A, et al. TIGR matrix surgical mesh – a two-year follow-up study and complication analysis in 65 immediate breast reconstructions. *J Plast Surg Hand Surg*. 2018;52:1–6.
43. Levy AS, Bernstein JL, Xia JJ, et al. Poly-4-hydroxybutyric acid mesh compares favorably with acellular dermal matrix in tissue expander-based breast reconstruction. *Ann Plast Surg*. 2020;85:S2–S7.
44. Mangialardi ML, Salgarello M, Cacciatore P, et al. Complication rate of prepectoral implant-based breast reconstruction using human acellular dermal matrices. *Plast Reconstr Surg Glob Open*. 2020;8:e3235.
45. Blough JT, Vu MM, Qiu CS, et al. Beyond 30 days. *Plast Reconstr Surg Glob Open*. 2018;6:e2065.