

# A Rare Case of *Staphylococcus lugdunensis* Causing a Pseudoaneurysm of the Aorta

Patrick Huynh<sup>1</sup>, Ashwin Mathew<sup>2</sup>, Ajinkya Buradkar<sup>3</sup>, Pooja Kharbanda<sup>3</sup>, Rahul Rauniyar<sup>3</sup>

Review began 12/09/2020

Review ended 04/05/2022

Published 04/27/2022

© Copyright 2022

Huynh et al. This is an open access article distributed under the terms of the Creative Commons Attribution License CC-BY 4.0., which permits unrestricted use, distribution, and reproduction in any medium, provided the original author and source are credited.

1. Internal Medicine, Northside Hospital, Lawrenceville, USA 2. Internal Medicine, The University of Edinburgh, Edinburgh, GBR 3. Internal Medicine, The Wright Center for Graduate Medical Education, Scranton, USA

**Corresponding author:** Ajinkya Buradkar, buradkara@thewrightcenter.org

---

---

## Abstract

*Staphylococcus lugdunensis* (SL) is a well-known skin commensal. It is coagulase-negative bacteria that has often been labeled as a contaminant. While coagulase-negative bacteria are not as virulent as *Staphylococcus aureus*, there has been an increasing trend for this organism to be associated with complications commonly known to occur with its more aggressive counterpart. We report a case of *Staphylococcus lugdunensis* causing infective endocarditis and pseudoaneurysm of the aorta.

---

**Categories:** Cardiology, Internal Medicine, Infectious Disease

**Keywords:** staphylococcus lugdunensis, staphylococcus, pseudoaneurysm

## Introduction

*Staphylococcus lugdunensis* is a coagulase-negative staphylococcus and well-documented organism, commonly found on the skin. It has also been a known culprit in skin and soft tissue infections. However, it can rarely cause fatal bacterial endocarditis. In rare cases, it can cause pseudoaneurysms of the aorta. We present a case of a patient with a large pseudoaneurysm of the ascending aorta caused by *Staphylococcus lugdunensis*.

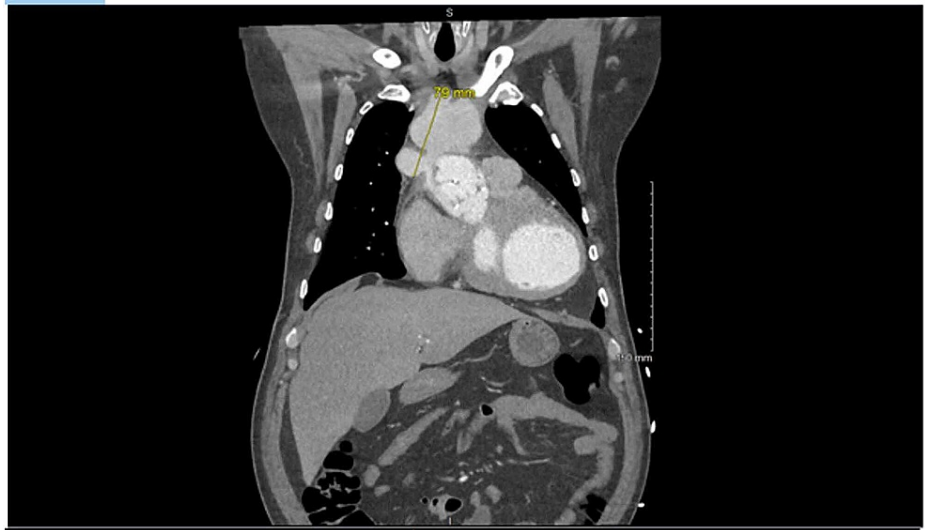## Case Presentation

We present a case of a 52-year-old Hispanic male with a history of bioprosthetic aortic valve replacement four years prior and tetralogy of Fallot (during childhood) presented with chest pain and abdominal pain for the past three weeks. The chest pain was substernal in location. The patient described the pain as 7/10 intensity and radiated to the epigastric region. He did not have associated diaphoresis, palpitations, or nausea. The patient was recently treated for aortic valve endocarditis with long-term intravenous antibiotic therapy lasting six weeks. The patient was admitted with a one-month history of fever, chills, and left upper quadrant discomfort. Upon presentation, he was febrile with laboratory values that were significant for leukocytosis and mild troponemia. The patient was admitted with a working diagnosis of sepsis of unknown etiology. Blood cultures were drawn, and the patient was started on broad-spectrum antibiotics.

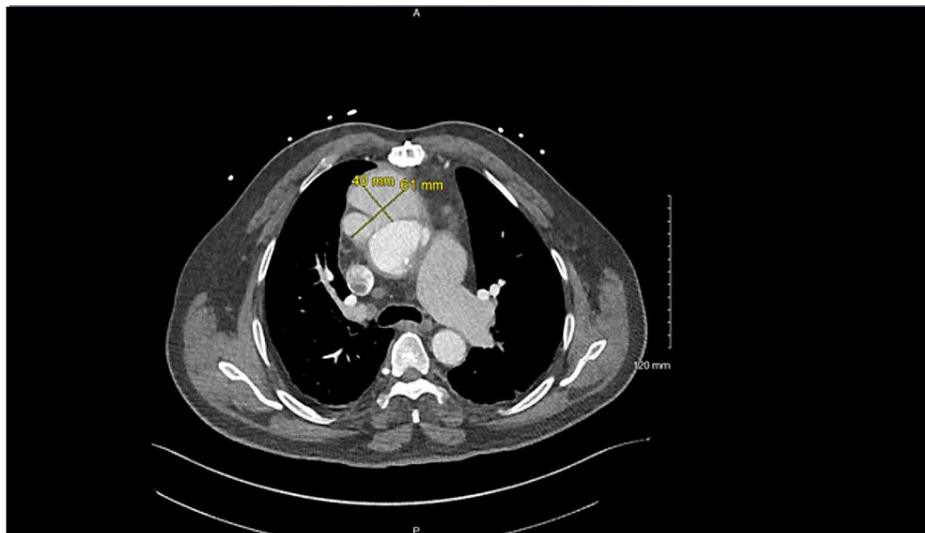
Echocardiogram was suggestive of a vegetation involving the bioprosthetic aortic valve. Computed tomography of the chest revealed signs of a pseudoaneurysm involving the ascending aorta (Figures 1, 2). Blood cultures eventually grew coagulase-negative staphylococci. The patient was ultimately cleared for surgery and prepped for pseudoaneurysm repair with aortic bioprosthetic valve replacement. However, while undergoing the repair, the patient experienced cardiac arrest during the procedure. Thus, further intervention was canceled. Due to the complicated intra-operative course, no intra-operative pictures were taken and no fragments of tissue were able to be cultured for growth. The patient was sent to the ICU and subsequently switched to hospice care after the cardiac arrest. No further intervention was pursued.

### How to cite this article

Huynh P, Mathew A, Buradkar A, et al. (April 27, 2022) A Rare Case of *Staphylococcus lugdunensis* Causing a Pseudoaneurysm of the Aorta. *Cureus* 14(4): e24530. DOI 10.7759/cureus.24530



**FIGURE 1: Coronal view of CT scan demonstrating the pseudoaneurysm of the aorta; yellow line demarcates the pseudoaneurysm with exact dimensions.**



**FIGURE 2: Trans-axial view of CT scan demonstrating the pseudoaneurysm of the aorta; yellow line demarcates the pseudoaneurysm with exact dimensions.**

## Discussion

We present a case of a 52-year-old Hispanic male with a medical history of bioprosthetic aortic valve replacement and tetralogy of Fallot (during childhood) corrected by modified Bentall procedure who is diagnosed with *Staphylococcus lugdunensis* infective endocarditis and pseudoaneurysm formation of the ascending aorta. We believe this to be one of the first few cases published of a pseudoaneurysm forming in the ascending aorta secondary to *Staphylococcus lugdunensis* (SL) endocarditis.

SL is coagulase-negative staphylococci and is a common commensal found on the skin, but predominantly over the perineal area [1]. It is distinguished from other coagulase-negative staphylococci such as *Staphylococcus epidermidis* by the presence of pyrrolidonyl arylamidase and ornithine decarboxylase activity on biochemical testing.

It is well-known that SL not only causes skin and soft tissue infections but is also implicated as a rare cause of bacterial endocarditis. A study by Herchline and Ayers showed that SL is only found to be a contaminant

in 15.4% of isolates and should generally be considered a true pathogen, especially in deep-seated infections [2].

SL is well known for its propensity towards an aggressive clinical course and is said to behave similarly to *Staphylococcus aureus*. Although this rare microbe has a predilection to affect native valves more often, prosthetic valve involvement has been linked with a more sinister outcome, with higher rates of complications such as heart failure, periannular abscess, embolization, shock, and death [3]. Mortality rates are found to be around 38.8-70% with higher rates being found in prosthetic valve involvement as compared to native valves [3,4].

The formation of mycotic aneurysms (pseudoaneurysms) secondary to SL is found to be an extremely rare occurrence with most of the data being available only through case reports. Pseudoaneurysms in these cases were found to involve the intracranial vessels such as the middle cerebral artery [5] and also extracranial sites, such as the left ventricle [6], subvalvular portion of aorta [7], ascending aorta [8], superior mesenteric artery [9,10], and tibial arteries [5]. The mechanism underpinning the aggressive nature of SL is largely unknown. However, it is postulated that certain adherence proteins such as von Willebrand factor (vWF) and fibrinogen-binding proteins may aid in the adherence of the bacterium to tissue and artificial surfaces [11]. The dislodgement of septic emboli may also cause seeding of the bacteria in distant sites, thus explaining the various locations of mycotic aneurysms mentioned above. Besides that, a unique feature of SL is the formation of biofilm which thus contributes to impaired host response towards the bacterium and also reduced penetration of antibiotics [11].

It is vitally important to recognize SL endocarditis as early as possible in view of its high mortality. A case review by Pada et al. recommends the use of 16S ribosomal DNA sequencing for the early diagnosis of SL bacterial endocarditis [12]. Although SL is associated with susceptibility to a large number of antibiotics, a purely medical approach has been shown to confer higher mortality [4]. Therefore, it is advisable to consider an early surgical intervention in these cases.

## Conclusions

This case highlights the importance of considering broad differentials, especially in the patients with extensive past medical history of structural and valvular heart disease, as these patients often have higher mortality rates in the setting of common skin commensals such as SL. It is vital to keep *Staphylococcus lugdunensis* in mind as a differential organism for bacterial endocarditis, especially in the presence of a pseudoaneurysm. When treating such a patient, aggressive initiation of antimicrobial therapy early in the disease course may help mitigate progression of this infection and subsequently formation of pseudoaneurysm. However, most patient often require a dual approach of medical and surgical intervention to appropriately manage these patients and improve outcomes.

## Additional Information

### Disclosures

**Human subjects:** Consent was obtained or waived by all participants in this study. **Conflicts of interest:** In compliance with the ICMJE uniform disclosure form, all authors declare the following: **Payment/services info:** All authors have declared that no financial support was received from any organization for the submitted work. **Financial relationships:** All authors have declared that they have no financial relationships at present or within the previous three years with any organizations that might have an interest in the submitted work. **Other relationships:** All authors have declared that there are no other relationships or activities that could appear to have influenced the submitted work.

## References

- Bellamy R, Barkham T: *Staphylococcus lugdunensis* infection sites: predominance of abscesses in the pelvic girdle region. *Clin Infect Dis*. 2002, 35:E32-4. [10.1086/341304](https://doi.org/10.1086/341304)
- Herchline TE, Ayers LW: Occurrence of *Staphylococcus lugdunensis* in consecutive clinical cultures and relationship of isolation to infection. *J Clin Microbiol*. 1991, 29:419-21. [10.1128/jcm.29.3.419-421.1991](https://doi.org/10.1128/jcm.29.3.419-421.1991)
- Anguera I, Del Río A, Miró JM, et al.: *Staphylococcus lugdunensis* infective endocarditis: description of 10 cases and analysis of native valve, prosthetic valve, and pacemaker lead endocarditis clinical profiles. *Heart*. 2005, 91:[10.1136/hrt.2004.040659](https://doi.org/10.1136/hrt.2004.040659)
- Liu PY, Huang YF, Tang CW, et al.: *Staphylococcus lugdunensis* infective endocarditis: a literature review and analysis of risk factors. *J Microbiol Immunol Infect*. 2010, 43:478-84. [10.1016/S1684-1182\(10\)60074-6](https://doi.org/10.1016/S1684-1182(10)60074-6)
- Tamdy A, El Louali F, Ounzar M, et al.: Multiple mycotic aneurysms reveal *Staphylococcus lugdunensis* endocarditis in a young patient. *Hear Lung*. 2011, 40:352-7. [10.1016/j.hrtlng.2010.05.048](https://doi.org/10.1016/j.hrtlng.2010.05.048)
- Itoda Y, Komae H, Yamamoto T, Takeda M: Left ventricular pseudoaneurysm after surgery for infective endocarditis. *Asian Cardiovasc Thorac Ann*. 2013, 21:82-4. [10.1177/0218492312445393](https://doi.org/10.1177/0218492312445393)
- Gennari M, Annoni A, Polvani G: Pseudoaneurysm of the left ventricular outflow tract after cardiac surgery. *Int J Cardiovasc Imaging*. 2017, 33:749-50. [10.1007/s10554-016-1051-5](https://doi.org/10.1007/s10554-016-1051-5)
- Braga A, Marques M, Abecasis M, Neves JP: Trauma: an unusual cause of endocarditis. *Rev Port Cir Cardiorac Vasc*. 2017, 24:
- Nagamine H, Date Y, Takagi T, Kawase Y: Spontaneous complete resolution of mycotic superior mesenteric

- artery pseudoaneurysm. *J Vasc Surg.* 2018, 68:1914-5. [10.1016/j.jvs.2018.06.197](https://doi.org/10.1016/j.jvs.2018.06.197)
10. Mukaihara K, Matsumoto K, Kadono J, Imoto Y: A surgical case of mycotic aneurysm with *Staphylococcus lugdunensis* endocarditis. *Asian Cardiovasc Thorac Ann.* 2017, 25:296-9. [10.1177/0218492316675705](https://doi.org/10.1177/0218492316675705)
  11. Frank KL, Pozo JL, Patel R: From clinical microbiology to infection pathogenesis: how daring to be different works for *Staphylococcus lugdunensis*. *Clin Microbiol Rev.* 2008, 21:111-33. [10.1128/CMR.00036-07](https://doi.org/10.1128/CMR.00036-07)
  12. Pada S, Lye DC, Leo YS, Barkham T: Utility of 16S ribosomal DNA sequencing in the diagnosis of *Staphylococcus lugdunensis* native valve infective endocarditis: case report and literature review. *Int J Infect Dis.* 2009, 13:511-3. [10.1016/j.ijid.2009.02.019](https://doi.org/10.1016/j.ijid.2009.02.019)