

# Thrombospondin-1 and VEGF in inflammatory bowel disease

Canan Alkim<sup>1</sup>, Damlanur Sakiz<sup>2</sup>, Huseyin Alkim<sup>3\*</sup>,  
Ayten Livaoglu<sup>2</sup>, Tulin Kendir<sup>4</sup>, Huseyin Demirsoy<sup>1</sup>,  
Levent Erdem<sup>1</sup>, Nihat Akbayir<sup>1</sup> and Mehmet Sokmen<sup>1</sup>

<sup>1</sup>Department of Gastroenterology, Sisli Etfal Training and Research Hospital, Istanbul, Turkey; <sup>2</sup>Department of Pathology, Sisli Etfal Training and Research Hospital, Istanbul, Turkey; <sup>3</sup>Department of Gastroenterology, Bakirkoy Dr. Sadi Konuk Training and Research Hospital, Istanbul, Turkey; <sup>4</sup>Department of Gastroenterology, Camlica Hospitalium, Istanbul, Turkey

**Background and aim:** Angiogenesis is an important process in the pathogenesis of chronic inflammation. We aimed to study the angiogenic balance in inflammatory bowel disease (IBD) by evaluating the expression of vascular endothelial growth factor (VEGF) and thrombospondin-1 (TSP-1) on colonic epithelial cells, together with the expression of inducible nitric oxide synthase (iNOS).

**Methods:** Twenty-one ulcerative colitis (UC), 14 Crohn's disease (CD), 11 colorectal cancer patients, and 11 healthy controls colonic biopsy samples were evaluated immunohistochemically.

**Results:** The expressions of TSP-1, VEGF, and iNOS in UC and CD groups were higher than expression in healthy control group, all with statistical significance. However, in colorectal cancer group, VEGF and iNOS expressions were increased importantly, but TSP-1 expression was not statistically different from healthy control group's expression. Both TSP-1 and VEGF expressions were correlated with iNOS expression distinctly but did not correlate with each other.

**Conclusions:** Both pro-angiogenic VEGF and antiangiogenic TSP-1 expressions were found increased in our IBD groups, but in colorectal cancer group, only VEGF expression was increased. TSP-1 increases in IBD patients as a response to inflammatory condition, but this increase was not enough to suppress pathologic angiogenesis and inflammation in IBD.

**Keywords:** *inflammatory bowel disease; thrombospondin-1; VEGF; iNOS; colon cancer*

Received: 30 August 2011; Revised: 20 December 2011; Accepted: 29 December 2011; Published: 30 January 2012

Inflammatory bowel disease (IBD) is a chronic intestinal disorder with an unknown etiology. IBD presents mainly in two forms: ulcerative colitis (UC) or Crohn's disease (CD). A wide list of environmental, genetic and immunologic factors can trigger an uncontrolled immune response in genetically predisposed individuals, which leads to chronic inflammation within the intestinal wall (1). This uncontrolled or inappropriately regulated immune system activation can cause sustained overproduction of reactive metabolites of oxygen and nitrogen, which was one of the mechanisms of intestinal injury and dysfunction observed in IBD (2). Nitric oxide is one of the major reactive species mainly produced in the intestines by the enzyme inducible nitric oxide synthase (iNOS). Especially, neutrophils and macrophages that contribute to the colitis generate reactive oxygen and nitrogen species (3–5).

The role of the non-immune cells, including endothelial cells, in the pathogenesis of IBD has long been recognized. So, not only the classical immune system elements (i.e. T and B lymphocytes, macrophages, and dendritic cells) but also vascular endothelial cells play important roles in triggering chronic and uncontrolled inflammation within the intestinal wall (6, 7). There is a continuous epithelial regeneration in the intestinal mucosa of the patients with IBD. In an inflamed mucosa, the need for nutrients and oxygen as well as the amounts of the waste products increases. For the maintenance of this circuit, formation of new blood vessels from the old ones was required, which is called angiogenesis (8).

The formation of new vessels (angiogenesis) is controlled by the balance between pro- and antiangiogenic molecules. Under normal conditions, intestinal damage is followed by a physiological angiogenesis for promoting

intestinal healing. But in IBD, it was thought that there is abnormal expression of some pro- and antiangiogenic molecules. So, the new balance between pro- and antiangiogenic molecules could cause a different or pathological vascular remodeling, which may favor and maintain the chronic inflammation seen in IBD (8, 9).

Angiogenesis is controlled by a complex network of activators and inhibitors. Between the wide list of factors playing a role in the angiogenesis, vascular endothelial growth factor (VEGF) was the major rate-limiting step during the process (7). VEGF is a potent angiogenic and vascular permeability-enhancing cytokine with overexpression during tissue repair processes, chronic inflammation, and tumoral growth (9–11). Thrombospondins (TSPs) are a family of secreted glycoproteins that play an important role in the maintenance of the structure of the extracellular matrix and the regulation of the cellular phenotype. Among the five subtypes in the TSP family, TSP-1 has significant antiangiogenic effects. Also, TSP-1 is involved in clotting, proliferation, cell attachment, and motility (12, 13). There are a lot of articles in the literature showing increased VEGF in IBD. But, there are a few inconclusive studies for TSP-1 in IBD. We aimed to investigate the angiogenic balance in IBD by evaluating the expression of VEGF and TSP-1 on colonic epithelial cells, together with the expression of iNOS.

## Materials and methods

The study included 21 patients with UC (11 male, age:  $40.8 \pm 15.2$ ) and 14 patients with CD (7 male, age:  $32.4 \pm 13.1$ ). Also, 11 patients with adenocarcinoma of the colon: colon cancer (CC) (6 male, age:  $62.4 \pm 8.3$ ) were included in the study as diseased control. The formalin-fixed paraffin-embedded tissue samples of sporadic (non-familial, non-IBD related) CC patients were obtained from our hospital pathology archive. Otherwise, healthy persons referred for screening with completely normal colonoscopy were used as healthy controls (11 persons, 5 male, age:  $44.2 \pm 10.6$ ). Consecutive IBD outpatients of our gastroenterology clinic were enrolled into the study. All the IBD patients had a definitive diagnosis of CD or UC confirmed by clinical, radiological, endoscopic, and histological findings. Disease activity in patients with CD and UC was assessed by Saverymuttu et al.'s method (14), and patients having grade-1 histological activity were excluded from the study. Also, patients using any other medication other than mesalazine and/or antibiotic in the last 6 months were not enrolled into the study.

Immunohistochemistry: as primary antibodies, mouse monoclonal antibody that recognizes VEGF (Ab-7, clone VG1: Lab vision, 1/100, Westinghouse, CA), rabbit polyclonal antibody that recognizes iNOS (Ab1: Lab vision, 1/100, Westinghouse, CA), mouse monoclonal antibody that recognizes TSP-1 (Ab-4, clone A6.1: Lab vision, 1/100, Westinghouse, CA) were used.

Immunoperoxidase studies were performed on 4- $\mu$ m-thick paraffin-embedded sections of formalin-fixed tissue samples. Immunohistochemical staining was performed using the streptavidin–biotin method. Briefly, the sections were deparaffinized with xylene for 10 min, rehydrated through a graded series of ethyl alcohol for 30 min, and immersed in 0.3% hydrogen peroxide in methanol for 20 min to block endogenous peroxidase activity. Then, the sections were washed with distilled water. Antigen retrieval was performed in citrate buffer (0.01 M, pH: 6.0) for TSP-1 and iNOS and in ethylenediaminetetraacetic acid (EDTA, 1 mM, pH: 8.0) for VEGF by microwave treatment. The sections in citrate buffer or EDTA were incubated at high temperature for 5 min and then at medium temperature for 15 min. Then, the sections were washed with phosphate-buffered saline (PBS pH: 7.6, 1:100) for 5 min. After that, they were placed in goat antipolyvalent immunoglobulin (1:100) for 10 min and then washed with PBS three times. The sections were incubated with primary antibodies for 1 h at room temperature, followed by three washes with PBS for  $3 \times 5$  min. Then, the sections were treated with biotin reagent for 20 min and avidin reagent for 20 min and washed again with PBS for  $2 \times 5$  min. Finally, specimens were treated with a mixture of 3-amino-9-ethylcarbazole (AEC, Thermo Scientific, Fremont, CA, USA) buffer and AEC chromogen and counterstained with hematoxylin. Then, they were washed, dehydrated and mounted with aqueous material for examination. The examination of the slides was done in a blinded manner.

Expression of the VEGF, iNOS, and TSP-1 were observed in the cytoplasm and/or membranes of the epithelial cells. The most prominent staining areas were evaluated for all sections. A semi-quantitative 'staining index' was assessed as first described by King et al. (15) and then by others (9, 16, 17). First, the staining distribution and staining intensity were evaluated. The staining extent (or distribution) of iNOS, VEGF, and TSP-1 was assessed as percentage of positively stained cells among 1,000 cells and classified into 1–5 categories (1: 0–5%; 2: 6–25%; 3: 26–50%; 4: 51–75%; 5: 76–100%). Staining intensity was graded as weak (1: +), moderate (2: ++), and strong (3: +++) using an arbitrary scale. And, finally the 'staining index' was calculated by adding the score of percentage expression to the intensity of staining. For example, the 'staining index' of a patient having 40% (means 3) ++ (means 2) staining was  $(3+2=5)$  five.

Statistical method: all statistical tests were done using SPSS 13 software. For non-parametric values, Kruskal–Wallis test and for parametric values one-way Anova and *t*-test were used. For correlation, Pearson correlation test was used. Statistical significance was set as *p* values lower than 0.05.

## Results

While evaluating demographic features of the study groups, the mean age of CC group was found significantly higher than the other three groups. Other features were similar. Two of the UC patients' Saverymattu score was 2 and the remaining 19 patients' score was 3. Five of the CD patients' Saverymattu score was 2 and the remaining nine patients score was 3. Mean disease time was  $4.9 \pm 6.5$  years for UC group and  $2.7 \pm 1.7$  years for CD group. Nine of the UC patients had extensive or pancolitis, four patients had left-sided colitis, and eight patients had distal colitis. Only one of the UC patients had CC in the past. We studied both colitis and cancer tissues of this patient. Eight of the CD patients had ileocolonic disease and the remaining six patients had colonic disease.

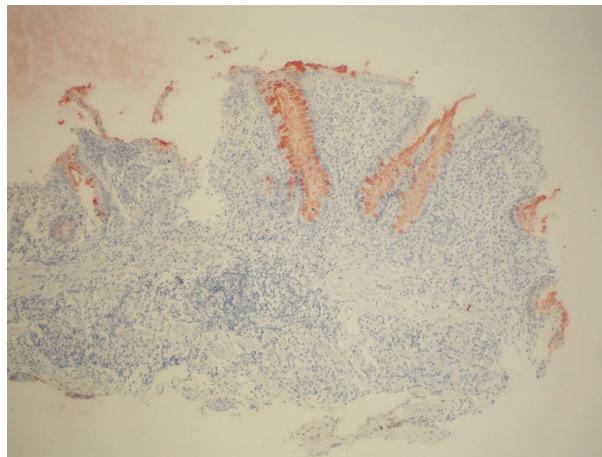
Immunohistochemistry results (staining index) of the groups are shown in Table 1. The expression of TSP-1 on colonic epithelial cells was detected as a cytoplasmic staining (Fig. 1). The expression of TSP-1 of both UC and CD groups was higher than the healthy control group statistically ( $p=0.004$ ,  $p=0.029$ , respectively). TSP-1 expression of CC group was intermediate between the IBD groups and healthy control group values and no statistical difference was detected. The highest expression of TSP-1 was detected in UC group, but it was not different from CD group. In UC group, we had a female patient with a history of 30 years of pancolitis who developed CC. Interestingly, we did not find the expression of TSP-1 on CC and other colon tissues of this patient.

The expression of VEGF on colonic epithelial cells was also detected as a cytoplasmic staining (Fig. 2). The expression of VEGF was lowest in healthy control group. Also, UC, CD, and CC groups had increased VEGF expressions relative to healthy control group's expression, with statistical significance ( $p=0.001$ ). But, there was not a difference between these three groups for the expression of VEGF.

**Table 1.** Table showing thrombospondin-1 (TSP-1), vascular endothelial growth factor (VEGF), and inducible nitric oxide synthase (iNOS) expressions (staining index) of the study groups

	TSP-1	VEGF	iNOS
Ulcerative colitis	$3.91 \pm 2.1^*$	$3.95 \pm 2.5^*$	$6.29 \pm 2.1^*$
Crohn's disease	$3.86 \pm 2.4^{**}$	$4.14 \pm 2.0^*$	$6.43 \pm 1.8^*$
Colorectal cancer	$3.09 \pm 1.9$	$3.45 \pm 1.8^*$	$5.73 \pm 2.5^*$
Healthy control	$2.20 \pm 0.9$	$0.57 \pm 0.9$	0.00

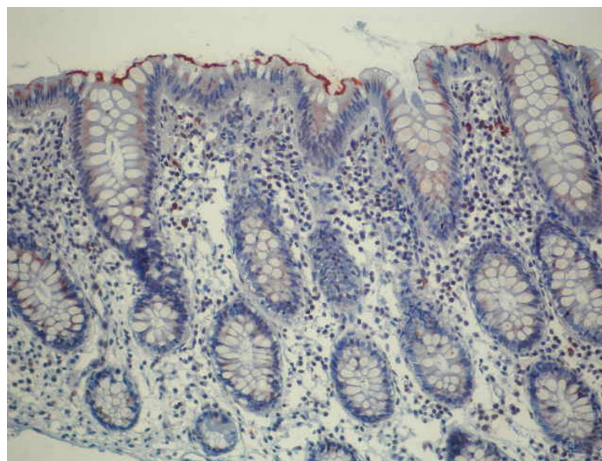
\* $p < 0.005$  according to healthy control, \*\* $p < 0.05$  according to healthy control.



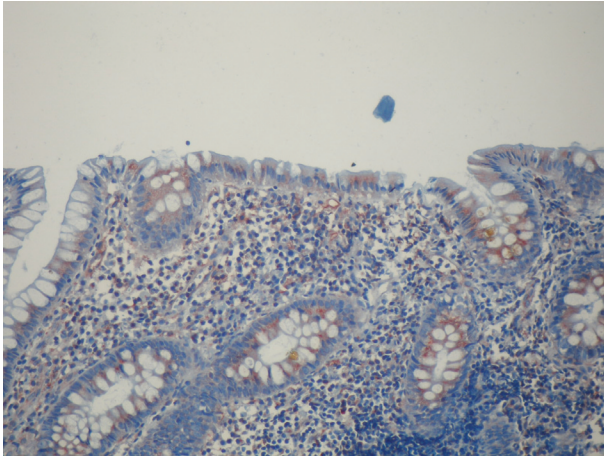
**Fig. 1.** Thrombospondin-1 expression in the cytoplasm of the colonic epithelium ( $\times 100$ ).

We could not find the expression of iNOS in healthy control group's tissues. All three disease groups' tissues demonstrated both cytoplasmic staining and borderline pattern on the apical surface of epithelium (Fig. 3). UC, CD, and CC groups had significantly higher iNOS expression than healthy control group ( $p=0.001$ ). But, the expressions of iNOS of these three groups were close to each other. However, CC group had lower expression of iNOS than IBD group.

Expression of TSP-1, iNOS, and VEGF was not different between UC and CD groups. CC group's expressions were not different from IBD groups, statistically. The expressions of TSP-1, VEGF, and iNOS in UC and CD groups were higher than expressions of healthy control group, all with statistical significance. However, in the CC group, VEGF and iNOS expressions were increased importantly, but TSP-1 expression was not statistically different from healthy control group's expression. Both TSP-1 ( $r: 0.650$ ,  $p < 0.01$ ) and VEGF ( $r: 0.397$ ,



**Fig. 2.** VEGF expression in the cytoplasm of the colonic epithelium ( $\times 200$ ).



**Fig. 3.** iNOS expression in the cytoplasm and the apical surface of the colonic epithelium ( $\times 200$ ).

$p < 0.01$ ) expressions were correlated with iNOS expression distinctly but did not correlate with each other.

No relation between these VEGF, TSP-1, and iNOS expressions and IBD patient's age, sex, disease time, histological activity, and disease location could be demonstrated.

## Discussion

Active inflammation of the colonic mucosa was associated with an increased production of tissue-derived cytokines, such as tumor necrosis factor- $\alpha$  (TNF- $\alpha$ ), interleukin-1- $\beta$ , and interferon- $\gamma$ , that are capable of inducing iNOS in enterocytes, neutrophils, and endothelial cells. Thus, the induction of iNOS in intestinal epithelial cells may represent a pathway for intestinal damage (18). The expression of iNOS on colonic epithelial cells and its relation with immunomodulatory cytokines were demonstrated in previous studies in IBD (19, 20). In the present study, we did not find iNOS expression on the normal mucosa of healthy control group. Kolios et al. (21) did not demonstrate the expression of iNOS on normal mucosa. However, Roberts et al. (22) reported that iNOS was often expressed in the surface epithelium of non-inflamed human colon. In our study, we showed increased expression of iNOS in IBD groups and CC group. This finding was correlated with the previous reports. But, our IBD groups' iNOS expression was not correlated with the histological activity. We thought that these data were due to excluding IBD patients with Saverymuttu's grade-1 mild colitis. On the other hand, iNOS expression correlated both with VEGF and TSP-1 expressions in our study. It is known that NO and iNOS have both anti-inflammatory and proinflammatory properties that are important in the pathogenesis of IBD (23). Our study supports this possible double effect of iNOS in IBD.

Thrombospondin-1 is the best-known molecule among antiangiogenic agents. TSP-1 was frequently studied for invasion, metastasis, and prognosis of malignancies, including ovarian cancer (24), gastric cancer (25), breast carcinoma (26), lung cancer (27), renal cell carcinoma (28), and pancreatic cancer (29). These studies demonstrated that low or absent expression of TSP-1 is associated with advanced stage cancer. Also, it was reported that decreased expression of TSP-1 was correlated with poor prognosis in colorectal carcinoma (13, 30–32). There are a few articles in the literature dealing with the role of TSP-1 in IBD. Zak et al. (12) studied TSP-1-deficient mice with experimental colitis, and they suggested that TSP-1 might decrease angiogenesis. We found that the expression of TSP-1 was higher in IBD groups relative to healthy control group. Also, our CC group's TSP-1 expression is intermediate between the IBD groups and HC group values, without any statistical difference. Jo et al. (13) demonstrated that TSP-1 was strongly expressed in normal colonic epithelial cells. Also, they showed that the loss of TSP-1 was observed in early colonic adenomas and it became undetectable in invasive CCs. We demonstrated the expression of TSP-1 in healthy control group, but CC group's TSP-1 expression, although it is not statistically important, was somewhat higher than that in the healthy control group. In our study, the expression of TSP-1 was not lost or down-regulated in CC. However, both colitis and cancer tissue of the only patient who developed CC during the course of her UC had no expression of TSP-1. We did not find difference between UC and CD groups. TSP-1 may have different functions in cell proliferation, apoptosis, angiogenesis inhibition, cell attachment, and motility. TSP-1 modulates the immune system, via binding and activating transforming growth factor- $\beta$ 1. It was reported that chronic inflammatory conditions have high expressions of TSP-1 (33). We suggest that TSP-1 increases in IBD patients as a response to inflammatory condition, but this increase was not enough to suppress pathologic angiogenesis and inflammation in IBD.

Vascular endothelial growth factor is a well-known pro-angiogenic factor. It also increases vascular permeability, stimulates leukocyte adhesion to the endothelium, and promotes monocyte chemotaxis. VEGF is found increased in IBD patients' tissue and sera (9, 10, 34, 35). In our study, we found that the expression of VEGF was increased in IBD groups relative to healthy control statistically. Also, CC group had significantly higher VEGF expression than healthy control group. These findings are compatible with the literature. Griga et al. (34) reported that the expression of VEGF was higher in active IBD patients than inactive IBD patients. We found no correlation between VEGF expression and disease activity in our previous (9) and the present studies.

Gupta et al. (36) reported that TSP directly inhibited VEGF-induced human angiogenesis both by the displacement of VEGF from endothelial cell heparan sulfate and by direct binding to VEGF. Maeda et al. (37) studied VEGF and TSP-1 together in CC. They demonstrated that TSP-1 was correlated with good prognosis and VEGF was correlated with worse prognosis. Inflammatory tissue is often hypoxic, and hypoxia is an important pro-angiogenic stimulus, acting through upregulation of factors such as VEGF, fibroblast growth factor, TNF- $\alpha$ , hypoxia-inducible factor-1, and other factors (38). VEGF is demonstrated to play a master role in angiogenesis and inflammation and regulates immune-driven angiogenesis in IBD (39, 40). TSP-1 may be a protective factor and may inhibit pathological angiogenesis in IBD. As reported previously, recombinant TSP-1 or mimetic peptide ABT-510 may decrease angiogenesis and inflammation and may be a new therapeutic approach in IBD (41, 42).

Angiogenesis is an important process in IBD. In our study, the expression of iNOS increased and correlated with VEGF and TSP-1. Both pro-angiogenic VEGF and antiangiogenic TSP-1 expressions were found increased in our IBD groups, but in CC group only VEGF expression was increased. Angiogenesis, immune-driven angiogenesis, or pathologic angiogenesis is a complex process that possibly includes multiple pathways and molecules. More advanced studies dealing with this issue will give important information about the pathogenesis of IBD and offer new therapeutic options to us.

### Conflict of interest and funding

The authors have not received any funding or benefits from industry or elsewhere to conduct this study.

### References

1. Neuman MG. Immune dysfunction in inflammatory bowel disease. *Transl Res*. 2007; 149: 173–86.
2. Pavlick KP, Laroux FS, Fuseler J, Wolf RE, Gray L, Hoffman J, et al. Role of reactive metabolites of oxygen and nitrogen in inflammatory bowel disease. *Free Radic Biol Med*. 2002; 33: 311–22.
3. Witte MB, Barbul A. Role of nitric oxide in wound repair. *Am J Surg*. 2002; 183: 406–12.
4. Itzkowitz SH, Yio X. Inflammation and cancer IV. Colorectal cancer in inflammatory bowel disease: the role of inflammation. *Am J Physiol Gastrointest Liver Physiol*. 2004; 287: G7–G17.
5. Alkim C, Balci M, Alkim H, Dagli U, Parlak E, Tezel A, et al. The importance of peripheral immune cells in inflammatory bowel disease. *Turk J Gastroenterol*. 2007; 18: 82–8.
6. Danese S. Inflammation and mucosal microcirculation in inflammatory bowel disease: the ebb and flow. *Curr Opin Gastroenterol*. 2007; 23: 384–9.
7. Costa C, Incio J, Soares R. Angiogenesis and chronic inflammation: cause or consequence? *Angiogenesis*. 2007; 10: 149–66.
8. Pousa ID, Mate J, Gisbert JP. Angiogenesis in inflammatory bowel disease. *Eur J Clin Invest*. 2008; 38: 73–81.
9. Alkim C, Savas B, Ensari A, Alkim H, Dagli U, Parlak E, et al. Expression of p53, VEGF, microvessel density and cyclin-D1 in noncancerous tissue of inflammatory bowel disease. *Dig Dis Sci*. 2009; 54: 1979–84.
10. Griga T, May B, Pfisterer O, Müller KM, Brasch F. Immunohistochemical localisation of vascular endothelial growth factor in colonic mucosa of patients with inflammatory bowel disease. *Hepatogastroenterology*. 2002; 49: 116–23.
11. Toi M, Matsumoto T, Bando H. Vascular endothelial growth factor: its prognostic, predictive, and therapeutic implications. *Lancet Oncol*. 2001; 2: 667–73.
12. Zak S, Treven J, Nash N, Gutierrez LS. Lack of thrombospondin-1 increases angiogenesis in a model of chronic inflammatory bowel disease. *Int J Colorectal Dis*. 2008; 23: 297–304.
13. Jo WS, Mizukami Y, Duerr EM, Zuberberg LR, Chung DC. Wnt signaling can repress thrombospondin-1 expression in colonic tumorigenesis. *Cancer Biol Ther*. 2005; 4: 1361–6.
14. Saverymuttu SH, Camilleri M, Rees H, Lavender JP, Hodgson HJ, Chadwick VS. Indium 111-granulocyte scanning in the assessment of disease extent and disease activity in inflammatory bowel disease. A comparison with colonoscopy, histology and fecal indium 111-granulocyte excretion. *Gastroenterology*. 1986; 90: 1121–8.
15. King RJB, Coffey AI, Gilbert J, Lewis K, Nash R, Millis R, et al. Histochemical studies with a monoclonal antibody raised against a partially purified soluble estradiol receptor preparation from human myometrium. *Cancer Res*. 1985; 45: 5728–33.
16. Mattern J, Koomagi R, Volm M. Association of vascular endothelial growth factor expression with intratumoral microvessel density tumour cell proliferation in human epidermoid lung carcinoma. *Br J Cancer*. 1996; 73: 931–4.
17. Bahnassy AA, Zekri AN, El-Houssini S, El-Shehaby AMR, Mahmoud MR, Abdallah S, et al. Cyclin A and cyclin D1 as significant prognostic markers in colorectal cancer patients. *BMC Gastroenterol*. 2004; 4: 22.
18. Perner A, Rask-Madsen J. Review article: the potential role of nitric oxide in chronic inflammatory bowel disease. *Aliment Pharmacol Ther*. 1999; 13: 135–44.
19. Dijkstra G, Moshage H, van Dullemen HM, de Jager-Krikken A, Tiebosch AT, Kleibeuker JH, et al. Expression of nitric oxide synthases and formation of nitrotyrosine and reactive oxygen species in inflammatory bowel disease. *J Pathol*. 1998; 186: 416–21.
20. Linehan JD, Kolios G, Valatas V, Robertson DA, Westwick J. Immunomodulatory cytokines suppress epithelial nitric oxide production in inflammatory bowel disease by acting on mononuclear cells. *Free Radic Biol Med*. 2005; 39: 1560–9.
21. Kolios G, Rooney N, Murphy CT, Robertson DA, Westwick J. Expression of inducible nitric oxide synthase activity in human colon epithelial cells: modulation by T lymphocyte derived cytokines. *Gut*. 1998; 43: 56–63.
22. Roberts PJ, Riley GP, Morgan K, Miller R, Hunter JO, Middleton SJ. The physiological expression of inducible nitric oxide synthase (iNOS) in the human colon. *J Clin Pathol*. 2001; 54: 293–7.
23. Grisham MB, Pavlick KP, Laroux FS, Hoffman J, Bharwani S, Wolf RE. Nitric oxide and chronic gut inflammation: controversies in inflammatory bowel disease. *J Investig Med*. 2002; 50: 272–83.
24. Wei W, Kong B, Yang Q, Qu X. Hepatocyte growth factor enhances ovarian cancer cell invasion through downregulation of thrombospondin-1. *Cancer Biol Ther*. 2010; 9: 79–87.
25. Guo W, Dong ZM, Guo YL, Yang ZB, Kuang G, Shan BE. Correlation of hypermethylation of TSP1 gene with TGF-beta1 level and T cell immunity in gastric cardia adenocarcinoma. *Ai Zhong*. 2009; 28: 1298–303.

26. Rice AJ, Steward MA, Quinn CM. Thrombospondin 1 protein expression relates to good prognostic indices in ductal carcinoma in situ of the breast. *J Clin Pathol.* 2002; 55: 921–5.
27. Papadaki C, Mavroudis D, Trypaki M, Koutsopoulos A, Stathopoulos E, Hatzidaki D, et al. Tumoral expression of TXR1 and TSP1 predicts overall survival of patients with lung adenocarcinoma treated with first-line docetaxel-gemcitabine regimen. *Clin Cancer Res.* 2009; 15: 3827–33.
28. Zubac DP, Bostad L, Kihl B, Seidal T, Wentzel-Larsen T, Haukaas SA. The expression of thrombospondin-1 and p53 in clear cell renal cell carcinoma: its relationship to angiogenesis, cell proliferation and cancer specific survival. *J Urol.* 2009; 182: 2144–9.
29. Laklai H, Laval S, Dumartin L, Rochaix P, Hagedorn M, Bikfalvi A, et al. Thrombospondin-1 is a critical effector of oncosuppressive activity of sst2 somatostatin receptor on pancreatic cancer. *Proc Natl Acad Sci USA.* 2009; 106: 17769–74.
30. Iddings DM, Koda EA, Grewal SS, Parker R, Saha S, Bilchik A. Association of angiogenesis markers with lymph node metastasis in early colorectal cancer. *Arch Surg.* 2007; 142: 738–44.
31. Miyanaga K, Kato Y, Nakamura T, Matsumura M, Amaya H, Horiuchi T, et al. Expression and role of thrombospondin-1 in colorectal cancer. *Anticancer Res.* 2002; 22: 3941–8.
32. Tokunaga T, Nakamura M, Oshika Y, Tsuchida T, Kazuno M, Fukushima Y, et al. Alterations in tumour suppressor gene p53 correlate with inhibition of thrombospondin-1 gene expression in colon cancer cells. *Virchows Arch.* 1998; 433: 415–8.
33. Gutierrez LS. The role of thrombospondin-1 on intestinal inflammation and carcinogenesis. *Biomarker Insight.* 2008; 3: 171–8.
34. Griga T, Voigt E, Gretzer B, Brasch F, May B. Increased production of vascular endothelial growth factor by intestinal mucosa of patients with inflammatory bowel disease. *Hepato-gastroenterology.* 1999; 46: 920–3.
35. Ferrante M, Pierik M, Henckaerts L, Joossens M, Claes K, van Schuerbeek N, et al. The role of vascular endothelial growth factor (VEGF) in inflammatory bowel disease. *Inflamm Bowel Dis.* 2006; 12: 870–8.
36. Gupta K, Gupta P, Wild R, Ramakrishnan S, Hebbel RP. Binding and displacement of vascular endothelial growth factor (VEGF) by thrombospondin: effect on human microvascular endothelial cell proliferation and angiogenesis. *Angiogenesis.* 1999; 3: 147–58.
37. Maeda K, Nishiguchi Y, Yashiro M, Yamada S, Onoda N, Sawada T, et al. Expression of vascular endothelial growth factor and thrombospondin-1 in colorectal carcinoma. *Int J Mol Med.* 2000; 5: 373–8.
38. Deban L, Correale C, Vetrano S, Malesci A, Danese S. Multiple pathogenic roles of microvasculature in inflammatory bowel disease: a jack of all trades. *Am J Pathol.* 2008; 172: 1457–66.
39. Scaldaferrri F, Vetrano S, Sans M, Arena V, Straface G, Stigliano E, et al. VEGF-A links angiogenesis and inflammation in inflammatory bowel disease pathogenesis. *Gastroenterology.* 2009; 136: 585–95.
40. Danese S. VEGF in inflammatory bowel disease: a master regulator of mucosal immun-driven angiogenesis. *Dig Liver Dis.* 2008; 40: 680–3.
41. Danese S. Negative regulators of angiogenesis in inflammatory bowel disease: thrombospondin in the spotlight. *Pathobiology.* 2008; 75: 22–4.
42. Puneekar S, Zak S, Kalter VG, Dobransky L, Puneekar I, Lawler JW, et al. Thrombospondin 1 and its mimetic peptide ABT-510 decrease angiogenesis and inflammation in a murine model of inflammatory bowel disease. *Pathobiology.* 2008; 75: 9–21.

---

**\*Huseyin Alkim**

Department of Gastroenterology  
 Bakirkoy Dr. Sadi Konuk Training and Research Hospital  
 Istanbul  
 TR-34363, Istanbul, Turkey  
 Tel: +90 (212) 2339446  
 Fax: +90 (212) 5710040  
 Email: alkim65@gmail.com