

Adjustment of radial forearm free flap design around self-inflicted wrist wounds

Zoey E. Morton ^{1,*}, Paul L. Davis², Robert O. Brown², W. Walsh Thomas²

¹ University of South Carolina School of Medicine Greenville, Greenville, SC, United States. ² Greenville ENT and Allergy Associates, Greenville, SC, United States.

*Corresponding author. Zoey Morton, University of South Carolina School of Medicine Greenville, 607 Grove Rd, Greenville, SC 29605, USA. Email: mortonz@email.sc.edu

How to cite this article: Morton ZE, Davis PL, Brown RO, et al. Adjustment of radial forearm free flap design around self-inflicted wrist wounds. Arch Clin Cases. 2022; 9(3):94-99. doi: 10.22551/2022.36.0903.10210

ABSTRACT

The radial forearm free flap (RFFF) is one option of many free-tissue flaps that is frequently selected to reconstruct defects of the head and neck. It is popular due to its relatively thin and pliable associated soft tissue, reliable supplying vasculature, and appropriate diameter and length of the supplying vessels to perform microvascular anastomosis. This case report describes the use of the RFFF to reconstruct an oral cavity defect following tumor resection in a patient who required adjustment of the typical RFFF design. This patient has a significant psychiatric history leading to self-induced forearm lacerations that resulted in substantial scarring of her bilateral forearms in the anatomical area typically included in the RFFF. Since the RFFF was the optimal reconstructive option for this patient, the design of the RFFF was able to be moved proximally up her forearm to avoid inclusion of the scars in the flap. Adequate blood flow of the ulnar artery was confirmed with an Allen's test preoperatively to ensure the radial artery could be taken as part of the RFFF without causing ischemia of the hand. Following surgical resection of the patient's tumor, the RFFF was harvested and inset to reconstruct the resulting oral cavity defect. The patient has had no complications following her resection and reconstruction to date. This report highlights the adaptability of the RFFF, allowing adjustments to typical flap design to optimize outcomes for each individualized patient.

KEYWORDS: Radial forearm free flap; self-inflicted wounds; oral cancer; head and neck reconstruction

■ BACKGROUND

Free-tissue flaps have opened doors to exceptional reconstruction outcomes within the field of head and neck surgery. Successful reconstructive surgery utilizing a free-tissue flap requires significant preoperative planning, skill with microvascular surgical technique, and careful post-operative monitoring. Preoperative planning for free flap reconstruction presents challenges to the head and neck surgeon that are unique to every patient regarding flap selection, design, harvest, and inset. When planning flap selection, the advantages and disadvantages of each flap option must be weighed out and balanced for each individual case. The donor site tissue characteristics and composition, soft-tissue bulkiness, characteristics of the defect, and dimensions of the vascular pedicle must be optimized when planning flap design [1].

The radial forearm free flap (RFFF) is one option of many free-tissue flaps that is frequently selected for defects of the

head and neck. The RFFF offers a thin segment of soft tissue that has been used to reconstruct many subsites of the oral cavity and oropharynx successfully [1-3]. This flap is based off of blood supply from the radial artery, which is ligated and harvested along with the soft tissue of the flap. It is paramount to ensure ulnar and radial artery patency preoperatively via an Allen's test to prevent ischemia of the hand once the radial artery is taken down and failure of the RFFF due to poor flow through the radial artery [1]. Self-inflicted lacerations to the forearms are a manifestation of various psychiatric conditions and present a dilemma for prospective RFFF harvest that has not been addressed previously in the literature [4]. There is a likely impact of previous, especially repeated, injury to components of a free flap due to the changes in tissue architecture resulted from wound healing [5]. Though this presents a challenge for RFFF design, it is not reason to abandon this flap altogether as the RFFF has been previously described as able to be moved proximally up the arm to optimize the quality of tissue selected [3]. This report describes a case in which the RFFF was selected for reconstruction of an oral cavity defect in a patient with history of self-inflicted lacerations to bilateral forearms.

Received: June 2022; **Accepted after review:** August 2022; **Published:** September 2022.



■ CASE REPORT

A 66-year-old female with past medical history of hypertension, tobacco use disorder, bipolar I disorder with major depressive features status post electroconvulsive therapy, and bulimia was referred to head and neck oncology after being found to have squamous cell carcinoma (SCCA) of the oral cavity. By the time of presentation to head and neck oncology, the patient had considerable oral cavity pain, bilateral ear pain, and difficulty chewing resulting in significant weight loss over the past several months. She originally presented to her primary care physician due to oral pain and was referred to a general otolaryngologist. Workup done by this otolaryngologist revealed a tongue mass found to be SCCA on biopsy. Initial computed tomography imaging showed diffuse enlargement of the posterior tongue with narrowing of the pharynx and shotty bilateral cervical lymph nodes without bulky adenopathy. Positron emission tomography (PET) was consistent with local and regional disease in the left anterior tongue and PET avid bilateral neck adenopathy, but no distant metastases.

When planning the patient's operation, it was clear that the defect following tumor resection would be large enough to require a free-tissue flap. The most frequently used free flaps in facial plastics and reconstructive surgery are the anterolateral thigh free flap (ALT), RFFF, ulnar forearm free flap (UFFF), and lateral forearm free flap (LFFF). Neither the ALT nor the LFFF were appropriate for this patient due to her comorbid obesity, BMI 46.84 kg/m². Since both of these flaps require the full depth of the subcutaneous fat to trace the perforator through the underlying musculature, each flap would be too thick for appropriate reconstruction. There are reports of thinning of ALT flaps with liposuction technique; however, that is not in the armamentarium of this patient's reconstructive surgeon [6]. The RFFF and UFFF were determined to be the most appropriate to provide optimal reconstructive outcomes for this patient. However, she presented a unique and previously unreported challenge associated with the use of a RFFF or UFFF with her history of self-inflicted forearm lacerations, shown in Figure 1A. The UFFF was less suited than the RFFF due to the patient's particular scarring pattern, so the RFFF was selected for reconstruction of this patient's defect. An Allen's test was performed preoperatively ensuring ulnar and radial artery patency, which was especially important in this case due to risk of damage to these vessels from her previous forearm lacerations. The typical design of the RFFF was adjusted for this patient so as not to include any of the scarred epidermis and dermis that resulted from her previous suicide attempt shown in Figure 1A. The necessary alteration was to shift the location of RFFF harvest proximally about 4 cm. Preoperative RFFF design planning for this patient is shown in Figure 1B.

Following extensive discussions of the risks and benefits of surgical treatment and other treatment options, the patient and care team agreed to proceed with surgical resection of the tumor with free flap reconstruction. In the operating room, an endophytic burrowing tumor centered over the left floor of mouth with extension adjacent to the mandible was found. The lesion was found to reach across the midline of the oral tongue and posteriorly to the left lateral pharyngeal wall at the anterior tonsillar pillar. A vertical marginal mandibulectomy was performed from the left angle to the right parasymphaseal mandible, this defect was reinforced

with a mandibular plating system. Therapeutic bilateral neck dissections were done as part of the operation.

As the ablative team worked to resect the patient's oral cavity tumor, the reconstructive team began harvest of the RFFF in the typical fashion. A 9 by 7 centimeter flap was marked out to include the left radial artery and cephalic vein as shown in Figure 1B. The RFFF is shown in Figure 2 intraoperatively prior to vascular pedicle division. Laser-assisted indocyanine green angiography (LAIGA) was used to confirm flap viability by assessing vascular perfusion prior to pedicle division. Progressive and adequate perfusion to the distal edges of the flap was observed as shown in Figures 3A and 3B, confirming flap viability. The medial superior edge of the flap marked by a square in Figure 3A contained the most proximal perforator harvested, perfusion from that perforator advancing throughout the entire skin paddle is shown from Figure 3A to 3B. Perfusion of the entire flap was demonstrated by LAIGA as shown in Figure 3B, proving its viability. The radial artery, venae comitantes, and cephalic vein were then ligated at the antecubital fossa. The radial sensory nerve and its branches were preserved.

Left and right oropharyngeal defects were closed primarily with bilateral pharyngoplasties. The RFFF was then brought up to the oral cavity defect where the proximal portion of the flap was sutured across the base of tongue and distal portion placed anteriorly with the midline sutured to the midline lower lip mucosa. The left lateral edge of the flap was sutured to the left buccal mucosa and right medial edge was sutured to the right buccal mucosa. Following partial inset as described with tacking sutures, microvascular anastomosis was performed without complications. The cephalic vein was anastomosed to the left facial vein and venae comitantes to the right facial vein with coupler devices. The radial artery was anastomosed to the right facial artery with sutures in typical end-to-end technique without leak. The soft tissue component of the RFFF was then fully secured using horizontal mattress sutures within the oral cavity. The patient tolerated the procedure well and there were no immediate complications.

Final pathology report revealed an R0 resection with clear microscopic and macroscopic surgical margins and metastatic squamous cell carcinoma to two cervical lymph nodes with extranodal extension. Adjuvant treatment consisting of chemotherapy and radiation therapy was recommended following discussion at multidisciplinary tumor board. The patient denied chemotherapy but did undergo six weeks of radiation treatment with radiation oncology. She continues to do well showing good healing of her recipient and donor sites at clinic visits to date up to four months postoperatively as shown in Figure 4.

■ DISCUSSION

The RFFF is commonly used to reconstruct defects of the head and neck for a variety of indications. The main advantages of the RFFF is the thin and pliable skin that makes up this flap, reliable anatomy of the supplying vasculature, and wide diameter and length of these vessels to ease microvascular anastomosis [1,2]. The pliability of the RFFF allows reconstruction of oral cavity and oropharyngeal defects without limiting mobility of surrounding structures like the tongue, lips, and jaw. The lack of subcutaneous fat of the flap makes it extremely useful in reconstructing a variety of defects of the head and neck since the oral cavity and

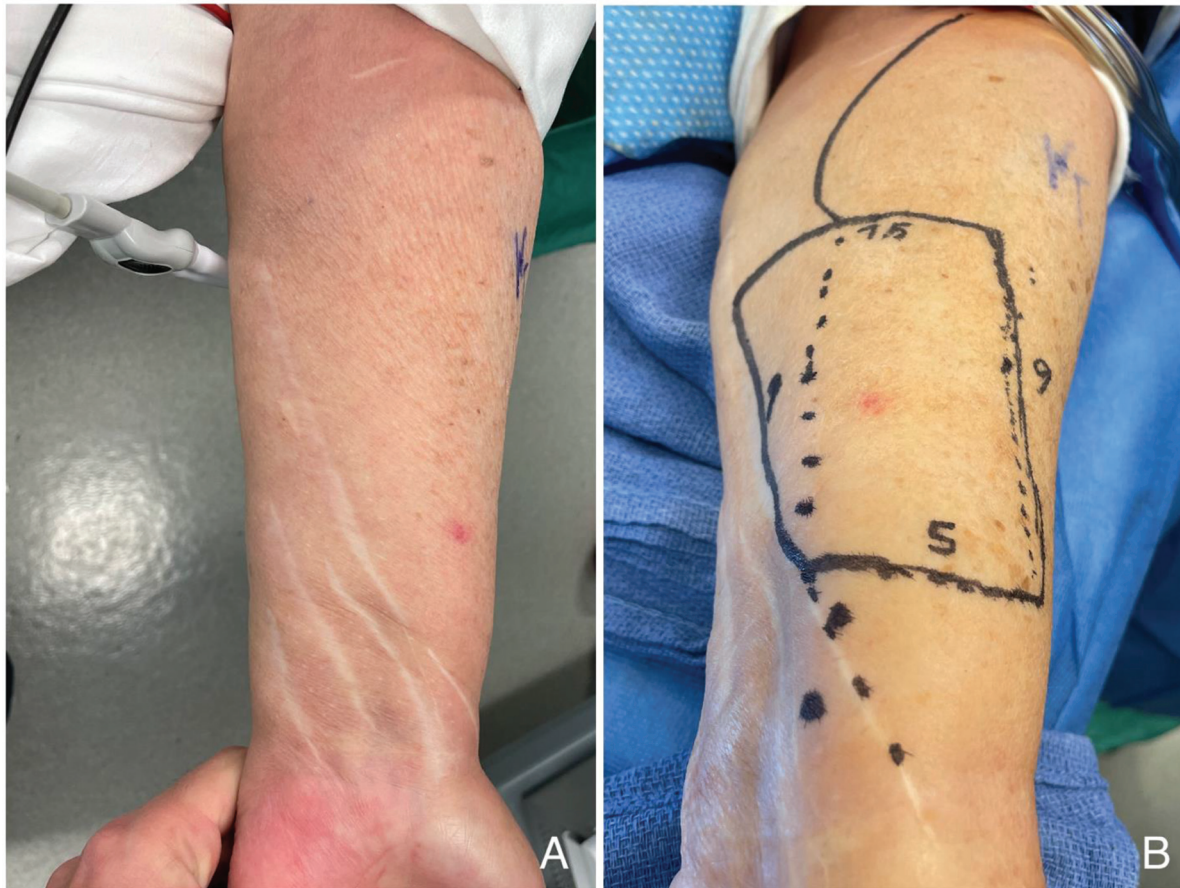

Fig. 1. The patient's left forearm and scars due to previous self-inflicted wrist laceration are shown in 1A; similar scarring was seen on the right dominant arm. Preoperative planning of RFFF design including planned dimensions of flap and course of radial artery proximally are shown in 1B.

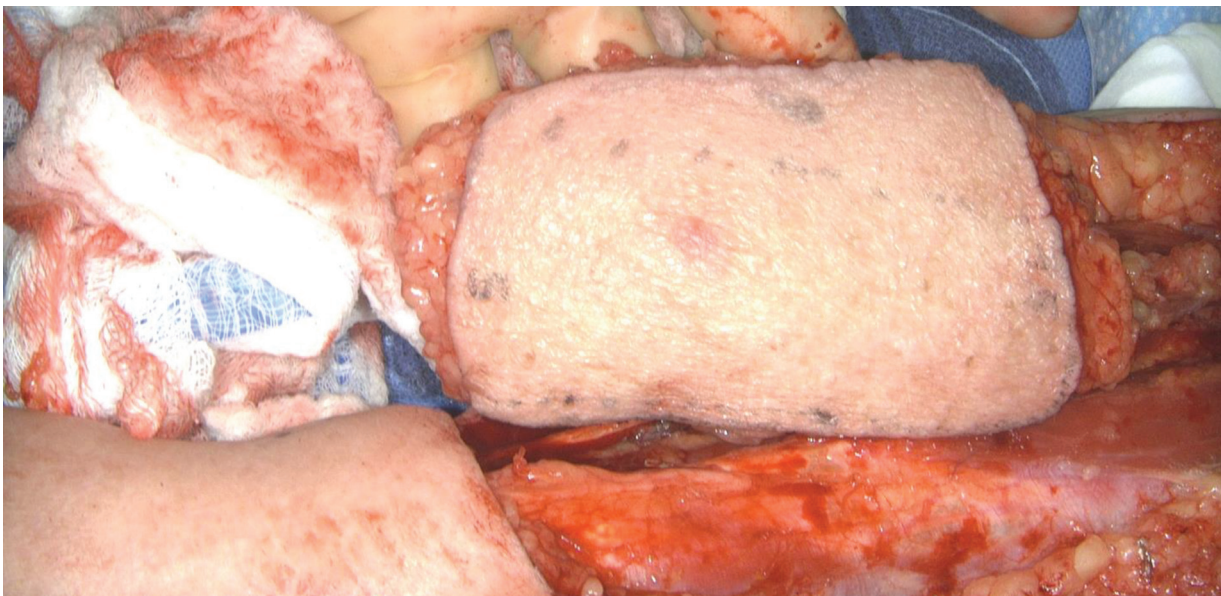


Fig. 2. Intraoperative photo showing RFFF harvest after lifting the flap from native tissue and dissecting out the vascular pedicle prior to its division. Demonstrates the individualized design of this patient's flap, the flap was moved about 4 cm proximally to avoid inclusion of the patient's scarred epidermis and dermis.

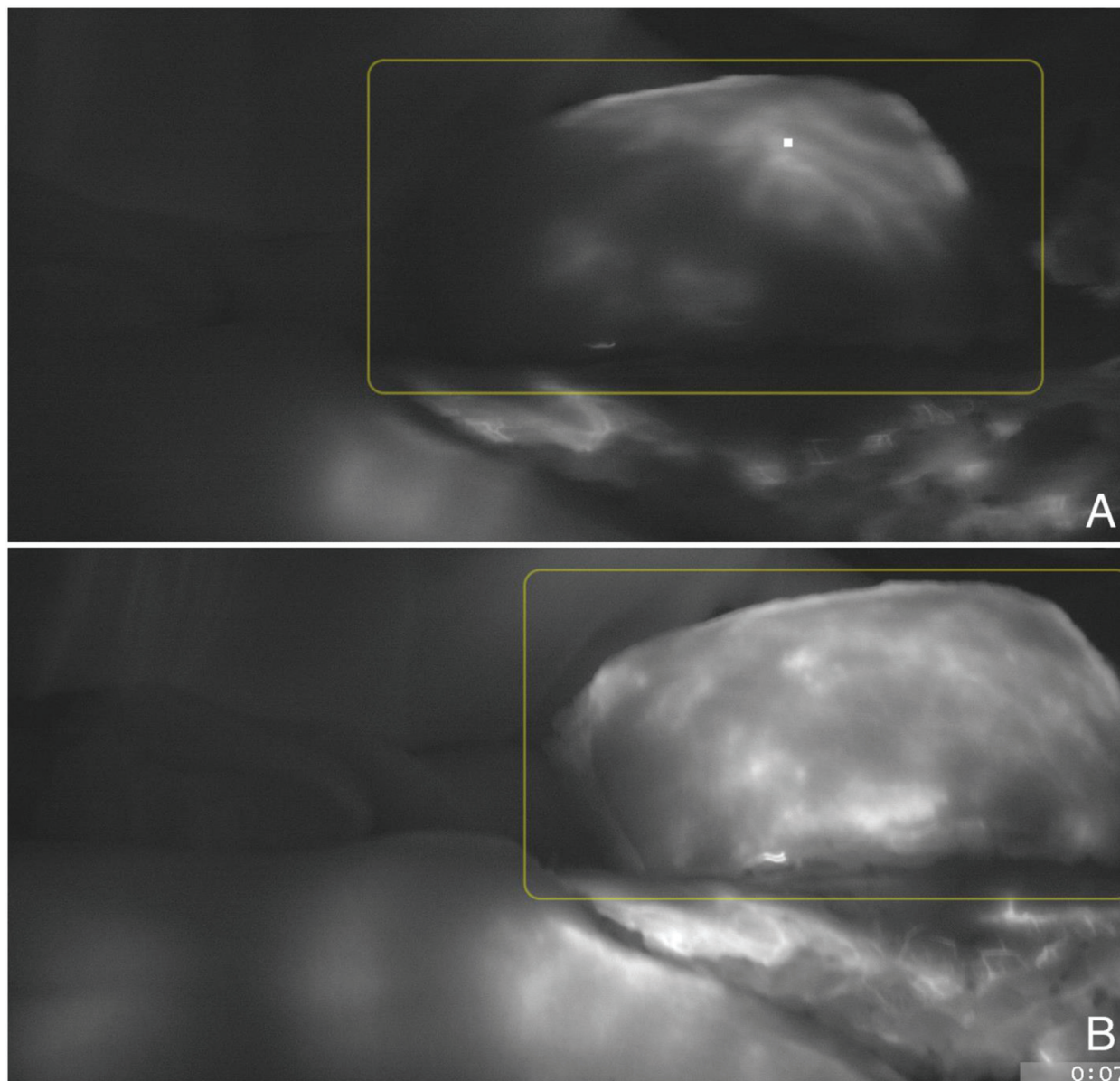


Fig. 3. Intraoperative LAIGA image prior to vascular pedicle division demonstrating progressive perfusion of the RFFF from 3A to 3B and viability of the entire skin paddle. The RFFF is pictured within the yellow rectangle in the same orientation as Figure 2. Increasing white intensity correlates with increasing perfusion of the tissue, the square marks the most proximal perforator.

oropharynx are such finite spaces. A key disadvantage of the RFFF is due to this same characteristic, the thinness of the flap can also be seen as a lack of bulky tissue that can be useful in other reconstructions that require greater amounts of soft tissue volume [1]. Another disadvantage of the RFFF is the unfavorable cosmesis at the donor site which often necessitates a full or partial thickness skin graft for closure. The harvest of the RFFF and difficulties with closure additionally pose risk to surrounding neurovascular structures that can result in hand numbness and very rarely possible ischemia [1-3].

It is important for reconstructive surgeons to consider individual factors of each patient when selecting the optimal strategy for reconstruction. Some free flaps have specific contraindications to their use, for example the fibula free flap is contraindicated in patients with severe peripheral vascular

disease or a dominant peroneal artery system [7]. It is clear these hard contraindications must be avoided; however, there are a myriad of factors that guide towards or away from the use of individual flaps or that guide flap design. One of these such things that has not been previously explored in existing literature is the presence of epidermal or dermal scarring of the soft tissue typically included in the desired flap.

The Allen's test is an important component of preoperative testing prior to RFFF reconstruction in any patient [1]. It is especially paramount in this case to ensure patency of the ulnar and radial arteries due to concern for potential damage to these vessels from her previous forearm lacerations. It was ascertained that ischemia of the hand due to inadequate ulnar artery flow after radial artery harvest or failure of the RFFF due to poor flow through the radial artery were

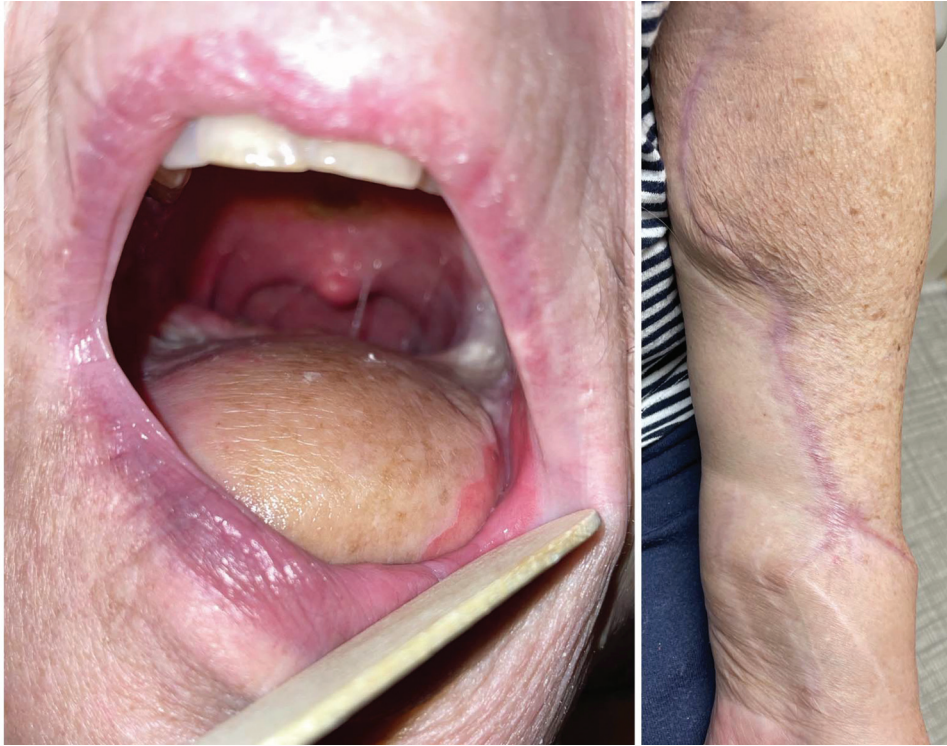

Fig. 4. Six-month postoperative photo demonstrating favorable healing of the RFFF in 4A within the oral cavity and of the forearm donor site which was able to be closed primarily in 4B.

unlikely since the Allen's test confirmed adequate blood flow prior to the operation from each of these vessels when the other was occluded.

Previously damaged tissue is avoided in flap design is to avoid harvesting skin where the perforating arteries were previously compromised, limiting the surrounding random axis perfusion. Following injury, the ending stages of the wound healing process involve the type III collagen of granulation tissue being replaced by type I collagen. Though this results in increased tensile strength of the scar, the integrity and architecture of the extracellular matrix never returns to that of the unwounded tissue [5]. These key sequential changes have not been investigated in terms of how they affect free flap viability and integration into host tissue. The increased presence of type I collagen and altered extracellular matrix could potentially limit the vascular changes necessary for free flap integration into the host tissue. This case demonstrates the importance of the Allen's test in preoperative RFFF workup and the relative ease of modifying free flap design around the patient's existing scars. If feasible, surgeons should avoid inclusion of scar tissue when designing free flaps so that these significant changes to the epidermis, underlying dermis, and perforating arteries to the skin are not included in the transferred tissue.

When determining location of donor tissue for a free flap, it is important to consider the patient's preference since harvest for a free-tissue flap results in a donor site scar. Previous research has shown that patients prefer a donor site scar to be in an anatomical location that is relatively easy to conceal under clothing [8]. This presents a unique advantage to selecting a free flap donor site that is in proximity to existing scars on a patient. If the flap design is able to be

adjusted, as it was in this case, it is preferred to be in proximity to existing scars without including them in the flap, rather than adding an additional location on a patient's body that is cosmetically affected by scarring is avoided.

■ CONCLUSION

Head and neck reconstructive surgeons are given the important job of balancing restoring functionality and favorable aesthetic results when repairing defects of various etiologies. This case emphasizes the importance of utilizing the full armamentarium of reconstructive strategies to optimize outcomes for each patient based on their individual factors and needs. When planning reconstruction, it is vital to consider advantages and disadvantages of the many local, regional, and free flaps for each individual patient; and perform sufficient preoperative testing to ensure favorable outcomes of the recipient and donor sites. It is favorable to avoid inclusion of preexisting damage resulting in compromised integrity of flap or surrounding vessels and scarring of soft tissues in free flap designs. This case demonstrates the ability of the reconstructive surgeon to modify their typical techniques to best treat the individual patient in front of them.

Acknowledgments

The authors would like to acknowledge the patient for being willing to share this case to improve understanding of related fields of medicine and improve patient care.

Competing Interests

The authors declare that they have no competing interests.

Disclaimer

The views expressed in this case report are the authors' own.

Disclosure Statement

The authors have no relevant financial or nonfinancial relationships to disclose. There was no funding for this work.

■ REFERENCES

1. Azizzadeh B, Yafai S, Rawnsley JD, et al. Radial forearm free flap pharyngoesophageal reconstruction. *Laryngoscope*. 2001; 111(5): 807-810. doi: 10.1097/00005537-200105000-00010.
2. Gapany M. Use of radial forearm free flaps in oncologic surgery of the head and neck. *Oper Tech Otolaryngol Head Neck Surg*. 2000; 11(3):184-192. doi: 10.1053/otot.2000.6794.
3. Garg RK, Wieland AM, Poore SO, et al. The radial forearm snake flap: A novel approach to oral cavity and oropharyngeal reconstruction that reduces forearm donor site morbidity. *Microsurgery*. 2017; 37(1):6-11. doi: 10.1002/micr.22425
4. McQuillan TJ, Franco JR, Sorg EM, et al. Understanding and Addressing Psychiatric Comorbidities and Upper-Extremity Trauma: Surgeons in a Multidisciplinary Care Model. *J Hand Surg Am*. 2021; 46(4):328-334. doi: 10.1016/j.jhssa.2021.01.005.
5. Wilkinson HN, Hardman MJ. Wound healing: cellular mechanisms and pathological outcomes. *Open Biol*. 2020; 10:200223. doi: 10.1098/rsob.200223.
6. Askouni EP, Topping A, Ball S, et al. Outcomes of anterolateral thigh free flap thinning using liposuction following lower limb trauma. *J Plast Reconstr Aesthet Surg*. 2012; 65(4):474-481. doi: 10.1016/j.bjps.2011.11.007.
7. Abou-Foul AK, Borumandi F. Anatomical variants of lower limb vasculature and implications for free fibula flap: Systematic review and critical analysis. *Microsurgery*. 2016; 36(2):165-172. doi: 10.1002/micr.30016.
8. McLeod GJ, Islur A. Donor Site Scar Preference in Patients Requiring Free Flap Reconstruction. *Plast Surg (Oakv)*. 2020; 28(2):88-93. doi: 10.1177/2292550320925922.