

Uncoiling of reamer during intramedullary nailing for fracture shaft of femur

**Sanjay Meena,
Vivek Trikha,
Vivek Singh,
Samarth Mittal,
Tanmay S. Kishanpuria**

Department of Orthopaedics, All India Institute of Medical Sciences, New Delhi, India

Address for correspondence:

Dr. Sanjay Meena, Department of Orthopaedics, All India Institute of Medical Sciences, New Delhi - 110 029, India. E-mail: sanjaymeena@hotmail.com

Abstract

Intramedullary nailing is considered the standard of care for closed femoral shaft fractures. Several studies have shown that reamed intramedullary nailing is a safe procedure in fracture shaft femur with lower nonunion rates than unreamed nailing. Reamed intramedullary nailing provides better stability because of increased contact between the nail and medullary canal. However, careful attention to reaming techniques as well good instrumentation is necessary while undertaking such a procedure. We report what is, to the best of our knowledge, the first case of uncoiling of reamer while reaming the medullary canal. Possible causes and measures to avoid such a complication are discussed.

Key words: *Femoral fractures, intramedullary nailing, intra-operative complications*

INTRODUCTION

Intramedullary interlocked nailing is the standard accepted treatment for closed diaphyseal fractures of the femur.^[1] Several prospective and randomized studies have shown improved rates of union with a reamed technique compared with unreamed nail insertion.^[2,3] Although a commonly performed procedure, sometimes complications may occur, if proper techniques are not followed and good instrumentation are not used. Uncoiling of reamer, as an intraoperative complication has never been reported in the literature. The aim of the present report is to describe an unusual case of uncoiling of flexible reamer during intramedullary nailing of fracture shaft femur.

CASE REPORT

A 28-year-old male presented to the emergency department after a road traffic accident in which he was riding a motorcycle and was hit by a truck at a speed of approximately 60 kilometres per hour. He was brought with a grossly deformed right thigh and complained of pain in his right thigh and the inability to move it. An examination of his extremities revealed contusions over his right thigh without any evidence of penetrating injury. There was marked swelling and tenderness in the middle part of his right thigh associated with a closed injury. There was no distal neurovascular deficit. In view of the above clinical findings, a radiograph of his right thigh was suggested. The radiograph revealed unilateral displaced comminuted fracture of shaft femur [Figure 1]. Our patient was then given first aid in the form of Thomas splint and he was planned for reamed interlocking nailing.

He was taken to the operating room and was placed supine on a fracture table. After cleaning and draping in a standard fashion a greater trochanter entry point was made. To hasten the surgery the surgeon started with a reamer of 10 mm and whole canal was reamed over beaded guide wire. While removing the reamer from the canal, the reamer got stuck and it was neither going forward or backwards. An intraoperative image showed uncoiling of reamer. Further reaming in either clockwise or anticlockwise direction led to increased uncoiling of the reamer [Figure 2]. It was not possible to remove the assembly by pulling it out. A slotted hammer was positioned over the reamer against the drill attachments and the assembly was tapped out. Unfortunately, this led to the removal of the guide wire along the reamer [Figure 3]. A new guide wire was then again reinserted through the entry point into the canal and the procedure of interlocking nailing was completed successfully [Figures 4a and b]. At six months' follow-up

the fracture had united and patient had resumed his occupation.

DISCUSSION

Bone healing after intramedullary nailing is usually predictable. Closed intramedullary nailing in closed fractures has the advantage of maintaining both the fracture hematoma and the attached periosteum. In addition, if reaming is performed, these elements provide a combination of osteoinductive and osteoconductive materials to the site of fracture.^[4] Finally, reaming may produce a periosteal vascular response that increases the local blood flow. As a result, secondary bone healing with abundant fracture callus formation is expected in most femur fractures treated with reamed intramedullary nailing.

Intraoperative technical complications may sometimes occur while reaming. The uncoiling of flexible reamer is a unique complication which has not been previously reported in the literature.

The flexible shafts of a reamer are made of coaxially arranged tubular wire coils. The shafts are driven clockwise with the power source. While removing the reamer from the canal they should be removed in the same direction (clockwise). The flexible shafts are designed to rotate only in one direction. Under no circumstances should they be reversed or the wire will uncoil with catastrophic results. In our case reversal of the coil was not done but this did not prevent the reamer from uncoiling. Several factors may be responsible for this complication.

Firstly, in our case reaming was initiated with 10-mm coil which may have contributed to uncoiling. Reaming should be initiated with the Flexible Shaft with 9.0-mm front-cutting reamer and progressed in 0.5-mm diameter increments.^[5] The reamer should be advanced with a steady, moderate pressure. At no time should it be forced into the canal. Partially retract the reamer often, to clear debris from the medullary canal. This prevents the reamer head from jamming in the medullary canal. If the reamer does get stuck inside the medullary canal, gentle use of the drill may free the reamer and a small-diameter reamer should then be used. Care should be taken when reaming across the fracture site as there may be some cortical damage, unless the fracture is properly reduced.^[6] If possible, the reaming rod should not be withdrawn across the fracture site. The position of the reaming rod should be reconfirmed with image intensification after this procedure.

Reaming should always be carried out so that the resultant

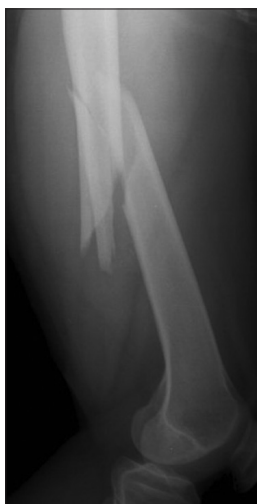

Figure 1: Radiograph of right femur showing fracture shaft femur

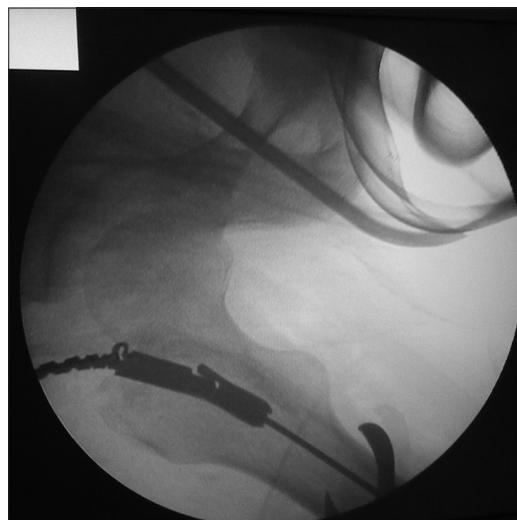

Figure 2: Intraoperative anteroposterior view of the right femur taken with image intensifier showing uncoiled reamer

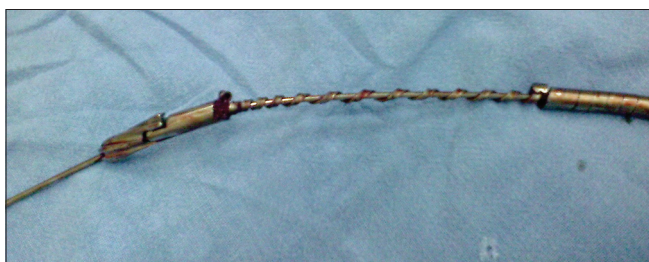

Figure 3: Photograph showing uncoiled reamer

track in the medullary canal is 1-mm wider than the intramedullary nail that the surgeon proposes to use. If reaming is difficult, than the surgeon may choose to ream only 0.5 mm more than the nail, but this is hazardous as the nail may get stuck and be impossible to remove, moreover the reamer may uncoil.

In our case once the flexible reamer uncoiled, it was not possible to remove it simply by pulling. Once uncoiling has occurred, further reaming in clockwise or anticlockwise direction may lead to more uncoiling. A slotted hammer may be positioned over the reamer against the drill attachments and the assembly tapped out. If these manoeuvres are unsuccessful, open operative removal will be necessary but fortunately this was not required in our case. The tapping out of the assembly lead to the removal of guide wire also. This may occur since due to uncoiling effect, the coils of the reamer has tightly gripped the guide wire and it will not be possible to push it alone. Once the assembly was removed, it was not possible to isolate the reamer and the guide wire, so a new guide wire was again inserted and nailing was then completed.

Another reason contributing to this unique complication is the use of an indigenous implant made of poor quality

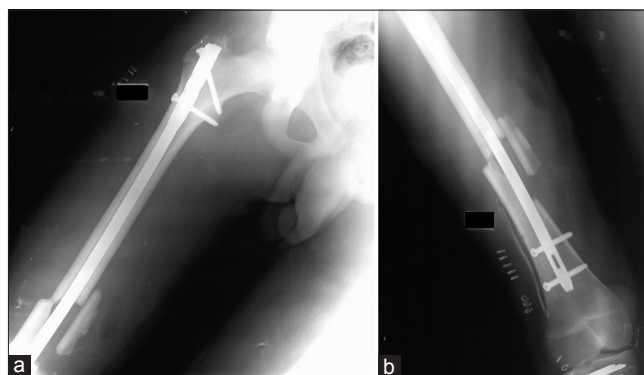


Figure 4: (a and b) Postoperative anteroposterior radiograph shows reduction and intramedullary fixation of right femur

stainless steel. It should be noted that the instrumentation should be of good quality and not be too old. Repeated use of the same reamer over a long time in multiple surgeries may cause wear and tear of the coils and that can cause such complications.

CONCLUSION

This case highlights the dangers associated with reamed interlocking nailing if proper techniques are not followed and good instrumentation are not used. Careful assessment of reaming techniques is crucial to avoid intra-operative complications. We recommend that reaming should be initiated with the smallest reamer size available with gradual increased in 0.5-mm increments. Reaming and removal of reamer should always be carried out in clockwise direction, otherwise uncoiling of reamer may occur. Frequent use of image intensifier during reaming is recommended for early recognition of such a complication and corrective actions.

REFERENCES

1. Starr AJ, Bucholz RW. Fractures of the shaft of the femur. In: Bucholz RW, Heckman JD, editors. Rockwood and Green's fractures in adults. Vol. 2, 5th ed. Philadelphia: Lippincott, Williams and Wilkins; 2001. p. 1683-730.
2. Tornetta P III, Tiburzi D. Reamed versus nonreamed anterograde femoral nailing. J Orthop Trauma 2000;14:15-9.
3. Tornetta P III, Tiburzi D. The treatment of femoral shaft fractures using intramedullary interlocked nails with and without intramedullary reaming: A preliminary report. J Orthop Trauma 1997;11:89-92.
4. Brumback RJ, Virkus WW. Intramedullary nailing of the femur: Reamed versus nonreamed J Am Acad Orthop Surg 2000;8:83-90.
5. Ricci WM, Gallagher B, Haidukewych GJ. Intramedullary nailing of femoral shaft fractures: Current concepts. J Am Acad Orthop Surg 2009;17:296-305.
6. Bucholz RW, Jones A. Current concepts review, fractures of the shaft

of the femur. J Bone Joint Surg Am 1991;73:1561.

How to cite this article: Meena S, Trikha V, Singh V, Mittal S, Kishanpuria TS. Uncoiling of reamer during intramedullary nailing for fracture shaft of femur. J Nat Sc Biol Med 2013;4:481-4.

Source of Support: Nil. **Conflict of Interest:** None declared.

Access this article online

Quick Response Code:	Website: www.jnsbm.org
	DOI: 10.4103/0976-9668.116985