

# Urachal borderline mucinous cystadenoma

## A rare case report and literature review

Jingjun Wu, MMed<sup>a</sup>, Ailian Liu, MD<sup>a,\*</sup>, Anliang Chen, MMed<sup>a</sup>, Pengxin Zhang, MMed<sup>b</sup>

### Abstract

**Rationale:** Urachal borderline mucinous cystadenoma is very rare and has only 9 cases in the current literature with the biological behavior between adenoma and adenocarcinoma.

**Patient concerns:** We reported a 41-year-old man with moderate lower abdominal pain, and the imaging examination found an irregular cystic lesion extending from umbilicus to the dome of urinary bladder with significant separations and calcifications.

**Diagnoses:** The diagnosis was confirmed according to the specific anatomical location and pathological examination which was proved as mucinous cystadenoma with low malignant potential.

**Interventions:** The patient undertook radical excision and partial cystectomy.

**Outcomes:** His postoperative condition was good.

**Lessons:** Urachal borderline mucinous cystadenoma can be located by image examination, which may also offer several diagnostic tips according to separation, calcification, and enhancement in computed tomography scan. When combined with pathological findings, qualitative diagnosis can be determined. Surgical resection should be chosen as an optimal treatment. Our present study reviewed the clinical and biological information of all previous cases which were diagnosed as urachal borderline mucinous cystadenoma and we supplemented more data for further study.

**Abbreviations:** CA19-9 = carbohydrate antigen 19-9, CEA = carcinoembryonic antigen, CT = computed tomography, PMP = pseudomyxoma peritone, PSA = prostate-specific antigen, WHO = World Health Organization.

**Keywords:** borderline tumor, cystadenoma, urachus

## 1. Introduction

Urachus, which connects the umbilicus and anterior wall of bladder, is an embryological remnant of allantois.<sup>[1]</sup> During the embryonic evolution process, urachus closes to become an umbilical median ligament.<sup>[2]</sup> However, if it undergoes an incomplete atresia resulting in a patent urachus, it may become the primary site of various lesions, including cyst, fistula, tumor, diverticulum, and so on.<sup>[3]</sup> Among them, urachal tumors are less reported and have attracted more attention due to their potential invasive ability. Furthermore, urachal tumors are mostly originated from epithelium and their pathological classifications were covered by the 2016 World Health Organization (WHO) classification of genitourinary tumors,<sup>[4]</sup> among which, the urachal borderline mucinous cystadenoma is especially rare, with only 9 clearly diagnostic cases revealed by published literatures.<sup>[5-13]</sup> Obviously, its diagnostic and therapeutic

experience remains limited. We aimed to share a case of urachal borderline mucinous cystadenoma from the aspects of clinical, imaging, operative, and pathological findings to provide more information for further study.

## 2. Case report

### 2.1. Clinical findings

A 41-year-old man attended our urology outpatient department with complaints of swelling and pain in lower abdomen for more than 1 year. The pain, which only extended to moderate degree, was paroxysmal and without obvious incentive. He had no history of gross hematuria, irritative urinary symptoms, osphalgia, or abdominal mass. During urinating, the patient had no attention about filamentous mucus, which was later discovered by microscopic observation in routine urinalysis. Otherwise, he had a history of appendectomy, and he denied recent weight loss or family history of tumor. All other blood analysis including tumor markers of free and total prostate-specific antigen (PSA) and chest computed tomography (CT) completed before surgery showed no abnormalities.

### 2.2. Imaging findings

Ultrasound examination of abdomen showed a mixed echo between bladder dome and abdominal wall on umbilical level. The mass, which was measured as 101 × 42 × 33 mm, was possessed of well-defined boundary, irregular shape, light vascularity, and several separations nearing bladder. Abdominal plain CT scan revealed a heterogeneous, lobulated hypodense mass measuring 3.8 × 3.3 cm in enterocolica of subumbilical plane (Fig. 1). More precisely, the complex cystic lesion extended from umbilicus to anterosuperior dome of the bladder. This

Editor: N/A.

The authors report no conflicts of interest.

<sup>a</sup> Department of Radiology, <sup>b</sup> Department of Pathology, the First Affiliated Hospital of Dalian Medical University, Dalian Shi, Liaoning Sheng, China.

\* Correspondence: Ailian Liu, Department of Radiology, the First Affiliated Hospital of Dalian Medical University, Dalian Shi, Liaoning Sheng, China (e-mail: qj.liuailian@vip.163.com).

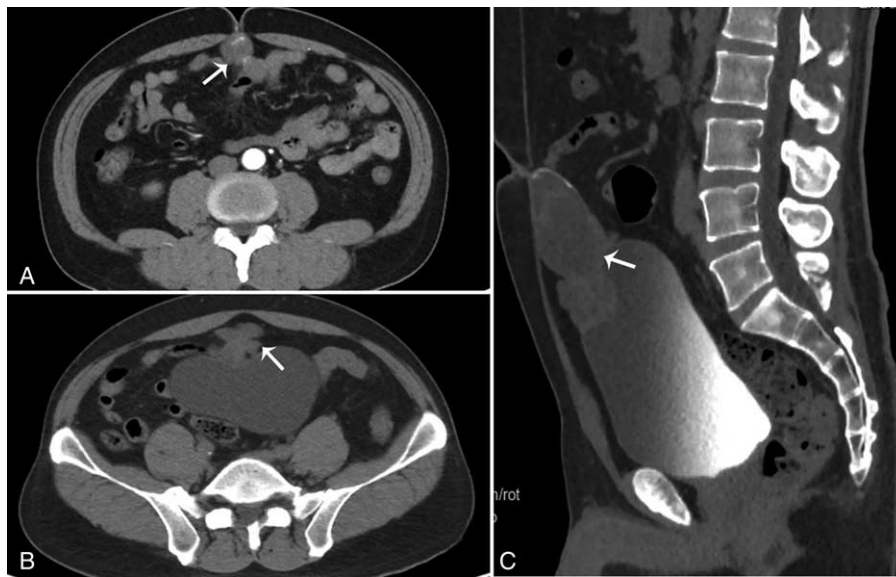Copyright © 2017 the Author(s). Published by Wolters Kluwer Health, Inc. This is an open access article distributed under the terms of the Creative Commons Attribution-Non Commercial-No Derivatives License 4.0 (CCBY-NC-ND), where it is permissible to download and share the work provided it is properly cited. The work cannot be changed in any way or used commercially without permission from the journal.

Medicine (2017) 96:47(e8740)

Received: 14 September 2017 / Received in final form: 20 October 2017 /

Accepted: 23 October 2017

<http://dx.doi.org/10.1097/MD.00000000000008740>



**Figure 1.** Abdominal plain CT scan revealed a hypo-dense mass with calcification (A) and lobulated shape (B) in enterocoelea extending from umbilicus to anterosuperior dome of bladder (C). CT=computed tomography.

hypo-density lesion showed no obvious enhancement in contrast-enhanced CT scan, but nonetheless, we also clearly observed asymmetrical septa and dense shadow at the margin of cystic wall, which showed mild enhancement in delayed phase (Fig. 2). There were no image features of metastatic lymph nodes or other sites. Radiologically, a diagnosis of urachal cystadenoma with unknown malignant potential was put forth.

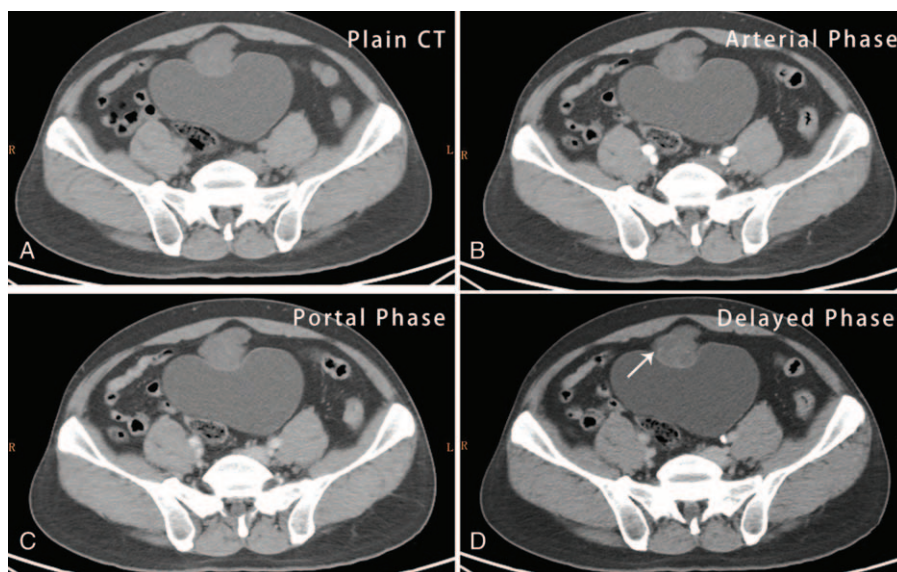
### 2.3. Operative findings

The patient subsequently underwent radical resection of urachal mass and partial cystectomy. At laparotomy, a cystic tumor connecting urachal remnant and dome of bladder was disclosed

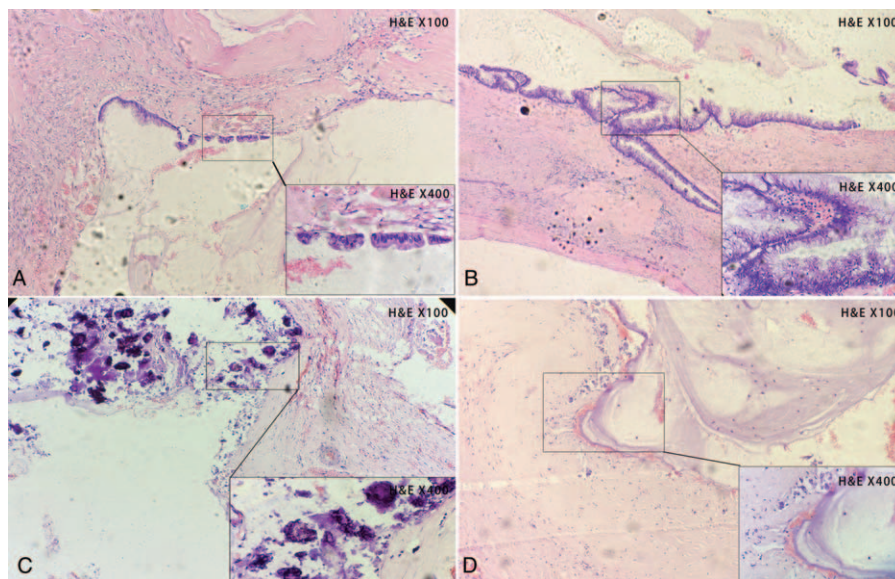
behind the peritoneum. Intraoperative view did not see evidence of pseudomyxoma peritonei (PMP), which has been previously reported that it may originate from urachal remnants and is characterized by the intraperitoneal spread of mucus.<sup>[8,14]</sup> Evaluation for invasive signs of lymph node and other organs including ovary was negative. The patient was uneventful during postoperative course.

### 2.4. Pathological findings

Grossly, we observed a polycystic mass measuring  $3 \times 3 \times 2$  cm without capsule. In cross-section, there was a smooth wall filled with thick gelatinous mucus within the lumen. Histological



**Figure 2.** Abdominal plain CT scan revealed an irregular hypo-dense lesion with higher dense shadow at the margin of cystic wall (A). Contrast-enhanced CT scan showed no obvious enhancement in both arterial (B) and portal phase (C). The marginal shadow showed mild enhancement in delayed phase (D). CT=computed tomography.



**Figure 3.** Histological presentation of urachal borderline mucinous cystadenoma. (A) Normal region of cystic wall was lined by single columnar epithelium. (B) The region of tumor showed glandular epithelial dysplasia with deeply stained nuclei and pseudostratified epithelium. (C) The underlying stroma is full of mucus and without invasion of tumor cells. (D) The calcification is found as blue particles or pieces.

examination revealed irregular glands floating in the mucous lake and part of the glandular epithelial dysplasia with deeply stained nuclei and pseudostratified epithelium (Fig. 3B). For comparison, we also selected the normal region of cystic wall which was lined by single columnar epithelium without abnormal cellular morphology or growth patterns (Fig. 3A). Otherwise, the cystic wall was lined by mucus columnar epithelium, with formation of visible nipple and secretion of mucus, and no tumor cells were observed in stroma (Fig. 3C). Otherwise, the performance of blue particles or pieces proved the presence of calcification (Fig. 3D). On the basis of dysplasia and noninvasion of stroma, we made a diagnosis of borderline condition of urachal mucinous cystadenoma.

Taking into account the histologically low malignant potential and no evidence of lymph node or distant organs metastasis, regardless of radiological, pathological, or intraoperative aspects, the patient was recommended with radical resection without adjuvant chemotherapy. The importance of follow-up has been emphasized in case of recurrence or canceration.

### 3. Discussion

The urachus is gradually blocked as a fiber cord and walks in the space between abdominal fascia and peritoneal loose connective tissue (Retzius gap) during the period of the 4th or 5th month of embryonic development, and bladder descends into the pelvis at the same time. The wall of the urachal tube consists of 3 layers of structure, which from inside to outside are followed by the transition epithelium, connective tissue, and residual smooth muscle cells. Epithelial neoplasms originating from urachus can be divided into nonglandular, glandular, and mixed neoplasm. The nonglandular neoplasms include urothelial neoplasm, squamous cell neoplasm, neuroendocrine neoplasm, and mixed-type neoplasm. Glandular neoplasm can be further classified as adenomas, mucinous cystic tumor of low malignant potential, and adenocarcinoma. These three stages of tumors may cover the tumors' transformation process from benign to

deterioration.<sup>[4]</sup> In above classifications, mucinous cystic tumor of low malignant potential means adenocarcinoma in situ with borderline biological behaviour, which suggests that early detection and treatment are necessary for better survival.

We made a detailed analysis about the previous reports, and our present case was also included (Table 1). Among the 10 cases of urachal borderline mucinous cystadenoma, 2 cases of female and 8 cases of male were reported. Patients were aged from 29 to 72 years, and the median age was 54 years old. The vast majority of initial symptoms were intermittent pain and/or mass in abdomen, excepting only 1 patient who had the chief complaint of haematuria and mucusuria during his visit. Most patients showed normal results about biochemistry and hematologic examinations. Our present patient had mucusuria, which was a rare but significant symptom for the diagnosis of urachus disease.<sup>[15]</sup> In addition, there was a case who had mild monocytosis and elevated fibrinogen; these laboratory findings in patients with pseudomyxoma peritonei were uncommon and not discriminative, but their appearance often prompts the risk of infection caused by urachal remnant.<sup>[16]</sup> Tumor markers have become the key basis for the diagnosis of various neoplastic lesions, but not all diseases have sensitive tumor markers. Considering the low incidence of urachal tumors, the present literature has not yet given a relatively sensitive tumor marker. Some researchers recorded the level of carcinoembryonic antigen (CEA) and carbohydrate antigen 19-9 (CA19-9), but found no abnormalities, except only 1 patient who had elevated CEA. When our patient was in the initial diagnosis, we checked PSA which has been shown to be associated with bladder neoplasm,<sup>[17]</sup> and we found both free and total PSA were within normal range. The advice was proposed to identify sensitive and specific tumor markers of urachal neoplasms after more relevant cases were reported. Otherwise, there were 3 patients with PMP which was originated from the urachal mucinous cystic tumor of low malignant potential. PMP is a clinically uncommon phenomenon with low incidence rate of only one millionth.<sup>[18]</sup> We always find massive amounts of mucous fluid in peritoneal cavity in people suffering from this disease, which is commonly caused by



**Table 1****Cases of urachal borderline mucinous cystadenoma reported in present literatures.**

Reference/year	Age	Sex	Initial symptom	Biochemistry and hematologic test	Tumor marker	PMP
Paul et al <sup>[5]</sup> /1998	68	M	Hematuria and mucusuria	—	—	No
Carr and McLean <sup>[6]</sup> /2001	72	M	—	—	CEA elevated	No
Stenhouse et al <sup>[7]</sup> /2003	54	M	Abdominal pain (migratory, stabbing)	Normal	—	Yes
Shinohara et al <sup>[8]</sup> /2006	54	M	Inguinal hernia	Normal	CEA, CA19–9 normal	Yes
Schell et al <sup>[9]</sup> /2009	70	F	Abdominal mass	Normal	—	No
Choi et al <sup>[10]</sup> /2012	29	F	Abdominal pain (intermittent)	Normal	—	No
Agrawal et al <sup>[11]</sup> /2014	50	M	Abdominal pain (intermittent, radiating to the back)	Monocytosis, elevated fibrinogen	CEA, CA19–9 normal	Yes
Prakash et al <sup>[12]</sup> /2014	58	M	Abdominal pain	Normal	—	No
Chahal et al <sup>[13]</sup> /2015	37	M	Incidental finding	—	—	No
Present case	41	M	Abdominal pain	Mucusuria	PSA normal	No

References/year	CT scan			Pathology		Treatment	Follow-up
	Separation	Calcification	Enhance	Size (cm)	Shape		
Paul et al <sup>[5]</sup> /1998	—	—	—	3	Papillary	Radical excision and partial cystectomy	1 y
Carr and McLean <sup>[6]</sup> /2001	—	—	—	4	Papillary	Radical excision and partial cystectomy	—
Stenhouse et al <sup>[7]</sup> /2003	No	Yes	—	14	Papillary unilocular	—	6 mos
Shinohara et al <sup>[8]</sup> /2006	No	No	—	6	Unilocular	Radical excision, partial cystectomy, intraperitoneal lavage, take 5'-deoxy-5-fluorouridine orally	7 y
Schell et al <sup>[9]</sup> /2009	—	Yes	—	15.5	Multilocular	Radical excision and partial cystectomy	1 y
Choi et al <sup>[10]</sup> /2012	—	Yes	—	5.5	Multilocular	Radical excision and partial cystectomy	11 mos
Agrawal et al <sup>[11]</sup> /2014	Yes	Yes	No	8	Multilocular	Radical excision, partial cystectomy	—
Prakash et al <sup>[12]</sup> /2014	Yes	Yes	Yes	10	Multilocular	Radical excision	6 mos
Chahal et al <sup>[13]</sup> /2015	No	Yes	No	4	Papillary	Radical excision	—
Present case	Yes	Yes	Yes	3	Multilocular	Radical excision and partial cystectomy	—

The symbol "—" refers to "not mentioned."

CA19–9=carbohydrate antigen 19–9, CEA=carcinoembryonic antigen, CT=computed tomography, F=female, M=male, PMP= pseudomyxoma peritone, PSA=prostate-specific antigen, y=year.

lesions of appendix or ovary and very few other primary sites. Our review of literature showed that the possibilities originating from urachal lesions should not be ignored when PMP was found (Table 1).

Next, we reviewed the imaging and pathologic data of all present cases. Among all of the patients, the CT scan of the abdomen and pelvis showed a circular or irregular cystic lesion with low density connecting the urinary bladder and umbilicus. All of the lesions had various size and no invasive signs of near organs or lymph nodes. Several special imaging signs which were worthy of our mention were also recorded. First of all, intracapsular separation was significant in CT scan of 3 patients and the postoperative specimens showed multiloculated mass in 5 patients. Next, calcification was also meaningful in 7 cases and the CT imaging often appears as minute peripheral calcification. We hypothesize that lobulation and marginal calcification are common scenes, but combining with previous literature, we find that these manifestations are still not specific, and these signs can also be expressed in urachal mucinous adenocarcinoma.<sup>[19–21]</sup> As for the enhanced CT scan signs, most literatures were not mentioned, with only 2 patients who were clearly pointed out with no enhancement, and another 2 patients who showed minimal peripheral enhancement. In conclusion, CT scan provides accurate information of position, size, and invasion for urachal lesions, but the value for qualitative diagnosis is limited. Several characteristics in CT scan including intracapsular separation, calcification, and enhancement may only give us some tips, but cannot give a definite diagnosis.

Pathologically, all patients showed mucinous cysts with abundant mucin, no matter whether there was papillary or loculated structures. Microscopically, the cyst wall of all cases was lined by the epithelium covered by atypical columnar cells

with nuclear pleomorphism and less polarity, which were the most reliable bases for diagnosis of low malignant potential. Apart from this, the absence of invasive signs including stroma and surrounding or distant organs supported that the disease was not deteriorated. All basic histological presentations were unanimous and supported our diagnosis.

All patients received the radical excision and partial cystectomy. Intraperitoneal lavage and excision of partial peritoneum in patients with PMP were conducted; there was 1 patient who took 5'-deoxy-5-fluorouridine (1200mg/d) orally for 4 years after surgery. The follow-up time ranged from 6 months to 7 years, and no patients showed evidence of recurrence or metastasis.

#### 4. Conclusions

We conclude that the risk of deterioration is low, and early surgical resection and abdominal lavage may maintain long survival time. In our patient, after resection, he was in good condition and had no complications; we forecast that he will have a good prognosis according to our above review. We reported this rare case which is the 10th case in present published researches. We expect that our report will help to supply more data about treatment and biological manifestations of urachal borderline mucinous cystadenoma for further study.

#### References

- [1] Nguyen M, Addicott B, Chu J, et al. Congenital cyst of the umbilical cord. *Fetal Pediatr Pathol* 2016;1–4.
- [2] Young S, McGeechan A, Davidson P, et al. Management of the giant umbilical cord: challenging the need for investigations in the newborn. *Archives of disease in childhood Fetal and neonatal edition* 2016.

- [3] Naiditch JA, Radhakrishnan J, Chin AC. Current diagnosis and management of urachal remnants. *J Pediatr Surg* 2013;48:2148–52.
- [4] Paner GP, Lopez-Beltran A, Sirohi D, et al. Updates in the pathologic diagnosis and classification of epithelial neoplasms of urachal origin. *Adv Anat Pathol* 2016;23:71–83.
- [5] Paul AB, Hunt CR, Harney JM, et al. Stage 0 mucinous adenocarcinoma in situ of the urachus. *J Clin Pathol* 1998;51:483–4.
- [6] Carr NJ, Mclean AD. A mucinous tumour of the urachus: adenoma or low grade mucinous cystic tumour of uncertain malignant potential? *Adv Clin Path* 2001;5:93–7.
- [7] Stenhouse G, Mcrae D, Pollock AM. Urachal adenocarcinoma in situ with pseudomyxoma peritonei: a case report. *J Clin Pathol* 2003;56:152–3.
- [8] Shinohara T, Misawa K, Sano H, et al. Pseudomyxoma peritonei due to mucinous cystadenocarcinoma in situ of the urachus presenting as an inguinal hernia. *Int J Clin Oncol* 2006;11:416–9.
- [9] Schell AJ, Nickel CJ, Isotalo PA. Complex mucinous cystadenoma of undetermined malignant potential of the urachus. *Can Urol Assoc J* 2009;3:E39.
- [10] Choi JW, Lee JH, Kim YS. Urachal mucinous tumor of uncertain malignant potential: a case report. *Korean J Pathol* 2012;46:83–6.
- [11] Agrawal AK, Bobiński P, Grzebieniak Z, et al. Pseudomyxoma peritonei originating from urachus: case report and review of the literature. *Curr Oncol* 2014;21:e155.
- [12] Prakash MR, Vijayalaxmi SV, Maitreyee R, et al. Complex mucinous cystadenoma of undetermined malignant potential of the urachus: a rare case with review of the literature. *Malays J Pathol* 2014; 36:145.
- [13] Chahal D, Martens M, Kinahan J. Mucinous cystic tumour of low malignant potential presenting in a patient with prior non-seminatous germ cell tumour. *Can Urol Assoc J* 2015;9:E750–753.
- [14] Mittal R, Chandramohan A, Moran B. Pseudomyxoma Peritonei: Natural History and Treatment. *Int J Hyperthermia* 2017;33:511–9.
- [15] Sugarbaker PH, Verghese M, Yan TD, et al. Management of mucinous urachal neoplasm presenting as pseudomyxoma peritonei. *Tumori* 2008;94:732–6.
- [16] Soto DM, Pedrero MG, Varo SC, et al. [Mucinous adenocarcinoma of the urachus and peritoneal pseudomyxoma]. *Actas Urologicas Españolas* 2006;30:222.
- [17] Serretta V, Gesolfo CS, Di Maida F, et al. The clinical value of PSA increase during intravesical adjuvant therapy for nonmuscle-invasive bladder cancer. *Urologia* 2016;83:145–8.
- [18] Bevan KE, Mohamed F, Moran BJ. Pseudomyxoma peritonei. *World J Gastrointest Oncol* 2010;2:44.
- [19] Liang L, Zhou N, Xu H, et al. Urachal mucinous adenocarcinoma with pseudomyxoma peritonei: a case report. *Medicine* 2017;96:e7548.
- [20] Yu HH, Leong CH. Carcinoma of the urachus: report of one case and a review of the literature. *Surgery* 1975;77:726–9.
- [21] Thali-Schwab CM, Woodward PJ, Wagner BJ. Computed tomographic appearance of urachal adenocarcinomas: review of 25 cases. *Eur Radiol* 2005;15:79–84.