

Case Report

Effectiveness of Cross Double McDonald Cerclage for Intractable Bleeding from a Cervical Varix in Pregnant Women

Yuya Fujibe, Tasuku Mariya*, Masahito Mizuuchi, Shinichi Ishioka, Tsuyoshi Saito

Department of Obstetrics and Gynecology, Sapporo Medical University School of Medicine, Sapporo, Japan

Abstract

Cervical varix during pregnancy is a rare condition, and standard management for bleeding from a varix has not been established. We performed cross double cervical cerclage and effectively stopped bleeding. A 41-year-old female had a twin pregnancy. The development of a cervical varix was observed during pregnancy and bleeding from ruptured varix started at 20 weeks of gestation. We performed surgical hemostasis by cervical cerclage. In the first cerclage, we could not stop the bleeding from the varix. For further restriction of blood supply to the cervical varix, we performed a second cerclage in a crossed position on a deeper side of the vagina than the first cerclage. Then the bleeding completely stopped and there was no bleeding until delivery. The “cross double McDonald cerclage” performed in our patient may be a useful modified cerclage method for stopping intractable bleeding from the cervix during pregnancy.

Keywords: Haemostasis, uterine cervix cerclage

INTRODUCTION

Cervical varix during pregnancy may cause moderate to severe hemorrhage if varix ruptures.^[1] Some reported cases needed termination of pregnancy or hysterectomy for uncontrollable bleeding.^[2,3]

In our case, massive hemorrhage caused by the rupture of cervical varix occurred at 20 weeks of gestation. She needed a blood transfusion and the bleeding could not be controlled by conservative treatment using gauze packing. Therefore, after a detailed explanation about the surgery, we tried cervical cerclage for hemostasis. We were able to stop the bleeding using a modified double McDonald cerclage technique. The clinical course and the method are described in detail in the following.

CASE REPORT

A 41-year-old woman, G1P0, had a DD (dichorionic-diamniotic) twin pregnancy by *in vitro* fertilization after

2 years of treatment for primary infertility. She had a history of cervical conization for adenocarcinoma *in situ*. At 20 weeks of gestation, she visited our hospital with a complaint of abnormal bleeding from her vagina. We found abnormal development of cervical varix by vaginal ultrasound and the bleeding seemed to be caused by varix. We performed vaginal gauze packing for hemostasis and the bleeding was decreased for a week. We performed a cervical pap test at that time and the result was negative for intraepithelial lesion or malignancy (NILM). However, at 21 weeks of gestation, massive bleeding occurred and the amount of bleeding reached almost 800 g. We recommended surgical hemostasis or termination of the pregnancy, but she refused both opinions because of the risks of the surgery, including infection and premature rupture of the membrane, and she wished to have further preservative treatment. Therefore,

Address for correspondence: Dr. Tasuku Mariya,

Department of Obstetrics and Gynecology, Sapporo Medical University School of Medicine, South 1 West 17, Chuo-Ku, Sapporo 060-8556, Japan.
E-mail: mariya.tasuku@sapmed.ac.jp

Article History:

Submitted: 11 June 2020

Revised: 13 July 2020

Accepted: 12 August 2020

Published: 3 August 2021

Access this article online

Quick Response Code:



Website:
www.e-gmit.com

DOI:
10.4103/GMIT.GMIT_74_20

This is an open access journal, and articles are distributed under the terms of the Creative Commons Attribution-NonCommercial-ShareAlike 4.0 License, which allows others to remix, tweak, and build upon the work non-commercially, as long as appropriate credit is given and the new creations are licensed under the identical terms.

For reprints contact: WKHLRPMedknow_reprints@wolterskluwer.com

How to cite this article: Fujibe Y, Mariya T, Mizuuchi M, Ishioka S, Saito T. Effectiveness of cross double mcdonald cerclage for intractable bleeding from a cervical varix in pregnant women. *Gynecol Minim Invasive Ther* 2021;10:177-80.

we added vaginal gauze packing once more and observed her with the administration of blood transfusion. However, the bleeding persisted and the amount of bleeding gradually increased. The total amount of bleeding reached about 2000 g at 22 weeks of gestation. We informed her that the bleeding was becoming life-threatening and that we must perform surgical treatment or termination of the pregnancy. She and her husband finally accepted to try surgical hemostasis by cervical cerclage.

Under spinal anesthesia, we detected two bleeding points on the surface of the cervix caused by rupture of cervical varix, the findings of a developed varix by vaginal ultrasound seemed to be match the bleeding points [Figure 1a]. We gently held the cervix with the varix using second uterine forceps and performed the first cerclage by the usual McDonald cerclage method using Teflon tape, enclosing the ruptured points of the varix. However, the bleeding only decreased slightly after the first cerclage and the bleeding persisted from each ruptured point. Therefore, we performed a second cerclage at a 45° rotated position on a deeper side of the vagina than the first cerclage. After the second cerclage, bleeding completely stopped. Vaginal ultrasound in color Doppler examination showed that the blood supply to the cervix appeared to be greatly decreased [Figure 1b]. Total operative time was 29 min, and blood loss was 1650 g.

After hemostasis by the cross double cerclage, there was no vaginal bleeding until delivery. From 30 weeks of gestation, the fetuses showed a discrepancy in estimated fetal weight. The second twin showed selective intrauterine growth restriction (sIUGR) even though her pregnancy was

dichorionic, and we suspected an effect of the surgery for cervical varix, but the cause was undetectable antenatally. Finally, we performed a cesarean section due to the significant growth arrest of the second twin at 34 weeks gestation. The first twin was male with a weight of 2010 g (appropriate for dates) and the second twin was female with a weight of 1248 g (small for dates). The placenta of the second twin showed velamentous insertion of the umbilical cord. We diagnosed velamentous insertion as the cause of the growth restriction of the second twin. Cervical varix rapidly disappeared after delivery of the fetuses, and the bleeding did not persist and needed no further treatment. We could remove the two Teflon tapes immediately after the cesarean section without any trouble. The patient was discharged from the hospital without any problems after surgery, and the babies were also discharged without any complications after temporary treatment in the neonatal care unit.

DISCUSSION

During pregnancy, general varices in the legs, vulva, and hemorrhoidal plexus are commonly observed in approximately 15% of all pregnancies. However, a uterine cervical varix is rare.^[3] It was previously reported that the risk of uterine cervical varices was increased by exposure to diethylstilbestrol (DES) during pregnancy.^[3] However, there have been few such reports recently DES has been defined as a contraindication to pregnancy. Some studies have suggested a relationship of cervical varices with surgeries for uterine cervixes such as trachelectomy and conization.^[1,4] The invasiveness of surgeries may induce the development of the vessels in uterine cervixes.

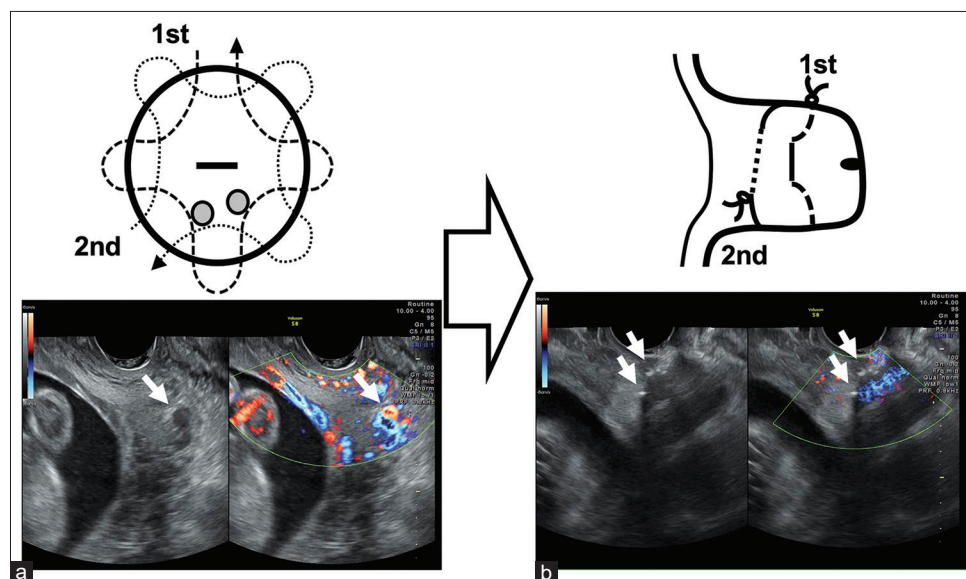


Figure 1: Method for cross double McDonald cerclage and findings in intraoperative transvaginal ultrasound. (a) Routes of the cross double cerclages and the bleeding point (gray circle), and the bleeding points are marked with a white triangle in transvaginal ultrasound. (b) Sagittal view from the right side of the cervix after cerclage, and sutured strings (marked with a white triangle)

Table 1: Reported cases of abnormal bleeding from cervical varix in pregnancy

Report	Age	Gravida/ Parity	GA at diagnosis	GA at termination	Treatment	Position of placenta	Reason for termination	Delivery mode	Blood loss
Follen <i>et al.</i> (1985)	32	4/3	22	35	Gauze packing, bed rest	NA	NA	(g)	NA
	31	5/1	13	31		NA	PROM		NA
	32	3/0	28	Term	Cervical cerclage, bed rest Gauze packing, bed rest	NA	-		NA
Fleming <i>et al.</i> (1993)	26	2/1	13	14	Cervical cerclage	NA	PROM	CS	NA
Hurton <i>et al.</i> (1998)	33	3/0	33	34	Tocolysis	Not low	Abnormal bleeding	CS with hysterectomy	5000
Yohimura <i>et al.</i> (2004)	34	1/0	18	27	Tocolysis, bed rest	Previa	Bleeding from previa	CS	920
Kusanovic <i>et al.</i> (2006)	26	3/0	21	32	Tocolysis, gauze packing	Low lying	Tocolysis failure, abnormal bleeding	CS	NA
Kumazawa <i>et al.</i> (2007)	30	1/0	27	32	Tocolysis, gauze packing	Previa	Tocolysis failure	CS	1814
Present case	41	1/0 DD twin	20	34	Double cerclage tocolysis, bed rest	Low lying	Fetal growth restriction	CS	3643

GA: Gestational age (week), CS: Cesarean section, VD: Vaginal delivery, NA: Not assessed; PROM: preterm rupture of membranes, DD twin: dichorionic diamniotic twin

As far as we know, there have been only 14 published cases of cervical varices that included eight cases of vaginal bleeding with cervical varices. The previously reported cases and our case are summarized in Table 1.^[2,5-9]

In eight of the nine cases, live infants were born between 27 weeks and 35 weeks of gestation by cesarean section, only one case being a term vaginal delivery. The main reason for the termination of pregnancy was vaginal bleeding of a cervical varix (2 of the 9 cases). Four of the nine cases were complicated with placenta previa or low-lying placenta. Placenta previa or low-lying placenta may contribute to the development of cervical varices through increased volume of the uterine cervical vasculature. In our case, the placenta was in a low position and the delivery mode was cesarean section due to significant growth restriction of the second twin not to vaginal bleeding. The pathology of the placenta revealed that the cause of selective IUGR was the velamentous insertion of the cord. In all cases, treatment was needed to stop the bleeding of the cervical varix. Cervical cerclage was performed in three of the nine cases. In one case, 1 week after cerclage placement, spontaneous abortion occurred due to premature rupture of the membrane.^[6] In the two other cases (including our case), cerclage was effective for hemostasis and the duration of pregnancy was extended for 14 weeks and 18 weeks. On the other hand, preservative treatments such as bed rest and packing extended the pregnancy by only 8.5 weeks on average.

Fleming and Anderson. first reported the use of cervical cerclage for preventing bleeding of cervical varix in 1993.^[6] Tsai *et al.* first reported double cerclage, but their purpose was preventing preterm labor, not bleeding of cervical varix. However, the reported double cerclages were not crossed position.^[10] In the present case, we performed the second cerclage in a rotated cross position for more efficient restriction of blood flow, as shown in Figure 1b. We explained to the patient about the risk of necrosis of the cervix by the loss of the blood supply after surgery. However, the condition we feared did not occur. We think that the gap between the two cerclages may have supplied the minimum necessary blood flow to the cervix. As for the difficulty of the method, we could perform the first and second cerclages without any failure even in poor condition of the operating field caused by massive bleeding from cervical varix and severe defect of the cervix. McDonald cerclage is an easier method than Shirodkar cerclage for cervical cerclage, and in the second cerclage, we can tug and control the cervix by holding the string of the first cerclage. Therefore, we could set the second cerclage on a deeper side of the cervix effectively without any problem.

Finally, we conclude that cross double McDonald cerclage is an effective and reliable method for hemostasis of a ruptured cervical varix. This method should be tried before consideration of termination of pregnancy in an early phase of pregnancy.

Declaration of patient consent

The authors certify that they have obtained all appropriate patient consent forms. In the form, the patient has given her consent for her images and other clinical information to be reported in the journal. The patient understands that name and initials will not be published and due efforts will be made to conceal identity, but anonymity cannot be guaranteed.

Financial support and sponsorship

Nil.

Conflicts of interest

There are no conflicts of interest.

REFERENCES

1. Brown JV 3rd, Mills MD, Wong H, Goldstein BH. Large volume cervical varix bleeding in a gravid patient. *Gynecol Oncol Case Rep* 2012;4:20-2.
2. Hurton T, Morrill H, Mascola M, York C, Bromley B. Cervical varices: An unusual etiology for third-trimester bleeding. *J Clin Ultrasound* 1998;26:317-9.
3. Tanaka M, Matsuzaki S, Kumasawa K, Suzuki Y, Endo M, Kimura T. Cervical varix complicated by placenta previa: A case report and literature review. *J Obstet Gynaecol Res* 2016;42:883-9.
4. Okugawa K, Kobayashi H, Sonoda K, Kaneki E, Kawano Y, Hidaka N, *et al.* Oncologic and obstetric outcomes and complications during pregnancy after fertility-sparing abdominal trachelectomy for cervical cancer: A retrospective review. *Int J Clin Oncol* 2017;22:340-6.
5. Follen MM, Fox HE, Levine RU. Cervical vascular malformation as a cause of antepartum and intrapartum bleeding in three diethylstilbestrol-exposed progeny. *Am J Obstet Gynecol* 1985;153:890-1.
6. Fleming AD, Anderson TL. Cervical AV malformation with in utero DES exposure. *Nebr Med J* 1993;78:138-9.
7. Yoshimura K, Hirsch E, Kitano R, Kashimura M. Cervical varix accompanied by placenta previa in twin pregnancy. *J Obstet Gynaecol Res* 2004;30:323-5.
8. Kusanovic JP, Soto E, Espinoza J, Stites S, Gonçalves LF, Santolaya J, *et al.* Cervical varix as a cause of vaginal bleeding during pregnancy: Prenatal diagnosis by color Doppler ultrasonography. *J Ultrasound Med* 2006;25:545-9.
9. Kumazawa Y, Shimizu D, Hosoya N, Hirano H, Ishiyama K, Tanaka T. Cervical varix with placenta previa totalis. *J Obstet Gynaecol Res* 2007;33:536-8.
10. Tsai YL, Lin YH, Chong KM, Huang LW, Hwang JL, Seow KM. Effectiveness of double cervical cerclage in women with at least one previous pregnancy loss in the second trimester: A randomized controlled trial. *J Obstet Gynaecol Res* 2009;35:666-71.