

# Sebaceous carcinoma of the penis: As aggressive as it is rare

Ranil Johann Boaz, Chandan Phukan, Mandeep S<sup>1</sup>, Antony Devasia

Departments of Urology and <sup>1</sup>Pathology, Christian Medical College, Vellore, Tamil Nadu, India

**Abstract** Malignant neoplasm of the penis is a rare cancer in industrialized countries but is not uncommon in India. Nearly 95% of penile cancer is squamous cell carcinoma. Malignant neoplasms of the sebaceous glands, which are mostly confined to the head and neck region, are even rarer. We present a 74-year-old male with sebaceous cell carcinoma of the penis. He underwent excision of the primary lesion with bilateral inguinal lymph node dissection followed by adjuvant chemotherapy.

**Keywords:** Penis, sebaceous carcinoma, treatment

**Address for correspondence:** Dr. Chandan Phukan, Department of Urology, Christian Medical College, Vellore, Tamil Nadu, India.

E-mail: drchandanph@yahoo.com

Received: 01.10.2018, Accepted: 01.02.2019

## INTRODUCTION

Carcinoma of the sebaceous glands of the penis is extremely rare. Only five verifiable cases have been documented. They metastasize mainly to the regional lymphnodes. The treatment has been largely on the same lines as penile squamous cell carcinoma (SCC).

## CASE REPORT

A 74-year-old-man presented with a growth adjacent to the root of the penis. He had undergone a circumcision at another center 6 months ago for a preputial lesion. A review of slides revealed sebaceous carcinoma. On examination, there were nontender, subcentimeter, firm, pearly-white nodules at the margin of the scar of circumcision. In addition, there was a nontender, 2 cm × 2 cm, proliferative nodular lesion to the left of the penile base with induration of the surrounding skin [Figure 1]. Bilateral inguinal lymph nodes were palpable and mobile. Fine needle aspiration of the nodes detected metastatic carcinoma. His case was discussed in

the multidisciplinary team meet, and he was planned for radical excision of the lesion followed by chemotherapy. He underwent excision of both the coronal and suprapubic lesions with bilateral inguinal lymphadenectomy and flap coverage. Biopsies of the primary penile lesions as well as the suprapubic lesion were consistent with multicentric, well-differentiated sebaceous carcinoma with lymphovascular invasion. Hemotoxylin and eosin section of the skin showed skin covered fibrocollagenous tissue infiltrated by tumor composed of sheets, nests, islands, and cords of polygonal cells with moderately pleomorphic, mitotically active, vesicular to hyperchromatic, round to oval nuclei with visible nucleoli, and moderate eosinophilic cytoplasm. There was no definite evidence of keratinization. There were foci of continuation with overlying epidermis. Immunohistochemistry was positive for epithelial membrane antigen and BerEP4 [Figure 2]. He was administered adjuvant chemotherapy (Carboplatin/Paclitaxel). He died at home 3 months after the operation having completed 2 cycles of chemotherapy.

This is an open access journal, and articles are distributed under the terms of the Creative Commons Attribution-NonCommercial-ShareAlike 4.0 License, which allows others to remix, tweak, and build upon the work non-commercially, as long as appropriate credit is given and the new creations are licensed under the identical terms.

**For reprints contact:** reprints@medknow.com

**How to cite this article:** Boaz RJ, Phukan C, Mandeep S, Devasia A. Sebaceous carcinoma of the penis: As aggressive as it is rare. *Urol Ann* 2019;11:226-8.

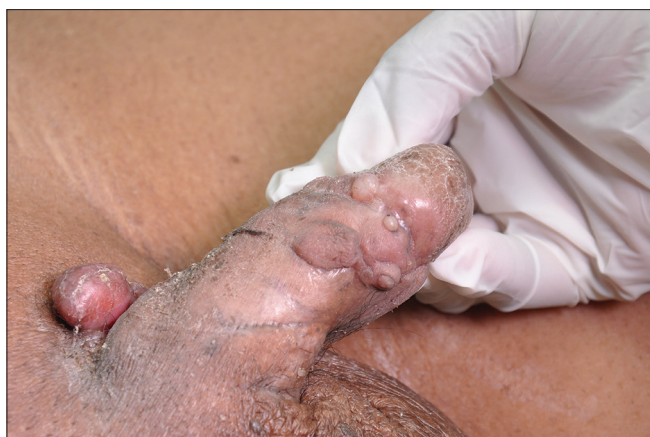Access this article online	
Quick Response Code:	Website: www.urologyannals.com
	DOI: 10.4103/UA.UA_139_18

## DISCUSSION

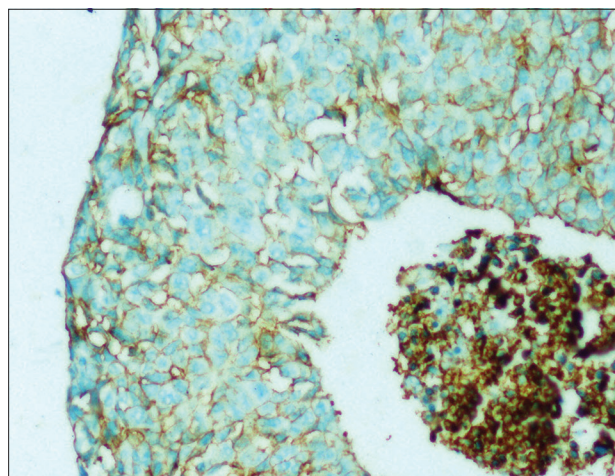
Malignant neoplasms of the sebaceous glands are rare and also remarkable for their aggressive nature. Sebaceous carcinoma arises from the adnexal epithelium of the gland. The majority of reported cases of sebaceous carcinoma are located in the head and neck region.<sup>[1]</sup> Sebaceous glands are not typically found on the skin of the penis, and the ectopic appearance of these is called Fordyce spots.

Penile carcinoma is of squamous cell origin in >95% of cases. A large retrospective review of nonsquamous penile carcinoma found only one case of sebaceous malignancy among their cohort of 12 cases of nonsquamous carcinoma which in turn comprised 8.5% of all penile carcinomas.<sup>[2]</sup> Only five verifiable cases of penile sebaceous carcinoma have been reported.<sup>[3-5]</sup> The clinicopathologic behavior of penile sebaceous carcinoma appears different to other extraorbital sites which have a lower propensity to metastasize.<sup>[1]</sup> Recent data for sebaceous carcinoma show an overall rate of regional metastasis in the region between 3% and 12%.<sup>[6]</sup> However, penile sebaceous carcinoma has a propensity for regional lymph node metastasis. Three out of five cases reported had bilateral palpable inguinal lymph nodes at presentation and underwent inguinal lymphadenectomies. Two out of these three had biopsy-proven nodal metastasis. Ornellas *et al.* described their use of lymph node sampling based on preoperative lymphoscintigraphy followed by sentinel node biopsy to assess regional nodal status.<sup>[5]</sup>

Sebaceous carcinomas are generally treated with wide local excision. Regional lymphadenectomy is performed if clinically significant nodes are found. Sebaceous carcinomas of the penis have been largely treated on the same lines as penile SCC. Existing reports are compared in Table 1.<sup>[3-5]</sup> Two cases were treated with local excision, the other four required either partial penile amputation (three) or radical penile amputation. All except one case underwent bilateral inguinal lymphadenectomies. Of the patients requiring penile amputations, the longest documented disease survival was 18 months. Two out of four died within 6 months of surgery. Adjuvant chemotherapy is an option for regional metastasis and recurrence; however, data are limited and the optimal regimen is yet to be defined. Due to paucity of cases, there is no standard protocol of chemotherapy. It was shown by Mellette *et al.* that the biological behavior of extraorbital sebaceous carcinoma is not different from the orbital sebaceous carcinoma.<sup>[6]</sup> Hence, by extrapolating the treatment of orbital sebaceous cell carcinoma, the protocol may be six cycles of 3 weekly paclitaxel and carboplatin.<sup>[7]</sup> This was administered to the index patient. Histopathological predictors of poor prognosis include multicentric origin, tumor dimension >1 cm, lymphovascular invasion, and pagetoid spread.<sup>[8]</sup> We encountered all of these adverse predictors in addition to regional node metastasis which undoubtedly contributed to the poor outcome. The histologic differential diagnosis of sebaceous carcinoma includes basal



**Figure 1:** 2 cm × 2 cm, proliferative nodular lesion to the left of the penile base



**Figure 2:** The immunohistochemistry positivity for BerEP4

**Table 1: A comparison of inguinal lymph nodal status and outcome across all reported cases**

	Operation for penile primary	Palpable inguinal nodes	Inguinal lymph node dissection	Period of follow up (months)	Status at last follow-up
Current report	Local excision	Yes	Yes	3	Deceased
Ornellas <i>et al.</i>	Partial amputation	No	No	18	Alive
Ornellas <i>et al.</i>	Partial amputation	Yes	Yes	12	Alive
Ornellas <i>et al.</i>	Partial amputation	Yes	Yes	5	Deceased
Wick <i>et al.</i>	Radical amputation	Yes	No	6	Deceased
Oppenheim <i>et al.</i>	Local excision	No	No	36	Alive

cell carcinoma, SCC, Paget disease, and melanoma. While extraorbital carcinoma has been considered less aggressive, with better prognosis than periorbital disease, the limited data on penile sebaceous carcinoma suggests a tendency toward regional metastasis resulting in poorer prognosis than sebaceous carcinoma at other sites. Sentinel lymph node biopsy has been advocated for both periorbital and extraorbital disease; however, its questionable negative predictive value and low-yield have not changed the need for close follow-up in patients with a negative sentinel node biopsy. For a penile primary with clinically negative groins, a bilateral modified inguinal lymphadenectomy is likely to be of greater value in view of poor outcomes without locoregional control as well as limited evidence for benefit with chemotherapy.

**Learning points:** Sebaceous carcinoma must be considered in the differential diagnosis of atypical penile lesions. Sentinel lymph node biopsy or modified inguinal lymphadenectomy are likely to be of value in clinically negative groins given the propensity for nodal spread.

#### **Financial support and sponsorship**

Nil.

#### **Conflicts of interest**

There are no conflicts of interest.

#### **Declaration of patient consent**

The authors certify that they have obtained all appropriate patient consent forms. In the form the patient(s) has/have given his/her/their consent for his/her/their images and other clinical information to be reported in the journal. The patients understand that their names and initials will not be published and due efforts will be made to conceal their identity, but anonymity cannot be guaranteed.

#### **REFERENCES**

1. Dasgupta T, Wilson LD, Yu JB. A retrospective review of 1349 cases of sebaceous carcinoma. *Cancer* 2009;115:158-65.
2. Moses KA, Sfakianos JP, Winer A, Bernstein M, Russo P, Dalbagni G, et al. Non-squamous cell carcinoma of the penis: Single-center, 15-year experience. *World J Urol* 2014;32:1347-53.
3. Oppenheim AR. Sebaceous carcinoma of the penis. *Arch Dermatol* 1981;117:306-7.
4. Wick MR, Goellner JR, Wolfe JT 3<sup>rd</sup>, Su WP. Adnexal carcinomas of the skin. II. Extraocular sebaceous carcinomas. *Cancer* 1985;56:1163-72.
5. Ornellas AA, Frota R, Lopes da Silva LF, Dauster B, Quirino R, de Santos Schwandt AB, et al. Sebaceous carcinoma of the penis. *Urol Int* 2009;82:477-80.
6. Mellette JR, Amonette RA, Gardner JH, Chesney TM. Carcinoma of sebaceous glands on the head and neck. A report of four cases. *J Dermatol Surg Oncol* 1981;7:404-7.
7. Joshi P, Joshi A, Norohna V, Prabhaskar K, Kane S, D'cruz AK, et al. Sebaceous carcinoma and systemic chemotherapy. *Indian J Med Paediatr Oncol* 2012;33:239-41.
8. Kyllö RL, Brady KL, Hurst EA. Sebaceous carcinoma: Review of the literature. *Dermatol Surg* 2015;41:1-15.