



Case report

Nodular glomerulosclerosis in a patient with cystic fibrosis, but not diabetes mellitus: A paediatric case

A.D. Lalayiannis^{a,*}, C. Thompson^a, R. Malcomson^b, D.V. Milford^a^a Nephrology Department, Birmingham Children's Hospital, Steelhouse Lane, Birmingham, B4 6NH, United Kingdom^b Histopathology Department, Leicester Royal Infirmary, Infirmary Square, Leicester, LE1 5WW, United Kingdom

ARTICLE INFO

Article history:

Received 11 January 2016

Received in revised form

7 July 2016

Accepted 11 July 2016

Keywords:

Cystic fibrosis

Insulin dependent diabetes mellitus (IDDM)

Kimmelstiel-Wilson nodules

Nodular glomerulosclerosis

ABSTRACT

Background: Nodular glomerulosclerosis is seen in insulin dependent diabetic patients with nephropathy. Kimmelstiel-Wilson nodules on biopsy are considered pathognomonic. Diabetic nephropathy is a spectrum of glomerular and tubular disease which correlates with the duration of the diabetes and the extent of glycaemic control.

Case report: An eleven year old girl with cystic fibrosis was referred with persistent heavy proteinuria. She underwent a renal biopsy which revealed nodular glomerulosclerosis with Kimmelstiel-Wilson-like nodules. Her investigations for diabetes were negative and she was treated with enalapril.

Conclusion: Nodular glomerulosclerosis in the absence of diabetes and poor glycaemic control have not previously been reported in a paediatric patient. In adult patients without diabetes, smoking, hypertension, hypercholesterolaemia and extrarenal vascular disease have been implicated.

The proteinuria decreased after commencement of treatment with enalapril. A recurrence of proteinuria responded to a dose increase.

© 2016 The Authors. Published by Elsevier Ltd. This is an open access article under the CC BY-NC-ND license (<http://creativecommons.org/licenses/by-nc-nd/4.0/>).

1. Background

Cystic Fibrosis is one of the commonest autosomal recessive conditions in Europe [1]. Almost 2000 mutations have been identified in the cystic fibrosis transmembrane conductance regulator (CFRT) gene, which affect secretory and epithelial cells with the cAMP-activated chloride channel, resulting in low secretion volume and increased viscosity [2]. Cystic fibrosis is a multisystem disease and the kidneys are amongst the affected organs. However, a specific renal phenotype has not been linked to any mutation despite the CFRT protein being widely expressed throughout the kidney [3]. Many renal co-morbidities have been described in the context of cystic fibrosis. These include low molecular weight proteinuria, membranoproliferative glomerulonephritis, hypercalciuria, nephrocalcinosis, amyloidosis and diabetic nephropathy. Acute kidney injury is also well recognised in the context of non-steroidal anti-inflammatory and aminoglycoside drug use [4], [5], [6].

Insulin dependent diabetes mellitus (IDDM) is a well-recognised consequence of the abnormal CFRT protein expressed in the pancreas. Cystic fibrosis patients with diabetes mellitus (CFDM) are

as prone to developing late diabetic complications such as retinopathy, nephropathy and neuropathy as patients with other causes of IDDM and similar glycaemic control [7].

However, in the absence of clinical hyperglycaemia or impaired glycaemic control there have been a few cases reported of diabetic nephropathy in adult patients; i.e. nodular glomerulosclerosis and Kimmelstiel-Wilson (KW) nodules on renal biopsy [8,3], [9], [10]. To our knowledge, there is no reported case of nodular glomerulosclerosis and diabetic nephropathy in a paediatric patient with cystic fibrosis in the absence of hyperglycaemia or confirmed IDDM.

2. Case report

An eleven year old girl with cystic fibrosis was referred by her local paediatrician following an incidental discovery of proteinuria in a routine cystic fibrosis clinic.

She was born at 36 weeks gestation after an uneventful pregnancy and was diagnosed with CF after birth due to meconium ileus producing a distended abdomen. This required surgical treatment for the resulting bowel perforation with resection of a segment of bowel and an end-to-end anastomosis. Molecular genetic analysis showed a homozygous mutation for $\Delta F508$. She had a generally uneventful disease progress with occasional courses of oral and

* Corresponding author.

E-mail address: alexander.lalayianis@nhs.net (A.D. Lalayiannis).

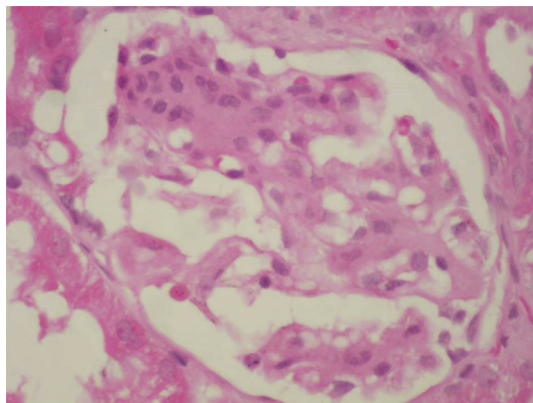


Fig. 1. A glomerulus showing a segmental nodular lesion with mesangial hypercellularity and a nodular area of mesangial matrix expansion reminiscent of a Kimmelsteil-Wilson nodule. Haematoxylin & Eosin stain.

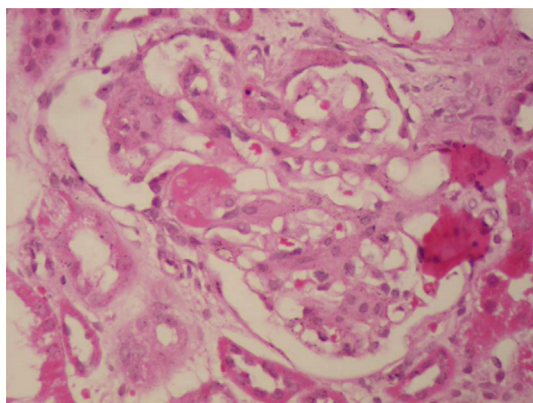


Fig. 2. Hyalinosis of a glomerular hilar arteriole and nodular appearance of the glomerular tufts. Haematoxylin & Eosin stain.

intravenous antibiotics for lower respiratory infections, and grew pseudomonas only on one occasion, with all sputum cultures negative thereafter.

She had primary nocturnal enuresis treated with a pad and alarm system, allowing her to be dry by six and a half years old. Glycosuria was documented once at this point but was not found on repeat testing. Her urine was regularly dip tested at her cystic fibrosis outpatient appointments and although she had transient proteinuria at 6 years of age this resolved at subsequent clinic visits. Five years later at the age of 11, parental dip testing of urine at home showed persistent proteinuria and microscopic haematuria. Early morning urine protein/creatinine ratio showed heavy proteinuria on two occasions (343 mg/mmol & 395 mg/mmol, normal <20 mg/mmol). She was not hypertensive. She had structurally normal kidneys and urinary tract on ultrasound scan. In addition, her renal function, cholesterol, triglycerides, albumin and complement levels were normal.

Due to the persistent proteinuria, she underwent a renal biopsy. Of the 71 glomeruli seen, three showed global sclerosis, one displayed a fibrous crescent, one showed capsular adhesion and four demonstrated subcapsular hyalinosis. The remainder showed mild, focal segmental increase in mesangial matrix with hints of Kimmelsteil Wilson nodules and a capsular adhesion at the tubular origin and capsular drops on the inside of Bowman's capsule (Fig. 1). There was patchy tubular atrophy, some arterioles showed hyalinosis and the small arteries exhibited mild thickening of the walls (Fig. 2). There was no evidence of amyloid on Congo Red staining. IgA and IgG staining was negative, but there was diffuse mesangial deposition of IgM and C9 was deposited in focal segmental capillary loops. On electron microscopy there was effacement of the podocyte foot processes, involving less than 5% of the surface area. The basement membrane was structurally normal with a mean thickness of 509 nm (range 360–645 nm; expected mean for age 310 nm with a range of 190–440 nm). The features seen were consistent with diabetic glomerulopathy with no chronic renal damage.

Following the biopsy, she was investigated for diabetes despite not being glycosuric. An oral glucose tolerance test performed at her local hospital showed mildly elevated readings at 30 and 60 mins (12.0 & 13.3 mmol/L) but she returned to normoglycaemia at 2 and 3 hours. Due to the abnormal first two readings, she had 2 days of pre and post prandial capillary glucose testing, which proved normal. She also had a normal HbA1c of 5.8% (3.6%–6.8%). Following discussions with endocrinology a diagnosis of IDDM was

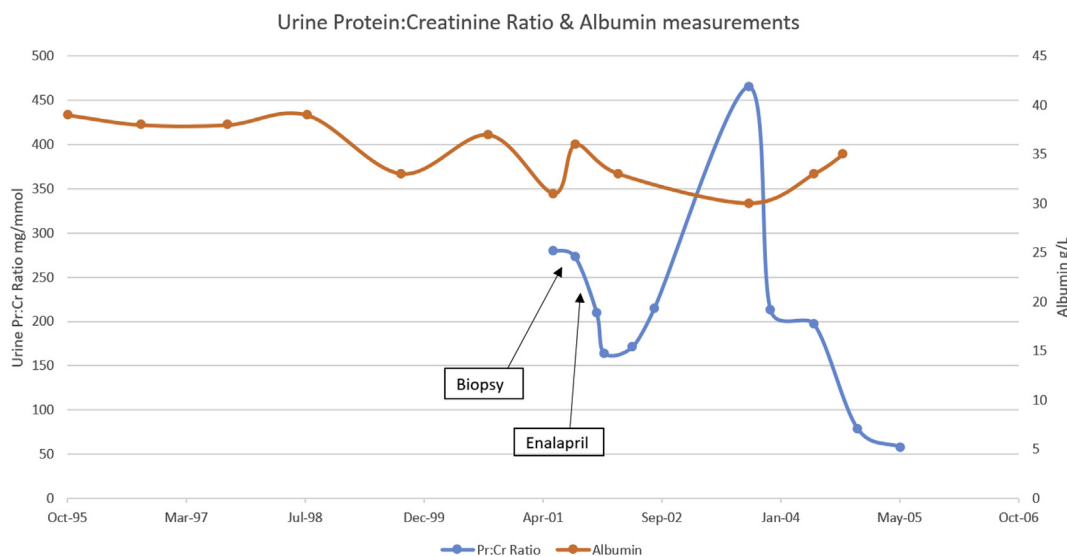


Fig. 3. Urine protein:creatinine ratio and serum albumin measurements during follow up.

not made and no specific therapy was recommended. As part of her assessment she had an ophthalmology review which did not reveal diabetic retinopathy. No glycosuria was documented during the subsequent 5 years of renal follow up at our centre and she remained diabetes free during her local centre follow up until the age of 22 when she moved to a different centre.

After the biopsy she was treated with enalapril with a reduction in proteinuria-(Fig. 3). She was transferred to adult services aged 17 years and subsequently required an increased dose of enalapril because of an increase in proteinuria; she declined a repeat biopsy.

3. Discussion

We report an eleven year old girl with cystic fibrosis who underwent a renal biopsy for persistent proteinuria and was found to have Kimmelstiel-Wilson-like nodules and nodular glomerulosclerosis despite not being diagnosed with IDDM, and not developing diabetes for 11 years after the biopsy. Kimmelstiel Wilson nodules are reported to be pathognomonic of diabetic nephropathy. They were first described in 1936 and were originally found in 8 adult onset diabetes patients [11].

Diabetic nephropathy is a spectrum of evolving glomerular changes determined by the severity and duration of poor glycaemic control. Initially, thickened glomerular basement membranes and mild mesangial expansion is noted. This leads to increased mesangial expansion which is nodular (Kimmelstiel-Wilson nodules), hyaline deposits in the arterioles, and grossly thickened glomerular basement membranes are evident on electron microscopy. There is also concurrent thickening of the tubular basement membranes. This is followed by interstitial fibrosis and tubular atrophy [12].

Nodular glomerulosclerosis has been reported in the absence of diabetes in adult patients as a distinct clinical entity. This, however, was in the context of hypertension, smoking, hypercholesterolaemia and extrarenal vascular disease [13]. All of the aforementioned were absent in our patient. To our knowledge there have been no cases reported of KW nodules in paediatric patients in the absence of diabetes.

The persistent proteinuria was initially well controlled with enalapril but subsequently recurrence prior to transfer to adult

services required a dose increase. She refused a second biopsy to monitor any progress or changes at this stage.

In conclusion, nodular glomerulosclerosis is seen in diabetes mellitus patients with nephropathy. Kimmelstiel-Wilson nodules were previously thought to be pathognomonic. Diabetic nephropathy is a spectrum of glomerular and tubular disease which correlates with the duration of the diabetes and the extent of glycaemic control. The renal biopsy findings of diabetic nephropathy have been noted in adults without diabetes, but have not been previously noted in a paediatric patient. The pathophysiology of these lesions is presently not known.

References

- [1] Y. Yahiaoui, M. Jablonski, D. Hubert, Renal involvement in cystic fibrosis: diseases spectrum and clinical relevance, *Clin. J. Am. Soc. Nephrol.* 4 (5) (2009 May) 921–928.
- [2] J.C. Davies, A.M. Ebdon, C. Orchard, Recent advances in the management of cystic fibrosis, *Archives Dis. Child.* 99 (11) (2014) 1033–1036.
- [3] G.P. Westall, J. Binder, T. Kotsimbos, Nodular glomerulosclerosis in cystic fibrosis mimics diabetic nephropathy, *Nephron Clin. Pract.* 96 (3) (2004) 70–75.
- [4] A.M. McLaughlin, T.B. Crotty, J.J. Egan, Amyloidosis in cystic fibrosis: a case series, *J. Cyst. Fibros.* 5 (1) (2006 January) 59–61.
- [5] E. Soriano, D. Fischman, P. Cheriyaath, Membranoproliferative Glomerulonephritis in patients with cystic fibrosis: coincidence or comorbidity? A case series, *South. Med. J.* 101 (6) (2008 June) 641–645.
- [6] C. Bertenshaw, A.R. Watson, S. Lewis, Survey of acute renal failure in patients with cystic fibrosis in the UK, *Thorax* 62 (6) (2007 January) 541–545.
- [7] S. Lanng, B. Thorsteinsson, C. Lund-Andersen, Diabetes Mellitus in Danish cystic fibrosis patients: prevalence and late diabetic complications, *Acta Paediatr.* 83 (1) (1994 January) 72–77.
- [8] K. Walsh, J. Wright, Idiopathic nodular glomerulosclerosis in non diabetic patients, *Br. J. Ren. Med.* 17 (1) (2012) 26–28.
- [9] C.S. Chang, A.H. Yang, C.H. Chang, Nodular glomerulosclerosis mimicking diabetic nephropathy without overt diabetes mellitus, *Clin. Nephrol.* 64 (4) (2005 October) 300–304.
- [10] D.A.J. Nash, R.W. Rogers, P.C. Langlinais, S.M.J. Bunn, Daibetic glomerulosclerosis without glucose intolerance, *Am. J. Med.* (1975 August) 191–199.
- [11] T.W.C. Tervaert, A.L. Mooyaart, K. Amann, Pathologic classification of Diabetic nephropathy, *J. Am. Soc. Nephrol.* 21 (4) (2010) 556–563.
- [12] B. Najafian, C.E. Alpers, A.B. Fogo, Pathology of human diabetic nephropathy, *Contrib. Nephrol.* (2011) 36–47.
- [13] G.S. Markowitz, J. Lin, A.M. Valeri, C. Avila, Idiopathic Nodular Glomerulosclerosis is a distinct clinicopathologic entity linked to hypertension and smoking, *Hum. Pathol.* 33 (8) (2002) 826–835.