




REVIEW

Management of the patient with failed hypospadias surgery presenting in adulthood [version 1; referees: 3 approved]

Reem Aldamanhori ^{1,2}, Christopher R. Chapple¹

¹Department of Urology, Royal Hallamshire Hospital, Sheffield, UK

²Department of Urology, University of Dammam, Dammam, Saudi Arabia

v1 **First published:** 26 Oct 2017, 6(F1000 Faculty Rev):1890 (doi: 10.12688/f1000research.11980.1)




Latest published: 26 Oct 2017, 6(F1000 Faculty Rev):1890 (doi: 10.12688/f1000research.11980.1)

Abstract

The management of patients who have had complications of primary surgery for the resolution of a hypospadiac deformity remains a therapeutic challenge. Adults with complications following childhood hypospadias repairs are undoubtedly a difficult population to treat, as there is usually a cosmetic deformity, lower urinary tract symptoms, and resulting psychosexual consequences. A surgeon's experience has been and still remains an important factor in determining subsequent surgical outcomes, particularly with more severe or complex cases. The purpose of this review is to evaluate the complications of hypospadias repair that present in adults and review published experience in treating them.

Open Peer Review

Referee Status: 

	Invited Referees		
	1	2	3
version 1 published 26 Oct 2017			

F1000 Faculty Reviews are commissioned from members of the prestigious F1000 Faculty. In order to make these reviews as comprehensive and accessible as possible, peer review takes place before publication; the referees are listed below, but their reports are not formally published.

- 1 **James Elmore**, Georgia Urology, USA
- 2 **Luis Braga**, McMaster University, Canada
- 3 **Marco Castagnetti**, University Hospital of Padova, Italy

Discuss this article

Comments (0)

Corresponding author: Reem Aldamanhori (reembaher@gmail.com)

Author roles: Aldamanhori R: Writing – Original Draft Preparation; Chapple CR: Writing – Review & Editing

Competing interests: The authors declare that they have no competing interests.

How to cite this article: Aldamanhori R and Chapple CR. **Management of the patient with failed hypospadias surgery presenting in adulthood [version 1; referees: 3 approved]** *F1000Research* 2017, 6(F1000 Faculty Rev):1890 (doi: [10.12688/f1000research.11980.1](https://doi.org/10.12688/f1000research.11980.1))

Copyright: © 2017 Aldamanhori R and Chapple CR. This is an open access article distributed under the terms of the [Creative Commons Attribution Licence](https://creativecommons.org/licenses/by/4.0/), which permits unrestricted use, distribution, and reproduction in any medium, provided the original work is properly cited.

Grant information: The author(s) declared that no grants were involved in supporting this work.

First published: 26 Oct 2017, 6(F1000 Faculty Rev):1890 (doi: [10.12688/f1000research.11980.1](https://doi.org/10.12688/f1000research.11980.1))

Hypospadias is seen in around one in 300 live births, making it the most prevalent congenital penile abnormality¹. Surgeons who perform hypospadias surgeries come from diverse specialty groups (pediatric surgery, plastic surgery, or urology). Consequently, preferred surgical technique and results vary significantly between different surgeons. Not surprisingly, the experience of the surgeon is also strongly associated with outcomes of hypospadias surgical repair², particularly when the length of the defect is greater. There is a steep learning curve for attaining surgical skill in primary hypospadias surgery, with limited long-term data on surgical outcomes, a dearth of information on patient-reported outcome measures, and limited reported expertise in redo surgery. Surgeons with subspecialist training in hypospadias surgery might be expected to achieve better outcomes with fewer complications than those without. If this is the case with primary hypospadias repair, then, inevitably, correcting the consequences of hypospadiac repair failure might be best managed in a specialized referral center.

In the absence of long-term follow-up and the limited number of centers providing transitional care from childhood to adulthood, there are limited long-term follow-up data. It can be speculated that the neourethra (a man-made tube) may fail to grow adequately in keeping up with the rest of the genital tissues during puberty, which may create a narrow or short tube. Due to rapid genital growth during puberty, some complications, including strictures, may not present until this time. In addition, it is assumed that the congenital lack of spongiosum covering the neourethra in those patients may not provide adequate vascular support to the urethra during this time. Similarly, it can be postulated that the trauma sustained during erection and sexual activity is not tolerated by the neourethra owing to lack of spongiosal support. The exact nature and range of complications in adulthood after childhood hypospadias repair remain poorly defined³. In order to address this, pediatric urologists should follow-up hypospadias patients with severe hypospadias and those who underwent major repairs through puberty and again during the mid-teens until the completion of sexual maturity to detect latent urethral strictures.

Most studies on complications after hypospadias surgery have described only the complications occurring shortly after pediatric hypospadias surgery restricted to the childhood period. Roughly 30% of patients who undergo an initially successful repair in childhood end up with complications in adulthood, suggesting that the outcomes of repair may not be as durable as estimated by studies with short-term follow-up⁴. Common complications that may require surgical resolution include meatal stenosis, urethrocutaneous fistulae, urethral stricture, persistent hypospadias, diverticula, and chordee. A further consideration, which is very important, is whether there is an associated skin condition such as balanitis xerotica obliterans (BXO), which would exclude the use of skin. The true incidence of urethral strictures is difficult to define because of a lack of series with long-term follow-up. Urethral strictures have been reported to be the second most common complication of hypospadias repair in the pediatric population with an incidence of 6.5%⁵ and 10% of cases⁶. Conversely, in a study of 74 adult patients who presented to a reconstructive urologist with complications related to prior hypospadias correction in childhood, urethral stricture disease

was prevalent in 53%, and 57% of these patients underwent surgical correction³. Although with any surgery some complications are unavoidable, there are certain factors that increase the chance of developing complications. These include poor surgical technique, postoperative infection, wound dehiscence, urine extravasation, hematoma, ischemia, and necrosis of the flap or graft used, leading to poor healing of the reconstructed tissue⁷.

According to the American Academy of Pediatrics, the ideal age for hypospadias surgery is between 6 and 12 months. It is suggested that healing at this age occurs more promptly with less severe scarring⁸. A study by Perlmutter *et al.*⁹ reported considerably higher re-operation rate for hypospadias repair in infants older than 6 months than in younger ones, but this study did not take into account other potentially confounding variables, and this assertion has been challenged by a number of other authors^{10,11}. A study by Snodgrass and colleagues suggested that increasing age does not indicate a greater risk for urethroplasty complications after hypospadias surgery¹⁰. Furthermore, a recent study in the pediatric population by Snodgrass and Bush¹² reported that urethroplasty complications doubled in those undergoing a second hypospadiac urethroplasty compared with those undergoing a primary repair. This risk increased to 40% with three or more re-operations, with a 1.5-fold increase in complication rate with each surgery.

A patient with failed hypospadiac repair presenting in adulthood will have a more densely scarred penis, with less vascular and less pliable tissues to work with¹³. Therefore, repeated attempts at surgical repair in those complicated cases are less likely to succeed. That is evident in a study by Hensle *et al.*¹⁴, where in an adult group of patients who underwent hypospadias repair, complications were noted in 37.5% of patients who had no previous hypospadias surgery, 41.67% of patients who had undergone one or more procedures in childhood but in whom local tissue was relatively intact, and 63.6% of patients who underwent multiple unsuccessful hypospadias repairs with various degrees of penile deformity and loss of local tissue. Other studies concluded that although the number of surgeries for the correction of primary hypospadias may represent a risk factor for surgical failure, it was stricture length, not the number of previous operations needed for primary hypospadias repair, that was significantly associated with a risk of failure¹⁵.

Patients with complications following hypospadias repair are a difficult population to treat. They could be left with deformities significantly worse than the primary congenital anomaly. The unanimous finding in the literature is that complications are significantly greater for re-operations than for primary repairs using the same surgical technique. This suggests the need for careful patient selection, modification of techniques for re-operation, and consideration of novel procedures not commonly used for primary repair¹⁶.

Careful patient analysis is fundamental in choosing the technique, thereby attaining a successful salvage repair outcome¹⁷. Careful and structured evaluation at the outpatient clinic is the key to the proper choice of surgical technique. Assessment of meatal site

and size, stricture length, presence of surrounding tissue integrity and quality that might help in closure, size of the penis and glans, presence of fistulae, and degree of curvature are all important in deciding which repair technique should be used. Careful counseling of patients before surgery, taking into account their aspirations and giving them a realistic expectation of functional and sexual functional outcome, is essential. Even in seemingly simple cases, other issues are frequently seen, such as fistulae, scarring, recurrent chordee, and an abnormal meatus, often related to a small glans, and nearly always with a deficiency of the dartos layer¹⁸, often with underlying associated psychosexual problems. Options for re-operative urethroplasty after failed hypospadias surgery include the use of either a flap or a graft to create a new urethra; this might be done in a single stage or usually over multiple stages depending on the extent of the repair needed. In particular, in addition to any underlying tissue deficiency, the presence of chordee, which has to be released, will often lead to proximal migration of the urethral meatus. Thus, treatment of strictures of the urethra and/or a meatal stenosis as a result of previous hypospadias surgery usually needs to be individualized.

There are several reported surgical techniques for the repair of complications after failed hypospadias repair in adults. The main principles of repair include excision of fibrosis to release any chordee and excision of scar tissue, which may include part, or even the whole length, of the previous urethroplasty, with any surrounding fibrous tissue. An adequate glans cleft is then created with the inlay of a graft or flap. The graft is secured to the corpora cavernosa from the proximal meatus out to the tip of the glans. If it is feasible, distal, and uncomplicated with good surrounding tissues and the urethroplasty segment is short, the creation of a neourethra and reconstruction of the glans can be done in one stage. If it is proximal and lengthy and needs a more extensive reconstruction and there is a deficiency of skin and subcutaneous tissues and dartos, it is best performed as a staged procedure with the inlay of a graft or flap and a subsequent closure procedure. Adequate time between staged procedures is needed for proper tissue healing and neovascularization to occur. This usually takes an average of 4–6 months. Patients are then evaluated in the outpatient clinic after the first stage to ensure that adequate healing has occurred with any significant fibrous contracture of the first stage and/or stenosis of the proximal urethral meatus. In some cases, a revision of the first stage might be necessary to deal with tissue contracture and/or inadequate take of the graft. Subsequently, to ensure optimal results, the final stage (closure) should include a watertight neourethral closure with good vascularized overlying tissue cover. In particular, care is taken not to overlap the suture lines in order to mitigate against fistula formation. The neourethra is reconstructed over a catheter or stent to divert the urine for 10–14 days with appropriate prophylactic antibacterial cover. In some cases, in our experience after the first stage procedure, a patient may decide to remain with the first stage rather than risk complications such as a meatal stenosis or chordee.

In a series of nine patients with adult urethral stricture disease after childhood hypospadias repair, three patients chose to receive repeated endoscopic treatments (visual internal urethrotomy and/or dilatations), and all of those cases had recurrence of the stricture¹⁹. This confirms experience with urethrotomy for stricture disease

in the penile urethra where urethrotomy cannot be recommended as a curative treatment. Reconstructive techniques including one-stage procedures (flaps or grafts) or multistage procedures with penile skin or buccal mucosa and even bladder mucosa have been described in the literature. There is controversy in the existing literature over which method should be chosen to treat this difficult situation, but in our view it is evident that therapy should be individualized to the patient following a careful evaluation, as noted above. In a series of primary repair, a comparison of flaps versus grafts has noted no significant difference in the complication rates when used to repair proximal hypospadias in children²⁰. Hypospadias repair with a bladder mucosa graft is feasible, although not popular, and long-term follow-up data are lacking. A series reported by Li *et al.*²¹ showed their experience in using a free bladder mucosa graft in failed hypospadias in adolescents and adults with an 87.6% success and 12.4% complication rate after a follow-up ranging from 3 months to 2 years. In contrast, in another series in which bladder mucosa was used as a tube graft neourethra, graft contracture and fistula formed. Bladder mucosa for urethroplasty after hypospadias repair did not achieve the same results in both studies¹⁴. The use of buccal mucosa as a substitute material in one-stage procedures showed complications requiring further surgery in between 24%²² and 32%²³ of patients. Currently, the use of bladder mucosa has become far less common with increased use of oral mucosa. In another series, multistage procedures using buccal mucosa grafts reported complication rates of 10 to 35%²⁴. In a series reported by Tang *et al.*¹⁹, four out of nine cases underwent urethroplasty with buccal mucosal grafts—single-stage repair was performed in two and two-stage repair was performed in another two—and two out of nine cases underwent salvage perineal urethrostomy. In a series by Barbagli *et al.*⁷, 60 adults with previously failed hypospadias repair included 34 cases that underwent treatment for urethral stricture recurrence. There was an 87% success rate with one-stage repair without grafts, an 80% success rate with one-stage techniques using penile skin, and an 82% success rate with one-stage techniques using buccal mucosa. Multistage repairs delivered 50% success with penile skin and those with buccal mucosa provided 82% success. The one-stage direct repair without graft provided a higher success rate compared to the use of skin or buccal mucosa grafts, but these procedures were applied to simpler cases not requiring the use of substitution material for the urethral reconstruction. The one-stage techniques provided higher success rates when compared to multistage techniques, probably not surprisingly as the cases were less complex and required a shorter length of substitution. Those who needed multistage repairs showed a higher risk of failure because they had more severe strictures and extremely poor-quality native tissue than those considered for a single-stage repair. In multistage procedures, the buccal mucosa was superior to penile skin, showing a higher success rate.

Most studies state the outcome of the procedures without a clear description of inclusion/exclusion criteria used in decision making. In a reported series of hypospadias reoperation in children, an operation decision-making algorithm was centered on the presence or absence of an elastic urethral plate. When the urethral plate had no visible scarring, a TIP (tubularized incised plate) procedure was performed. If the urethral plate was previously excised but a skin strip without visible scarring remained in its location, one-stage

inlay grafting was used. When the urethral plate, residual skin, or neourethra was visibly scarred, or there was a persistent ventral curvature greater than 30 degrees, hair in the neourethra, or suspicion of BXO, all grossly abnormal tissues were excised back to healthy urethra and a two-stage buccal graft urethroplasty was performed¹⁶.

A significant portion of adults with hypospadias complications ultimately requires surgical intervention. Strictures in adults who had a hypospadias repair in childhood are usually complex; the neourethra usually contains skin from the earlier repair. Our experience over the last 35 years supports the observation that the longer the length of the previous repair, the more likely a stricture is to develop and the more complicated the stricture is likely to be²⁵. Urethral strictures in hypospadias failure can occur decades after initial hypospadias surgery and in view of their complexity often require multiple surgical procedures for their resolution¹⁹. Although the impact of hypospadias repair almost unquestionably continues through adulthood, the majority of hypospadias studies lack long-term follow-up into adulthood²⁶. This is clearly shown by a survey of patients evaluated for failed hypospadias repair in a single reference center²⁷. Ideally, therefore, patients undergoing hypospadias surgery may receive lifelong follow-up but should at the very least be counseled to seek advice if they develop symptoms such as voiding difficulty and erectile deformity.

In adults with complications after failed hypospadias repair, no single procedure is considered standard of care. It is rare to see

a patient who just needs a simple straightforward repair. Usually, taking down the previous urethroplasty and creating a new urethra, requiring more than one stage, is necessary. Owing to the variability of the deformities seen and the consequent functional abnormality, each patient should be evaluated as a separate entity and the treatment should be individualized. It is a challenging surgery, which needs comprehensive experience in the field of reconstruction. It must be borne in mind that any complex reconstructive procedure of this type has to be considered to comprise two phases—one has to take apart before putting back together—therefore, the surgeon's experience is an important factor associated with a successful outcome⁴. Nevertheless, all methods of urethral repair in this group of patients have the potential to fail; therefore, it is important to extend the follow-up after any such surgery, particularly in the more complex cases.

In the future, more attention needs to be placed on patient-reported outcome measures, taking into account cosmetic appearance, sexual function, and the patient's wishes^{28,29}.

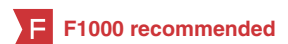Competing interests

The authors declare that they have no competing interests.

Grant information

The author(s) declared that no grants were involved in supporting this work.

References



- Nelson CP, Park JM, Wan J, *et al.*: **The increasing incidence of congenital penile anomalies in the United States.** *J Urol.* 2005; **174**(4 Pt 2): 1573–6.
[PubMed Abstract](#) | [Publisher Full Text](#)
- F** Ansari MS, Agarwal S, Sureka SK, *et al.*: **Impact of changing trends in technique and learning curve on outcome of hypospadias repair: An experience from tertiary care center.** *Indian J Urol.* 2016; **32**(3): 216–20.
[PubMed Abstract](#) | [Publisher Full Text](#) | [Free Full Text](#) | [F1000 Recommendation](#)
- F** Hoy NY, Rourke KF: **Better Defining the Spectrum of Adult Hypospadias: Examining the Effect of Childhood Surgery on Adult Presentation.** *Urology.* 2017; **99**: 281–6.
[PubMed Abstract](#) | [Publisher Full Text](#) | [F1000 Recommendation](#)
- F** Ching CB, Wood HM, Ross JH, *et al.*: **The Cleveland Clinic experience with adult hypospadias patients undergoing repair: their presentation and a new classification system.** *BJU Int.* 2011; **107**(7): 1142–6.
[PubMed Abstract](#) | [Publisher Full Text](#) | [F1000 Recommendation](#)
- Duel BP, Barthold JS, Gonzalez R: **Management of urethral strictures after hypospadias repair.** *J Urol.* 1998; **160**(1): 170–1.
[PubMed Abstract](#) | [Publisher Full Text](#)
- Wray RC Jr, Ribaldo JM, Weeks PM: **The Byars hypospadias repair. A review of 253 consecutive patients.** *Plast Reconstr Surg.* 1976; **58**(3): 329–31.
[PubMed Abstract](#) | [Publisher Full Text](#)
- Barbagli G, De Angelis M, Palminteri E, *et al.*: **Failed hypospadias repair presenting in adults.** *Eur Urol.* 2006; **49**(5): 887–94; discussion 895.
[PubMed Abstract](#) | [Publisher Full Text](#)
- Timing of elective surgery on the genitalia of male children with particular reference to the risks, benefits, and psychological effects of surgery and anesthesia. *American Academy of Pediatrics. Pediatrics.* 1996; **97**(4): 590–4.
[PubMed Abstract](#)
- Perlmutter AE, Morabito R, Tarry WF: **Impact of patient age on distal hypospadias repair: a surgical perspective.** *Urology.* 2006; **68**(3): 648–51.
[PubMed Abstract](#) | [Publisher Full Text](#)
- F** Bush NC, Holzer M, Zhang S, *et al.*: **Age does not impact risk for urethroplasty complications after tubularized incised plate repair of hypospadias in prepubertal boys.** *J Pediatr Urol.* 2013; **9**(3): 252–6.
[PubMed Abstract](#) | [Publisher Full Text](#) | [F1000 Recommendation](#)
- F** Snodgrass W, Villanueva C, Bush N: **Primary and reoperative hypospadias repair in adults—are results different than in children?** *J Urol.* 2014; **192**(6): 1730–3.
[PubMed Abstract](#) | [Publisher Full Text](#) | [F1000 Recommendation](#)
- F** Snodgrass W, Bush NC: **Re-operative urethroplasty after failed hypospadias repair: how prior surgery impacts risk for additional complications.** *J Pediatr Urol.* 2017; **13**(3): 289.e1–289.e6.
[PubMed Abstract](#) | [Publisher Full Text](#) | [F1000 Recommendation](#)
- Stecker JF Jr, Horton CE, Devine CJ Jr, *et al.*: **Hypospadias cripples.** *Urol Clin North Am.* 1981; **8**(3): 539–44.
[PubMed Abstract](#)
- Hensle TW, Tennenbaum SY, Reiley EA, *et al.*: **Hypospadias repair in adults: adventures and misadventures.** *J Urol.* 2001; **165**(1): 77–9.
[PubMed Abstract](#) | [Publisher Full Text](#)
- Barbagli G, Fossati N, Larcher A, *et al.*: **Pd60-04 Predictive Factors Of Success In Adult Patients Treated For Urethral Stricture After Primary Hypospadias Repair Failure: A Multivariable Analysis Of A Single-Surgeon Series.** *J Urol.* 2017; **197**(4): e1184.
[Publisher Full Text](#)
- Snodgrass WT, Bush N, Cost N: **Algorithm for comprehensive approach to hypospadias reoperation using 3 techniques.** *J Urol.* 2009; **182**(6): 2885–91.
[PubMed Abstract](#) | [Publisher Full Text](#)
- van der Werff JF, van der Meulen JC: **Treatment modalities for hypospadias**

- cripples. *Plast Reconstr Surg.* 2000; **105**(2): 600–8.
[PubMed Abstract](#) | [Publisher Full Text](#)
18. Mundy AR: **Failed hypospadias repair presenting in adults.** *Eur Urol.* 2006; **49**(5): 774–6.
[PubMed Abstract](#) | [Publisher Full Text](#)
 19. **F** Tang S, Hammer CC, Doumanian L, *et al.*: **Adult urethral stricture disease after childhood hypospadias repair.** *Adv Urol.* 2008; **2008**: 150315.
[PubMed Abstract](#) | [Publisher Full Text](#) | [Free Full Text](#) | [F1000 Recommendation](#)
 20. Powell CR, Mcaleer I, Alagiri M, *et al.*: **Comparison of flaps versus grafts in proximal hypospadias surgery.** *J Urol.* 2000; **163**(4): 1286–8; discussion 1288–9.
[PubMed Abstract](#) | [Publisher Full Text](#)
 21. Li LC, Zhang X, Zhou SW, *et al.*: **Experience with repair of hypospadias using bladder mucosa in adolescents and adults.** *J Urol.* 1995; **153**(4): 1117–9.
[PubMed Abstract](#) | [Publisher Full Text](#)
 22. Fichtner J, Filipas D, Fisch M, *et al.*: **Long-term followup of buccal mucosa onlay graft for hypospadias repair: analysis of complications.** *J Urol.* 2004; **172**(5 Pt 1): 1970–2; discussion 1972.
[PubMed Abstract](#) | [Publisher Full Text](#)
 23. Hensle TW, Kearney MC, Bingham JB: **Buccal mucosa grafts for hypospadias surgery: long-term results.** *J Urol.* 2002; **168**(4 Pt 2): 1734–6; discussion 1736–7.
[PubMed Abstract](#)
 24. **F** Snodgrass W, Elmore J: **Initial experience with staged buccal graft (Bracka) hypospadias reoperations.** *J Urol.* 2004; **172**(4 Pt 2): 1720–4; discussion 1724.
[PubMed Abstract](#) | [Publisher Full Text](#) | [F1000 Recommendation](#)
 25. **F** Breyer BN, McAninch JW, Whitson JM, *et al.*: **Multivariate analysis of risk factors for long-term urethroplasty outcome.** *J Urol.* 2010; **183**(2): 613–7.
[PubMed Abstract](#) | [Publisher Full Text](#) | [F1000 Recommendation](#)
 26. **F** Turchi A, Hoebcke P: **Long-term outcome of male genital reconstruction in childhood.** *J Pediatr Urol.* 2013; **9**(6 Pt B): 980–9.
[PubMed Abstract](#) | [Publisher Full Text](#) | [F1000 Recommendation](#)
 27. Sansalone S, Barbagli G, Iacovelli V, *et al.*: **A natural history of primary and failed hypospadias repair in a selected series of 408 patients.** *European Urology Supplements.* 2016; **15**(8): 371.
[Publisher Full Text](#)
 28. Castagnetti M: **Childhood hypospadias repairs--do they stand the test of time?** *J Urol.* 2015; **193**(3): 756–7.
[PubMed Abstract](#) | [Publisher Full Text](#)
 29. **F** Cimador M, Vallasciani S, Manzoni G, *et al.*: **Failed hypospadias in paediatric patients.** *Nat Rev Urol.* 2013; **10**(11): 657–66.
[PubMed Abstract](#) | [Publisher Full Text](#) | [F1000 Recommendation](#)

Open Peer Review

Current Referee Status:



Editorial Note on the Review Process

F1000 Faculty Reviews are commissioned from members of the prestigious F1000 Faculty and are edited as a service to readers. In order to make these reviews as comprehensive and accessible as possible, the referees provide input before publication and only the final, revised version is published. The referees who approved the final version are listed with their names and affiliations but without their reports on earlier versions (any comments will already have been addressed in the published version).

The referees who approved this article are:

Version 1

- 1 **Marco Castagnetti** University Hospital of Padova, Padova, Italy
Competing Interests: No competing interests were disclosed.
- 1 **Luis Braga** McMaster University, Hamilton, ON, Canada
Competing Interests: No competing interests were disclosed.
- 1 **James Elmore** Georgia Urology, Atlanta, GA, USA
Competing Interests: No competing interests were disclosed.