

Crohn's Disease Initially Accompanied by Deep Vein Thrombosis and Ulnar Neuropathy without Metronidazole Exposure

Woohyeon Kim, Borami Kang, Byung-Wook Kim, Joon Sung Kim, Hae-Mi Lee, Eun-Joo Lim, Jong In Kim, Bong-Koo Kang, Jeong-Seon Ji, Bo-In Lee, and Hwang Choi

Division of Gastroenterology, Department of Internal Medicine, Incheon St. Mary's Hospital, The Catholic University of Korea College of Medicine, Incheon, Korea

Extraintestinal manifestations are not uncommon in Crohn's disease, and a thromboembolic event is a disastrous potential complication. Deep vein thrombosis is the most common manifestation of a thromboembolic event and typically occurs in association with active inflammatory disease. Peripheral neuropathy in Crohn's disease has rarely been reported and is considered an adverse effect of metronidazole therapy. Here, we describe a patient who was initially diagnosed with Crohn's disease complicated with deep vein thrombosis and ulnar neuropathy without metronidazole exposure. The simultaneous occurrence of these complications in the early stage of Crohn's disease has never been reported in the English literature. (**Gut Liver 2013;7:252-254**)

Key Words: Crohn disease; Venous thrombosis; Mononeuropathies

INTRODUCTION

Crohn's disease (CD) can be considered as a systemic disease because such diseases are often associated with extraintestinal manifestations and can involve nearly any organ system including the musculoskeletal, dermatologic, hepatopancreatobiliary, ocular, metabolic, renal, vascular, and neurologic systems.¹ Patients with CD have a three-fold increased risk of venous thromboembolism.² The condition usually occurs in active inflammatory diseases.² Peripheral neuropathy is an uncommon late complication of CD and often develops after exposure to metronidazole, although it does occur without metronidazole exposure. Peripheral neuropathy without drug exposure is known to be associated with CD activity and usually causes complications later in the disease process. Here, we report a pa-

tient who was initially diagnosed with CD complicated by deep vein thrombosis (DVT) and ulnar neuropathy without metronidazole exposure. To our knowledge, this occurrence has never been reported in the English literature.

CASE REPORT

A 35-year-old male patient visited emergency department, complaining of hematochezia with diarrhea for 2 days and a weight loss of more than 5 kg over the previous 3 months. Before he visited our hospital, he was managed intermittently in other hospital due to right calf pain for the past 4 months. On physical examination, he looked pale and skin rash was found

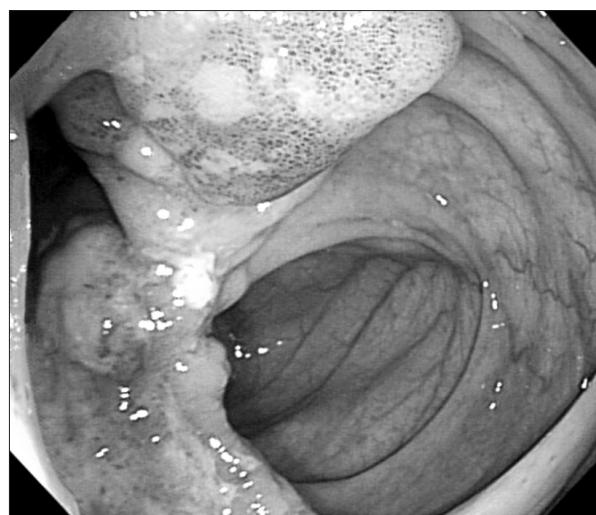


Fig. 1. Initial colonoscopy. Ulceration and deformity are noted at the ileocecal valve.

Correspondence to: Byung-Wook Kim

Division of Gastroenterology, Department of Internal Medicine, Incheon St. Mary's Hospital, The Catholic University of Korea College of Medicine, 56 Dongsu-ro, Bupyeong-gu, Incheon 403-720, Korea

Tel: +82-32-280-5052, Fax: +82-32-280-5987, E-mail: gastro@catholic.ac.kr

Received on September 22, 2011. Revised on December 28, 2011. Accepted on January 9, 2012.

pISSN 1976-2283 eISSN 2005-1212 <http://dx.doi.org/10.5009/gnl.2013.7.2.252>

© This is an Open Access article distributed under the terms of the Creative Commons Attribution Non-Commercial License (<http://creativecommons.org/licenses/by-nc/3.0>) which permits unrestricted non-commercial use, distribution, and reproduction in any medium, provided the original work is properly cited.

on right calf. Left forearm paresthesia was noted on neurologic examination. He denied smoking and has been worked as an office manager. We could not find any risk factors for DVT on his past medical history. Colonoscopic examination showed multiple ulcerations near the ileocecal valve, which was compatible with CD (Fig. 1). Histologic examination revealed granuloma. The CD activity index was 191 at initial diagnosis.

On admission, physical examination revealed moderate right calf erythema, tenderness, and positive Homan's sign. Lower extremity computed-tomography angiogram confirmed the presence of DVT (Fig. 2). Laboratory tests were unremarkable except for decreased hemoglobin (12.1 g/dL) and elevated C-reactive protein (47.96 mg/L). The tests for hypercoagulable states including cardiolipin immunoglobulin G/immunoglobulin M, lupus anticoagulant, β 2-glycoprotein I antibody, plasminogen activator inhibitor, thrombin time, antithrombin III, factor V/VIII, factor V Leiden, and homocysteine were within the normal range.

Sensory nerve conduction examination of the left ulnar nerve showed low sensory nerve action potential, which was compat-

ible with ulnar nerve mononeuropathy (Fig. 3).

Mesalamine and folic acid treatment was initiated and warfarin was administered after heparinization. Rehabilitational support for ulnar nerve mononeuropathy was also initiated. Left forearm paresthesia has been disappeared with the improvement of CD activity index down to 36. The patient's condition improved and was discharged 2 months later.

DISCUSSION

A large cohort study showed that the overall incidence of thromboembolic events is 6.15% in inflammatory bowel disease (IBD) patients.² Systemic thromboembolic events occur in both venous and arterial circulation.³ DVT and pulmonary embolism are the most common types of thromboembolic events in IBD.² Although the contribution of thrombophilic disorders such as factor V Leiden, prothrombin gene mutations and hyperhomocysteinemia have been discussed, no consistent unifying etiology has been determined.^{4,5} It is also plausible that decreased mobility in CD patients is associated with increased risk of DVT.⁶

It has been suggested that activation of the coagulation cascade is more pronounced when the disease is active in IBD.⁷ Persistent inflammatory changes can induce coagulopathy and DVT development in CD is usually delayed. In one report, the median duration of IBD at the time of the first thromboembolic event was 5 years.² In our case, however, the patient initially presented with DVT. Considering the role of increased coagulation in IBD's pathogenesis,⁸ this case suggests that DVT might not be a consequence of long-term progression of CD, but aggressive inflammatory changes in CD within a short time also contributes to the development of DVT.

There are increasing evidences that IBD may manifest in the nervous system.⁹⁻¹¹ Peripheral neuropathy is one of the most frequently reported neurological complications, and several different peripheral neuropathy have been described in IBD patients.¹² Medical treatment with metronidazole or vitamin deficiencies caused by malabsorption have been thought to be responsible for peripheral neuropathy, because the condition usually occurs several years after the initial disease presentation. In one study,

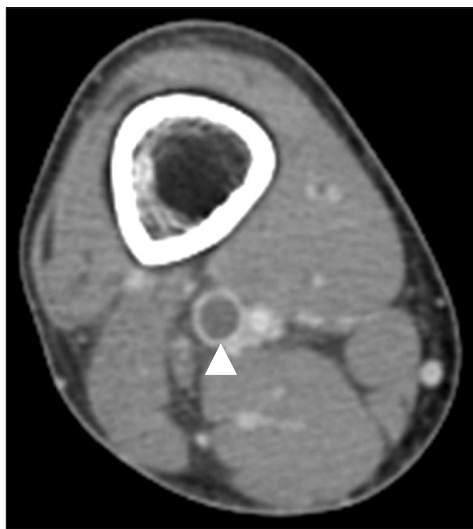


Fig. 2. Computed tomography angiogram of the right lower extremity. A dark filling defect (arrowhead) is visible in the right popliteal vein, which is consistent with deep vein thrombosis.

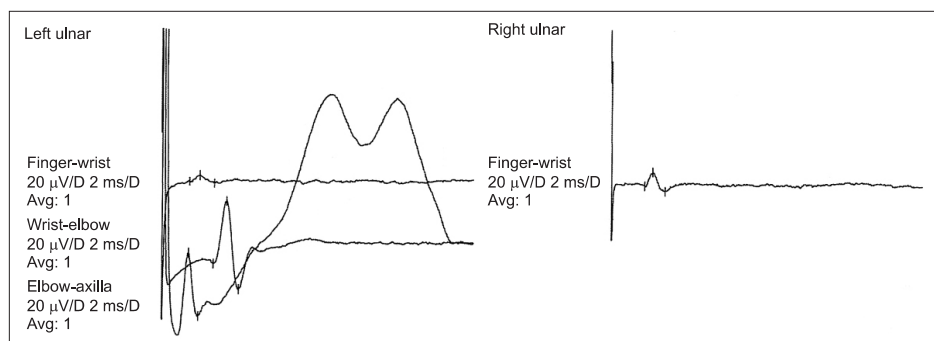


Fig. 3. Sensory nerve conduction study of the left ulnar nerve. Low sensory-nerve action potential is evident over the finger-wrist segment of the left ulnar nerve.

most of the peripheral neuropathy symptoms began 11.8 years after CD onset.¹¹ However, our case presented with peripheral neuropathy initially without exposure to metronidazole.

In conclusion, DVT and peripheral neuropathy could occur as initial presentations of CD. When thromboembolic events and peripheral neuropathy are suspected in CD, proper management including anticoagulation should be initiated immediately to prevent possible lethal complication.

CONFLICTS OF INTEREST

No potential conflict of interest relevant to this article was reported.

REFERENCES

1. Danese S, Semeraro S, Papa A, et al. Extraintestinal manifestations in inflammatory bowel disease. *World J Gastroenterol* 2005;11:7227-7236.
2. Miehsler W, Reinisch W, Valic E, et al. Is inflammatory bowel disease an independent and disease specific risk factor for thromboembolism? *Gut* 2004;53:542-548.
3. Ha C, Magowan S, Accortt NA, Chen J, Stone CD. Risk of arterial thrombotic events in inflammatory bowel disease. *Am J Gastroenterol* 2009;104:1445-1451.
4. Bernstein CN, Blanchard JF, Houston DS, Wajda A. The incidence of deep venous thrombosis and pulmonary embolism among patients with inflammatory bowel disease: a population-based cohort study. *Thromb Haemost* 2001;85:430-434.
5. Srirajakanthan R, Winter M, Muller AF. Venous thrombosis in inflammatory bowel disease. *Eur J Gastroenterol Hepatol* 2005;17:697-700.
6. Pohl JF, Mulne A, Chambers LJ, Neese P. Extensive venous thrombosis in a pediatric patient with Crohn's disease. *Inflamm Bowel Dis* 2009;15:807-808.
7. Souto JC, Martínez E, Roca M, et al. Prothrombotic state and signs of endothelial lesion in plasma of patients with inflammatory bowel disease. *Dig Dis Sci* 1995;40:1883-1889.
8. Koutroubakis IE. Unraveling the mechanisms of thrombosis in inflammatory bowel disease. *Am J Gastroenterol* 2001;96:1325-1327.
9. Elsehety A, Bertorini TE. Neurologic and neuropsychiatric complications of Crohn's disease. *South Med J* 1997;90:606-610.
10. Benavente L, Moris G. Neurologic disorders associated with inflammatory bowel disease. *Eur J Neurol* 2011;18:138-143.
11. Gondim FA, Brannagan TH 3rd, Sander HW, Chin RL, Latov N. Peripheral neuropathy in patients with inflammatory bowel disease. *Brain* 2005;128(Pt 4):867-879.
12. Ståhlberg D, Bárány F, Einarsson K, Ursing B, Elmqvist D, Persson A. Neurophysiologic studies of patients with Crohn's disease on long-term treatment with metronidazole. *Scand J Gastroenterol* 1991;26:219-224.