

Case Report

***Aeromonas hydrophila* sepsis with septic embolism and rhabdomyolysis in a chronic iron overload haemodialysis patient treated with deferoxamine**

Supachat Chompoonuch¹, Wittaya Wangsomboonsiri², Pawinee Wongprasit²,
Somnuek Sungkanuparph² and Bunyong Phakdeekitcharoen³

¹Department of Medicine, ²Division of Infectious Diseases and ³Division of Nephrology, Department of Medicine, Faculty of Medicine, Ramathibodi Hospital, Mahidol University, Bangkok, Thailand

Correspondence and offprint requests to: Bunyong Phakdeekitcharoen; E-mail: rabpd@mahidol.ac.th

Abstract

Aeromonas infection in humans is associated with certain underlying diseases, especially chronic liver disease or malignancy. However, *Aeromonas* infection associated with iron overload is rarely reported. We report a case of a 47-year-old female with end-stage renal disease on haemodialysis and on deferoxamine treatment for iron overload who developed *Aeromonas* sepsis with septic embolism and rhabdomyolysis. Although the patients with *Aeromonas* infection and rhabdomyolysis have been correlated with high mortality, this reported case survived. We suggest that a chronic haemodialysis patient on deferoxamine treatment for iron overload is vulnerable to *Aeromonas* infection. In such cases, the clinician should be alerted to the possibility of rhabdomyolysis, and frequent haemodialysis is necessary.

Keywords: *Aeromonas*; deferoxamine; haemodialysis; rhabdomyolysis

Introduction

Aeromonas hydrophila is a facultative anaerobic gram-negative bacillus that belongs to the *Aeromonadaceae* family. It can be found worldwide in aquatic environments including ground water, drinking water and polluted water [1]. *Aeromonas* infections in humans can be found in various clinical manifestations including gastroenteritis, wound infection, septicaemia, meningitis, peritonitis, respiratory tract disease and ocular infection [1]. The association between a patient with iron overload treated with deferoxamine and *Aeromonas* infection is rarely reported [2]. There has been no report of this association in a chronic haemodialysis patient.

Case report

A 47-year-old female was diagnosed with end-stage renal disease of unknown aetiology and on chronic haemodialysis

twice weekly since 1994. She received a living-related kidney transplant in December 2003. Unfortunately, her transplant was complicated by graft rejection in December 2004 and haemodialysis became necessary in July 2005. In November 2007, she developed anaemia despite receiving 80 U/kg/week of erythropoietin. She was diagnosed with pure red cell aplasia from hypocellular bone marrow and positive anti-EPO in January 2008 and she needed chronic blood transfusions, of about 1–2 units of packed red blood cells per month. She developed iron overload in May 2008 with a serum ferritin level of 2650 ng/mL. She was treated with deferoxamine 1500 mg twice weekly.

In August 2008, the patient was struck by a fish bone in the right hand while she was boning fresh water fish. Subsequently, she developed a high-grade fever and generalized muscle pain the next day. Due to the progressive pain and redness of the wound, she presented to our hospital on the third day of fever.

On admission, the patient's body temperature was 39.2 °C, with a pulse rate of 100/min, a respiratory rate of 24/min and a blood pressure of 140/90 mmHg. The wound at the ridge of her right hand was swollen but there was no fluctuation (Figure 1). Her right hand and right arm were also swollen and tender. Marked generalized muscle tenderness was noted which caused the patient to avoid moving her arms or legs. Initial laboratory investigation revealed that her white blood cell count (WBC) was 9700 cells/mm³ with a neutrophil predominance. The haematocrit was 22.5% and platelet count was 101 000/mm³. Blood biochemistries showed sodium 129 mEq/L, potassium 6.23 mEq/L, chloride 93 mEq/L, bicarbonate 22.8 mEq/L, blood urea nitrogen 84 mg/dL, creatinine 15.9 mg/dL, aspartate transaminase 31 U/L, alanine transaminase 35 U/L and creatinine phosphokinase (CPK) 1218 U/L. Urinalysis was marked positive for blood with marked proteinuria without red blood cell or white blood cell sediment.

Because of the severe sepsis, the patient received meropenem and vancomycin as empirical antibiotics. Blood cultures revealed *Aeromonas hydrophila* that was

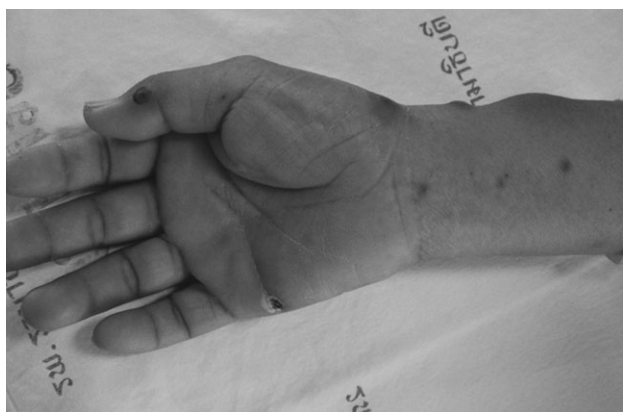

Fig. 1. Multiple lesions of septic embolism on the right arm and old wound from fish bone on the ridge of the hand.

susceptible to the second and third generation of cephalosporins, gentamicin, trimethoprim–sulfamethoxazole and fluoroquinolones. The antibiotics were switched to ceftriaxone after the results of the blood culture. Although fever rapidly subsided within 3 days, the WBC and CPK continued to rise. Meanwhile, she developed pustular skin lesions compatible with septic embolism over all extremities (Figure 1). On the sixth day of admission, ciprofloxacin was added. Cultures from the skin lesion also recovered *A. hydrophila*. WBC peaked at 43 300 cells/mm³ on the 7th day of admission and returned to a normal value on the 15th day. CPK peaked at 13 317 U/L on the fourth day of admission and returned to a normal value on the ninth day (Figure 2). She needed more frequent haemodialysis than her previous schedule during the first few days because of severe hyperkalaemia caused by rhabdomyolysis. No further skin lesion developed after the 11th day of admission. She was discharged on the 19th day of admission. The clinical course is shown in Figure 2.

Discussion

Aeromonas bacteraemia is associated with certain underlying diseases such as chronic liver disease (48%) and ma-

lignancy (24%) [3] and is predominant in males (2:1) for unknown reasons [4]. The overall mortality rate in these patients has ranged from 36 to 64% [3,4]. In this reported case, the patient had been struck by a fish bone in the right hand prior to development of *Aeromonas* bacteraemia. This could be the most likely portal of entry of the organism. Previous studies have described that *A. hydrophila* septicaemia is commonly caused by minor skin and soft-tissue trauma from freshwater fish and the environment [5,6]. *A. hydrophila* has been identified from environmental sources, i.e. fresh water, in Thailand [7].

Iron overload treated with deferoxamine has been reported to be associated with certain infections. Systemic *Y. enterocolitica* infection and *zygomycosis* are well-known clinical infections associated with iron overload and deferoxamine therapy [8,9]. In addition, a thalassaemic patient with iron overload treated with deferoxamine has also been reported to be associated with *A. hydrophila* infection [2].

Interestingly, Lin *et al.* [10] reported the association between a fatal outcome from *Aeromonas* bacteraemia and deferoxamine use in a haemodialysis patient with aluminium bone disease, not iron overload. The authors believed that the iron–deferoxamine complex accumulated in the uraemic patient after intravenous administration of deferoxamine alone [11]. They also demonstrated that only the iron–deferoxamine complex, and not any other chelator complex, enhanced *Aeromonas* growth in an iron-restricted environment *in vitro* [10]. Moreover, Ho *et al.* [12] showed that the flexible pilin expression, believed to be one of the virulence factors of *A. hydrophila*, was increased in the presence of deferoxamine in iron-replete media. Rabsch *et al.* [13] demonstrated *in vitro* that *A. hydrophila* could use ferrioxamine (iron–deferoxamine complex) as an additional iron source. Taken together, it seems that the iron–deferoxamine complex, rather than iron overload alone, is a risk factor for this infection due to the additional iron source and the enhancement of some virulent properties. More data are required to explain the relationship between iron overload, deferoxamine and *Aeromonas* infection.

Rhabdomyolysis has been associated with a wide variety of infections including those from viruses, bacteria, fungus and parasites [14]. A prospective study by Betrosian *et al.* [15] found that about two-thirds of bacterial sepsis

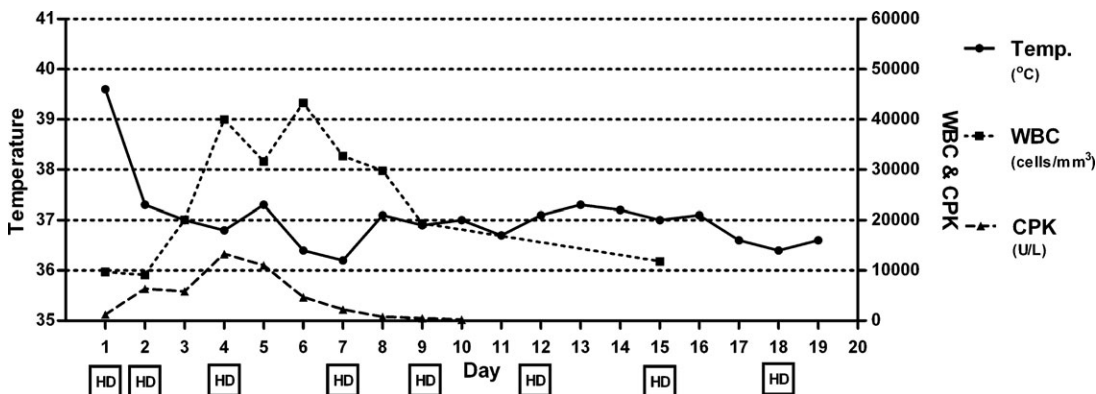


Fig. 2. Clinical course of the patient. Temperature (°C), white blood count (cell/mm³), creatinine phosphokinase (U/L), square box with 'HD' = haemodialysis.

Table 1. Clinical characteristics of *Aeromonas* infection with rhabdomyolysis of the present case and review of the literatures

Reference	Age (years)	Sex	Underlying conditions	Organism	Peak CPK (U/L)	Outcomes
[16]	49	M	Alcoholic liver disease	<i>A. sobria</i>	24 085	Dead on day 2
[17]	50	M	ANLL post-SCT	<i>A. sobria</i>	24 000	Dead on day 3
[17]	41	F	ANLL	<i>A. hydrophila</i>	1 006	Improved
This case	47	F	Chronic haemodialysis with iron overload	<i>A. hydrophila</i>	13 317	Improved

CPK: creatinine phosphokinase; ANLL: acute non-lymphoblastic leukaemia; SCT: stem cell transplantation.

patients complicated with rhabdomyolysis were caused by gram-positive organisms and about one-third of the cases were caused by gram-negative organisms including *Pseudomonas aeruginosa* (20%), *Escherichia coli* (8.5%) and *Klebsiella pneumoniae* (2.8%). To the best of our knowledge, there have been three reported cases of rhabdomyolysis associated with *Aeromonas* infection with high mortality [16,17] (Table 1). In this case, we first experienced rhabdomyolysis associated with *Aeromonas* infection in a chronic haemodialysis patient on deferoxamine treatment for iron overload. Although the patient may have liver disease, there was no significant compromised liver or malignancy in this case. Iron overload and deferoxamine may be responsible for this susceptible infection.

Fever is generally a good indicator for a treatment response. However, the process of infection still progressed with septic embolism despite the resolution of the fever in this present case. While white blood cell count did not rise significantly in the first few days, it had a good correlation with treatment response.

In conclusion, this reported case presents a clinical course of *A. hydrophila* sepsis that was complicated by rhabdomyolysis and septic embolism in a chronic haemodialysis patient on deferoxamine treatment for iron overload. We suggest that, in addition to *Yersinia* and *Mucormycosis*, *Aeromonas* sepsis should be suspected in chronic haemodialysis patients on deferoxamine treatment for iron overload who present with sepsis. Clinicians should be alerted to rhabdomyolysis in this clinical setting, and frequent haemodialysis is necessary.

Acknowledgements. We are grateful to the patient who participated in our report and to many physicians who supplied specimens and clinical information.

Conflict of interest statement. None declared.

References

- Horneman AJ, Ali A, Abbott SL. *Aeromonas*. In Murray PR, Baron EJ (eds). *Manual of Clinical Microbiology*. Washington, DC: ASM Press, 2007, 716–722
- Cigni A, Tomasi PA, Pais A *et al.* Fatal *Aeromonas hydrophila* septicemia in a 16-year-old patient with thalassemia. *J Pediatr Hematol Oncol* 2003; 25: 674–675
- Ko WC, Chuang YC. *Aeromonas* bacteremia: review of 59 episodes. *Clin Infect Dis* 1995; 20:1298–1304
- Lau SM, Peng MY, Chang FY. Outcomes of *Aeromonas* bacteremia in patients with different types of underlying disease. *J Microbiol Immunol Infect* 2000; 33: 241–247
- Vinh DC, Embil JM. Rapidly progressive soft tissue infections. *Lancet Infect Dis* 2005; 5: 501–513
- Thaichinda S, Kositpantawong N. Necrotizing skin and soft-tissue infections associated with septicemia: 7 cases report and review. *J Med Assoc Thai* 2008; 91: 117–123
- Maluping RP, Lavilla-Pitogo CR, DePaola A *et al.* Occurrence, characterisation and detection of potential virulence determinants of emerging aquatic bacterial pathogens from the Philippines and Thailand. *New Microbiol* 2004; 27: 381–389
- Gallant T, Freedman MH, Vellend H *et al.* *Yersinia* sepsis in patients with iron overload treated with deferoxamine. *N Engl J Med* 1986; 314: 1643
- Boelaert JR, Fenves AZ, Coburn JW. Deferoxamine therapy and mucormycosis in dialysis patients: report of an international registry. *Am J Kidney Dis* 1991; 18: 660–667
- Lin SH, Shieh SD, Lin YF *et al.* Fatal *Aeromonas hydrophila* bacteremia in a hemodialysis patient treated with deferoxamine. *Am J Kidney Dis* 1996; 27: 733–735
- Verpooten GA, D’Haese PC, Boelaert JR *et al.* Pharmacokinetics of aluminexamine and ferrioxamine and dose finding of desferrioxamine in haemodialysis patients. *Nephrol Dial Transplant* 1992; 7: 931–938
- Ho AS, Mietzner TA, Smith AJ *et al.* The pili of *Aeromonas hydrophila*: identification of an environmentally regulated ‘mini pilin’. *J Exp Med* 1990; 172: 795–806
- Rabsch W, Winkelmann G. The specificity of bacterial siderophore receptors probed by bioassays. *Biol Met* 1991; 44: 244–250
- Crum-Cianflone NF. Bacterial, fungal, parasitic, and viral myositis. *Clin Microbiol Rev* 2008; 21: 473–494
- Betrosian A, Thireos E, Kofinas G *et al.* Bacterial sepsis-induced rhabdomyolysis. *Intensive Care Med* 1999; 25: 469–474
- Itoh H, Kuwata G, Tateyama S *et al.* *Aeromonas sobria* infection with severe soft tissue damage and segmental necrotizing gastroenteritis in a patient with alcoholic liver cirrhosis. *Pathol Int* 1999; 49: 541–546
- Martino R, Santamaria A, Pericas R *et al.* Acute rhabdomyolysis and myonecrosis complicating *Aeromonas* bacteremia in neutropenic patients with hematologic malignancies: report of two cases. *Haematologica* 1997; 82: 692–694

Received for publication: 6.1.09; Accepted in revised form: 16.2.09