

Strategies for Successful Percutaneous Revascularization of Chronic Total Occlusion of the Femoropopliteal Arteries When the Antegrade Passage of a Guide Wire Fails

Hui Jin Lee, MD, Sang Woo Park, MD, PhD, Il Soo Chang, MD, PhD, Hae Jeong Jeon, MD, PhD, Jeong Hee Park, MD, PhD

All authors: Department of Radiology, Konkuk University Hospital, Konkuk University School of Medicine, Seoul 143-729, Korea

Objective: To evaluate the efficacy of various strategies for revascularization of chronic total occlusion of femoropopliteal arteries when the guide wire does not pass in an antegrade direction.

Materials and Methods: Twenty-four patients with totally occluded femoropopliteal arteries (mean occlusion length 13.75 cm; range, 6-22 cm) were treated by using a retrograde approach and two novel catheters. After successful recanalization or reentry, balloon angioplasty followed by stent placement was performed to complete the revascularization.

Results: In 16 cases in which to cross the occlusion via intraluminal or subintimal route was failed, we used Frontrunner catheters in five cases and Outback catheters in 11 cases. In eight cases in which to reenter after subintimal passage of the guide wire was failed, we used Outback catheters. Successful recanalization was achieved intraluminally or subintimally in all cases. One perforation occurred during subintimal passage of the guide wire that was controlled by recanalization of another subintimal tract. There were no cases of distal thromboembolism or other complications.

Conclusion: A retrograde approach and using the Frontrunner and Outback catheters are safe and effective for successful revascularization of chronic total occlusion of femoropopliteal arteries. In particular, they are useful when the initial antegrade attempts at recanalization have failed.

Index terms: Intervention; Percutaneous transluminal angioplasty; Angiography; Fluoroscopy

INTRODUCTION

A particularly challenging condition for percutaneous transluminal angioplasty are chronic total occlusions (CTOs). CTOs are one of the primary causes of procedural failure in

peripheral interventions (1-4). Percutaneous negotiation of a guide wire, either intraluminally or subintimally, should be done to recanalize the CTO successfully. However, percutaneous recanalization of long CTOs of the femoropopliteal artery by antegrade methods, using a guide wire and catheter, has only moderate success rates - 40% to 60% - depending on lesion length, calcification, operator experience, and runoff vessels; negotiation failures lead to failure of recanalization of CTOs (5). Therefore, other methods that can enhance the success rate of guide wire negotiation, whether intraluminally or subintimally, are needed.

Since Tønnesen et al. first reported the utility of retrograde popliteal access two decades ago, this approach has been employed in challenging femoropopliteal interventions (6-11). Currently, retrograde subintimal tracking via the popliteal approach, which utilizes the

Received September 19, 2011; accepted after revision October 13, 2011.

This study was supported by LG Life Sciences.

Corresponding author: Sang Woo Park, MD, PhD, Department of Radiology, Konkuk University Hospital, Konkuk University School of Medicine, 120-1 Neungdong-ro, Gwangjin-gu, Seoul 143-729, Korea.

- Tel: (822) 2030-5525 • Fax: (822) 2030-5549
- E-mail: psw0224@kuh.ac.kr

This is an Open Access article distributed under the terms of the Creative Commons Attribution Non-Commercial License (<http://creativecommons.org/licenses/by-nc/3.0>) which permits unrestricted non-commercial use, distribution, and reproduction in any medium, provided the original work is properly cited.

anatomical characteristics of the femoropopliteal artery, delivers an endovascular solution for unsuccessful antegrade CTO crossings (12).

The frontrunner XP CTO catheter (Cordis, Miami, FL, USA) is an intraluminal blunt microdissection device used for the recanalization of CTOs intraluminally. This device has jaws that can separate the plaque, thereby creating a passage through the occlusion for the subsequent placement of a guide wire. The Outback LTD catheter (Cordis, Miami, FL, USA) has been used when subintimal guide wire passage into the true lumen fails; when this device is used, a needle is introduced across the intima into the true lumen to facilitate the reentry process.

A retrograde popliteal approach and these two novel catheter technologies, the Frontrunner and Outback catheters, were used for recanalization of femoropopliteal arterial CTOs, and here, their safety and efficacy is reported.

MATERIALS AND METHODS

Patient Selection and Study Population

The study was done prospectively and was approved by the local institutional review board. From August 2005 to July 2011, 277 patients with angiographically documented CTOs in the femoropopliteal arteries and at least a 6-month

history of symptoms presented for endovascular therapy. The conventional antegrade guide wire and catheter recanalization, intraluminally or subintimally, failed in 24 patients (M : F = 17 : 7, mean age: 66.2 years) that were treated with a retrograde popliteal approach or the Frontrunner or Outback catheter. Thirteen of 24 patients had intermittent claudication of Fontaine classifications IIa (n = 4) and IIb (n = 9), and 9 patients had critical limb ischemia associated with resting pain. Eleven patients had lesions in the superficial femoral artery (SFA), and thirteen patients had a lesion in the SFA and P1 segment of the popliteal artery. The mean lesion length was 13.75 cm (range 6 to 22 cm).

Procedure

Informed written consent was obtained from all patients before treatment. The procedure was performed under local anesthesia, and for all patients, access was obtained with an antegrade or retrograde approach via the ipsilateral or contralateral common femoral artery. Subsequently, all patients received 3000 IU of heparin intra-arterially.

After initial angiographic imaging, the CTO was crossed with a combination of a 0.035 inch non-hydrophilic guide wire (Bentson; Cook, Bloomington, IN, USA) and a 4-Fr angiographic catheter (Terumo, Tokyo, Japan). When guide

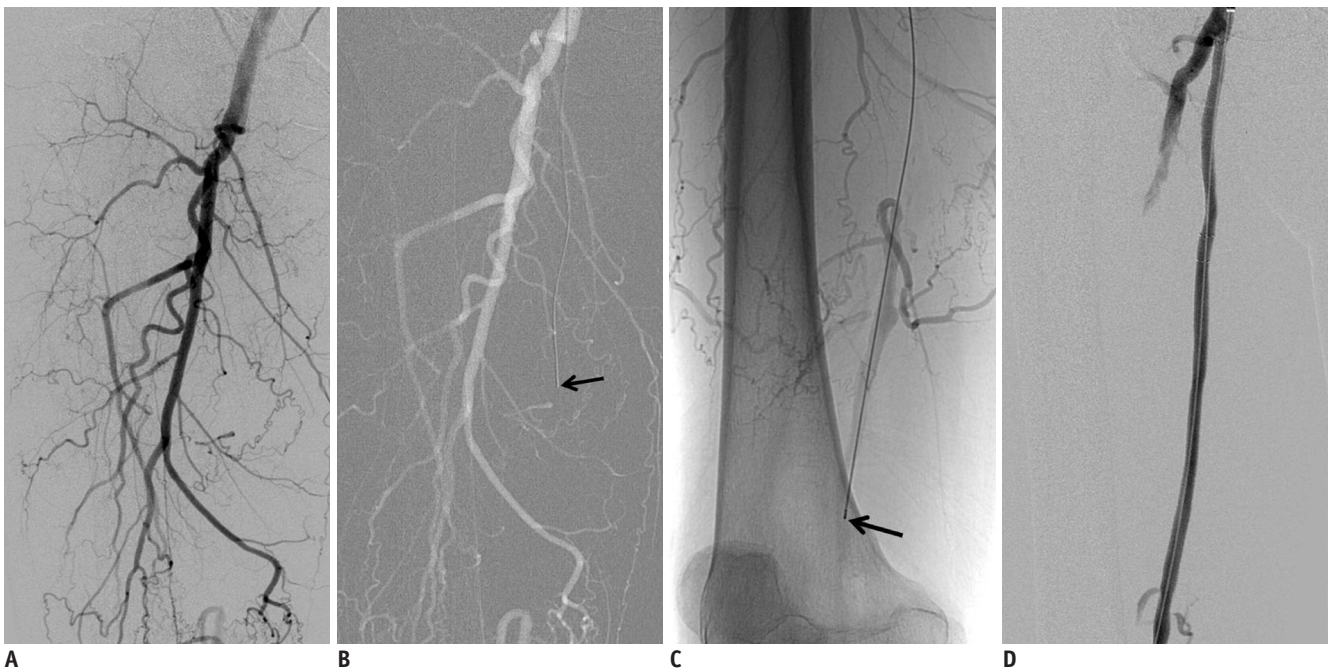


Fig. 1. 64-year-old man with severe claudication (Fontaine classification IIb) of right leg.

A-C. Patient had chronic total occlusion of about 20 cm of right superficial femoral artery on angiogram. Successful recanalization with Frontrunner XP chronic total occlusion catheter was achieved into reconstituted artery (arrow). **D.** Primary stent placement with self-expandable nitinol stents was performed.

wire advancement could not be achieved into the CTO, despite several attempts, the Frontrunner catheter was used to facilitate the intraluminal or subintimal negotiation of the guide wire. After jaw opening and closing, and passage through the proximal cap of the CTO, the Frontrunner microtome was navigated forward through the occluded segments with its jaws closed. Then, to create a larger microdissection canal, the Frontrunner catheter was repeatedly pulled back with an "open jaw". Fluoroscopic roadmapping was used throughout to verify the alignment of the catheters with the vessel lumen. After the initial passage of the Frontrunner catheter, it was advanced into the distal reconstituted artery and used for guide wire introduction. Balloon angioplasty was performed, and the vessel was dilated from the distal to the proximal segment. Adjunctive stenting with self-expandable nitinol stents was performed in all cases (Fig. 1).

Intraluminal or subintimal passage using the Frontrunner catheter was performed in patients in whom passage of the guide wire into the CTO failed. However, if the guide wire was able to be passed into the CTO subintimally, subintimal angioplasty was done in the femoropopliteal CTO. If the guide wire was not able to enter the true lumen after passage along the subintimal tract, the retrograde approach method or the Outback reentry catheter was used to obtain successful reentry into the true lumen. Initially, when reentry into the true lumen after subintimal passage of the guide wire was not successful, the retrograde approach method was used ($n = 8$) because the Outback catheter was not available at that time. After the Outback catheter was introduced, it was used instead of the retrograde approach whenever reentry using the antegrade approach method failed ($n = 11$).

An attempt to traverse the occlusion with the subintimal technique, with a combination of the 0.035-inch hydrophilic guide wire (Terumo, Tokyo, Japan) and a 4-Fr non-taper angle catheter (Terumo, Tokyo, Japan), was performed. Reentry was then attempted with the same or similar guide wires. When reentry into the true lumen could not be achieved, despite several attempts with standard guide wires, the retrograde approach was used or the Outback catheter was introduced to gain access to the true lumen.

The retrograde approach was attempted with the patient in the decubitus position, and the popliteal fossa was sterilized. Under ultrasound guidance, a popliteal arterial puncture was performed using a 22-G needle and a 4-Fr microsheath was placed in the popliteal artery through the

0.018-inch guide wire. Then, the CTO lesion was crossed subintimally in retrograde fashion using a 0.035-inch hydrophilic guide wire. An antegrade snare (Pfm medical, Koln, Germany) was used to maneuver the wire into the sheath to facilitate subsequent procedures in an antegrade manner. Thereafter, balloon angioplasty followed by stent placement was performed in femoropopliteal arteries and hemostasis was established by manual compression (Fig. 2).

The Outback catheter was delivered to the point of planned reentry over a 0.014 inch guide wire (Cordis, Miami, FL, USA) through a 6-Fr sheath and manipulated under fluoroscopic guidance with two fluoroscopic views to orient the radio-opaque marker located on the nosecone of the catheter toward the desired arterial lumen. Then, the curved needle was deployed across the intima into the true lumen. The needle was retracted, and the catheter was removed. Balloon angioplasty followed by stent placement was done in a manner that was similar to the other methods (Fig. 3).

A final angiography was performed to evaluate the treated site and distal runoff vessels and to check for the presence of complications in all cases.

Assessment

The technical success of the use of both catheters and the retrograde method, in addition to any complications during or immediately after the procedure were evaluated. The technical success of the Frontrunner catheter was defined as an advancement of the catheter into the reconstituted vessel over the CTO, allowing the guide wire to pass. Successful subintimal passage of the guide wire was defined as advancement of the hydrophilic guide wire with looping and reentry into the true lumen. The technical success of the retrograde method was defined as successful puncture of the popliteal artery, looping and subintimal upward advancement of a hydrophilic guide wire, and successful capture of the guide wire using an antegrade snare. The technical success of the use of the Outback catheter was defined as an advancement of the catheter to the CTO and reentry of the guide wire into the true lumen after puncture. Complications including angiographically visible perforations with or without the need for surgical repair and distal thromboembolism were evaluated.

RESULTS

The Frontrunner catheter was used in five patients. Intraluminal passage of the catheter into the reconstituted

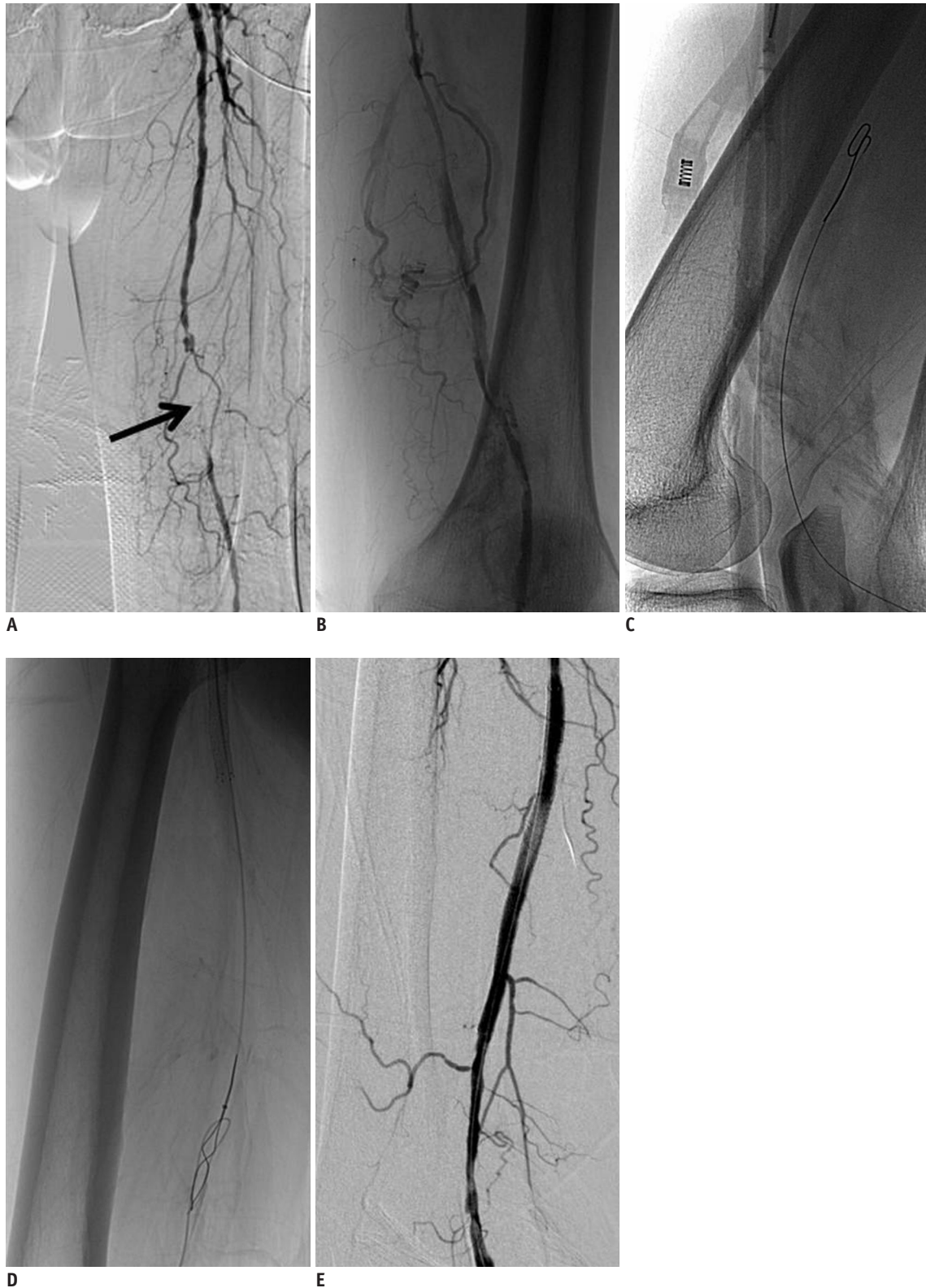


Fig. 2. 73-year-old man with severe claudication (Fontaine classification IIb) of both legs.

A. Patient had chronic total occlusion of about 8 cm of left superficial femoral artery on angiogram (arrow). **B.** Reentry of 0.035 inch hydrophilic guide wire into true lumen could not be achieved. **C, D.** Under ultrasound guidance, popliteal arterial puncture was performed and chronic total occlusion lesion was crossed subintimally in retrograde fashion. Anterograde snare was used to maneuver wire into sheath to facilitate subsequent procedures in anterograde manner. **E.** Thereafter, balloon angioplasty followed by stent placement was performed in femoropopliteal arteries and hemostasis in popliteal artery was established by manual compression.

artery was successful in four patients, and subintimal passage of the catheter with successful reentry into the true lumen was performed in one patient. The overall technical success rate was 100%. Three patients had CTOs in the SFA, and two patients had a lesion in the distal SFA and popliteal artery. A contralateral approach with the catheter was performed in three patients that had the lesion in the SFA, and an ipsilateral retrograde approach was performed in two patients with the CTO far from the ipsilateral common femoral artery. In one patient with a long CTO in the SFA (20 cm), re-entry into the true lumen was not possible after subintimal passage of the occluded segment; attempts to pull the catheter back to the proximal cap of the CTO and cross the lesion again intraluminally were successful for intraluminal passage. All patients underwent balloon angioplasty with a 4 mm balloon catheter followed

by stent placement using a 6-7 mm self-expandable stent after the passage of the guide wire.

In eight of the remaining nineteen patients, the retrograde approach via popliteal arterial access was used. The technical success rate was 100%, and all patients underwent balloon angioplasty followed by stent placement in the same fashion as the cases using the Frontrunner catheter (Fig. 2).

In all eleven patients in which the Outback catheter was used, reentry of the guide wire into the true lumen was successful (100%). Nine patients obtained successful reentry into the popliteal artery; two obtained successful reentry into the SFA (Fig. 3). A contralateral approach of the catheter was used in all patients. One patient had successful reentry into the true lumen using only the hydrophilic guide wire. However, reentry sites achieved with

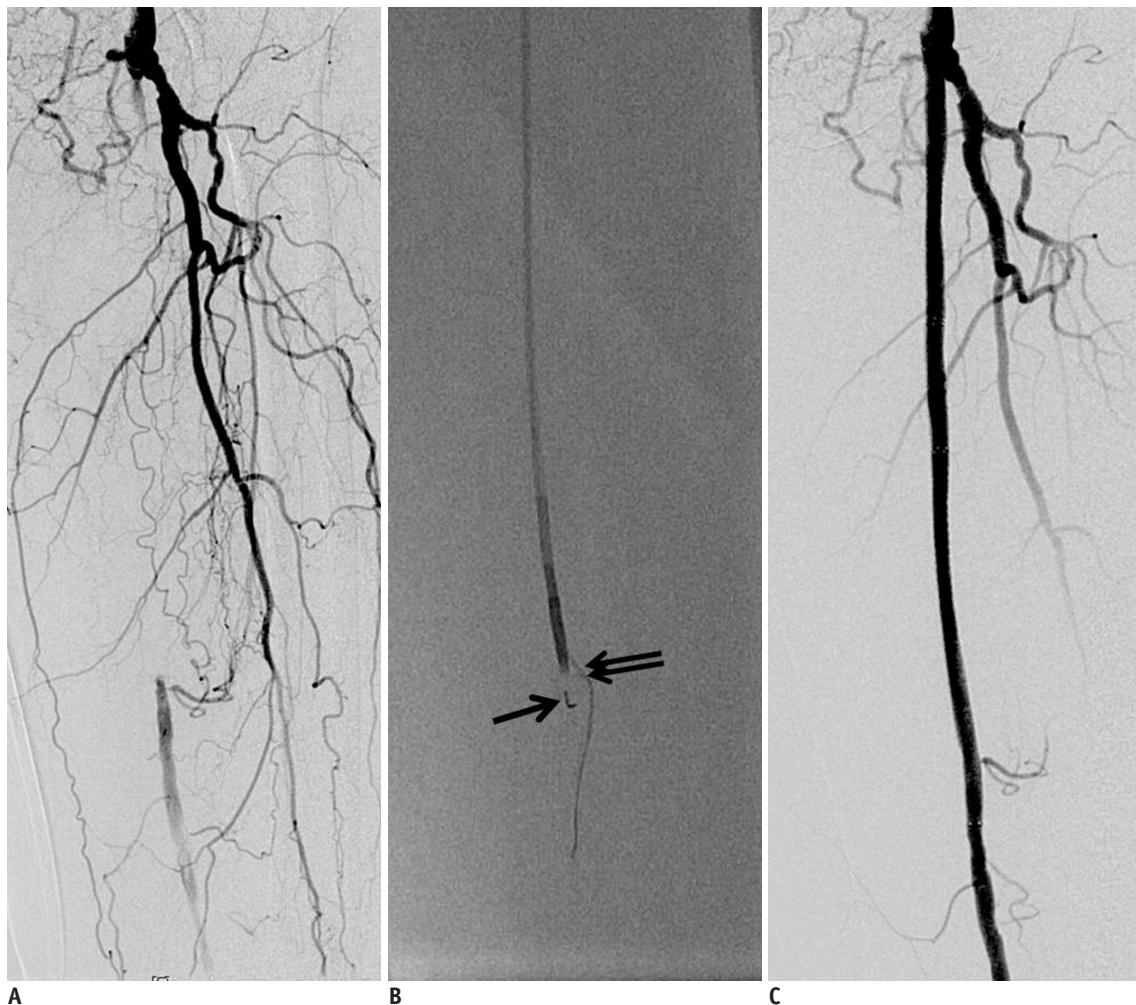


Fig. 3. 81-year-old-woman with severe claudication (Fontaine classification IIb) of left superficial femoral artery (SFA).

A. Patient had chronic total occlusion of about 17 cm in left SFA on angiogram. **B.** Fluoroscopic images show Outback catheter and its needle deployed (double arrows) with free passage of guide wire into true lumen of reconstituted artery. L configuration at catheter nosecone is noted (arrow). **C.** Final angiogram demonstrates that patency was restored following stent placement.

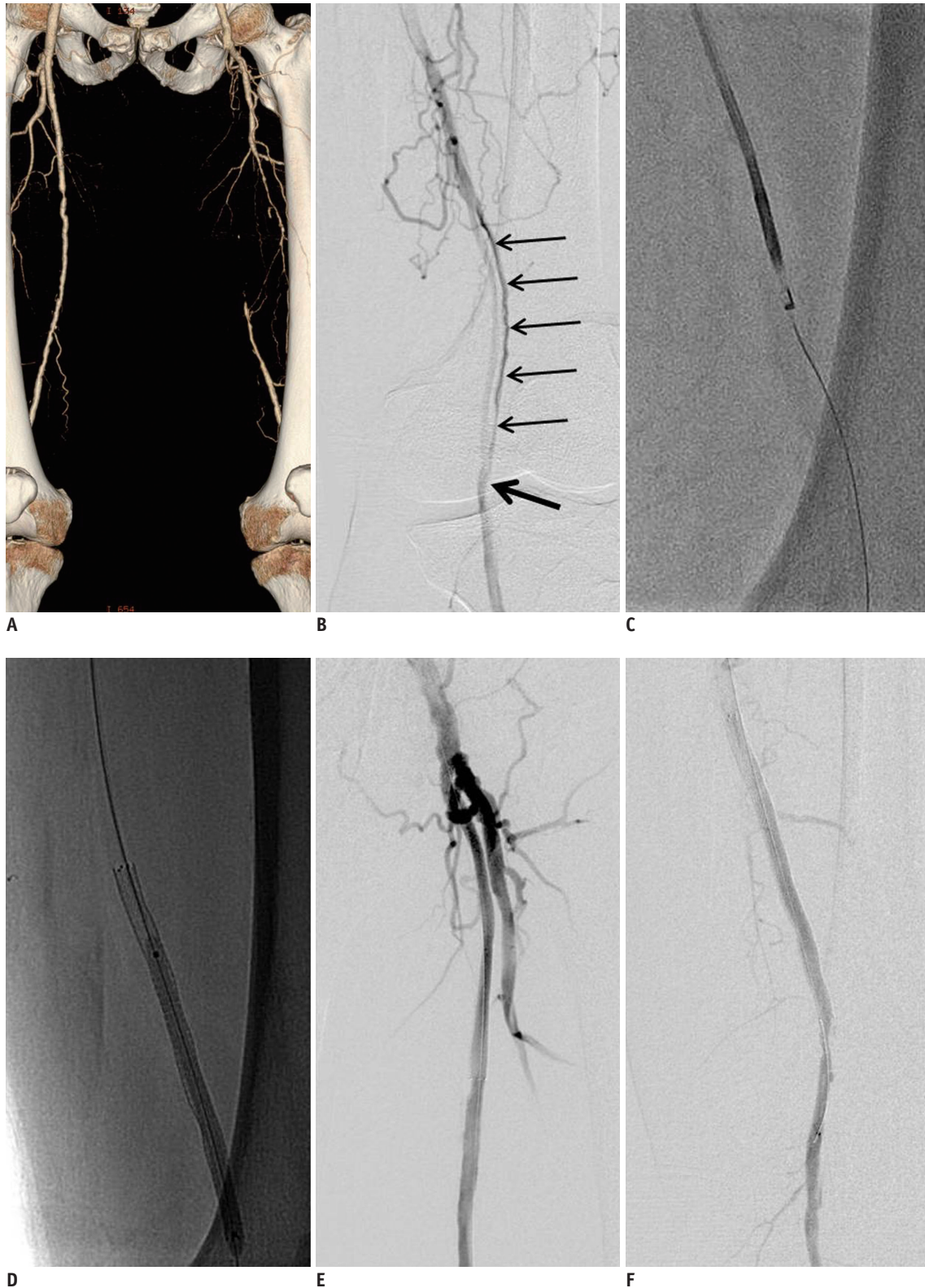


Fig. 4. 71-year-old-man with resting pain (Fontaine classification III) in left foot.

A. CT angiography shows chronic total occlusion of left superficial femoral artery (SFA). **B.** Initial attempt with conventional techniques using hydrophilic guide wire and angiographic catheter created reentry at P2 segment of popliteal artery (arrow). Angiogram after subintimal angioplasty showed suboptimal results (thin arrows). **C.** Outback catheter was used to create new reentry site at more proximal artery to P2 segment of popliteal artery to allow stent to be placed. **D.** Self-expandable nitinol stent was placed at distal SFA including new reentry site. **E, F.** Final angiogram demonstrates that patency was restored following stent placement.

only the guide wire were usually located much more distally over the P2 segment of the popliteal artery; the result of subintimal balloon angioplasty using 5 mm and 6 mm balloon catheters (Cordis, Miami, FL, USA) was suboptimal for stent implantation for the supply of sufficient blood flow. Therefore, the Outback catheter was used to create a new reentry site more proximally for stent placement. The stent placement was performed in the SFA including the newly created reentry site and blood flow was completely restored (Fig. 4). Two patients with femoropopliteal occlusion had some calcifications at the reentry sites; initial attempts to create reentry at those sites failed. Therefore, the Outback catheter was advanced more distally where the calcification was scarce and successful reentry was achieved. In one patient, no catheter could advance over the 0.014 guide wire after successful reentry using the Outback catheter. A 2.0 Fr microcatheter (Terumo, Tokyo, Japan) was advanced over the guide wire, and it was exchanged for a 0.018 guide wire (V18; Boston Scientific, Natick, MA, USA). Subsequent procedures were done using this wire.

In one patient, the Outback catheter was not able to be advanced to the arteries distal to the SFA. Therefore, dilatation with a 4 mm balloon catheter was performed after which the catheter could be advanced. One patient with SFA occlusion had a perforation during the subintimal passage of the guide wire. However, the guide wire and catheter were pulled back to the common femoral artery and subintimal passage through another tract was attempted. The final angiogram, after successful creation of the reentry site and stent placement in the SFA, showed no visible vessel perforation. No distal thromboembolism during or immediately after the procedure was observed.

DISCUSSION

Chronic occlusions account for a significant portion of peripheral vascular lesions and have historically represented a serious technical challenge to endovascular interventionalists using conventional guide wires and catheters (13). Recently, new technologies and methods have been introduced for recanalization of CTOs. Subintimal recanalization with distal re-entry has been advocated as a solution to the problem of unsuccessful passage through multisegmented long calcified occlusions. London et al. (14) reported a 90% technical success rate for SFA subintimal angioplasty in a series of patients with a mean occlusion length of 15 cm. This approach, however, has been limited

in some cases by the lack of controlled re-entry into the true lumen of the target vessel. In addition, true lumen re-entry using hydrophilic wires and catheters is not achieved until subintimal passage to a site significantly remote from the level of vessel lumen patency; this causes subintimal angioplasty or stenting to extend beyond the occluded segment. In fact, in the present study, one case occurred in which the creation of a new reentry site proximal to the remote reentry site created by the traditional subintimal technique allowed the stent to be placed, overcoming the suboptimal subintimal balloon angioplasty. Some surgeons report using retrograde popliteal access (15) for subintimal recanalization or a "kissing catheter" or "wire pull-through" technique (16, 17), which requires two access sites (femoral and popliteal). After femoral access and catheter or guide wire advancement through the subintimal plane around the occlusion, the patient is placed in a prone position, and the popliteal artery is accessed. A catheter is advanced then through the popliteal artery in the same subintimal plane to meet the initial catheter. Our study also had a 100% technical success rate in cases with failure of advancement of the guide wire into the true lumen. However, this retrograde approach technique causes patients discomfort, a complicates the access site, and is technically feasible only for the superficial femoral artery (18). Therefore, new instruments, such as the Outback catheter, that can enhance the reentry success rate, have been needed; the purpose of using this reentry catheter is to overcome the above limitations and problems that prolong the procedure and increase the amount of exposure of the patient to radiation while achieving true lumen access in a controlled manner.

The results of our study demonstrate that use of a reentry catheter significantly improves the outcome of endovascular treatment in patients with femoropopliteal occlusions, with no additional risks or complications. Etezadi et al. (13) reported that true lumen reentry was achieved in 87% and 91% of patients with femoropopliteal and aortoiliac occlusions, respectively, and the overall technical success rate with the device was 88%. Hausegger et al. (19) reported that eight of ten patients had successful true lumen reentry with the prototype of the Outback catheter; two technical failures occurred in heavily calcified arteries. Wiesinger et al. (18) reported a 50% success rate of reentry (5/10 patients). Although, in our study, the number of patients was fewer than in previous studies, reentry was achieved in 100% of cases. It has been suggested that

heavy calcification of the vessel wall is a contributing factor to reentry failure (13). In our study there were two cases that failed reentry at the initial puncture site with the Outback catheter due to calcification; successful reentry was achieved after puncture at a more distal site with scarce calcification. Although the amount of calcification was not specifically evaluated, based on the limited experience in this study, it may be necessary to avoid calcification that interferes with successful reentry at heavy calcification sites. Decreases in procedure time and radiation exposure have been suggested as additional benefits of the use of reentry catheters; these factors were not evaluated in our study. Therefore, additional prospective studies with the assessment of calcification, procedure time, and radiation hazard are needed.

The Outback catheter could not be advanced to the target lesion and the angiographic catheter could not be advanced over the reentry site after successful reentry of the 0.014 inch guide wire into the true lumen. This might be explained by the presence of a thick intima or heavy calcifications. Based on the limited experience of this study, such problems can be overcome technically by pre-balloon dilatation or use of a microcatheter. The durability of the subintimally created channels is currently a topic of debate. Only a few studies on the efficacy of subintimal angioplasty in the treatment of very long lesions extending over multiple limb segments have been undertaken thus far. The initial relatively high long-term patency rate reported by Bolia's group has not been reproduced by most other studies (20-23). Although some recent investigations suggest that the subintimal technique is effective, no randomized study comparing subintimal angioplasty with intraluminal angioplasty has yet been performed (24, 25). Therefore, some surgeons still prefer intraluminal angioplasty to the subintimal technique.

The Frontrunner catheter, a relatively new device, is thought to selectively cause disruption of plaques and the adventitia and is designed to improve the technical success of traversing complex lesions. Although it sometimes creates extraluminal passages along subintimal planes in CTOs, the passage created by the Frontrunner device is frequently intraluminal (26). The Frontrunner catheter is safe and effective to use; however, few reports are available on the results of peripheral arterial CTO. Charalambous et al. (27) reported a 65.4% success rate of recanalization using the Frontrunner for the SFA; the main reasons for failure were inability to cross the lesion due to heavy calcification,

similar to the studies using the Outback catheter. In our study, the success rate using the Frontrunner catheter was 100%. Although the number of patients was small and calcium in the lesions was not assessed, our study included only patients with failure of guide wire advancement into the CTO. In fact, this advancement failure can make it difficult to use any tools or methods to achieve reentry. The Frontrunner catheter could pass this lesion and successful recanalization could be achieved via this catheter. Occasionally, the Frontrunner catheter was advanced into the subintimal tract in the femoropopliteal artery and did not obtain successful reentry into the true lumen. This occurred in one case, and several attempts to use the Frontrunner catheter again after pulling it back into the proximal cap of the CTO resolved the problem.

In conclusion, these various methods using a retrograde approach and a Frontrunner or Outback catheter for recanalization of CTOs are promising. Although the study sample was small, appropriate use of these approaches appear to be safe and effective options after failed recanalization of CTOs of the femoropopliteal arteries by conventional methods using guide wires and angiographic catheters.

REFERENCES

1. Kjellgren O, Feld S, Loyd D, Schroth G, Anderson HV, Smalling RW. Successful treatment of chronic total peripheral occlusions that failed conventional techniques using the stiff backend of the Glidewire. *Cathet Cardiovasc Diagn* 1995;36:360-363
2. Gupta AK, Ravimandalam K, Rao VR, Joseph S, Unni M, Rao AS, et al. Total occlusion of iliac arteries: results of balloon angioplasty. *Cardiovasc Intervent Radiol* 1993;16:165-177
3. Bolia A, Miles KA, Brennan J, Bell PR. Percutaneous transluminal angioplasty of occlusions of the femoral and popliteal arteries by subintimal dissection. *Cardiovasc Intervent Radiol* 1990;13:357-363
4. Henry M, Amor M, Ethevenot G, Henry I, Mentre B, Tzvetanov K. Percutaneous endoluminal treatment of iliac occlusions: long-term follow-up in 105 patients. *J Endovasc Surg* 1998;5:228-235
5. van der Heijden FH, Eikelboom BC, Banga JD, Mali WP. Management of superficial femoral artery occlusive disease. *Br J Surg* 1993;80:959-963
6. Tønnesen KH, Sager P, Karle A, Henriksen L, Jørgensen B. Percutaneous transluminal angioplasty of the superficial femoral artery by retrograde catheterization via the popliteal artery. *Cardiovasc Intervent Radiol* 1988;11:127-131
7. Zaitoun R, Iyer SS, Lewin RF, Dorros G. Percutaneous popliteal

- approach for angioplasty of superficial femoral artery occlusions. *Cathet Cardiovasc Diagn* 1990;21:154-158
8. Heenan SD, Vinnicombe SJ, Buckenham TM, Belli AM. Percutaneous transluminal angioplasty by a retrograde subintimal transpopliteal approach. *Clin Radiol* 1994;49:824-827; discussion 827-828
 9. Villas PA, Cohen G, Goyal A, Putnam SG 3rd, Ball D. The merits of percutaneous transluminal angioplasty of a superficial femoral artery stenosis via a retrograde popliteal artery approach. *J Vasc Interv Radiol* 1999;10:325-328
 10. Yılmaz S, Sindel T, Ceken K, Alimoglu E, Lüleci E. Subintimal recanalization of long superficial femoral artery occlusions through the retrograde popliteal approach. *Cardiovasc Intervent Radiol* 2001;24:154-160
 11. Cutress ML, Blanshard K, Shaw M, Bown M, White S, Sayers RD. Retrograde subintimal angioplasty via a popliteal artery approach. *Eur J Vasc Endovasc Surg* 2002;23:275-276
 12. Spinosa DJ, Harthun NL, Bissonette EA, Cage D, Leung DA, Angle JF, et al. Subintimal arterial flossing with antegrade-retrograde intervention (SAFARI) for subintimal recanalization to treat chronic critical limb ischemia. *J Vasc Interv Radiol* 2005;16:37-44
 13. Etezadi V, Benenati JF, Patel PJ, Patel RS, Powell A, Katzen BT. The reentry catheter: a second chance for endoluminal reentry at difficult lower extremity subintimal arterial recanalizations. *J Vasc Interv Radiol* 2010;21:730-734
 14. London NJ, Srinivasan R, Naylor AR, Hartshorne T, Ratliff DA, Bell PR, et al. Subintimal angioplasty of femoropopliteal artery occlusions: the long-term results. *Eur J Vasc Surg* 1994;8:148-155
 15. Yılmaz S, Sindel T, Lüleci E. Subintimal versus intraluminal recanalization of chronic iliac occlusions. *J Endovasc Ther* 2004;11:107-118
 16. Conroy RM, Gordon IL, Tobis JM, Hiro T, Kasaoka S, Stemmer EA, et al. Angioplasty and stent placement in chronic occlusion of the superficial femoral artery: technique and results. *J Vasc Interv Radiol* 2000;11:1009-1020
 17. Yılmaz S, Sindel T, Luleci E. Bilateral transpopliteal approach for treatment of complex SFA and iliac occlusions. *Eur Radiol* 2002;12:911-914
 18. Wiesinger B, Steinkamp H, König C, Tepe G, Duda SH. Technical report and preliminary clinical data of a novel catheter for luminal re-entry after subintimal dissection. *Invest Radiol* 2005;40:725-728
 19. Hausegger KA, Georgieva B, Portugaller H, Tauss J, Stark G. The outback catheter: a new device for true lumen re-entry after dissection during recanalization of arterial occlusions. *Cardiovasc Intervent Radiol* 2004;27:26-30
 20. Ingle H, Nasim A, Bolia A, Fishwick G, Naylor R, Bell PR, et al. Subintimal angioplasty of isolated infragenicular vessels in lower limb ischemia: long-term results. *J Endovasc Ther* 2002;9:411-416
 21. Lazaris AM, Tsiamis AC, Fishwick G, Bolia A, Bell PR. Clinical outcome of primary infrainguinal subintimal angioplasty in diabetic patients with critical lower limb ischemia. *J Endovasc Ther* 2004;11:447-453
 22. Laxdal E, Jenssen GL, Pedersen G, Aune S. Subintimal angioplasty as a treatment of femoropopliteal artery occlusions. *Eur J Vasc Endovasc Surg* 2003;25:578-582
 23. Smith BM, Stechman M, Gibson M, Torrie EP, Magee TR, Galland RB. Subintimal angioplasty for superficial femoral artery occlusion: poor patency in critical ischaemia. *Ann R Coll Surg Engl* 2005;87:361-365
 24. Molloy KJ, Nasim A, London NJ, Naylor AR, Bell PR, Fishwick G, et al. Percutaneous transluminal angioplasty in the treatment of critical limb ischemia. *J Endovasc Ther* 2003;10:298-303
 25. Hynes N, Akhtar Y, Manning B, Aremu M, Oiakhinan K, Courtney D, et al. Subintimal angioplasty as a primary modality in the management of critical limb ischemia: comparison to bypass grafting for aortoiliac and femoropopliteal occlusive disease. *J Endovasc Ther* 2004;11:460-471
 26. Yang YM, Mehran R, Dangas G, Reyes A, Qin J, Stone GW, et al. Successful use of the frontrunner catheter in the treatment of in-stent coronary chronic total occlusions. *Catheter Cardiovasc Interv* 2004;63:462-468
 27. Charalambous N, Schäfer PJ, Trentmann J, Hümme TH, Stöhring C, Muller-Hulsbeck S, et al. Percutaneous intraluminal recanalization of long, chronic superficial femoral and popliteal occlusions using the Frontrunner XP CTO device: a single-center experience. *Cardiovasc Intervent Radiol* 2010;33:25-33