



ELSEVIER

Contents lists available at ScienceDirect

IJID Regions

journal homepage: www.elsevier.com/locate/ijregi

Case Report

Fascioliasis complicated by acute necrotizing pancreatitis in an Ethiopian child – a case report on a rare complication of a rarely reported emerging disease

Tinsae Alemayehu^{a,b,*}, Selamawit Tariku^a, Kaleab Tesfaye^c^a American Medical Centre, Addis Ababa, Ethiopia^b St. Paul's Hospital Millennium Medical College, Addis Ababa, Ethiopia^c Samaritan Surgical Centre, Addis Ababa, Ethiopia

ARTICLE INFO

Keywords:

Fascioliasis
Fasciola spp.
 Helminth
 Eosinophilia
 Liver masses
 Pancreatitis

ABSTRACT

Background: Fascioliasis is a zoonotic infection caused by *Fasciola* spp. (liver fluke). Although infrequently diagnosed, it is emerging as a helminth infection of public health importance in many parts of the world. There are few reports on human fascioliasis from Africa.

Case report: This article reports a case of a 12-year-old Ethiopian boy who presented with left-sided abdominal pain and a history of frequent consumption of leafy vegetables. His work-up showed leukocytosis with marked eosinophilia, and increased serum amylase and lipase, and imaging confirmed multiple subcapsular hepatic masses as well as acute necrotizing pancreatitis. Upon serological testing for helminths, he tested positive on *Fasciola hepatica* enzyme-linked immunosorbent assay.

Conclusions: Fascioliasis may present with acute pancreatitis, and should be considered as a possible diagnosis in people with acute biliary disease in endemic settings.

Background

Fascioliasis is a liver fluke infection caused by *Fasciola hepatica* and *Fasciola gigantica*, with a global distribution (Tezer et al., 2013). Predominantly a livestock illness, human fascioliasis only started to garner attention in the 1990s (Dermauw et al., 2021). Only 12 African countries have reported human fascioliasis, and the disease is likely to be underdiagnosed in many parts of Africa (Dermauw et al., 2021). Although many factors that predispose for human fascioliasis, such as consumption of raw secondary intermediate hosts (e.g. fish), exist in Ethiopian dietary practice, and consumption of leafy vegetables is common, there have been very few reports of human fascioliasis in Ethiopia. Acute pancreatitis is a very rarely reported complication of fascioliasis (Bayu et al., 2005; Fentie et al., 2013). This article presents the clinical findings and evaluation of a 12-year-old Ethiopian boy with fascioliasis presenting with acute pancreatitis.

Case presentation

A 12-year-old boy living in Addis Ababa, Ethiopia presented with left-sided abdominal pain of 2 days' duration. He also complained of low-grade intermittent fever, but had no other symptoms. His past med-

ical history was unremarkable. His dietary history consisted of frequent consumption of salads, comprising of leafy vegetables like lettuce and tomatoes. There were no streams or rivers in his residential district. His vaccinations were up to date. On examination, his anthropometric measurements were optimal, and his vital signs were within normal limits for his age. He had mild left flank tenderness.

His work-up showed a white blood cell count of 16,020/mm³ (43.8% neutrophils, 12.4% lymphocytes, 40% eosinophilia, absolute eosinophil count 6400/mm³), and an otherwise normal complete blood count, normal liver enzymes, and normal creatinine and lipid profiles. Serum amylase (815 U/L) and lipase (562 U/L) were elevated. Abdominal ultrasound showed left upper quadrant bowel wall thickening with inflammatory changes, inflamed pancreatic tail, moderate ascites, gallbladder sludge and small periportal reactive lymph nodes. Chest x ray, stool microscopy and urinalysis had normal findings. Pre-treatment blood cultures revealed no growth, and *Strongyloides stercoralis*-specific immunoglobulin G test was negative.

Abdominal computed tomography showed an enlarged focal non-enhanced pancreatic body and tail with moderate ascites (acute necrotizing focal pancreatitis), an enhanced gallbladder wall, and multiple small patchy ill-defined hypo-attenuating non-enhanced hepatic lesions with subcapsular and periportal distribution, best seen in the portal

* Corresponding author at: Tinsae Alemayehu, P.O. Box 62706, Addis Ababa, Ethiopia.

E-mail addresses: tinsae.alemayehu@sphmmc.edu.et, tigisttinsae@gmail.com (T. Alemayehu).

<https://doi.org/10.1016/j.ijregi.2022.03.016>

Received 7 February 2022; Received in revised form 21 March 2022; Accepted 21 March 2022

2772-7076/© 2022 The Author(s). Published by Elsevier Ltd on behalf of International Society for Infectious Diseases. This is an open access article under the CC BY-NC-ND license (<http://creativecommons.org/licenses/by-nc-nd/4.0/>)

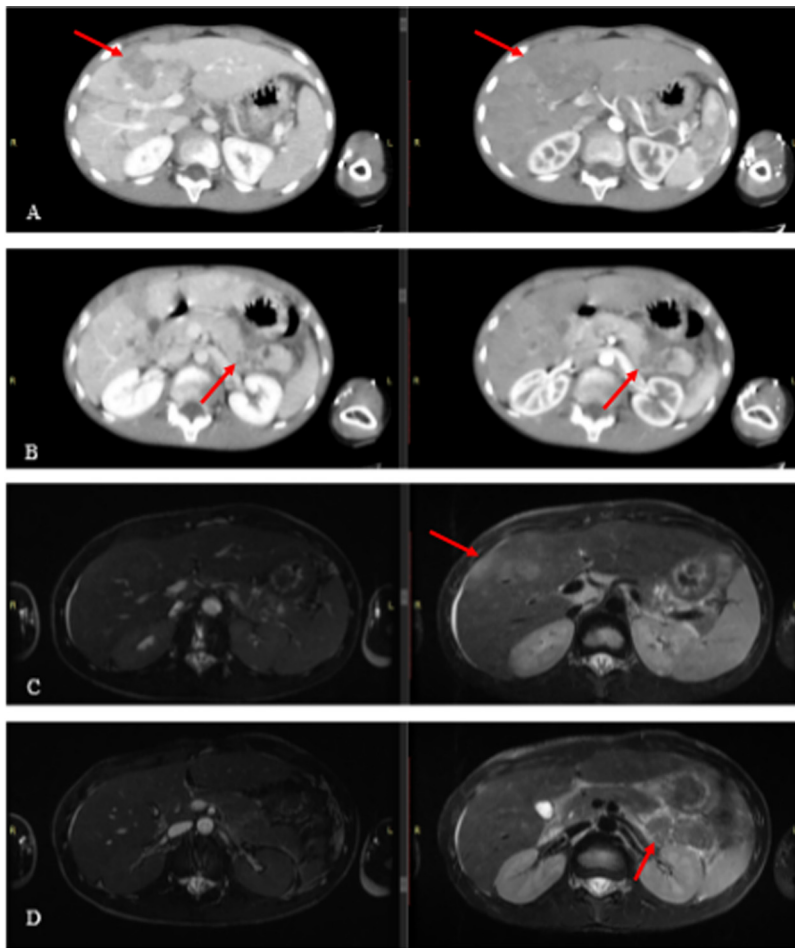


Figure 1. (A,B) Acute necrotizing focal pancreatitis, enhanced gallbladder wall, and multiple small patchy ill-defined hypodense hepatic lesions with subcapsular and periportal distribution, best seen in the portal venous phase. (C,D) Axial T2 and T2 fat suppression magnetic resonance cholangiopancreatography images showing multi-focal, branching and, predominantly, subcapsular hepatic lesions with restricted diffusion.

venous phase (Figure 1A,B). With suspicion of a hepatobiliary parasite, abdominal magnetic resonance imaging (MRI)/magnetic resonance cholangiopancreatography was performed, and revealed multi-focal, branching and, predominantly, subcapsular hepatic lesions with restricted diffusion; these findings likely represented inflammatory phlegmons. Obstruction of the biliary tree was not observed (Figure 1C,D).

Considering the child's presentation, dietary risks, eosinophilia and suggestive radiological findings, samples were drawn for serological testing for *F. hepatica*. With a preliminary diagnosis of acute necrotizing pancreatitis and liver abscesses, the patient was started empirically on parenteral ciprofloxacin and metronidazole (antibiotics which achieve better concentrations in the biliary tree and which target common pathogens of bacterial liver abscess), intravenous omeprazole and fluid hydration (130% of daily requirement), with enteral feeds encouraged. Serum glucose measurements remained normal. Empiric treatment with a single dose of albendazole and a thrice-daily regimen of praziquantel were added to the management (addressing hepatobiliary parasites such as *Ascaris* spp. and *Schistosoma* spp.) pending the helminthic serological tests. No interventional radiology services were available. Serial imaging 2 and 4 weeks after the initiation of treatment showed a normal pancreas, cleared gallbladder sludge, minimal persistent ascites, and minimal improvement in the size of the liver lesions. While the total white blood cell count normalized (upon completion of 4 weeks of antibiotics: $8370/\text{mm}^3$), eosinophilia persisted with an absolute eosinophil count of $3189/\text{mm}^3$. After 4 weeks of antibiotics (2 weeks parenterally and 2 weeks orally), an enzyme-linked immunosorbent assay (ELISA) for *F. hepatica* gave a positive result. With a diagnosis of fascioliasis complicated by acute necrotizing pancreatitis, oral triclabendazole 10 mg/kg as two doses 12 h apart was prescribed.

Discussion and conclusions

Both *F. hepatica* and *F. gigantica* cause human fascioliasis in Africa. *F. gigantica* fascioliasis has been diagnosed throughout Africa, but *F. hepatica* fascioliasis has mainly been reported from north and eastern Africa (Dermauw et al., 2021). The infection is caused by a freshwater zoonotic trematode which livestock acquire by grazing on grass, and humans acquire by consuming leafy water plants or raw secondary intermediate hosts such as fish (Nyindo and Lukumbagire, 2015). The ingested encysted metacercariae excyst in the duodenum and penetrate the intestine, progressing through the peritoneum to the hepatic capsule and biliary ducts, which are the primary site of infection (Moazeni and Ahmadi, 2016). The leaf-shaped worms are large and visible to the naked eye, with *F. hepatica* worms measuring 3 cm by 1.5 cm and *F. gigantica* worms measuring up to 7.5 cm by 1 cm (Lukumbagire et al., 2015). Unembryonated eggs pass through faeces and later hatch into miracidia which are consumed by snails (intermediate hosts). Cercariae leave snails to encyst on aquatic plants, ready to initiate another infectious cycle (Moazeni and Ahmadi, 2016).

Initial symptoms appear a few days to a few months after ingestion of the metacercariae, and consist of nausea, anorexia, vomiting, low-grade fever and right upper quadrant abdominal pain, reflecting migration of the larvae through the liver. Symptoms may last for 3 months or more. The illness progresses to chronic (biliary) disease mediated by sexually mature parasites, manifesting with cholangitis, obstructive jaundice and, very rarely, pancreatitis. Left untreated, the chronic stage may last for years (Caravedo and Cabada, 2020; Moshfe et al., 2020). Very few patients present with acute pancreatitis, and an extensive review of available data showed fewer than 10 reports of *Fasciola* spp. infection

complicated by pancreatitis (Pattarapuntakul et al., 2019). Symptoms may not be recognized or may be minimal in affected individuals in endemic areas. An overlap may be seen between the two phases, and symptoms suggestive of both acute and chronic disease may co-exist (Caravedo and Cabana, 2020).

Eosinophilia (especially during the hepatic stage) is a notable feature. Stool microscopy has low sensitivity for diagnosis due to intermittent release of bile fluids through the gut, failure to detect infections with low parasite burden, and inability to detect acute infections when eggs are not produced (Kaya et al., 2011; Gonzales Santana et al., 2013). While eggs are detected in 8–27% of stool examinations (Moshfe et al., 2020), stool microscopy has better specificity. Although invasive and impractical in most settings, eggs can be detected 3–4 weeks after exposure by examining duodenal or biliary aspirates (Kaya et al., 2011).

Fasciola-specific serology, such as antigen tests (serum, stool) and ELISA, are required for early diagnosis before the appearance of eggs in stool (10–12 weeks after infection), but both serology and stool microscopy should be performed in suspected cases (Gonzales Santana, 2013). Hypodense track-like lesions are demonstrated on imaging (especially MRI) during the migratory phase (Caravedo and Cabana, 2020).

Oral triclabendazole 10 mg/kg repeated after 12 h is the preferred treatment as it is active against metacercariae and adult worms (Tezer et al., 2013). Oral artesunate, metronidazole, nitazoxanide, praziquantel, albendazole and bithionol are less-effective alternatives (Hien et al., 2008; Gandhi et al., 2019).

The study patient consumed leafy vegetables frequently. There are no large water bodies in or around Addis Ababa. Leafy vegetables are purchased from grocery stores and local vendors selling from road-side carts. The produce sold is often from small-scale farms near the numerous small rivers flowing through the city. The patient presented with overlapping features of acute (eosinophilia, imaging findings) and chronic (acute pancreatitis) illness. His diagnosis was confirmed by ELISA for *F. hepatica*. Fascioliasis should be considered among people with predisposing dietary practices, eosinophilia and liver lesions.

Funding

This research did not receive any specific grant from funding agencies in the public, commercial, or not-for-profit sectors.

Author contributions

TA: Conception and design of study, data collection, data analysis, manuscript preparation and revision.

ST: Data collection, data analysis, manuscript revision.

KT: Data collection, data analysis, manuscript revision.

Conflict of interest statement

None declared.

Ethical approval

Not required.

References

- Bayu B, Asnake S, Woretaw A, Ali J, Gedefaw M, Fente T, et al. Cases of human fascioliasis in north-west Ethiopia. *Ethiop J Health Dev* 2005;19:237–40.
- Caravedo MA, Cabada MM. Human fascioliasis: current epidemiological status and strategies for diagnosis, treatment and control. *Res Rep Trop Med* 2020;11:149–58.
- Dermauw V, Muchai J, Al Kappany Y, Fajardo Castaneda AL, Dorny P. Human fascioliasis in Africa – a systemic review. *PLoS One* 2021;16.
- Fentie T, Erqou S, Gedefaw M, Desta A. Epidemiology of human fascioliasis and intestinal parasitosis among school children in Lake Tana Basin, northwest Ethiopia. *Trans R Soc Trop Med Hyg* 2013;107:480–6.
- Gandhi P, Schmitt EK, Chen CW, Samantray S, Venishetty VK, Hughes D. Triclabendazole in the treatment of human fascioliasis: a review. *Trans R Soc Trop Med Hyg* 2019;113:797–804.
- Gonzales Santana B, Dalton JP, Vasquez Camargo F, Parkinson M, Ndao M. The diagnosis of human fascioliasis by enzyme-linked immunosorbent assay (ELISA) using recombinant cathepsin L protease. *PLoS Negl Trop Dis* 2013;7:e2414.
- Hien TT, Truong NT, Minh NH, Dat HD, Dung NT, Hue NT, et al. A randomized controlled pilot study of artesunate versus triclabendazole for human fascioliasis in central Vietnam. *Am J Trop Med Hyg* 2008;78:388–92.
- Kaya M, Bestas R, Cetin S. Clinical presentation and management of *Fasciola hepatica* infection: single center experience. *World J Gastroenterol* 2011;17:4899–904.
- Lukambagire AH, Mchale DN, Nyindo M. Diagnosis of human fascioliasis in Arusha region, northern Tanzania by microscopy and clinical manifestations in patients. *BMC Infect Dis* 2015;15:1–8.
- Moazeni M, Ahmadi A. Controversial aspects of the cycle of *Fasciola hepatica*. *Exp Parasitol* 2016;169:81–9.
- Moshfe A, Aria A, Erfani N, Jamshidi A, Sarkari B, Abdolahi KS, et al. Clinical features, diagnosis and management of patients with suspicion of fascioliasis in Kohgiluyeh and Boyer-Ahmad province, southwestern Iran. *Iran J Parasitol* 2020;15:84–90.
- Nyindo M, Lukambagire AH. Fascioliasis: an ongoing zoonotic trematode infection. *BioMed Res Int* 2015;2015.
- Pattarapuntakul T, Ovartlarnporn B, Rojsanga W, Yungyoo T. Biliary fascioliasis in chronic calcific pancreatitis presenting with ascending cholangitis and biliary stricture. *Case Rep Gastroenterol* 2019;13:434–8.
- Tezer H, Yuksek SK, Parlakay AÖ, Gülhan B, Tavil B, Tunç B. Evaluation of cases with *Fasciola hepatica* infection: experience in 6 children. *Asian Pac J Trop Dis* 2013;3:211–16.