

# Saddle embolism treated by thrombolysis and thrombus aspiration via bilateral femoral artery puncture catheter

## A case report

Jie Min, MD, Guangqiang Zhang, MD\*

### Abstract

**Introduction:** Abdominal aortic saddle embolism is a rare and severe disease with the manifestation of abrupt onset, rapid progression and high mortality. Endovascular therapy becomes a new option for this disease due to its minor trauma, less complications, no requirement for general anesthesia or abdominal incisions, and shorter hospitalization duration.

**Methods:** A 50-year-old female was diagnosed as abdominal aortic saddle embolism, and thrombus aspiration was given immediately via bilateral femoral artery puncture catheter along with artery indwelling catheter thrombolysis.

**Results:** The saddle embolism was removed completely. After 1-month follow-up, the computed tomography angiography (CTA) examination showed neither stenosis nor thrombus in the abdominal aorta and iliac artery. The patient achieved perfect outcome.

**Conclusions:** Endovascular therapy may be an optional solution for saddle embolism.

**Abbreviations:** AAT = acute aortic thrombosis, CT = computed tomography, CTA = computed tomography angiography, DSA = digital subtraction angiography, MIP = maximum intensity projection.

**Keywords:** abdominal aortic saddle embolism, aorto-occlusive disease, indwelling catheter thrombolysis, thrombus aspiration

## 1. Introduction

Acute aortic thrombosis (AAT) is a rare life threatening event that leads to a sudden occlusion of the aorta. The mortality and morbidity of AAT is still high despite modern surgical techniques. Usually it is the result of a large saddle embolus to the aortic bifurcation. Abdominal aortic saddle embolism is a kind of AAT with the manifestation of abrupt onset, rapid progression and high mortality.<sup>[1,2]</sup> Currently, the treatment methods for arterial embolism include thrombolytic therapy, arterial dissection and endovascular therapy. Endovascular therapy becomes a new option for this disease due to its minor trauma, less complica-

tions, no requirement for general anesthesia or abdominal incisions, and shorter hospitalization duration. We report a case of abdominal aortic saddle embolism that was treated with thrombus aspiration via bilateral femoral artery puncture catheter along with artery indwelling catheter thrombolysis, and achieved perfect outcome.

## 2. Case report

A 50-year-old female presented to the emergency department with sudden onset pain and numbness in both lower limbs for 2 hours with no obvious predisposing cause, after which her lower limbs suffered continuous pain and numbness, especially on the left side. In the emergency department the doctor in charge diagnosed the patient as cerebral infarction. A further inquiry about the patient's medical history found the patient had a history of rheumatic heart disease for 10 years, and she was diagnosed with paroxysmal atrial fibrillation 10 days ago. Unfortunately, suggested treatment was refused by the patient. The patient was conscious and a physical examination revealed that she was well nourished with normal vital signs. Her heart rate was 100 per minute with arrhythmia. Her skin felt cool on both lower limbs, and there was no palpable pulse on the dorsalis pedis artery. Sensation was diminished but her tendon reflexes were normal in all extremities, and the muscle strength was classified V. The emergency computed tomography (CT) scan demonstrated thrombosis in the lower part of the abdominal aorta, bilateral iliac artery and left femoral artery. The artery was stenosed with incomplete or complete obstruction (Fig. 1).

We diagnosed the patient with abdominal aortic saddle embolism type II. Endovascular treatment was planned and

Editor: N/A.

We have not received financial support in our research.

The authors report no conflicts of interest.

Ethical statement: Our treatment plan was approved by all the family members of the patient and signed informed consent.

Department of Radiology, the Second Affiliated Hospital, Zhejiang University School of Medicine, Hangzhou, Zhejiang, China.

\* Correspondence: Guangqiang Zhang, Department of Radiology, the Second Affiliated Hospital, Zhejiang University School of Medicine, Hangzhou, Zhejiang, China (e-mail: zhgzqz@126.com).

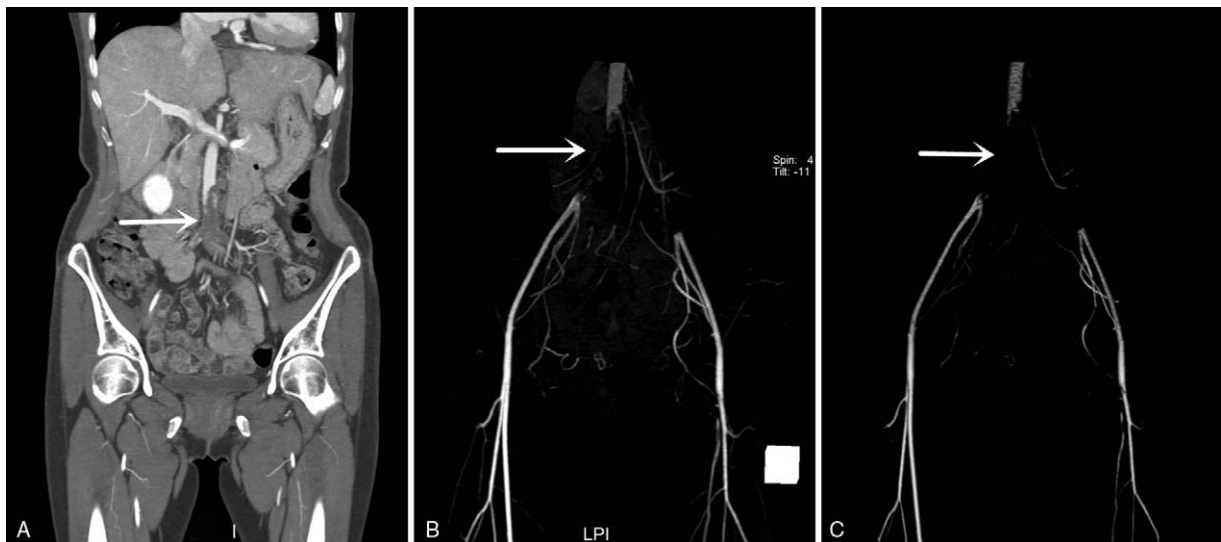
Copyright © 2018 the Author(s). Published by Wolters Kluwer Health, Inc. This is an open access article distributed under the terms of the Creative Commons Attribution-Non Commercial License 4.0 (CCBY-NC), where it is permissible to download, share, remix, transform, and buildup the work provided it is properly cited. The work cannot be used commercially without permission from the journal.

Medicine (2018) 97:13(e0212)

Received: 4 January 2018 / Received in final form: 28 February 2018 /

Accepted: 1 March 2018

<http://dx.doi.org/10.1097/MD.00000000000010212>



**Figure 1.** CTA shows thrombus (arrow heads) in the inferior segment of the abdominal aorta and bilateral common iliac artery, left femoral artery and left common iliac artery. (A) coronal maximum intensity projection (MIP). (B and C) volume reconstruction.

the plan was approved by her family members and signed informed consent. The patient was transferred to the interventional radiology department for emergency surgery. Left femoral artery puncture catheterization was performed and a 0.35 inch guidewire was passed into the stenosed part of the abdominal aorta. Digital subtraction angiography (DSA) was performed by a pigtail catheter (Fig. 2A). Then, thrombus aspiration was performed by a 8F guiding catheter. Since the thrombus could not be completely aspirated, the patient was given thrombolytic therapy with urokinase 40,000 units per hour, which was continuously injected by a micro pump through a thrombolysis catheter in the aorta. After 12 hours, the DSA showed no significant improvement in the stenosed aorta (Fig. 2B), so we continued the thrombolytic therapy. After 36 hours, we repeated the DSA and found that the major part of the thrombus had resolved (Fig. 2C). However, the left wall of the abdominal aorta and left common iliac artery proximal ends had mural thrombus which we assumed was stale thrombus. So we performed balloon dilatation in the left common iliac artery to expand the lumen. The stenosis in the left common iliac artery decreased after the operation.

Since the residual thrombus was in the left common iliac artery, it was difficult to aspirate from the right femoral artery catheter. So we planned a thrombus aspiration through the left femoral artery and found that the thrombus had flowed into the right femoral artery. While performing DSA in the catheter, we ensured that the pedicle of the thrombus was in the left wall of the abdominal aorta (Fig. 2D). Thrombus aspiration was performed by an 8F guiding catheter through the left femoral artery, and the head of the guiding catheter was positioned at the pedicle of the thrombus. We aspirated a large volume of white thrombus and mixed thrombus (Fig. 3). After the operation, DSA showed no thrombus in the abdominal aorta and the common iliac artery (Fig. 2E), but the lower extremities DSA showed that the left peroneal artery was occluded (Fig. 2F). We suspected that the thrombus was shedding from the upper artery and stopped thrombolysis therapy to decrease the risk of bleeding. The collateral circulation had already formed. The skin temperature of the left extremity recovered

and the pain disappeared after 1 day. CTA examination showed no stenosis or thrombus in the abdominal aorta and iliac artery after 1 month (Fig. 4).

### 3. Discussion

Arterial embolization often leads to ischemia or tissue necrosis, and could even lead to amputation or death. Acute embolic occlusion of the artery is associated with high morbidity and mortality. The mortality following surgical management of aortic emboli is reported to be 29%, but is as high as 58% without surgery. Surowiec et al reported that the overall in-hospital mortality is 31%. About 75% of arterial emboli are of cardiac origin, primarily due to atrial fibrillation and myocardial infarction. The final lodging site of an embolus correlates with the narrowing at bifurcation, laminar blood flow, and the origin of the embolus. About 25% of emboli lodge in the aortoiliac area, which is an extremely serious type of arterial embolization.<sup>[1]</sup> The cause of death is severe reperfusion injury, electrolyte disorder, and rapid multiple organ failure. The delay in diagnosis will seriously affect the prognosis of patients; so early detection is the key to diagnosis and treatment of the disease. The elderly are the high-risk population for this disease and often suffer from organic heart disease, atherosclerosis, atrial fibrillation, etc. So when patients have more risk factors along with decrease in local skin temperature or hypoesthesia, the possibility of aorto-occlusive disease should be considered to provide ample time for treatment.

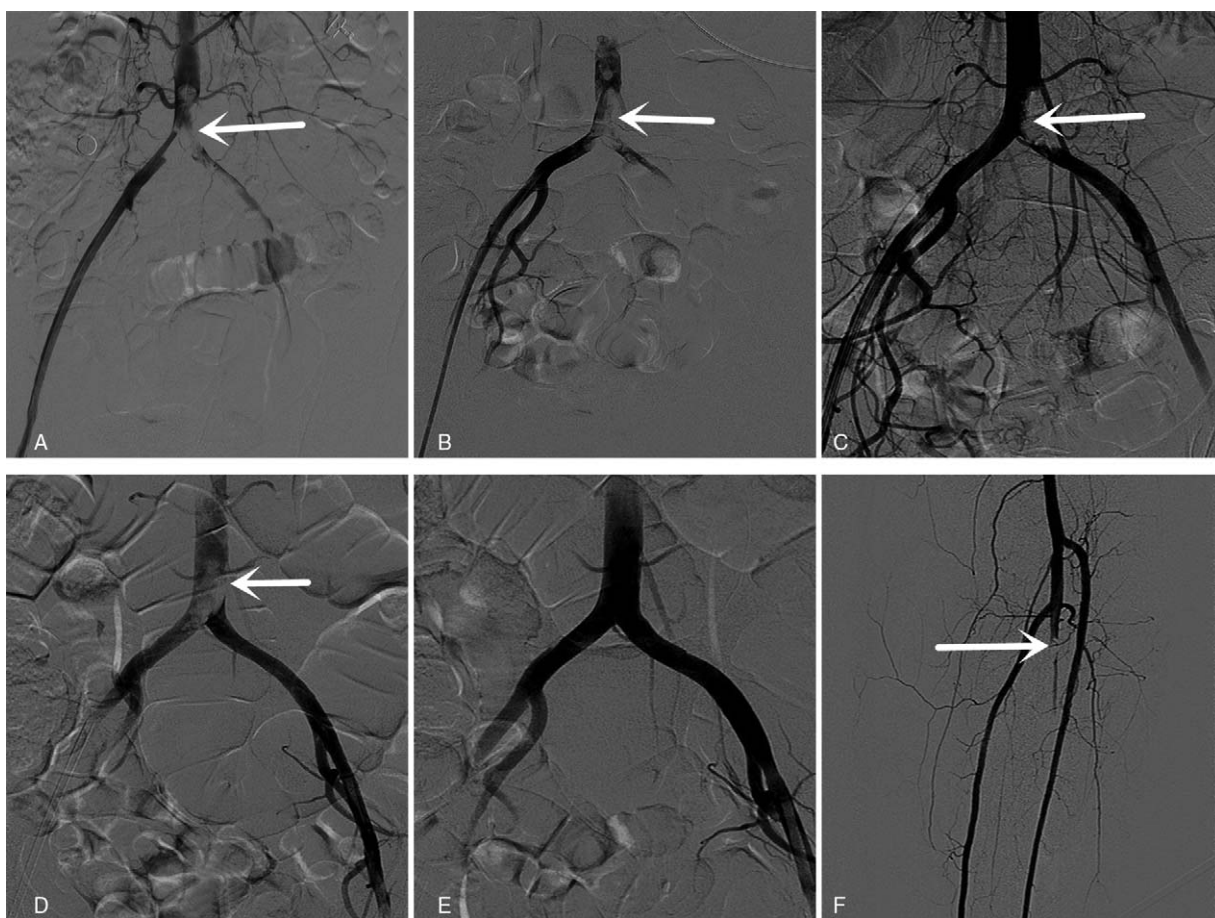
Aorto-occlusive disease is classified into 3 subtypes:

Type – I: stenoses within the aorta and common iliacs

Type – II: stenoses extending into the external iliac arteries

Type – III: stenoses within the aorta, iliac vessels and common femoral arteries.<sup>[3]</sup>

Currently, the treatment methods for arterial embolism include thrombolytic therapy, arterial dissection and endovascular therapy. Patients with limited stenosis or occlusions of types I and II are more suitable for endovascular therapy. Patients with wider stenosis or occlusion are more suitable for open surgery. However, pharmacological therapy is also an



**Figure 2.** (A) Emergency DSA shows thrombus (arrow heads) in the inferior segment of the abdominal aorta and bilateral iliac artery. (B) After 12 hours of thrombolysis, the thrombus presence can be noticed. (C) After 36 hours, the major part of thrombus was dissolved, and the left wall of the abdominal aorta and the left common iliac artery have proximal mural thrombus. (D) Left femoral arterial sheath angiography shows that the embolus in the left abdominal aorta wall is mural thrombus and floating. (E) After aspiration, the thrombus in the aortic and iliac artery completely disappeared. (F) Bilateral lower extremity angiography shows left fibular artery occlusion.

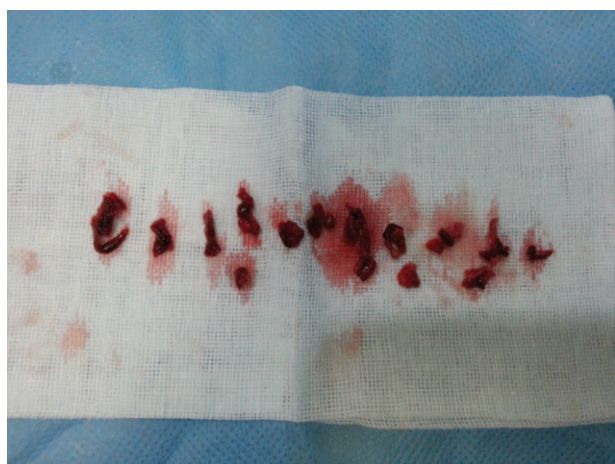auxiliary treatment option for this disease.<sup>[4]</sup> Doctors and patients are increasingly opting for endovascular therapy due to minor trauma, less complications, no requirement for general

anesthesia or abdominal incisions, and shorter hospitalization duration.<sup>[5]</sup>

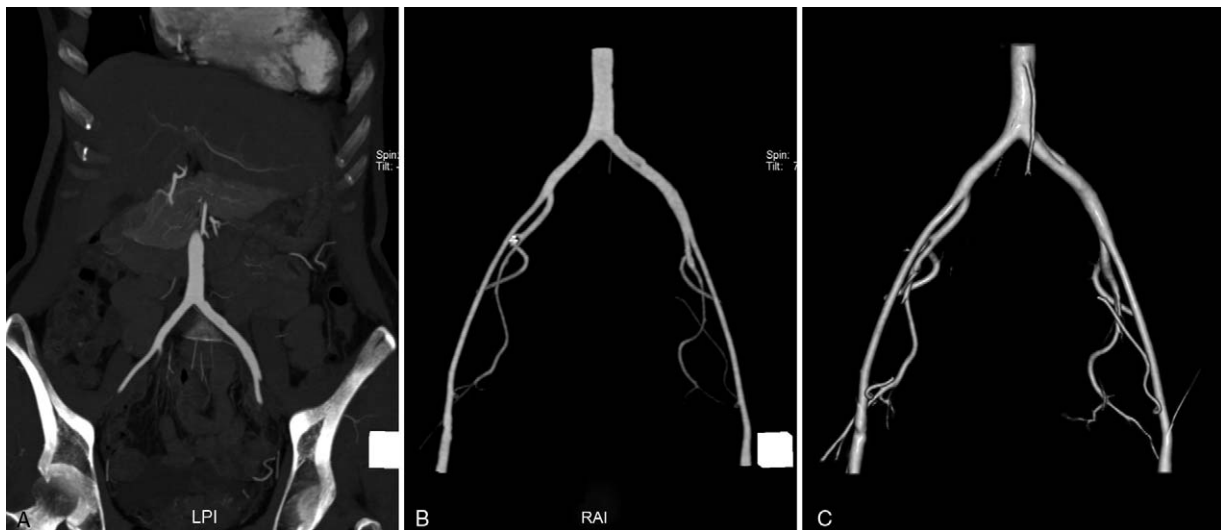
Our patient was classified as aorto-occlusive disease type II and achieved perfect outcome after arterial catheter thrombolysis and thrombus aspiration. We advocate investigating for aorto-occlusive disease in elderly patients with risk factors of atrial fibrillation or atherosclerosis. Our patient was diagnosed as cerebral infarction at the emergency room until her physical examination showed asymmetric skin temperature in the lower limbs. Surgical treatment of aorto-occlusive disease is not optimal due to its serious trauma and high mortality, so endovascular therapy should be the first option. Thrombolysis therapy alone cannot always completely dissolve the thrombus. We should try to find the attachment site during the surgery and perform thrombus aspiration to obtain perfect outcome.

#### 4. Conclusion

Early diagnosis is very important for aorto-occlusive patient. Patients have more risk factors along with decrease in local skin temperature or hypoesthesia, the possibility of aorto-occlusive disease should be considered. Endovascular therapy may be the first option for saddle embolism.



**Figure 3.** White thrombus and mixed thrombus aspirated by an 8F guiding catheter.



**Figure 4.** CTA shows no stenosis or thrombus in the abdominal aorta and the iliac artery after 1 month.

### Author contribution

Writing – original draft: J. Min.

Writing – review & editing: G. Zhang.

### References

- [1] Johnston RB Jr, Cohn EJJr, Cotlar AM. Acute embolic occlusion of the distal aorta. *Curr Surg* 2003;60:191–2.
- [2] Kaschwich M, Behrendt CA, Tsilimparis N, et al. Management of acute aortic thrombosis. *J Cardiovasc Surg* 2017;58:313–20.
- [3] Morris-Stiff G, Ogunbiyi S, Winter RK, et al. Aortic replacement in aorto-occlusive disease: an observational study. *BMC Surg* 2008;8:19–19.
- [4] Yamamoto H, Nishimaki H, Imai N, et al. Aortic thrombus in a patient with myeloproliferative thrombocytosis, successfully treated by pharmaceutical therapy: a case report. *J Med Case Rep* 2010;4:219–1219.
- [5] Alhan C, Karabulut H, Senay S, et al. Endovascular treatment of occlusive abdominal aortic thrombosis. *Heart Vessels* 2010;25:70–2.