


CASE REPORT

Open Access



Late endovascular coil migration following traumatic pulmonary artery pseudoaneurysm embolization: case report

Alina-Maria Budacan¹, Akshay J. Patel^{1,2*} , Helen Foss¹, Valeria Abiuso¹, Arul Ganeshan³ and Maninder Kalkat¹

Abstract

Background: Percutaneous vascular interventions are performed for the treatment of haemoptysis and involve embolization of bronchial arteries, pulmonary arteries and pulmonary arteriovenous malformations. There are isolated reports of embolization of pseudoaneurysms forming in the pulmonary vasculature. The migration of components of the coils used in the embolization of vascular pulmonary pathologies is rare.

Case presentation: A 46-year-old man presented to the emergency department with cough, haemoptysis, and expectoration of lengths of metal wire. He had an episode of coughing out a wire about a year prior to his admission to our hospital, which he attributed to be present in the can of coke he had consumed at that time and did not report it to the doctors. His past medical history was significant for stab injury to the right chest 17 years ago, for which he underwent right thoracotomy and exploration for bleeding. Injury to the lung parenchyma was noted and repair was performed by suturing the defect. Post operatively the CT scan demonstrated development of pulmonary artery pseudoaneurysm. We report a case of a patient expectorating coils 17 years after embolization of this traumatic pulmonary artery pseudoaneurysm. Radiological imaging demonstrated coils in the perihilar area of the lung parenchyma and in the tracheobronchial lumen. Operative intervention was used to remove the coils.

Conclusions: Although percutaneous catheter based vascular interventions have emerged as safe and effective procedures, the long-term complications such as coil migration, recanalization and need for further embolization ought to be considered and patients need to be counselled and followed-up accordingly. To the best of our knowledge, this is the first case of migrated coil post embolization of post-traumatic pulmonary artery pseudoaneurysm. Ultimately, the management of endobronchial coil migration post embolization, be it surgical or bronchoscopic, should be decided on a case-by-case basis, considering the patient's symptoms and the risk fatal complications.

Keywords: Endobronchial coil, Embolization, Complications

Introduction

Post-traumatic pulmonary artery pseudoaneurysms are rare, at risk of enlargement and rupture, and associated with high mortality [1]. They can be managed surgically or via percutaneous endovascular interventions, such as

introduction of metallic coils, with reported good outcomes [2]. Despite having a low rate of complications, coil embolization for pulmonary artery disorders do pose some risks such as recanalization, coil migration, coils misplaced in undesirable sites, damage to the vessel wall and delayed bacterial contamination of the thrombus and pulmonary artery. Erratic coil migration into the bronchial tree or other areas of the lung parenchyma is a very rare complication, with only a few cases having been described in the literature [3–5]. Erosion into the bronchi

*Correspondence: ajp.788@gmail.com

¹ Department of Thoracic Surgery, Queen Elizabeth Hospital, University Hospitals Birmingham, Mindelsohn Way, Birmingham B15 2TH, UK
Full list of author information is available at the end of the article



© The Author(s) 2022. **Open Access** This article is licensed under a Creative Commons Attribution 4.0 International License, which permits use, sharing, adaptation, distribution and reproduction in any medium or format, as long as you give appropriate credit to the original author(s) and the source, provide a link to the Creative Commons licence, and indicate if changes were made. The images or other third party material in this article are included in the article's Creative Commons licence, unless indicated otherwise in a credit line to the material. If material is not included in the article's Creative Commons licence and your intended use is not permitted by statutory regulation or exceeds the permitted use, you will need to obtain permission directly from the copyright holder. To view a copy of this licence, visit <http://creativecommons.org/licenses/by/4.0/>. The Creative Commons Public Domain Dedication waiver (<http://creativecommons.org/publicdomain/zero/1.0/>) applies to the data made available in this article, unless otherwise stated in a credit line to the data.

results in cough, expectoration, haemoptysis, and hoarseness [3]. The fistulisation into the pulmonary artery can result in air embolism or life-threatening haemoptysis [6, 7].

Case report

We report the case of a patient who expectorated a coil 17 yrs following embolization of a post-traumatic pulmonary artery pseudoaneurysm. A 46-year-old man presented to the emergency department with a cough, haemoptysis, and expectoration of lengths of metal wire. 17 years previously he had suffered a significant stab injury to the chest, for which he underwent right thoracotomy and exploration in a different hospital. A suture repair of a parenchymal lung injury was performed. Post-operative computed tomography (CT) scan demonstrated pulmonary artery pseudoaneurysm formation and percutaneous endovascular coils were inserted to prevent rupture and massive haemoptysis. The medical records had been destroyed by the time of this presentation; hence no further information was available.

During the current admission, chest x-ray and chest CT demonstrated coils in the right lung parenchyma posterior to the oblique fissure, with a length of coil in the lower lobe bronchus, resulting in adjacent haemorrhagic areas and pneumatoceles (Fig. 1). The patient underwent

rigid and flexible bronchoscopy, re-do right thoracotomy, lower lobectomy and removal of the coils.

Bronchoscopy identified a thin wire emerging from the right lower lobe basal segmental bronchus into the right main bronchus, extending to the proximal trachea and larynx. There was marked inflammation with significant blood-stained purulent secretions emanating from the lower lobe bronchus. The wire could not be pulled out with gentle traction. On entry into the chest, the lung was densely adherent to the chest wall and posterior mediastinum. The adhesions were particularly dense and inseparable from the oesophagus, azygos vein and the whole area was one thick indistinguishable fibrotic mass. A subsequent lower lobe bronchotomy was performed and the wire was traced into the lower lobe. This wire was removed, and lower lobectomy was performed by dissecting out all the relevant structures. The bronchus intermedius was stapled off just distal to uptake of middle lobe bronchus where it was less inflamed. After removal of the lower lobe, it was noted that there was a dense fibrotic mass around the posterior segment of the upper lobe. The upper lobe itself was densely fibrotic and stuck to the chest posteriorly and inseparable from the oesophagus and the azygos vein.

After lower lobe removal, the residual fibrotic area was incised to ensure no further wires were left in situ. It was

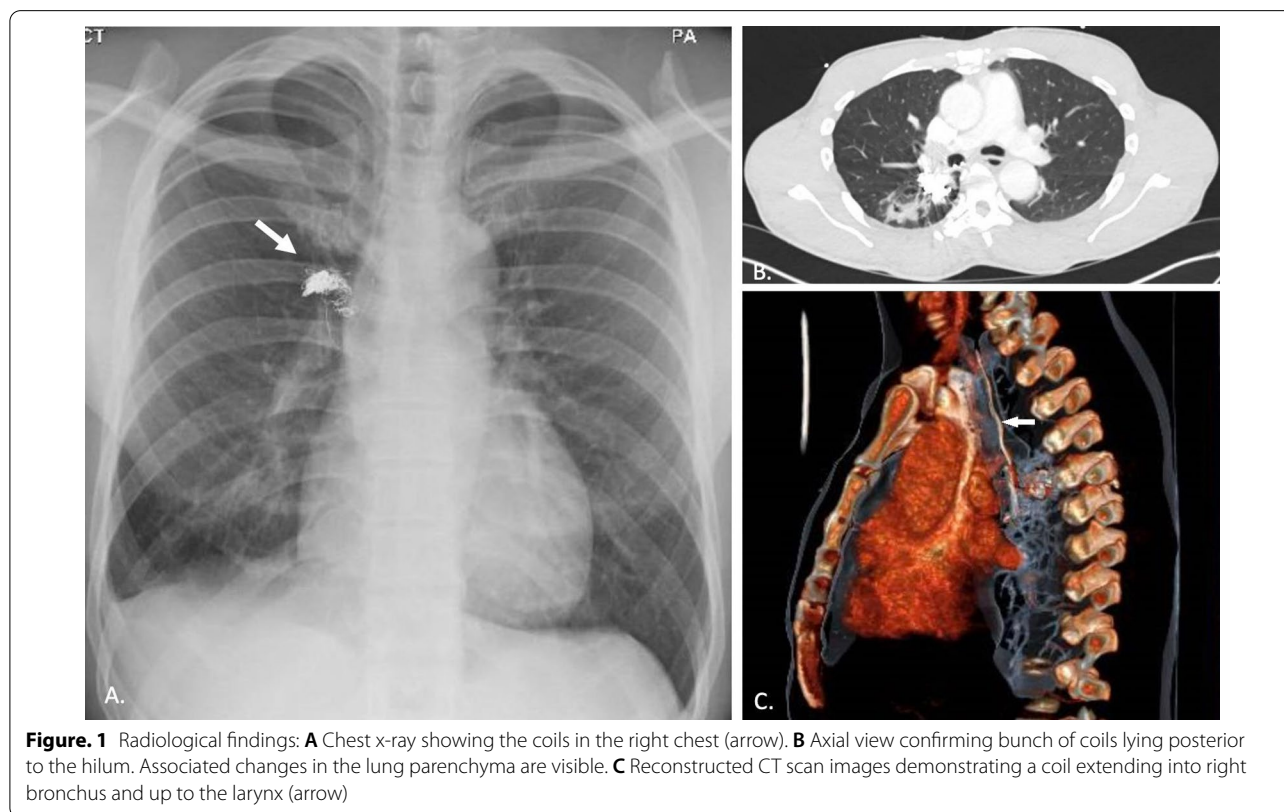


Figure. 1 Radiological findings: **A** Chest x-ray showing the coils in the right chest (arrow). **B** Axial view confirming bunch of coils lying posterior to the hilum. Associated changes in the lung parenchyma are visible. **C** Reconstructed CT scan images demonstrating a coil extending into right bronchus and up to the larynx (arrow)

well encapsulated (3*2 cm) and this process revealed necrotic pinkish grey material and a bunch of wires which were subsequently removed. At this point the cavity was closed as there was no evidence for fistulation into the airways or any such tracheobronchial communication. Several coils of metal wires were removed, and the cavity was cleared of all the necrotic debris. The wall of this cavity was inflamed granulation tissue and due to the size, location and adhesions to the mediastinum and oesophagus, the resection was felt not to be possible. In view of this, the cavity was closed using interrupted 2-0 Vicryl suture in two layers ensuring obliteration of the cavity.

Four days post-operatively, the patient showed no sign of clinical improvement and this correlated with worsening inflammatory markers and an exaggerated SIRS response. Features of empyema were noted on imaging. The patient was taken back to theatre for rigid bronchoscopy where pus was seen coming out of the right lower lobe bronchial stump soiling the left side. This was vigorously suctioned, and the chest re-opened via the same posterolateral incision (right). The cavity was washed out and it was noted that the previous suture on the capsule of the posterior segment of upper lobe had broken down and resulted in a communication between the capsule and the stump of the lower lobe bronchus. As such, an intercostal muscle bundle was harvested and patched on the opening of the fistulous tract of the lower lobe bronchial stump with multiple 3-0 vicryl. Post patching, there was minimal air leak on dual lung ventilation and at repeat bronchoscopy there was no further purulent discharge from lower lobe stump.

Streptococcus anginosus, *Bacteroides fragilis* and *Eikenella corrodens* were grown from operative samples. The patient was discharged home with chest drain in situ and a long course of appropriate antibiotics. The chest drain was later removed in the outpatient clinic. The current follow-up period to date is 12 months since discharge.

Comment

The patient described in this report proceeded to surgery to mitigate against the potential for complications such as haemoptysis, recurrent chest infections and troublesome symptoms of cough. The type of intervention, however, was debateable between bronchoscopic retrieval of the coils or open surgical procedure to resect the lung parenchyma containing the coils. The uncertainty of retrieving all the coils endoscopically, possibility of haemorrhage and perceived difficulty of emergency thoracotomy due to adhesions from the previous surgery led to the decision in favour of a surgical intervention.

Some cases of migrated coils fistulating into the bronchus have been removed endobronchially using rigid bronchoscopy [3]. However, most documented cases with migration of these coils have been treated with surgical resection of varying amounts of lung parenchyma and coil retrieval. Abad et al. reported a case of endobronchial coil migration 6 weeks after embolization for a segmental pulmonary artery aneurysm, treated by right lower lobectomy [4] and the use of basal segmentectomy has also been reported to treat similar complications [8].

To the best of our knowledge, this is the first case of migrated coil following embolization of post-traumatic pulmonary artery pseudoaneurysm. On reflection, placing a muscle bundle or some form of vascularised pedicle over the bronchial stump at the time of the lobectomy, particularly in the setting of such inflammation may have helped to avoid fistulation and propagation of sepsis. Ultimately, the management of endobronchial coil migration post-embolization, be it surgical or bronchoscopic, should be decided on a case-by-case basis, taking into account the patient's symptoms and the risk of fatal complications.

Acknowledgements

No further acknowledgments to make.

Author contributions

All authors contributed to this piece of work. All authors read and approved the final manuscript.

Funding

There are no sources of funding to declare.

Availability of data and materials

All data and materials are available upon reasonable request from the corresponding author.

Declarations

Ethics approval and consent to participate

There was no ethical approval needed as this did not directly involve patients.

Consent for publication

Consent was sought from the patient in question.

Competing interests

There are no known competing interests.

Author details

¹Department of Thoracic Surgery, Queen Elizabeth Hospital, University Hospitals Birmingham, Mindelsohn Way, Birmingham B15 2TH, UK. ²Institute of Immunology and Immunotherapy, University of Birmingham, Birmingham, UK. ³Department of Interventional Radiology, University Hospitals Birmingham (Heart of England), Bordesley Green East, Birmingham B9 5SS, UK.

Received: 28 December 2021 Accepted: 17 April 2022

Published online: 27 April 2022

References

1. Pelage JP, El Hajjam M, Lagrange C, et al. Pulmonary artery interventions: an overview. *Radiographics*. 2005;25:1653–67.

2. Ishimoto S, Sakurai H, Higure R, et al. Pulmonary artery pseudoaneurysm secondary to lung inflammation. *Ann Thorac Cardiovasc Surg*. 2018;24:154–6.
3. Ishikawa H, Omachi N, Ryuge M, et al. Erratic coil migration in the bronchus after bronchial artery embolization. *Respirol Case Rep*. 2019;7:1–5.
4. Abad J, Villar R, Parga G, et al. Bronchial migration of pulmonary arterial coil. *Cardiovasc Intervent Radiol*. 1990;13:345–6.
5. Umehara T, Aoki M, Kamimura G, et al. Coil intrabronchial migration in an arteriovenous malformation patient treated 10 years ago. *Ann Thorac Cardiovasc Surg*. 2017;23:200–2.
6. Loke GPY, Story DA, Liskaser F, et al. Pulmonary arteriovenous malformation causing massive haemoptysis and complicated by coronary air embolism. *Anaesth Intensive Care*. 2006;34:75–8.
7. Hoffman WS, Weinberg PM, Ring E, et al. Massive hemoptysis secondary to pulmonary arteriovenous fistula. Treatment by a catheterization procedure. *Chest*. 1980;77:697–700.
8. Elhusseiny M, Moawad A, AbdAlla D, et al. Pulmonary artery coil: unexpected expectorated foreign body. *Chest*. 2016;149:A421.

Publisher's Note

Springer Nature remains neutral with regard to jurisdictional claims in published maps and institutional affiliations.

Ready to submit your research? Choose BMC and benefit from:

- fast, convenient online submission
- thorough peer review by experienced researchers in your field
- rapid publication on acceptance
- support for research data, including large and complex data types
- gold Open Access which fosters wider collaboration and increased citations
- maximum visibility for your research: over 100M website views per year

At BMC, research is always in progress.

Learn more biomedcentral.com/submissions

