

Received: 2018.03.01
Accepted: 2018.05.29
Published: 2018.08.23

e-ISSN 1941-5923
© Am J Case Rep, 2018; 19: 998-1003
DOI: 10.12659/AJCR.909717

High Resolution Impedance Manometry: A Necessity or Luxury in Esophageal Motility Disorder?

Authors' Contribution:
Study Design A
Data Collection B
Statistical Analysis C
Data Interpretation D
Manuscript Preparation E
Literature Search F
Funds Collection G

BEF 1 **Han Sin Boo**
E 1 **Ian Chik**
D 2 **Chai Soon Ngiu**
BD 3 **Shyang Yee Lim**
EG 1 **Razman Jarmin**

1 Department of Surgery, Universiti Kebangsaan Malaysia Medical Center, Cheras, Kuala Lumpur, Malaysia
2 Department of Gastroenterology, Universiti Kebangsaan Malaysia Medical Center, Cheras, Kuala Lumpur, Malaysia
3 Division of Upper Gastrointestinal Surgery, Department of General Surgery, Penang General Hospital, Penang, Malaysia

Corresponding Author: Ian Chik, e-mail: ianchik@ppukm.ukm.edu.my
Conflict of interest: None declared

Case series

Patient: Female, 71 • Male, 48 • Female, 44 • Female, 62
Final Diagnosis: Esophageal motility disorder
Symptoms: Dysphagia
Medication: —
Clinical Procedure: Manometry
Specialty: Gastroenterology and Hepatology

Objective: Rare disease


Background: The esophagus can be affected by a variety of disorders that may be primary or secondary to another pathologic process, but the resulting symptoms are usually not pathognomonic for a specific problem, making diagnosis and further management somewhat challenging. High resolution impedance manometry (HRiM) has established itself as a valuable tool in evaluating esophageal motility disorder. HRiM is superior in comparison with conventional water perfused manometric recordings in delineating and tracking the movement of functionally defined contractile elements of the esophagus and its sphincters, and in distinguishing the luminal pressurization of spastic esophageal contraction from a trapped bolus. Making these distinctions can help to identify achalasia, distal esophageal spasm, functional obstruction, and subtypes according to the latest Chicago Classification of Esophageal Motility Disorders version 3.0.

Case Report: We report a case series of 4 patients that presented with dysphagia; and with the ancillary help of the HRiM, we are able to diagnose esophageal motility disorder and evaluate its pathogenetic mechanism. This approach aids in tailoring each management individually and avoiding disastrous mismanagement.

Conclusions: From the series of case reports, we believe that HRiM has an important role to play in deciding appropriate management for patients presenting with esophageal motility disorders, and HRiM should be performed before deciding on management.

MeSH Keywords: Diagnostic Errors • Esophageal Motility Disorders • Manometry

Full-text PDF: <https://www.amjcaserep.com/abstract/index/idArt/909717>

 2307

 1

 4

 14



Background

Esophageal motility disorders (EMDs) are uncommon but vary in etiology as it can be primarily a disease of the esophagus, or it can be a secondary from another systemic disease. EMDs usually present with dysphagia, chest pain, or both, due to the loss of esophageal coordination of contraction, or due to incorrect pressure contractions (too high or too weak, rendering ineffective contractions). Common EMDs include achalasia, spastic esophageal motility disorders (diffuse esophageal spasm/DES, nutcracker esophagus, and hypertensive lower esophageal sphincter), non-specific esophageal motility disorder (inefficient esophageal motility disorder), and secondary esophageal motility disorders (secondary to scleroderma, diabetes mellitus, alcohol consumption, psychiatric disorders and presbyesophagus). Given the variation of etiology, each disease variation requires specific tailored management according to its full diagnosis, least patient be given substandard and unsuccessful treatment.

The usual workup for patient with suspicion of EMD is classically barium esophagography, supplemented with water-perfused esophageal manometry. An esophagogastroscope would also be performed to ensure that there is no mechanical obstruction or pseudo achalasia causes like esophageal gastric junction tumors. With high resolution impedance manometry (HRiM), more data is available and is an essential adjunct in the diagnosis and planning of treatment for EMDs. This includes distal contraction integral and bolus transit, which is useful in diagnosing minor EMDs.

HRiM is essentially an upgrade to regular manometry, to which more sensors are placed closer, as to obtain more information. It then produces results that are presented dynamically, yielding anatomy and pressure gradients, and the contractile activity of the esophagus. HRiM is better than conventional manometry in recording the movement of the esophagus and its sphincters, and it is able to differentiate the luminal pressurization of spastic esophageal contraction and a trapped bolus [1]. Knowing this difference can help diagnose achalasia, distal esophageal spasm, esophago-gastro junction outflow obstruction, and subtypes as per Chicago Classification of Esophageal Motility Disorders version 3.0 [2]. A further illustration of the subtypes of EMDs and the diagnostic characteristics are shown in Table 1.

In this case series, we review 4 different patients and discuss their diagnosis. We discuss the use of HRiM in each patient's workup and how it differs in terms of the patient's diagnosis.

Case Reports

This case series consists of 3 females and 1 male. The mean age was 56 years (range of 44 to 71 years). All of the patients had symptoms of dysphagia and regurgitation. Two patients had HRiM prior to surgical decision and the other 2 patients had surgery prior to the introduction of HRiM to our center on July 2014.

Patient A

A 71-year-old Indian female with underlying rheumatoid arthritis was diagnosed with gastroesophageal reflux disease (GERD) with dysphagia and was on prolonged proton pump inhibitor (PPI). Despite treatment, she remained symptomatic and was referred for feasibility of fundoplication. An esophagogastroduodenoscopy (OGDS) done on July 2014 showed hiatal hernia and a moderately dilated esophagus with limited peristalsis. She also had reflux esophagitis (Los Angeles (LA) Classification Grade B). HRiM was done as part of her pre-fundoplication workup, which revealed aperistaltic esophagus [median distal contractile integral (DCI) 2 mmHg-cm-s with 10 swallows] with hypotensive lower esophageal sphincter (LES), normal integrated relaxation pressure (IRP), complete failed bolus transit in all swallows (Figure 1) based on impedance. A barium swallow study on September 2014 showed dilated mid to distal esophagus with poor peristaltic wave, raising the suspicion of EMD. Due to absent contractility and failed bolus transit, the patient did not proceed for fundoplication as this would worsen her dysphagia.

Patient B

A 48-year-old Chinese male was referred for surgical intervention of Zenker's diverticulum. He presented with a 1-month history of dysphagia to solid, with recurrent complaints of pharyngitis and left neck swelling. A barium swallow study showed outpouching lesion at the left lateral aspect of upper esophagus. OGDS revealed a diverticulum, 17 cm from the incisor with food debris, the esophagus appeared mildly dilated but peristalsis was noted. Esophageal HRiM showed a weak upper esophageal sphincter with hypercontractile esophagus and increased contraction vigor DCI >8000 mmHg-cm-s in more than 20% of swallows (Figure 2). He also had reduced bolus transit based on impedance. Based on the Chicago Classification v3.0, the patient was diagnosed with Jackhammer esophagus [2]. Due to high DCI, this patient did not undergo any surgery, and neither was he treated with medication, but had improvement with a change in diet. During his last clinic follow-up, he had no more complaints of dysphagia or even halitosis.

Table 1. Subtypes of esophageal motility disorder and its diagnostic criteria [2].

Esophageal motility disorder	Median IRP	Peristalsis	DCI	Others
Achalasia				
Type I	Increased (>15 mmHg)	100% failed	<00 mmHg-cm-s	
Type II	Increased (>15 mmHg)	100% failed	Not calculated	Contractions may not be seen due to esophageal pressurization.
Type III	Increased (>15 mmHg)	Abnormal peristalsis	20% or more swallows have DCI >450 mmHg-cm-s	Premature contraction. May be mixed with pan esophageal pressurization
EGJ outflow obstruction	Increased (>15 mmHg)	Present but differs from type III		
Major disorders of peristalsis				
Absent contractility	Normal	100% failed		
Distal esophageal spasm	Normal	Premature contractions	DCI >450 mmHg/cm/s	
Hypercontractile esophagus (jackhammer)	Normal	Hypercontractility may be confined to lower esophageal sphincter only, or in combination with rest of esophagus	2 swallows or more have DCI >8000 mmHg-cm-s	
Minor disorders of peristalsis				
Ineffective esophageal motility (IEM)		50% or more swallows are ineffective. May be failed or weak swallows	DCI <450 mmHg-cm-s	
Fragmented peristalsis		50% or more swallows are ineffective		
Normal esophageal motility	None of criteria described as above			

Premature contractions with DCI <450mmHg-cm-s fulfills “failed peristalsis criteria”. Cutoffs here were using Sierra device.

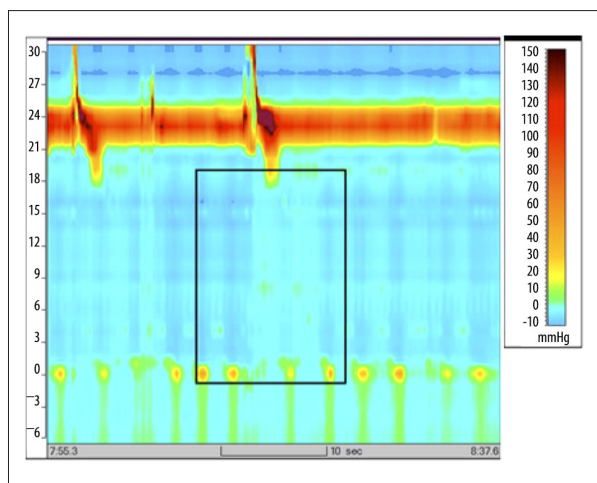


Figure 1. Aperistaltic esophagus with hypotensive LES and normal IRP 2 mmHg. Complete failed bolus transits in all swallows. LES – lower esophageal sphincter; IRP – integrated relaxation pressure.

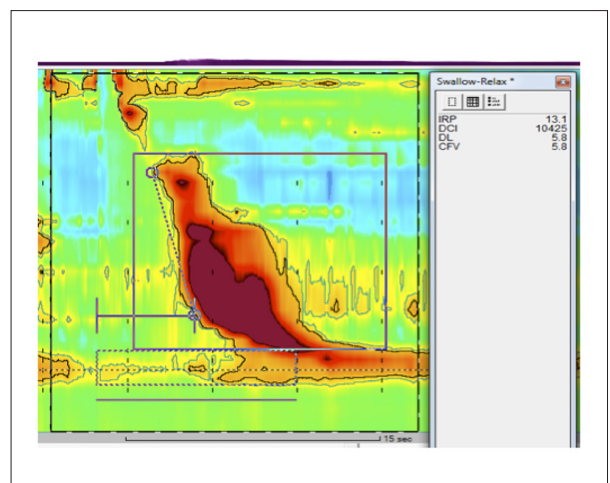


Figure 2. Normal IRP (16 mmHg) and DL (5.4 sec). Increased DCI >8000 mmHg-cm-s. IRP – integrated relaxation pressure; DL – distal latency; DCI – distal contraction integral.

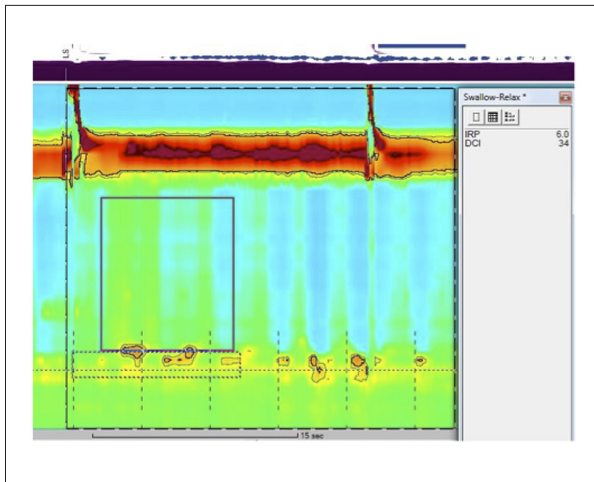


Figure 3. Ineffective esophageal motility with hypotensive LES (LESP 5.5 mmHg; IRP 6 mmHg). LES – lower esophageal sphincter; IRP – integrated relaxation pressure.

Patient C

A 44-year-old Indian female was clinically diagnosed with achalasia cardia and underwent surgical myotomy without anti-reflux procedure. Despite the surgery, she remained symptomatic and underwent multiple pneumatic balloon dilatations. A barium study was done post-surgery, and it was suggestive of recurrent achalasia. She had water-perfused conventional manometry done for her recurrent symptoms which showed aperistaltic esophagus with normal LES pressure. A recent OGDS showed a LA Classification Grade D reflux esophagitis with Schatzki's ring. HRiM revealed an ineffective esophageal motility with hypotensive LES (LESP 5.5 mmHg; IRP 6 mmHg) (Figure 3). Her DCI was within normal limits with reduced bolus transit, resulting in the decision for conservative management. Her condition fell under the diagnosis of fragmented peristalsis.

Patient D

A 62-year-old Indian female was diagnosed with esophageal diverticulum and underwent left thoracotomy and esophageal diverticulectomy. She remained symptomatic with odynophagia and dysphagia to solid. Water-perfused conventional manometry had normal findings. A repeat OGDS showed recurrent distal esophageal diverticulum at 32 cm, with the esophagogastric junction patent. A video-fluoroscopy showed contrast hold-up proximal to the diverticulum, with proximal esophagus dilatation. We proceeded with HRiM, which confirmed that the patient had IEM (Figure 4) with a DCI of 2 mmHg-cm-s and failed bolus transit. Her disease was classified as a minor disorder of dysmotility according to the Chicago Classification v3.0 [2].

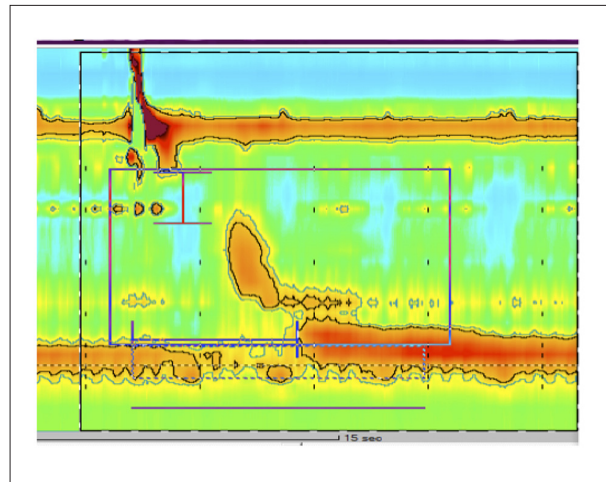


Figure 4. Fragmented peristalsis (minor disorder of dysmotility) →50%fragmented contraction with DCI >450 mmHg, i.e., impaired clearance; DCI 893 mmHg, IRP 17 mmHg (N). DCI – distal contraction integral; IRP – integrated relaxation pressure.

Discussion

Esophageal motility disorders (EMDs) consist of a complicated array of disturbances associated with dysphagia, gastroesophageal reflux, and noncardiac chest pain [3]. Until now, it has been unclear as to whether EMDs represent an independent group of diseases or an incidental phenomenon caused by other diseases as the clinical presentation may be perplexing. High resolution impedance manometry (HRiM) has established itself as a valuable tool in evaluating benign EMD and this may serve as basis to offer the appropriate therapeutic options for the patients [4].

Patient A and Patient B had their manometry done prior to surgical decision. Patient A was referred for fundoplication in view of severe GERD and PPI dependent. The presence of dysphagia in a patient with heartburn is an alarming symptom. In the algorithm of management of dysphagia, upper endoscopy is highly recommended to look for mechanical esophageal obstruction. In contrast, this patient has a dilated esophagus, pooling of liquid or saliva, and reflux changes at the distal esophagus without an obvious intraluminal obstructing lesion. This led to the suspicion of esophageal motility disorder. The commonest motility esophageal disorder that could mimic GERD is achalasia cardia. In achalasia, retained food as a result of failed bolus transit is fermented to acid and thus produces heartburn like symptoms of GERD. Narrowing of the distal esophagus that mimicked bird's beak appearance that was demonstrated in the barium swallow of this patient, may cause a misdiagnosis of achalasia cardia. Placing the pieces together with the HRiM findings of aperistalsis and hypotensive LES (without esophagogastric obstruction), points to

the diagnosis of scleroderma with an early reflux stricture. By subjecting this patient to a fundoplication without diagnosing the underlying aperistaltic esophagus via HRiM, would inevitably cause complete dysphagia. On the other hand, a myotomy is equally as morbid in worsening reflux. In patient A's case, conservative management may not fully cure the symptoms, but it would possibly worsen her condition if any surgical intervention were performed.

Patient B was referred as a case of Zenker's diverticulum for surgical intervention after confirmation with OGDS and barium swallow studies. Literature has shown that esophageal manometry is not routinely required. However, it may help to illuminate the pathogenesis of the diverticulum [5] HRiM was performed in view of this patient's atypical presentation of Zenker's diverticulum at a relative young age compared to the classical presentation in the elderly population. HRiM revealed that the patient had a hypertensive esophagus of Jackhammer esophagus. A diverticulectomy would likely have been offered for treatment for this patient if HRiM was not performed. This would have led to a possible disastrous complication of a leak to a recurrent diverticulum, as the issue of high intra-luminal esophageal pressure from the spastic esophagus contraction had not been resolved. On the other hand, a simple change in the patient's diet and intake of food bolus *per se*, improved his symptoms without further intervention and the need to start pharmaceutical treatment.

Patient C and Patient D underwent surgical intervention prior to the introduction of HRiM. Patient C remained symptomatic despite surgical myotomy and repeated endoscopic pneumatic balloon dilatation for achalasia cardia. HRiM revealed ineffective esophageal motility with hypotensive LES and absent peristalsis. In hindsight, we postulated that this patient was incorrectly diagnosed with achalasia based on the barium swallow study alone, when she actually had a fragmented peristalsis with severe reflux stricture. Hence, there was no return of peristalsis despite a normal LES relaxation after repeated surgical and endoscopic myotomy. She was treated with pro-motility medication and anti-acid treatment. She was also advised to modify her diet as to ease the transit of food. However, she was still somewhat symptomatic despite medical treatment.

Patient D was diagnosed with esophageal diverticulum. A manometry would have diagnosed her with a pulsion diverticulum. However, she was treated with diverticulectomy resulting in a leak from diverticulectomy post-operatively. According to her result parameters on the HRiM, this patient had IEM. However, due to poor bolus transit, she was only treated with pro-motility medication and diet modification. She remained quite asymptomatic and did not required further treatment.

HRiM is not widely available currently, and many clinicians do not see its importance in the clinical setting. Based on history, examination, and investigation findings, the conventional patient workup is a barium swallow study or upper endoscopy. With the limited data that barium swallow study or upper endoscopy provides, patients are often subjected to surgery. If esophageal dysmotility disorder is suspected based on the history of the patient, or even based on clinical findings, we suggest the inclusion of HRiM as a confirmation of diagnosis before embarking on surgery, which potentially can be morbid for the patient if complications ensue. As previously mentioned, HRiM has a higher sensitivity than the normal manometry due to the information retrieved and its display shown in aiding interpretation of disease.

Esophageal motility is studied by looking at peristaltic pressure and bolus transit. Conventionally, bolus transit has been studied using barium swallow tests, but with intraluminal impedance tests, the same function may be carried out [6]. In the latest Chicago Classification v3.0, bolus transit becomes important, and as it looks at ineffective swallows, it helps arrive at diagnosis, especially in minor disorders of peristalsis [2]. Jain et al. [7] found that while manometry measures peristalsis, impedance measures the actual bolus movement, making it a very powerful combination for the purpose of diagnosis, as 51% of patients with IEM have normal bolus transit. IEM is a minor EMD, which is usually a combination of weak and failed peristalsis. By definition, IEM has a weak peristalsis, with small and large peristaltic defects, and often failed peristalsis, with at least half of the swallows having a DCI less than 450 mmHg-cm-s [8]. As high as 49.4% patients that present with GERD were actually found to have IEM [9], which means it may be more common than initially thought. However, further studies are only warranted when a patient presents with worrying symptoms like dysphagia.

As IEM is associated with reflux disease [10], one may perhaps attempt to conclude that for patients diagnosed with IEM who have poor bolus and reduced DCI, there can be attempts of treatment with prokinetics. This association was also delineated in studies by Simren et al. [11] and Fornari et al. [12]. Jain et al. [7] suggested that in patients with DCI <100 mmHg-cm-s and impaired bolus clearance, prokinetics like bethanechol can be used, while a patient with DCI <100 mmHg-cm-s but with reasonable bolus transit and GERD may still be treated with a partial anti-reflux. In the same paper, patients with IEM with DCI >100 mmHg-cm-s were opted for conservative management. Heider et al. [13] claimed that esophageal body contraction amplitude improves with anti-reflux surgery, giving further support to the association of IEM and reflux disease. However, Mello et al. [10] disagreed in his study of 68 patients, where it was seen that some patients persist, while some others develop new onset of IEM.

Impedance is not yet included in the latest Chicago Classification v3.0 [2], although bolus transit is mentioned in the diagnosis of minor motility disorder. Its advantage in the use during patient workup for motility disorders is that it does not include radiation exposure [14]. It may be difficult to justify the complete use of HrIM as an adjunct at this point, as Patient B would not require impedance to diagnose Jackhammer esophagus. The cost effectiveness of performing this study is also unknown and further studies should be performed to see its importance in managing esophageal motility disorders. The caveat to this case series is that Chicago Classification v3.0 is originally meant for non-operated esophagus. Despite this, we still believe that it will be helpful in decision-making for post-operative EMDs.

References:

1. Kahrilas PJ, Sifrim D: High-resolution manometry and impedance-pH/manometry: Valuable tools in clinical and investigational esophagology. *Gastroenterology*, 2008; 135: 756–69
2. Kahrilas PJ, Bredenoord AJ, Fox M et al: The Chicago Classification of esophageal motility disorders, v3.0. *Neurogastroenterol Motil*, 2015; 27(2): 160–74
3. Richter JE: Oesophageal motility disorders. *Lancet*, 2001; 358: 823–28
4. Zerbib F, Roman S: Current therapeutic options for esophageal motor disorders as defined by the Chicago Classification. *J Clin Gastroenterol*, 2015; 49(6): 451–60
5. Nehring P, Krasnodębski IW: Zenker's diverticulum: Aetiopathogenesis, symptoms and diagnosis. Comparison of operative methods. *Prz Gastroenterol*, 2013; 8(5): 284–89
6. Abdel Jalil AA, Castell DO: Ineffective esophageal motility (IEM): The old-new frontier in esophagology. *Curr Gastroenterol Rep*, 2016; 18(1): 1
7. Jain A, Baker JR, Chen JW: In ineffective esophageal motility, failed swallows are more functionally relevant than weak swallows. *Neurogastroenterol Motil*, 2018; 30(6): e13297
8. Xiao Y, Kahrilas PJ, Kwasny MJ et al: High-resolution manometry correlates of ineffective esophageal motility. *Am J Gastroenterol*, 2012; 107(11): 1647–54
9. Ho SC, Chang CS, Wu CY, Chen GH: Ineffective esophageal motility is a primary motility disorder in gastroesophageal reflux disease. *Dig Dis Sci*, 2002; 47(3): 652–56
10. Mello MD, Shriver AR, Li Y et al: Ineffective esophageal motility phenotypes following fundoplication in gastroesophageal reflux disease. *Neurogastroenterol Motil*, 2016; 28(2): 292–98
11. Simren M, Silny J, Holloway R et al: Relevance of ineffective oesophageal motility during oesophageal acid clearance. *Gut*, 2003; 52: 784–90
12. Fornari F, Blondeau K, Durand L et al: Relevance of mild ineffective oesophageal motility (IOM) and potential pharmacological reversibility of severe IOM in patients with gastro-oesophageal reflux disease. *Aliment Pharmacol Ther*, 2007; 26(10): 1345–54
13. Heider TR, Behrns KE, Koruda MJ et al: Fundoplication improves disordered esophageal motility. *J Gastrointest Surg*, 2003; 7(2): 159–63
14. Tutuian R, Castell DO: Clarification of the esophageal function defect in patients with manometric ineffective esophageal motility: Studies using combined impedance–manometry. *Clin Gastroenterol Hepatol*, 2004; 2(3): 230–36

Conclusions

We concluded that HrIM is an important diagnostic adjunct that could affect the management decision of benign esophageal disorders and hence, tailor management accordingly. HrIM diagnosis can indeed change the decision to a non-operative approach or a more selective surgical intervention. However, its cost effectiveness is not known, and this needs to be examined further.

Conflict of interests

None.