

Images in Clinical Hematology

Visceral leishmaniasis: amastigotes in the bone marrow



Thiago Rodrigo de Noronha, Ricardo Ambrósio Fock*

Hospital Universitário da Universidade de São Paulo (HU USP), São Paulo, SP, Brazil

ARTICLE INFO

Article history:

Received 12 December 2017

Accepted 20 June 2018

Available online 17 July 2018

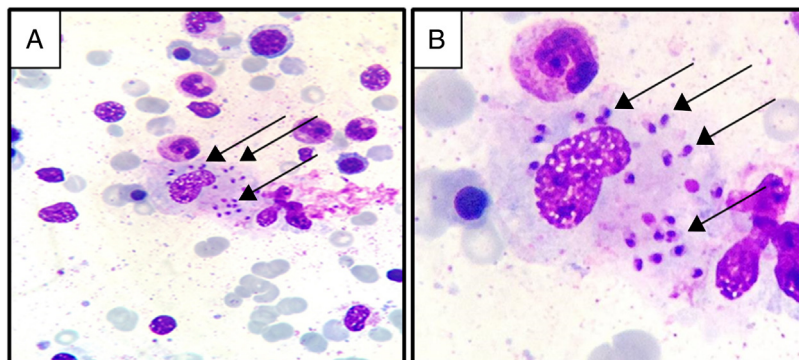


Figure 1 – Leishmania amastigotes phagocytosed by macrophages. Black arrows show amastigotes (May-Grünwald stain; (A) magnification: 400×, (B) magnification: 1000×).

A 50-year-old man came to the emergency room of a university hospital complaining of weight loss, fever and abdominal pain associated with hepatosplenomegaly. Laboratory investigations revealed pancytopenia with red blood cell (RBC) count of $2.35 \times 10^{12}/L$, hemoglobin 7.2 g/dL (RBCs with rouleaux

formation), platelets of $75.7 \times 10^9/L$, white blood cell count of $2.77 \times 10^9/L$ (with 58% neutrophils, 27% lymphocytes, 15% monocytes, 0% eosinophils and 0% basophils), hypoalbuminemia (1.31 g/dL) and hypergammaglobulinemia (6.63 g/dL). Serological test results were negative for antibodies for

* Corresponding author. Clinical Laboratory Division, Pharmacy and Clinical Laboratory Department, University Hospital, University of São Paulo. Av. Lineu Prestes, 2565. São Paulo, SP, Brazil. CEP: 05508-900. Tel.: +55 11 3091 3639..

E-mail address: hemato@usp.br (R.A. Fock).

<https://doi.org/10.1016/j.htct.2018.06.003>

2531-1379/© 2018 Associação Brasileira de Hematologia, Hemoterapia e Terapia Celular. Published by Elsevier Editora Ltda. This is an open access article under the CC BY-NC-ND license (<http://creativecommons.org/licenses/by-nc-nd/4.0/>).

hepatitis (B and C) and human immunodeficiency virus (HIV). Due to the laboratory findings and sustained pancytopenia, a bone marrow biopsy was performed which showed *Leishmania* amastigotes phagocytosed by macrophages (Figure 1) confirming the diagnosis of visceral leishmaniasis infection.^{1,2}

REFERENCES

1. Pagliano P, Esposito S. Visceral leishmaniasis in immunocompromised host: an update and literature review. *J Chemother.* 2017;29(5):261-6.
2. Koster KL, Laws HJ, Troeger A, Meisel R, Borkhardt A, Oommen PT. Visceral leishmaniasis as a possible reason for pancytopenia. *Front Pediatr.* 2015;29(3):59.