



CASE REPORT

Epstein-Barr Virus-Associated Vesiculopapular Eruption on the Face of a Patient with Natural Killer T Cell Lymphoma

Ji Soo Lim, Tae Min Kim¹, Kwang Hyun Cho

Departments of Dermatology and ¹Internal Medicine, Seoul National University Hospital, Seoul, Korea

Unlike typical hydroa vacciniforme (HV), Epstein-Barr virus (EBV)-associated HV-like eruption is more variable in its clinical manifestations. In some patients, progression to lymphoma or leukemia has been reported, which are characterized by the T-cell immunophenotype. Here, we report the first Korean case of EBV-associated vesiculopapular eruption on the face of a patient with natural killer (NK)/T cell lymphoma. A 32-year-old Korean man presented with a late adolescent-onset recurrent necrotic papulovesicles on his face. The patient was previously diagnosed with EBV-associated NK/T cell lymphoma of the oral cavity and also had childhood-onset hypersensitivity to mosquito bites. Biopsy of his facial skin showed EBV-associated vesiculopapular eruptions, though ultraviolet provocation did not reproduce the skin lesions. EBV viral load in his peripheral blood was detected but low. The patient was treated with systemic chemotherapy. The lymphoma went into remission, but the facial EBV-associated vesiculopapular eruption had a relapsing and remitting course. (*Ann Dermatol* 29(5) 618~620, 2017)

-Keywords-

Epstein-Barr virus, Epstein-Barr virus-associated hydroa

Received August 22, 2016, Revised November 8, 2016, Accepted for publication November 11, 2016

Corresponding author: Kwang Hyun Cho, Department of Dermatology, Seoul National University Hospital, 101 Daehak-ro, Jongno-gu, Seoul 03080, Korea. Tel: 82-2-2072-2417, Fax: 82-2-742-7344, E-mail: khcho@snu.ac.kr

This is an Open Access article distributed under the terms of the Creative Commons Attribution Non-Commercial License (<http://creativecommons.org/licenses/by-nc/4.0>) which permits unrestricted non-commercial use, distribution, and reproduction in any medium, provided the original work is properly cited.

Copyright © The Korean Dermatological Association and The Korean Society for Investigative Dermatology

vacciniforme-like eruption, Epstein-Barr virus-associated vesiculopapular eruption, hydroa vacciniforme, natural killer T cell lymphoma

INTRODUCTION

Epstein-Barr virus (EBV)-associated hydroa vacciniforme (HV)-like eruption has a spectrum of clinical manifestations, from benign course to fatal disease. In many cases, it is provoked by ultraviolet (UV) radiation. Progression to lymphoma or leukemia has been reported in some cases, which are characterized by the T-cell immunophenotype. Unlike typical HV, EBV-associated HV-like eruption can present at non sun-exposed areas, and patients may experience systemic symptoms such as fever and malaise¹⁻⁶. Iwatsuki et al.⁷ has reported that increased number of EBV DNA copies in the peripheral blood correlates with disease severity.

CASE REPORT

A 32-year-old Korean man presented with late adolescent-onset recurrent necrotic papulovesicles and localized swellings on his face. He had previously visited the Department of Otolaryngology regarding an ulcer at the hard palate of his oral cavity that had been present for two years, and had been diagnosed with EBV-associated natural killer (NK)/T cell lymphoma. He was subsequently admitted to the Department of Internal Medicine and consulted for skin lesions on his face. The scattered pruritic erythematous papulovesicles with partial crust formation had started about 17 years before (Fig. 1A), and had not well responded to intralesional triamcinolone injection,

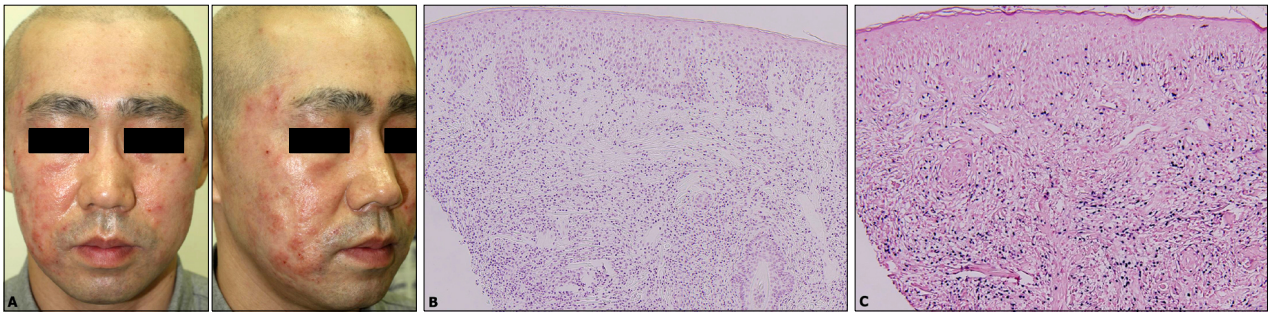


Fig. 1. (A) Mild erythematous and edematous papulovesicular eruptions on the patient's face. (B) Microscopic findings of small to medium sized lymphocytic infiltration through dermis (H&E, $\times 100$). (C) *In situ* hybridization. Epstein-Barr virus early RNA (EBER) positive lymphocytes are found in biopsy specimen (EBER, $\times 100$).

topical steroids and systemic steroids since then. The patient also described childhood-onset hypersensitivity to mosquito bites.

A skin biopsy showed small to medium-sized atypical lymphocytic infiltration through the dermis and subcutaneous layer with angiocentric and periadnexal patterns. Immunohistochemistry staining was CD-3 positive, CD-8 negative, CD-56 negative, granzyme B positive, and the Ki-67 proliferation index was 10%. The EBV *in situ* hybridization test was also positive (Fig. 1B, C). EBV was detected in a few bone marrow cells and in the cerebrospinal fluid (fewer than 100 copies/ml). EBV viral load in the peripheral blood was 51,370 copies/ml.

The patient was finally diagnosed with EBV-associated vesiculopapular eruption. He received six cycles of chemotherapy with ifosfamide, methotrexate, etoposide, and prednisolone (IMEP) and pegaspargase. The lymphoma had a complete response to treatment. Four months after chemotherapy, EBV viral load in the peripheral blood had decreased to 6,380 copies/ml. UVA provocation for five consecutive days at the gluteal region was both grossly and pathologically negative ($25 \sim 30 \text{ J/cm}^2/\text{d}$, total cumulative dose of 110 J). Despite the chemotherapy, the severity of his facial lesions had waxed and waned, and he was being monitored without further treatment.

DISCUSSION

EBV-associated HV-like eruption, previously termed atypical HV, is a rare chronic vesicular disease. It is associated with latent EBV infection, and scars remain after resolution^{3,6,8}. The pathogenesis of this condition remains unknown, but it is known to manifest clinically when EBV-infected T or NK cells are reactivated by various stimuli. Triggers may include UV irradiation and hypersensitivity to mosquito bites. However, with its etiology as yet unknown, this type of hypersensitivity could also be

interpreted as an overlap with the clinical manifestations of latent EBV infection⁸.

EBV-associated HV-like eruption primarily affects Asia and Latin America. Histological examination of the eruption demonstrates angiocentric and periadnexal infiltration of lymphocytes containing a few atypical cells. These characteristics led the World Health Organization to classify it as systemic EBV+ T-cell lymphoproliferative disease of childhood (associated with chronic active EBV infection) and HV-like lymphoma in 2008. However, due to its variable clinical presentation, it was re-classified in 2016 as systemic EBV+ T-cell lymphoma of childhood and HV-like lymphoproliferative disorder⁹.

When accompanied by hematologic malignancies, its immunophenotype is typically reported as T-cell lymphoma, NK-cell leukemia, or granular lymphocyte proliferative disorders. In our case, it is noteworthy that the patient had concomitant nasal NK/T cell lymphoma. Extranodal NK/T-cell lymphoma is representative of lymphomas associated with latent EBV latent infection, and its endemic presence in Asia, Central, and South America is similar to that of EBV-associated HV-like eruption. Histologically, its atypical lymphocytic infiltration and angiocentric distribution pattern were also similar to EBV-associated HV-like eruption, but it has not been reported to occur in concurrence with HV-like eruption. Zhang et al.¹⁰ reported facial HV-like eruptions as nasal type NK/T-cell lymphoma, which is distinct from our case, which had no systemic symptoms or invasion of other organs.

Patients with chronic EBV infections typically have a high EBV viral load in their peripheral blood. A higher number of EBV DNA copies has been reported in clinically severe HV-like eruption^{7,11}. It is important that despite having lymphoma, our patient had a relatively low viral load compared to other patients with chronic EBV infection or with severe HV-like eruption accompanied by malignancy¹.

In our case, the clinical presentation was atypical: EBV DNA copies were low, UV provocation produced a negative result, and facial eruption was mild despite the concurrent presence of lymphoma. This invites the question of whether the patient could also be described as having an EBV-associated HV-like eruption.

Given the widely variable range of clinical manifestations, the status of EBV-associated HV-like eruption should be reconsidered: is it an isolated disease entity, or one of the cutaneous manifestations of latent EBV infection? As such, we propose that 'EBV-associated vesiculopapular eruption of the face' would be a more appropriate term than EBV-associated HV-like eruption.

CONFLICTS OF INTEREST

The authors have nothing to disclose.

REFERENCES

1. Cho KH. Epstein-Barr virus associated hydroa vacciniforme-like eruption. *Korean J Dermatol* 2011;49:773-779.
2. Chen HH, Hsiao CH, Chiu HC. Hydroa vacciniforme-like primary cutaneous CD8-positive T-cell lymphoma. *Br J Dermatol* 2002;147:587-591.
3. Cho KH, Kim CW, Lee DY, Sohn SJ, Kim DW, Chung JH. An Epstein-Barr virus-associated lymphoproliferative lesion of the skin presenting as recurrent necrotic papulovesicles of the face. *Br J Dermatol* 1996;134:791-796.
4. Cho KH, Kim CW, Heo DS, Lee DS, Choi WW, Rim JH, et al. Epstein-Barr virus-associated peripheral T-cell lymphoma in adults with hydroa vacciniforme-like lesions. *Clin Exp Dermatol* 2001;26:242-247.
5. Tokura Y, Ishihara S, Tagawa S, Seo N, Ohshima K, Takigawa M. Hypersensitivity to mosquito bites as the primary clinical manifestation of a juvenile type of Epstein-Barr virus-associated natural killer cell leukemia/lymphoma. *J Am Acad Dermatol* 2001;45:569-578.
6. Huh SY, Choi M, Cho KH. A case of Epstein-Barr virus-associated hydroa vacciniforme. *Ann Dermatol* 2009;21:209-212.
7. Iwatsuki K, Satoh M, Yamamoto T, Oono T, Morizane S, Ohtsuka M, et al. Pathogenic link between hydroa vacciniforme and Epstein-Barr virus-associated hematologic disorders. *Arch Dermatol* 2006;142:587-595.
8. Cho KH, Li KS, Kim YK, Jeon YK, Kim CW, Lee SK, et al. Epstein-Barr virus associated lymphoproliferative lesion presenting as a hydroa vacciniforme-like eruption. *Korean J Dermatol* 2004;42:846-855.
9. Swerdlow SH, Campo E, Pileri SA, Harris NL, Stein H, Siebert R, et al. The 2016 revision of the World Health Organization classification of lymphoid neoplasms. *Blood* 2016;127:2375-2390.
10. Zhang G, Bai HX, Yang L, Ma MH, Su Y, Luo Y, et al. NK-/T-cell lymphoma resembling hydroa vacciniforme with positive CD4 marker expression: a diagnostic difficulty. *Am J Dermatopathol* 2013;35:94-97.
11. Maeda A, Wakiguchi H, Yokoyama W, Hisakawa H, Tomoda T, Kurashige T. Persistently high Epstein-Barr virus (EBV) loads in peripheral blood lymphocytes from patients with chronic active EBV infection. *J Infect Dis* 1999;179:1012-1015.